

We are IntechOpen, the world's leading publisher of Open Access books Built by scientists, for scientists

4,800

Open access books available

122,000

International authors and editors

135M

Downloads

Our authors are among the

154

Countries delivered to

TOP 1%

most cited scientists

12.2%

Contributors from top 500 universities



WEB OF SCIENCE™

Selection of our books indexed in the Book Citation Index
in Web of Science™ Core Collection (BKCI)

Interested in publishing with us?
Contact book.department@intechopen.com

Numbers displayed above are based on latest data collected.

For more information visit www.intechopen.com



Restorative and compensatory changes in the brain during early motor recovery from hemiparetic stroke: a functional MRI study

Hiroyuki Kato^a and Masahiro Izumiya^b

^a *Department of Neurology, International University of Health and Welfare Hospital, Nasushiobara, Japan*

^b *Department of Neurology, Sendai Nakae Hospital, Sendai, Japan*

1. Introduction

Stroke is a leading cause of disability in the elderly, and a considerable number of stroke patients suffer from residual motor deficits, particularly hemiparesis. There is a wide range of motor functional recovery after stroke, depending on the site, size and nature of the brain lesion (Duncan et al., 1992). Full recovery of hemiparesis is often observed when it is mild, and considerable recovery is not exceptional even after initial severe deficit. Functional recovery after stroke may be caused by resolution of acute effects of stroke, such as low blood flow, diaschisis and brain edema. However, functional gains may be prolonged past the period of this acute tissue response and its resolution. Stroke rehabilitation is introduced in order to promote brain plasticity and facilitate motor recovery. Understanding the mechanism of motor functional recovery after stroke is important because it may provide scientific basis for rehabilitation strategies.

Recent advances in non-invasive functional neuroimaging techniques, such as positron emission tomography (PET), functional MRI (fMRI) and near-infrared spectroscopy (NIRS), have enabled us to study directly the brain activity in humans after stroke (Herholz & Heiss, 2000; Calautti & Baron 2003; Rossini et al., 2003; Obrig & Villringer, 2003). Initial cross-sectional studies at chronic stages of stroke have demonstrated that the pattern of brain activation is different between paretic and normal hand movements, and suggested that long-term recovery is facilitated by compensation, recruitment and reorganization of cortical motor function in both damaged and non-damaged hemispheres (Chollet et al., 1991; Weiller et al., 1992; Cramer et al., 1997; Cao et al., 1998; Ward et al., 2003a). Subsequent longitudinal studies from subacute to chronic stages (before and after rehabilitation) have revealed a dynamic, bihemispheric reorganization of motor network, and emphasized the necessity of successive studies (Marshall et al., 2000; Calautti et al., 2001; Feydy et al., 2002; Ward et al., 2003b).

However, only limited data are available relating poststroke motor recovery to dynamic changes in cerebral cortical reorganization at the acute stage of stroke. We therefore measured the changes in cortical activation using fMRI during paretic hand movement both

at the acute stage of stroke (the first study within 7 days of onset) and at the chronic stage when motor recovery was obtained.

2. Materials and Methods

2.1 Subjects

We selected 9 ischemic stroke patients with mild hemiparesis without a history of prior stroke, who received fMRI study within 7 days of stroke onset. The patients presented with neurological deficit including hemiparesis, and were admitted to our hospital. They received standard stroke therapy and rehabilitation, and were discharged from the hospital, when they were independent regarding activities of daily living. They were 58-85 years of age, 8 males and 1 female, and all of them were right-handed. All the cerebral infarcts were evidenced by MRI, and were located in various regions of the cerebrum. The hand motor area was preserved in all patients. Six of the patients had left hemiparesis and 3 had right hemiparesis. They could move their hands, even though weakly, when the first fMRI was performed. No patients in this study had language or attention deficits. Clinical data are summarized in Table 1. Nine right-handed, normal subjects (40-81 years of age; 3 males and 6 females) served as controls. This study was approved by the ethics committee of our hospital and informed consent was obtained from all subjects in accordance with the Declaration of Helsinki.

	Age Sex	H	Stroke location	PMH	first fMRI			second fMRI		
					day	GS	fMRI pattern	day	GS	fMRI pattern
1	76M	L	R MCA branches	af	1d	33/25	Red/ Add	29d	36/34	Red (Am)
2	83M	L	R MCA posterior branch	HT	3d	32/30	Red	35d	30/31	Norm
3	65M	L	R MCA	HT	4d	24/24	Red/ Add	28d	NA	Add
4	58M	L	R thalamus	HT DM	2d	32/27	Red/ Add	24d	35/33	Norm
5	85M	L	R corona radiata	HT DM	4d	12/0	Red	88d	17/8	Red (Am)
6	75F	L	R corona radiata	HT	7d	13/0	Add	48d	16/13	Norm
7	70M	R	L corona radiata	HT	5d	30/35	Red	26d	39/38	Norm
8	79M	R	L corona radiata	-	6d	29/31	Add	20d	25/30	Norm
9	78M	R	L MCA-PCA watershed	HT	7d	33/36	Red/ Add	31d	33/35	Norm

Table 1. Patient characteristics

M = male; F = female; H = hemiparesis; R = right; L = left; MCA = middle cerebral artery; PCA = posterior cerebral artery; PMH = past medical history; af = atrial fibrillation; HT = hypertension; DM = diabetes mellitus; GS = grip strength in kg for right hand/left hand; d = day; NA = not available; fMRI pattern, Red = reduced activation; Add = additional activation; Red(Am) = reduction ameliorated; Red/Add = reduced activation + additional activation; Norm = activation normalized

2.2 Functional MRI

Two fMRI studies were performed over time in all patients, the first one within 7 days of stroke onset (4.3 ± 2.1 days; the mean value \pm SD) and the second one approximately 1 month later before they were discharged from the hospital (36.6 ± 20.9 days). The fMRI studies were performed using a 1.5 T Siemens Magnetom Symphony MRI scanner as described previously (Kato et al., 2002). Briefly, blood oxygenation level-dependent (BOLD) images (Ogawa et al., 1990) were obtained continuously in a transverse orientation using a gradient-echo, single shot echo planar imaging pulse sequence. The acquisition parameters were as follows: repetition time 3 s, time of echo 50 ms, flip angle 90° , 3-mm slice thickness, 30 slices through the entire brain, field of view 192×192 mm, and 128×128 matrix.

During the fMRI scan, the patients and normal controls performed sequential, self-paced hand movements (repeated closing and opening of the hand). This task performance occurred in periods of 30 s, interspaced with 30 s rest periods. The cycle of rest and task was repeated 5 times during each hand movement. Therefore, the fMRI scan of each hand movement took 5 min to complete, producing 3,000 images. A staff member monitored the patient directly throughout the study, and gave the start and stop signals by tapping gently on the knee, and confirmed the absence of mirror movements. All the stroke patients completed the task but the paretic hand movement appeared abnormal at the acute stage.

Data analysis was performed using Statistical Parametric Mapping (SPM) 99 (Wellcome Department of Cognitive Neurology, London, UK, <http://www.fil.ion.ucl.ac.uk/spm/>) implemented in MATLAB (The MathWorks Inc., Natick, MA, USA). After realignment and smoothing, the general linear model was employed for the detection of activated voxels. The voxels were considered as significantly activated if $p < 0.05$ (corrected for multiple comparison). All the measurements were performed with this same statistical threshold. The activation images were overlaid on corresponding T1-weighted anatomic images.

The criteria for the changes in the fMRI activation pattern in stroke patients were as follows. 1. A reduction of activation was considered when the area of activation was reduced to $< 50\%$ compared to that induced by unaffected hand movement of the patient. 2. An expansion of activation was considered when the area of activation was increased by $> 50\%$ compared with that induced by unaffected hand movement. 3. An appearance of activation was considered when a cluster of activation was induced in a region where unaffected hand movement induced no or little activation.

3. Results

3.1 Control subjects

In control subjects, each hand movement activated predominantly the contralateral primary sensorimotor cortex (SM1), supplementary motor areas (SMA), and the ipsilateral anterior lobe of the cerebellum (Cbll) (Fig. 1). Contralateral SM1 and ipsilateral Cbll were always involved with a variation between individuals, and SMA was activated in 6 of 9 subjects with more variation. Ipsilateral SM1 was slightly activated in 2 of 9 control subjects. There was no large difference between right and left hand movements.

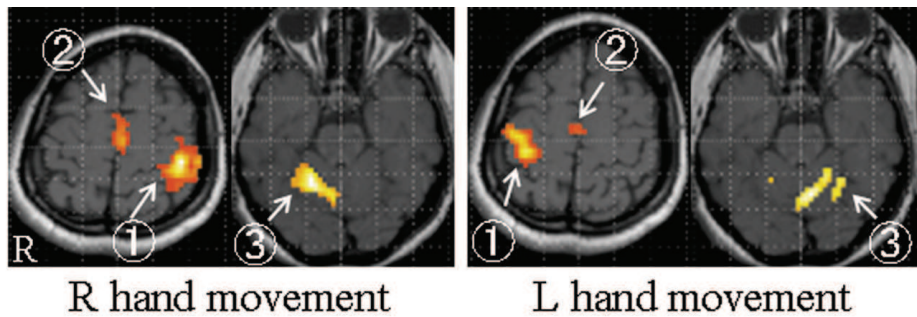


Fig.1. fMRI of a 40-year old normal female. Right or left hand movement activated contralateral primary sensorimotor cortex (①), supplementary motor areas (②), and ipsilateral anterior lobe of the cerebellum (③). There was no large difference between activations during right and left hand movements.

3.2 Stroke patients

During unaffected hand movements, the patients activated the same motor cortical areas as the control subjects did.

The brain activation pattern during paretic hand movements within 7 days of stroke onset (the first fMRI) was different from that during unaffected or normal hand movements (Figs. 2-4). There were two major findings.

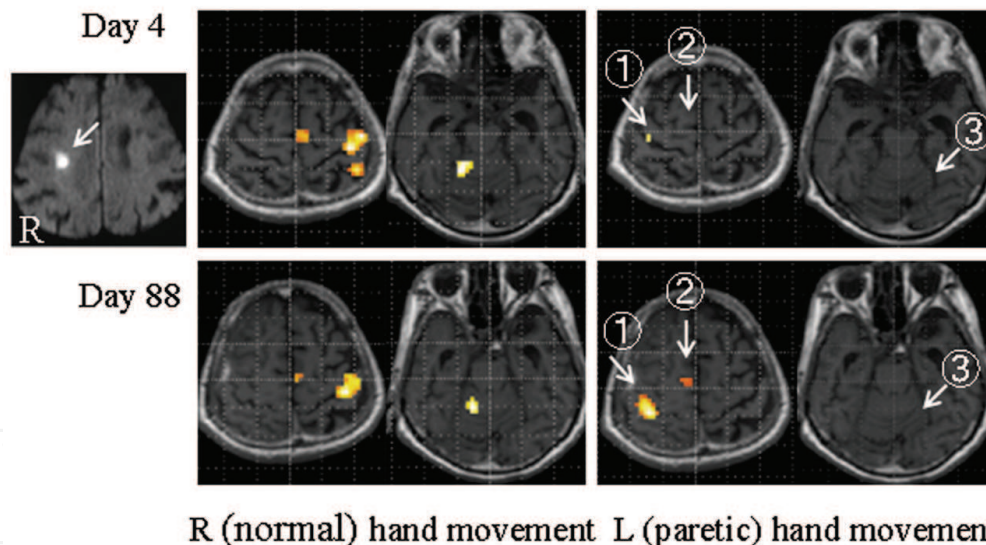


Fig. 2. fMRI of a 85-year old man (patient 5) who had a cerebral infarct in the right corona radiata near the motor hand area (arrow on the diffusion-weighted MRI). After 4 days of stroke onset, right (normal) hand movement induced a normal activation pattern in the left primary sensorimotor cortex, supplementary motor areas, and right cerebellum. During left (paretic) hand movement, activation in contralateral primary sensorimotor cortex (①) was reduced and no activation was seen in the supplementary motor areas (②) and the cerebellum (③). After 88 days, both right (normal) and left (paretic) hand movements induced a normal activation pattern except that no activation was induced in the cerebellum (③) during left (paretic) hand movement.

First, activations were reduced or lost in part or all of the normally activated regions (contralateral SM1, SMA, and ipsilateral Cbll) in 8 of 9 patients. Activation in contralateral SM1 was reduced or lost in 5 of 9 patients; in 4 of 4 patients with cortical infarction (Fig. 3) and in 1 of 5 patients with subcortical infarction (Fig. 2). In the latter patient, subcortical infarct was located near the motor hand area. In 4 of 5 patients with subcortical infarction, in contrast, activation in contralateral SM1 was preserved. Even when contralateral SM1 was activated, there was a posterior or ventral shift or expansion of activation in 2 patients.

Ipsilateral cerebellar activation was reduced or lost in 5 of 9 patients. SMA activation was reduced or lost in 4 of 7 patients who activated SMA during unaffected hand movement.

Second, a recruitment of additional motor-related areas was seen in 4 of 9 patients. The additional activations were observed in ipsilateral SM1 (4 patients), contralateral Cbll (1 patient), premotor cortex (bilateral in 1 patient and ipsilateral in 1 patient), and bilateral parietal cortex (1 patient) (Fig. 4).

At the second fMRI study approximately 1 month later, the brain activation pattern during paretic hand movement had returned to normal in 7 of 9 patients and near normal in 2 other patients. Additional activation was still seen in ipsilateral SM1 in 1 patient.

4. Discussion

In this study, we observed a remarkable difference in cerebral cortical activation between affected and unaffected hand movements at the acute stage of stroke (within 7 days of onset). Paretic hand movement-induced brain activation may be reduced markedly in cortical areas that are normally activated by unaffected hand movements (contralateral SM1, SMA, and ipsilateral Cbll). The reduction of SM1 activation was observed predominantly in patients with cortical infarction and was exceptional in patients with subcortical infarction. Early recruitment of additional motor-related areas (ipsilateral SM1 in particular and secondary motor areas) may occur. At the chronic stage (the second fMRI), brain activations during paretic hand movement had returned to normal or near-normal. Thus, early motor recovery after stroke was accompanied by two major changes on fMRI, i.e., restoration of brain activity and recruitment of additional brain activity.

We wanted to investigate into motor-related brain activation, and selected such patients who could move their hands, even though weakly, when the first fMRI study was performed within 7 days of stroke onset. As a result, we needed to select stroke patients with mild motor deficit and resultant excellent recovery because patients with poor motor function cannot perform the task of this study. This a priori limited the scope of the findings of our study. Furthermore, the motor performance of the paretic hand was not normal and one may point out that the brain activities during paretic and unaffected hand movements cannot be compared.

But our results suggest that motor functional recovery occurred primarily using the standard motor system when damage to it was mild or partial, recruiting functionally related motor areas when necessary as a compensatory strategy. The recruitment of additional activation of motor-related areas was often transient. Therefore, this additional activation may reflect compensation and unmasking or disinhibition of existing motor network which is masked or inhibited under normal conditions since the activation appeared early after stroke. Of interest is that these restorative and compensatory changes occurred within the first month after stroke, and this period seemed critical to motor functional recovery.

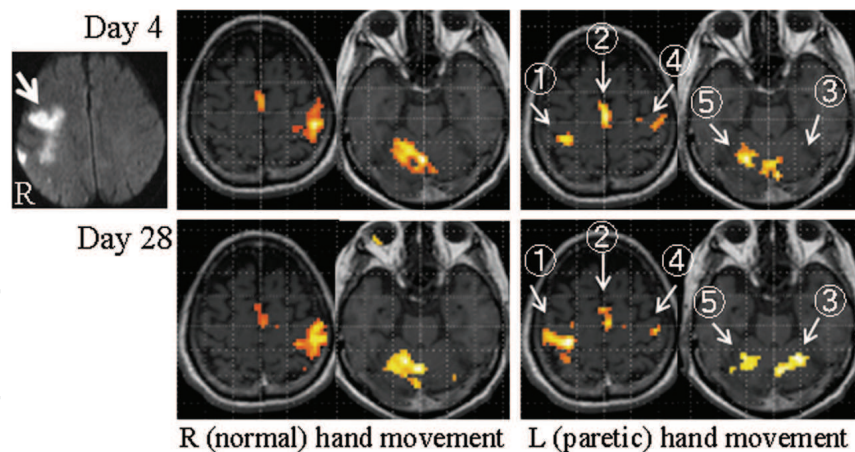


Fig. 3. fMRI of a 65-year old man (patient 3) who had a cerebral infarct in the right middle cerebral artery territory (arrow on the diffusion-weighted MRI). After 4 days of stroke onset, right (normal) hand movement induced normal activation in the left primary sensorimotor cortex, supplementary motor areas, and the right cerebellum. During left (paretic) hand movement, activation in the contralateral primary sensorimotor cortex (①) was reduced and that in the ipsilateral cerebellum (③) was lost. Activations in ipsilateral primary motor cortex (④) and contralateral cerebellum (⑤) were observed. Activation in the supplementary motor areas (②) appeared normal. After 28 days, activations in contralateral primary sensorimotor cortex (①) and ipsilateral cerebellum (③) had been normalized. Activations in ipsilateral primary motor cortex (④) and contralateral cerebellum (⑤) were still seen. Right (normal) hand movement induced a normal activation pattern.

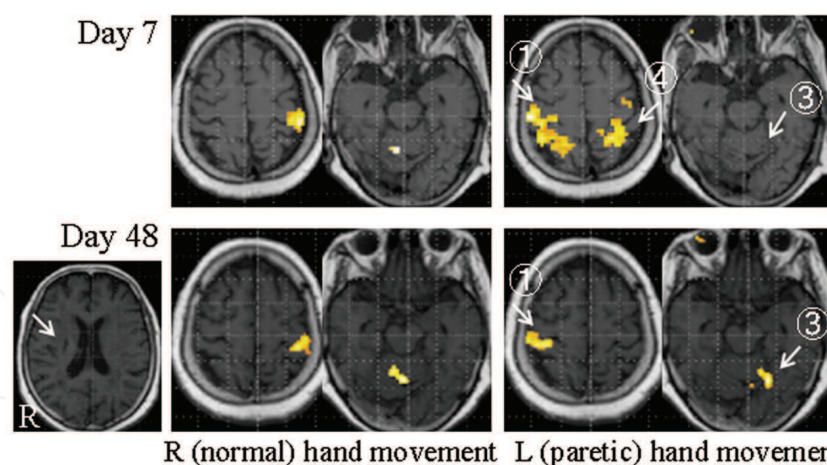


Fig. 4. fMRI of a 75-year old female (patient 6) who had a cerebral infarct in the right corona radiata (arrow on the T1-weighted MRI). After 7 days of stroke onset, right (normal) hand movement induced normal activation in the left primary sensorimotor cortex and the right cerebellum. No activation was seen in the supplementary motor areas in this patient. During left (paretic) hand movement, extensive activation was seen in bilateral primary sensorimotor and parietal cortices (① and ④) but no activation was seen in the supplementary motor areas and the cerebellum (③). After 48 days, both paretic (left) and normal (right) hand movements induced a normal activation pattern.

Earlier functional neuroimaging studies on poststroke cerebral reorganization from subacute to chronic stages revealed several activation patterns during paretic hand movement (Ward & Cohen, 2004; Jang, 2007). These include (1) a posterior shift of contralateral SM1 activation (Pineiro et al., 2001; Calautti et al., 2003) or peri-infarct reorganization after primary motor cortex infarction (Cramer et al., 1997; Jang et al., 2005a), (2) a shift of primary motor cortex activation to the ipsilateral (contralesional) cortex (Chollet et al., 1991; Marshall et al., 2000; Feydy et al., 2002), (3) contribution of the secondary motor areas (Cramer et al., 1997; Carey et al., 2002; Ward et al., 2006), and (4) higher contralateral activity in the cerebellar hemisphere (Small et al., 2002). In the present study, we observed similar additional activation patterns at the acute stage of stroke. The earlier studies have also shown that the expanded activations may later decrease with functional improvements, which was also true in many of our acute stroke patients. The contralesional shift of activation may return to ipsilesional SM1 activation with functional gains (Feydy et al., 2002; Takeda et al., 2007), but worse outcome may correlate with a shift in the balance of activation toward the contralesional SM1 (Calautti et al., 2001; Feydy et al., 2002; Zemke et al., 2003). Thus, the patterns of cerebral activation evoked by hand movement show impaired organization and reorganization of brain motor network, and best recovery may depend on how much original motor system is reusable. The patterns of activation may also be dependent on the patient's ability to recruit residual portions of the bilateral motor network (Silvestrini et al., 1998).

The fMRI findings need to be considered within the context of technical and task-dependent factors. The fMRI mapping obtained by the BOLD technique is dependent on the spatial extent of hemodynamic changes induced by local synaptic activity and field potentials (Logothetis et al., 2001). Localization of neural activity may be confounded by many factors (Ugurbil et al., 2003). BOLD-dependent capillary density and draining veins and the perfusion of brain tissue may differ between damaged and undamaged tissues, especially at acute stages of stroke. fMRI activation can even be lost in stroke patients because of altered vasomotor reactivity, demonstrating uncoupling of neuronal activity and fMRI activation (Rossini et al., 2004; Binkofski & Seitz 2004; Murata et al., 2006). In our study, paretic hand movement at the acute stage resulted in reduced motor cortex activation in the damaged hemisphere, especially in patients with cortical infarction. This reduced activation may be due not only to impaired neural activity but also to this uncoupling when cerebral infarction was close to the SM1. Thus, we need to be cautious when interpreting fMRI results at the acute stage of stroke. In contrast, patients with subcortical infarction did not usually display a reduction in motor cortex activation because the lesion was distant from the motor cortex.

Of interest is the determinant of fMRI activation patterns induced by paretic hand movement. Motor system reorganization may also be influenced by stroke topography (Feydy et al., 2002; Luft et al., 2004), time after stroke (Ward et al., 2004), and stroke side (Zemke et al., 2003). Cortical motor organizations between dominant and non-dominant hand movements may be different, and non-dominant hand movements are more bilaterally organized (Kim et al., 1993). Furthermore, the performance of complex motor tasks is accompanied by bilateral activation of motor cortices in contrast to simple motor tasks that result in only contralateral activation (Shibasaki et al., 1993). Hemiparesis would increase task difficulty. When task demand increases, more regions would be activated by a motor task. Improvement in motor skills may depend on rehabilitation, handedness, motivation, and age-related capacity for plasticity. Then motor reorganization after stroke may be

obtained depending on a number of factors. If motor reorganization is related to the degree of damage to the pyramidal tract, information on the sensorimotor projections would help further understand the brain reorganization in the context of structure and function. Diffusion tensor imaging tractography, which non-invasively visualizes the pyramidal tract using the water molecule diffusion characteristics in the white matter, may be the tool to analyze its integrity (Masutani et al., 2003). The combination of fMRI and tractography of the pyramidal tract would further elucidate the mechanism of motor functional recovery after stroke (Jang et al., 2005b).

The ipsilateral primary motor cortex activation may be seen slightly in normal subjects and we cannot distinguish whether the ipsilateral motor activities found in stroke patients existed prior to stroke or are a result of brain plasticity. Furthermore, we do not know whether additional activation that appeared after stroke really contributed to motor functional recovery. With regard to these fundamental points, of interest are the findings of experimental studies using animal models. Nishimura et al. (2007) have shown using a monkey model of unilateral pyramidal tract injury that motor recovery involves bilateral primary motor cortex during the early recovery stage and more extensive regions of contralesional primary motor cortex and bilateral premotor cortex during the late recovery stage. Nudo et al. (1996) and Frost et al. (2003) used an ischemic brain injury model in the monkey and showed substantial enlargement of the hand representation within the primary motor cortex and the ventral premotor cortex. These animal studies suggest that reorganization in brain motor network provides a neural substrate for adaptive motor behavior and plays a critical role in the recovery of motor function after stroke.

5. Conclusion

We investigated the changes in cortical activation using fMRI during paretic hand movement both at the acute stage of stroke and at the chronic stage when motor recovery was obtained. The findings of this study suggest that early motor recovery after stroke occurs primarily using the standard motor system, by recovering from reversible injury and by recruiting related motor areas for functional compensation. fMRI is an important tool for revealing the capacity and progress of rehabilitation-dependent changes in the brain motor network after stroke, and provides a neuroscientific basis for stroke rehabilitation. Future studies should clarify the relation between the motor recovery mechanisms and clinical outcome, and the importance of the critical period that greatly influences motor functional recovery after stroke.

6. Acknowledgments

We thank the staff members of the MRI section of Sendai Nakae Hospital, Ms. Fumi Kozuka, Ms. Satsuki Ohi, Mr. Takeru Ohmukai, Ms. Yoko Sato, Ms. Aya Kanai, and Mr. Katsuhiro Aki, for their help to perform fMRI studies. We also thank Dr. Naohiro Saito, Department of Physiology, Tohoku University School of Medicine, Sendai, Japan, for his expert assistance on the fMRI-spm99 analysis.

This study was supported by Grant-in-Aid for Scientific Research (16500352 and 19500458), Japan Society for the Promotion of Science, and by CREST, Japan Science and Technology Agency.

7. References

- Binkofski, F. & Seitz, R.J. (2004). Modulation of the BOLD-response in early recovery from sensorimotor stroke. *Neurology*, 63, 1223-1229
- Calautti, C.; Leroy, F.; Guincestre, J.Y. & Baron, J.-C. (2001). Dynamics of motor network overactivation after striatocapsular stroke: a longitudinal PET study using a fixed-performance paradigm. *Stroke*, 32, 2534-2542
- Calautti, C. & Baron, J.-C. (2003). Functional neuroimaging studies of motor recovery after stroke in adults. A review. *Stroke*, 34, 1553-1566
- Calautti, C.; Leroy, F.; Guincestre, J.Y. & Baron, J.-C. (2003). Displacement of primary sensorimotor cortex activation after subcortical stroke: a longitudinal PET study with clinical correlation. *Neuroimage*, 19, 1650-1654
- Cao, Y.; D'Olhaberriague, L.; Vikingstad, E.M.; Levine, S.R. & Welch, K.M.A. (1998). Pilot study of functional MRI to assess cerebral activation of motor function after poststroke hemiparesis. *Stroke*, 29, 112-122
- Carey, J.R.; Kimberley, T.J.; Lewis, S.M.; Auerbach, E.J.; Dorsey L.; Rundquist, P. & Ugurbil, K. (2002). Analysis of fMRI and finger tracking training in subjects with chronic stroke. *Brain*, 125, 773-788
- Chollet, F.; DiPiero, V.; Wise, R.J.S.; Brooks, D.J.; Dolan, R.J. & Fracowiak, R.S.J. (1991). The functional anatomy of motor recovery after stroke in humans: a study with positron emission tomography. *Ann. Neurol.*, 29, 63-71
- Cramer, S.C.; Nelles, G.; Benson, R.R.; Kaplan, J.D.; Parker, R.A.; Kwong, K.K.; Kennedy, D.N.; Finklestein, S.P. & Rosen, B.R. (1997). A functional MRI study of subjects recovered from hemiparetic stroke. *Stroke*, 28, 2518-2527
- Duncan, P.W.; Goldstein, L.B.; Matchar, D.; Divine, G.W. & Feussner, J. (1992). Measurement of motor recovery after stroke: outcome measures and sample size requirements. *Stroke*, 23, 1084-1089
- Feydy, A.; Carlier, R.; Rody-Brami, A.; Bussel, B.; Cazalis, F.; Pierot, L.; Burnod, Y. & Maier, M.A. (2002). Longitudinal study of motor recovery after stroke: recruitment and focusing of brain activation. *Stroke*, 33, 1610-1617
- Frost, S.B.; Barbay, S.; Friel, K.M.; Plautz, E.J. & Nudo, R.J. (2003). Reorganization of remote cortical regions after ischemic brain injury: a potential substrate for stroke recovery. *J. Neurophysiol.*, 89, 3205-3214
- Herholz, A. & Heiss, W.-D. (2000). Functional imaging correlates of recovery after stroke in humans. *J. Cereb. Blood Flow Metab.*, 20, 1619-1631
- Jang S.H. (2007). A review of motor recovery mechanisms in patients with stroke. *NeuroRehabilitation*, 22, 253-259
- Jang, S.H.; Ahn, S.H.; Yang, D.S.; Lee, D.K.; Kim, D.K. & Son, S.M. (2005a). Cortical reorganization of hand motor function to primary sensory cortex in hemiparetic patients with a primary motor cortex infarct. *Arch. Phys. Med. Rehabil.*, 86, 1706-1708
- Jang, S.H.; Kwon, Y.-H.; You, S.H.; Song, J.C.; Lee, M.Y.; Kim, J.H.; Park, K.H. & Cho, Y.W. (2005b). Medial reorganization of motor function demonstrated by functional MRI and diffusion tensor tractography. *Restor. Neurol. Neurosci.*, 23, 265-269
- Kato, H.; Izumiyama, M.; Koizumi, H.; Takahashi, A. & Itoyama, Y. (2002). Near-infrared spectroscopic topography as a tool to monitor motor reorganization after hemiparetic stroke. A comparison with functional MRI. *Stroke*, 33, 2032-2036


- Kim, S.-G.; Ashe, J.; Hendrich, K.; Ellermann, J.M.; Merkle, H.; Ugurbil, K. & Georgopoulos, A.P. (1993). Functional magnetic resonance imaging of motor cortex: hemispheric asymmetry and handedness. *Science*, 261, 615-617
- Logothetis, N.; Pauls, J.; Augath, M.; Trinath, T. & Oeltermann, A. (2001). Neurophysiological investigation of the basis of the fMRI signal. *Nature*, 412, 150-157
- Luft, A.R.; Waller, S.; Forrester, L.; Smith, G.V.; Whittall, J.; Macko, R.F.; Schulz, J.B. & Hanley, D.F. (2004). Lesion location alters brain activation in chronically impaired stroke survivors. *Neuroimage*, 21, 924-935
- Marshall, R.S.; Perera, G.M.; Lazar, R.M.; Krakauer, J.W.; Constantine, R.C. & DeLaPaz, R.L. (2000). Evolution of cortical activation during recovery from corticospinal tract infarction. *Stroke*, 31, 656-661
- Masutani, Y.; Aoki, S.; Abe, O.; Hayashi, N. & Otomo, K. (2003). MR diffusion tensor imaging: recent advance and new techniques for diffusion tensor visualization. *Eur. J. Radiol.*, 46, 53-66
- Murata, Y.; Sakatani, K.; Hoshino, T.; Fujiwara, N.; Kano, T.; Nakamura, S. & Katayama, Y. (2006). Effects of cerebral ischemia on evoked cerebral blood oxygenation responses and BOLD contrast functional MRI in stroke patients. *Stroke*, 37, 2514-2520
- Nishimura, Y.; Onoe, H.; Morichika, Y.; Perfiliev, S.; Tsukada, H. & Isa, T. (2007). Time-dependent central compensatory mechanisms of finger dexterity after spinal cord injury. *Science*, 318, 1150-1155
- Nudo, R.J.; Wise, B.M.; SiFuentes, F. & Milliken, G.W. (1996). Neural substrate for the effects of rehabilitative training on motor recovery after ischemic infarct. *Science*, 272, 1791-1794
- Obrig, H. & Villringer, A. (2003). Beyond the visible – imaging the human brain with light. *J. Cereb. Blood Flow Metab.*, 23, 1-18
- Ogawa, S.; Lee, T.M.; Kay, A.R. & Tank, D.W. (1990). Brain magnetic resonance imaging with contrast dependent on blood oxygenation. *Proc. Natl. Acad. Sci. U.S.A.*, 87, 9868-9872
- Pineiro, R.; Pendlebury, S.; Johansen-Berg, H. & Matthews, P.M. (2001). Functional MRI detects posterior shifts in primary sensorimotor cortex activation after stroke. Evidence of local adaptive reorganization? *Stroke*, 32, 1134-1139
- Rossini, P.M.; Calautti, C.; Pauri, F. & Baron, J.C. (2003). Post-stroke plastic reorganization in the adult brain. *Lancet Neurol.*, 2, 493-502
- Rossini, P.M.; Altamura, C.; Ferretti, A.; Vernieri, F.; Zappasodi, F.; Caulo, M.; Pizzella, V.; Del Gratta, C.; Romani, G.-L. & Tecchio, F. (2004). Does cerebrovascular disease affect the coupling between neuronal activity and local haemodynamics? *Brain*, 127, 99-110
- Shibasaki, H.; Sadato, N.; Lyshkow, H.; Yonekura, Y.; Honda, M.; Nagamine, T.; Suwazono, S.; Magata, Y.; Ikeda, A.; Miyazaki, M.; Fukuyama, H.; Asato, R. & Konishi, J. (1993). Both primary motor cortex and supplementary motor area play an important role in complex finger movement. *Brain*, 116, 1387-1398
- Silvestrini, M.; Cupini, L.M.; Placidi, F.; Diomedì, M. & Bernardi, G. (1998). Bilateral hemispheric activation in the early recovery of motor function after stroke. *Stroke*, 29, 1305-1310
- Small, A.L.; Hlustik, P.; Noll, D.C.; Genovese, C. & Solodkin, A. (2002) Cerebellar hemispheric activation ipsilateral to the paretic hand correlates with functional recovery after stroke. *Brain*, 125, 1544-1557

- Takeda, K.; Gomi, Y.; Imai, I.; Shimoda, N.; Hiwatari, M. & Kato, H. (2007). Shift of motor activation areas during recovery from hemiparesis after cerebral infarction: a longitudinal study with near-infrared spectroscopy. *Neurosci. Res.*, 59, 136-144
- Ugurbil, K.; Toth, L. & Kim, D.S. (2003). How accurate is magnetic resonance imaging of brain function? *Trends Neurosci.*, 26, 108-114
- Ward, N.S.; Brown, M.M.; Thompson, A.J. & Frackowiak, R.S.J. (2003a). Neural correlates of outcome after stroke: a cross-sectional fMRI study. *Brain*, 126, 1430-1448
- Ward, N.S.; Brown, M.M.; Thompson, A.J. & Frackowia, R.S.J. (2003b). Neural correlates of motor recovery after stroke: a longitudinal fMRI study. *Brain*, 126, 2476-2496
- Ward, N.S.; Brown, M.M.; Thompson, A.J. & Frackowiak, R.S.J. (2004). The influence of time after stroke on brain activations during a motor task. *Ann. Neurol.*, 55, 829-834
- Ward, N.S. & Cohen, L.G. (2004). Mechanisms underlying recovery of motor function after stroke. *Arch. Neurol.*, 61, 1844-1848
- Ward, N.S.; Newton, J.M.; Swayne, O.B.; Lee, L.; Thompson, A.J.; Greenwood, R.J.; Rothwell, J.C. & Frackowiak, R.S. (2006). Motor system activation after subcortical stroke depends on corticospinal system integrity. *Brain*, 129(Pt. 3), 809-819
- Weiller, C.; Chollet, F.; Friston, K.J.; Wise, R.J. & Frackowiak, R.S. (1992). Functional reorganization of the brain in recovery from striatocapsular infarction in man. *Ann. Neurol.*, 315, 463-472
- Zemke, A.C.; Heagerty, P.J.; Lee, C. & Cramer, S.C. (2003). Motor cortex organization after stroke is related to side of stroke and level of recovery. *Stroke*, 34, e23-28

IntechOpen

IntechOpen

IntechOpen



Neuroimaging

Edited by Cristina Marta Del-Ben

ISBN 978-953-307-127-5

Hard cover, 136 pages

Publisher Sciyo

Published online 17, August, 2010

Published in print edition August, 2010

Neuroimaging has become a crucial technique for Neurosciences. Different structural, functional and neurochemical methods, developed in recent decades, have allowed a systematic investigation on the role of neural substrates involved in functions performed by the central nervous system, whether normal or pathological. This book includes contributions from the general area of the neuroimaging to the understanding of normal functions and abnormalities of the central nervous system.

How to reference

In order to correctly reference this scholarly work, feel free to copy and paste the following:

Hiroyuki Kato and Masahiro Izumiyama (2010). Restorative and Compensatory Changes in the Brain During Early Motor Recovery from Hemiparetic Stroke: a Functional MRI Study, *Neuroimaging*, Cristina Marta Del-Ben (Ed.), ISBN: 978-953-307-127-5, InTech, Available from:

<http://www.intechopen.com/books/neuroimaging/restorative-and-compensatory-changes-in-the-brain-during-early-motor-recovery-from-hemiparetic-strok>

INTECH

open science | open minds

InTech Europe

University Campus STeP Ri
Slavka Krautzeka 83/A
51000 Rijeka, Croatia
Phone: +385 (51) 770 447
Fax: +385 (51) 686 166
www.intechopen.com

InTech China

Unit 405, Office Block, Hotel Equatorial Shanghai
No.65, Yan An Road (West), Shanghai, 200040, China
中国上海市延安西路65号上海国际贵都大饭店办公楼405单元
Phone: +86-21-62489820
Fax: +86-21-62489821

© 2010 The Author(s). Licensee IntechOpen. This chapter is distributed under the terms of the [Creative Commons Attribution-NonCommercial-ShareAlike-3.0 License](https://creativecommons.org/licenses/by-nc-sa/3.0/), which permits use, distribution and reproduction for non-commercial purposes, provided the original is properly cited and derivative works building on this content are distributed under the same license.

IntechOpen

IntechOpen