

We are IntechOpen, the world's leading publisher of Open Access books Built by scientists, for scientists

4,800

Open access books available

122,000

International authors and editors

135M

Downloads

Our authors are among the

154

Countries delivered to

TOP 1%

most cited scientists

12.2%

Contributors from top 500 universities



WEB OF SCIENCE™

Selection of our books indexed in the Book Citation Index
in Web of Science™ Core Collection (BKCI)

Interested in publishing with us?
Contact book.department@intechopen.com

Numbers displayed above are based on latest data collected.

For more information visit www.intechopen.com



Robotic Surgery of the Colon: The Peoria Experience

Steven S Tsoraides, M.D., M.P.H., Franziska Huettner, M.D., P.h.D.,
Arthur L Rawlings M.D., M.Div. and David L Crawford, M.D.
*Department of Surgery, University of Illinois College of Medicine at Peoria, Illinois
USA*

1. Introduction

The application of robotics in surgery has expanded since its introduction not so long ago. Robotic surgery is promoted by hospitals and sought out by patients. Residency programs are including training in robotics and the next generation of surgeons is becoming more facile with robotic procedures. Use of robotics in surgery has been applied to general surgical, gynecologic, urologic, and cardiac procedures.

As this technology expands, many questions arise. Cost is a major concern, as are the resources and staffing necessary for robotic procedures. Although these debates are ongoing, it is clear that the technology is expanding and robotics will continue to be promoted and applied. Here we present our experience with robotic colectomy and discuss some of the pertinent issues related to this topic.

2. Background and history

Robotic surgery developed as a project of the Department of Defense with the goal of enabling a surgeon to operate remotely from a patient. Although its application in this aspect has not been realized, robotic systems have advanced, and it is now the private sector which has taken on this technology. The Automated Endoscopic System for Optimal Position (AESOP) was the first robotic system approved for intraabdominal surgery by the Food and Drug Administration (FDA) in 1993 (Computer Motion, Goleta, California) (Oddsdottir et al., 2004). This computerized robotic camera assistant is used in laparoscopic surgery. The voice-activated system allows a surgeon to control the visual field while keeping his/her hands free for operating.

The da Vinci system (Intuitive Surgical, Inc., Sunnyvale, California) was introduced in 1997 and approved by the FDA in 2000. This system allows for direct manipulation and dissection capabilities and has become the only available "robotic" system. The first robotic procedure using the da Vinci system was a cholecystectomy performed in Brussels in 1997 (Kelley, 2002).

The da Vinci system includes a surgeon's console, a surgical cart, and the vision tower. Although newer generations are available, the basic concepts are similar. The surgeon's console includes binocular monitors, foot pedals, and hand-held masters for manipulation of the surgical instruments and camera. The robot is draped into the field and includes up to

Source: Robot Surgery, Book edited by: Seung Hyuk Baik,
ISBN 978-953-7619-77-0, pp. 172, January 2010, INTECH, Croatia, downloaded from SCIYO.COM

four surgical arms, one for the camera, two for the operating surgeon's hands, and a fourth as an assistant arm. The vision tower includes similar equipment to a laparoscopic tower: an insufflator, light source, camera, and printer, as well as the 3-D image synchronizing hardware.

Participating as a university-affiliated, community training program at the University of Illinois College of Medicine at Peoria, The Peoria Surgical Group became the first private practice owner of the da Vinci system in 2002. The system has since been purchased by the local hospital, and a second hospital in our community also has a da Vinci system. More recently, one of our hospitals has purchased a recent generation da Vinci Si HD system. Robotic procedures are performed by general and cardiac surgeons, urologists, and gynecologists. A wide variety of general surgical procedures have been performed, including foregut and colon operations. We will focus our discussion on a single-surgeon (DLC) experience with robotic colectomy.

Right colectomy was the first laparoscopic procedure performed on the colon by Moises Jacobs in 1990 in Miami (Jacobs et al., 1991). Robotic-assisted colectomy was reported eleven years later in 2001 (Ballantyne et al., 2001). Multiple reports have since been published on robotic colectomy, including our own results. The benefits of cosmesis and recovery translate similarly to both techniques. Robotic surgery can be applied in both benign and malignant disease as long as appropriate principles are adhered to. Although controversy still exists as to the application of minimally invasive techniques in the treatment of rectal malignancies, multiple reports in the recent literature describe the use of the robot in performing pelvic dissection. It seems the benefits of using the robot in colorectal surgery are most appreciated in performing a total mesorectal excision, where the constraints of the pelvis limit maneuverability with common laparoscopic instruments. Although this area will likely receive more attention in the near future, it is not part of the senior author's practice currently.

3. Procedures

The decision to proceed with a robotic colectomy is made after discussion between the operating surgeon and the patient. Of the three hospitals in our community, two have a da Vinci system available. If the patient is a candidate for minimally invasive surgery and has been scheduled at one of these two hospitals, they are offered the option of robotic surgery. These cases are typically scheduled as the first case of the day to allow for adequate staffing and preparation. Indications for surgery are similar to those for laparoscopic colectomy. Procedures performed include Robotic Right Colectomy and Robotic Sigmoid Colectomy.

3.1 Robotic right colectomy

Robotic Right Colectomy is performed with the patient in the supine position. The patient is placed on a bean bag and the bag wraps the left arm. The chest and legs are secured to the table with conventional straps on the legs and heavy tape at the level of the clavicles (Image 1). These measures are essential given the degree and variation of positioning necessary to carry out the procedure. Once pneumoperitoneum is established, trocars are placed as depicted in Figure 1. The camera is placed through the 12mm periumbilical trocar. With the omentum retracted cranially, the planned point of division of the transverse colon and mesocolon are marked with endoclips based on the right branch of the middle colic artery. The terminal ileum is also run for 20-30cm to ensure it is not fixed in the pelvis, as it must reach the transverse colon for anastomosis. The table is then tilted to the left and slightly

head down to allow the small bowel to retract out of the visual field and to encourage the omentum to stay above the transverse colon. The robot is positioned over the right upper quadrant and the camera and instruments are docked. The robot's right/green arm is placed through the 5mm epigastric trocar and the left/yellow arm is placed through the 5mm right lower quadrant trocar. A five millimeter trocar is inserted in the left lower quadrant for use by an assistant in retracting and exposing the ileocolic vascular pedicle. A grasper placed through the 12mm left lateral abdominal wall port can be used to hold the transverse mesocolon up and out of the way.

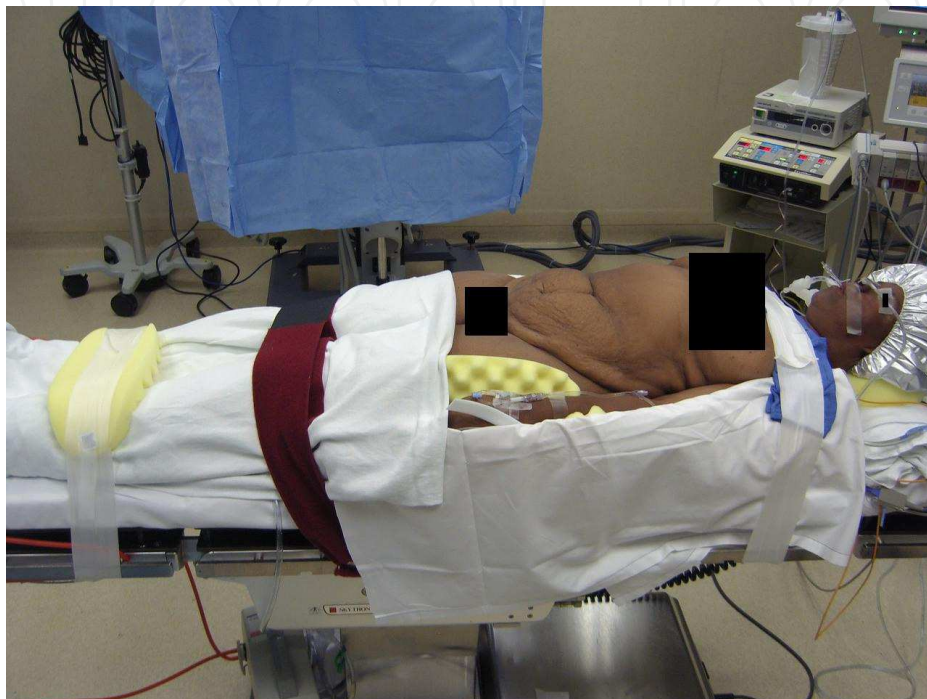

Image 1. Patient Positioning

We proceed with a medial to lateral dissection by dividing the ileocolic vascular pedicle with a vascular load laparoscopic stapler at the level of the duodenum. The right mesocolon is then mobilized from Gerota's fascia. After identification of the ureter, the ileal mesentery is divided using a harmonic energy device to a point ten centimeters proximal to the ileocecal valve. Once the entire right colon is mobilized out to the abdominal wall and around to the duodenal sweep, attention is directed to the transverse mesocolon. The previously incised or clipped line on the mesocolon is found and the right branch of the middle colic artery is identified. Clips and vascular staplers are used as needed to control this at its base. The mesocolon is then divided with a harmonic device up to the colon. The transverse colon and ileum are then divided intracorporeally with a laparoscopic stapler, however the right colon remains attached to its lateral peritoneal attachments to keep it retracted laterally. Once the transverse colon is divided, we improve the view in the area of the final attachments of the colon to the head of the pancreas as well as the distal stomach and duodenum. These final attachments are taken down with harmonic energy or clips until the specimen is free.

An intracorporeal anastomosis is then created in an isoperistaltic side-to-side fashion between the ileum and transverse colon. The ileum is adjoined to the transverse colon 6cm from the end of the ileum using a 30cm 2-0 silk suture on a Keith needle. This needle is then

externalized in the right upper quadrant and clamped externally for retraction (Image 2). A harmonic energy device is then used to create enterotomies, through which the ends of an

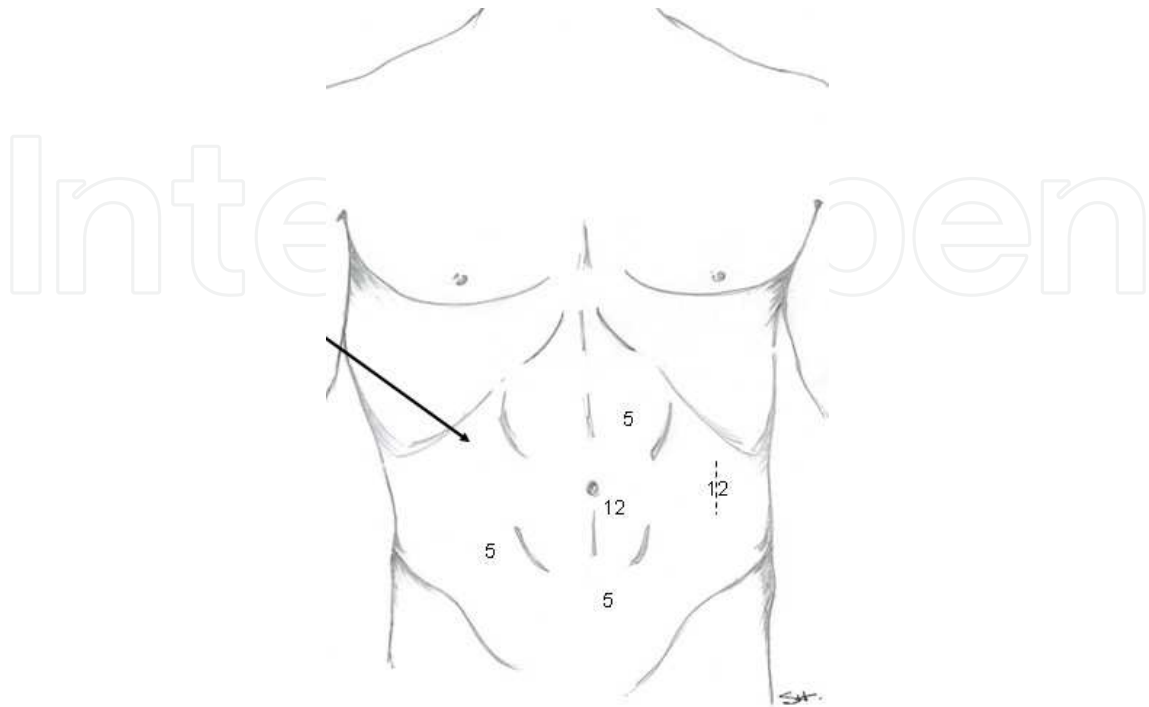


Fig. 1. Trocar Placement for Robotic Right Colectomy.

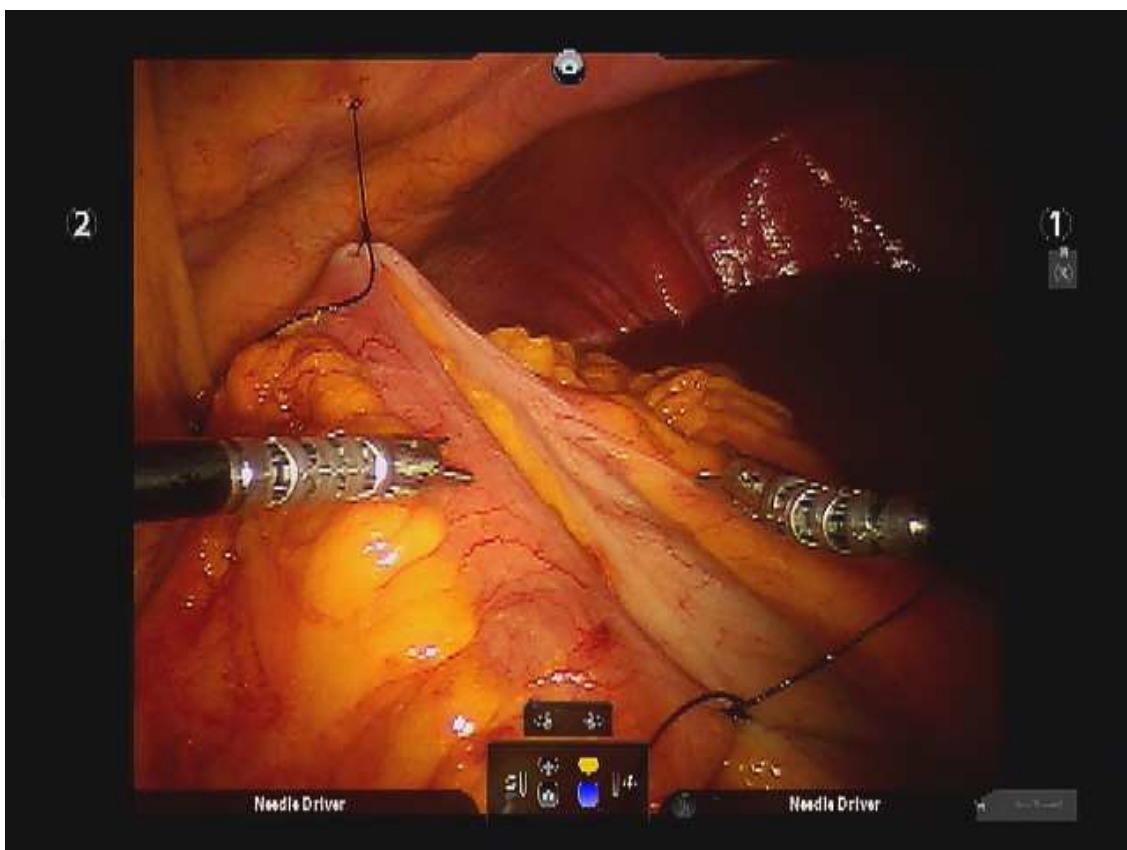


Image 2. Bowel Alignment for Intracorporeal Ileocolic Anastomosis

endoscopic linear cutting stapler are inserted through the left lateral 12mm trocar and the stapler is fired. The defect is closed with a running 2-0 absorbable braided suture. The mesenteric defect is then closed with absorbable suture. The retracting 2-0 silk suture is divided and the lateral attachments of the right colon are taken down with a harmonic device or cautery. The specimen is extracted through the left lateral 12mm trocar site, which is extended to approximately four centimeters to accommodate extraction. The wound is protected with a bag to prevent contact with the specimen. Standard closure techniques are then followed.

3.2 Robotic Sigmoid Colectomy

Robotic Sigmoid Colectomy is performed with the patient in a supine modified lithotomy position, in which the anterior thighs are in the same plane as the abdominal wall. The patient is placed on a bean bag so that the bag can wrap the right arm and the chest is secured to the table with heavy tape at the clavicles. Trocars are placed as seen in Figure 2 after pneumoperitoneum is obtained. The procedure is begun with the patient in a steep right sided tilt and reverse Trendelenburg position. The robot is brought in from the left side of the patient (see arrow a, Figure2). The right/green arm and its trocar are slipped through the suprapubic 12mm port or the arm can be docked to the left lateral abdominal wall 5mm robot port. The left/yellow arm is docked to the epigastric port. A harmonic energy device is used in the left arm and a grasper in the right. The splenic flexure is taken down by dividing the gastrocolic ligament then elevating the mesocolon off of Gerota's fascia. Downward and medial retraction by the assistant from the right sided trocars is invaluable. Electrocautery can be used for the latter portion of this mobilization over Gerota's fascia but harmonic energy is particularly helpful with the thick and often vascular gastrocolic ligament. Visualization of the ligament of Treitz through the mesentery marks the medial extent of proximal mobilization. The inferior mesenteric vein is selectively taken for benign diagnoses and routinely taken for malignant. Because left ureter visualization medially is

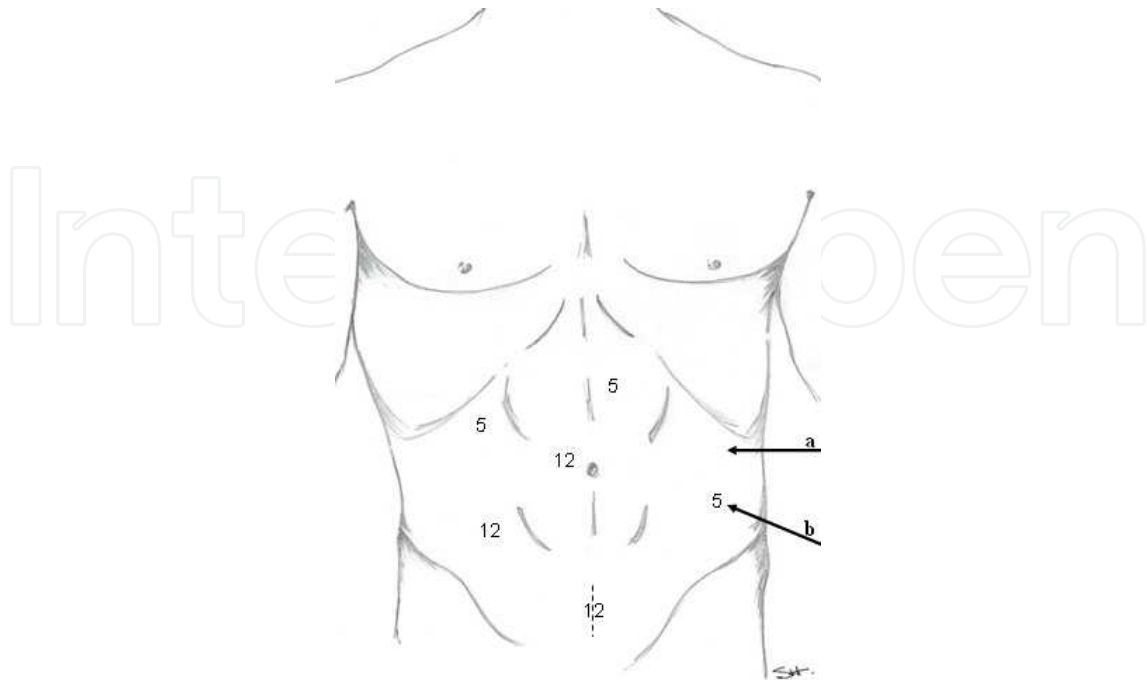


Fig. 2. Trocar Placement for Robotic Sigmoid Colectomy.

the goal all the way to the pelvic brim, changing table position is required. The robot is disengaged and drawn back from the table. The patient is placed in Trendelenberg position and the robot is brought in from the left hip (see arrow b, Figure 2). The right/green arm and its trocar are slipped through the right lower quadrant 12mm port and cautery or harmonic energy device is attached. The left/yellow arm is connected to the left lateral abdominal wall robot trocar and a grasper is inserted. The sigmoid colon is elevated and the inferior mesenteric vascular pedicle is demonstrated. The peritoneum on the right side of the rectosigmoid colon is scored at its base and the inferior mesenteric artery is isolated. The rectosigmoid colon is then mobilized circumferentially down to the desired level on the rectum while visualizing both ureters.

At this point the robot is disengaged and endoscopic staplers are used to divide the inferior mesenteric artery and the rectum. The suprapubic port is extended to accommodate externalization of the specimen through a protecting bag. After proximal division of the colon and resection of the specimen, the anvil of an end-to-end anastomotic stapler is secured into the end of the colon. The colon is returned to the abdomen and the fascia is closed to allow for reestablishment of the pneumoperitoneum. The stapler is then inserted transanally through the rectum and attached to the anvil and fired. We routinely test our anastomoses with insufflation. Standard closure techniques are then followed.

Post operative care is similar to that in patients undergoing laparoscopic colectomy, with an emphasis on quicker recovery times. Clear liquids are offered the day of surgery and early ambulation is encouraged. Patient controlled analgesia is employed until patients are tolerating diet and oral medicines. Epidurals are not used. Criteria for discharge include tolerance of liquids, ability to void, adequate pain control with oral analgesics and evidence of bowel function. Follow up visits are scheduled within one to two weeks from the day of discharge.

4. Methods

Institutional Review Board (IRB) approval was obtained. From 2002 to 2009 a total of 102 consecutive robotic colectomies were performed by a single surgeon (DLC) at two institutions with varying amounts of resident participation. Data was recorded in a Statistical Package for the Social Services (SPSS) database prospectively and a retrospective review of this data was performed.

5. Results

One-hundred and two robotic colectomies were performed. Procedures included 59 right colectomies and 43 sigmoid colectomies. For all colectomies, average patient age was 63.5 years (22-86). Forty-nine patients were male and 53 were female. Preoperative indications included polyps in 53 patients, diverticular disease in 27 patients, cancer in 19 patients, and carcinoid in 3 patients.

Total operative time for all cases averaged 219.6 minutes \pm 45.1, with an average robot time of 126.6 minutes \pm 41.6. For right colectomies port time averaged 32.4 minutes \pm 10.5, robot time 145.2 minutes \pm 39.6, and total case time 212.3 minutes \pm 46.4. For the sigmoid colectomies port time averaged 31.2 minutes \pm 9.6, robot time 101.2 minutes \pm 29.2, and total case time 229.7 minutes \pm 41.6.

Average blood loss was 66.6 milliliters. Four procedures were converted to laparoscopy and five to an open approach, with an overall conversion rate of 8.8%. Complications occurred in

19 patients with an overall complication rate of 18.6%. Anastomotic leak occurred in one patient (0.98%). Median length of stay for all patients was 3 days with a range of 2 to 27 days.

6. Discussion

The advance of technology in the recent era of surgery has outpaced the ability of the medical community to adequately interrogate the true utility of certain techniques prior to their widespread adoption. Often hospitals and patients within a community seeking the latest technology become a driving force for surgeons to adopt new techniques. Ideally, the benefit of these measures are examined and discussed within the surgical community prior to their establishment as "common practice." Many surgeons would argue that the true role for robotics in surgery is yet to be properly defined. Certainly there is an appeal for hospitals in marketing themselves as centers offering robotic surgery, and for surgeons to be promoted as regional experts in robotics and minimally invasive surgery. Although they may not know why, patients request robotic surgery in the hopes that they are receiving the most advanced care possible. We as surgeons, however, must decide when the application of robotics is truly advantageous.

There is no doubt that the robot enhances the technical ability of the surgeon in ways that common laparoscopic techniques currently do not. The wristed instruments increase the maneuverability of the operating instruments with two more degrees of freedom than traditional laparoscopic instruments. The robot adds internal pitch and yaw to the pitch, yaw, grasp, rotation, and in-and-out motions of the laparoscopic instruments. The end result is that the instruments mimic the motion of a surgeon's hands with the added benefits of tremor reduction and motion scaling. Confined spaces such as the pelvis and mediastinum provide arenas where these benefits are best realized.

The visualization offered by the da Vinci system also serves as an enhancement to traditional laparoscopy. A stereoscopic camera allows for representation in both two-dimensional and three-dimensional views. The three-dimensional view provides a clarity and depth of field which further improves the surgeon's ability to discriminate among tissue planes. Furthermore, the surgeon has the added benefit of control over the camera with one of the robot arms. This eliminates the frustration that can be met with inexperienced or fatigued camera operators and enhances the ability of the surgeon to complete difficult maneuvers in an efficient fashion.

Another benefit of robotics not to be overlooked is the reduction of surgeon fatigue. The long term toll of laparoscopy on an individual surgeon may still not be fully realized given the fairly recent adoption of laparoscopy into the every day practice of many surgeons. Over the course of a twenty to thirty year career, the stresses of awkward positioning and maneuvering may prove to be detrimental to the health of many operating surgeons. During a robotic procedure, the surgeon is sitting comfortably with arms and head resting against padded surfaces. Recentering of hand controls eliminates the cumbersome task of maintaining positions beyond the normal range of comfort and convenience. Control of the visual field with the head comfortably supported reduces the neck strain often encountered during many laparoscopic procedures. Although the immediate benefit to any given patient is difficult to demonstrate, the pending dilemma of physician shortage reminds us that

physician longevity is perhaps more important than previously thought. The robotic model presents an opportunity to minimize surgeon fatigue that may warrant further investigation. These advantages must be weighed against the disadvantages of using the robot for any given procedure. System-based considerations include staffing and accessibility. Staff must be properly educated on setup and troubleshooting to ensure that robotic procedures can be completed without undue delay. Often, an increased number of skilled staff is required to execute a robotic procedure. Operative suites must be of adequate size to accommodate the robot while at the same time ensure procedures not requiring the robot be unhindered by its presence. Rooms must be fashioned in a way that allows for effective surgeon to staff communication, as the traditional prominence of the surgeon standing over the patient is altered in robotic surgery.

Technically, the loss of tactile sensation and the ability to accurately gauge “strength” presents a challenge to the operating surgeon. The risk of patient injury is increased if the surgeon is unfamiliar with these limitations and visual clues become very important to the surgeon when handling tissue. Also limiting is the difficulty in operating in the far lateral extensions of the operative field, where robot arms are restricted from operating beyond a certain distance. Robot arms can interfere with each other outside the patient as well, creating an added challenge not encountered in traditional laparoscopy. Port placement, experience, and planning are critical in minimizing the incidence of this problem. Unlike traditional laparoscopy, instruments and camera are not conveniently interchanged to accommodate the various fields encountered in a given procedure. The robot must be moved in and out of the docked position to accomplish significant alterations in port, camera, and instrument positions. This is often timely and cumbersome. An important goal with any robotic procedure is to minimize time wasted with repositioning of the robot. Positioning of the patient too is important. Laparoscopy often requires frequent and exaggerated position changes to assist in retraction and accessibility of tissues. This must be anticipated in any robotic case, as most patient position changes require repositioning of the robot as well.

The largest concern, of course, is cost. The system itself is expensive to acquire, as are instruments and the disposable equipment required for robotic cases. Often, increased time and staffing are required to accommodate robotic procedures. No specific reimbursement pattern exists to recuperate these costs. Whether private or nationally supported, a payer source must be able to justify the cost of the technology for it to survive in modern health care. This is an ongoing debate, and the outcome of this debate may determine what role robotics plays in the future.

In our previous review, adjusted to 2005 US dollars, robotic colectomy carried a 15% greater total hospital cost compared to laparoscopic colectomy, although there was not statistical significance. In 17 robotic right colectomy cases, average total hospital cost was \$9,255 compared to \$8,073 for laparoscopic cases (Rawlings et al., 2007). Little else has been published regarding cost data, despite the fact that this is often a matter of debate. Delaney et al. also showed a higher total hospital cost for robotic procedures, with a \$350 difference in operating room and equipment costs (Delaney et al., 2003). These costs have to be taken on by the operating institution. Interestingly, it is often these same institutions pushing surgeons to utilize the technology, despite the lack of avenues to directly regain the

difference in cost. This cost, in some ways, can be considered a “marketing” expense that institutions assume when purchasing the da Vinci system. Any surgeon considering performing robotic surgery must also consider the local financial and institutional environment and should have support from their institution prior to employing robotics within their practice. Surgeons should be open about cost issues with both their patients and their institutions to avoid misconceptions about this significant matter.

Taking the above issues into consideration, one must ask “why robotics?” Certainly there are advantages and disadvantages, as there are many proponents and perhaps even more opponents to robotic surgery. When looking at the literature, we find that it is difficult to show a clear outcomes benefit to patients when comparing laparoscopy to robotic surgery of the colon. Multiple authors have reported their experiences and common points of discussion typically include operative time, cost, length of stay and complications. From 2004, we have identified five papers reporting experience with robotic surgery of at least 30 patients, as well as our own (Table 1). Here we discuss these papers.

Author	Year	n	Total Case Time (min)	Conversion	Complications
Luca	2009	55	290	0	12
Baik	2009	56	190.1	0	6
Spinoglio	2008	50	383.8	2	7
Crawford	2008	70	225	8	8
Hellan	2007	39	285	1	5
Crawford	2006	30	226	2	6
D'Annibale	2004	53	240	6	4

Table 1. Publications of Robotic Colon Surgery with at least 30 patients

When looking at the literature, operative time for robotic surgery of the colon typically ranges from 200 to 300 minutes, however some reach almost 400 minutes. In the papers we have focused on, average reported total procedure time is 262.8 minutes in 353 robotic colon cases. This includes all types of cases, from right colectomy to intersphincteric resection and APR. Conversion occurred in 19 (5.4%) cases with 9 to laparoscopic and 9 to open. Outcomes from robotic colectomy reflect those of laparoscopic colectomy. Complications were reported in 48 (13.6%) of the 353 patients with 14 (4.0%) representing anastomotic leak. Our low anastomotic leak rate and operative time compare favorably to these results. Our conversion rate was slightly higher, but similar to these results.

In considering available series discussing robotic surgery of the colon, we find a good deal of inconsistency in the data collected. Conversion tends to be a rather infrequent occurrence, with conversion to both conventional laparoscopy and laparotomy (Table 2). Operative times vary, and no clear trend can be identified between operative experience and total case time. Outcomes also vary, but here too it seems results are comparable to those in conventional laparoscopic surgery. Certainly it can be argued that robotic surgery is safe and feasible for surgery of the colon when considering patient outcomes. The increase in operative time may be a concern when dealing with patients of increased preoperative morbidity, and we advocate surgeon discretion in these scenarios.

Author	Year	n	Total Case Time (min)	Conversion	Conversion Type	
					Laparotomy	Laparoscopy
Crawford	2009	102	219.6 (50-380)	9	5	4
Luca	2009	55	290 (164-487)	0		
Baik	2009	56	190.1 (120.0-315.0)	0		
Choi	2009	13	260.8 (210-390)	0		
Spinoglio	2008	50	383.8	2	1	1
Baik	2008	18	217.1 (149-315)	0		
Crawford	2008	70	225 (147-380)	8	5	3
Baik	2007	9	220.8 (153-315)	0		
Hellan	2007	39	285 (180-540)	1	1	0
DeNoto	2006	11	197 (145-345)	1	0	1
Crawford	2006	30	226 (90-340)	2	2	0
Ayav	2005	6	172 (45 - 280)	1	1	0
Braumann	2005	5	201 (80-300)	2	2	0
Anvari	2005	6	109 (90 - 160)	0		
Woeste	2004	4	236.7	1	1	
D'Annibale	2004	53	240	5	0	5
Anvari	2004	10	155.3	0		
Ayav	2004	5	265 (180 - 240)	1	1	
Hanly	2004	35	177	5	5	0
Hubens	2004	7	NA	0		
Ewing	2004	12	248 (180-350)	0		
Delaney	2003	6	216.5 (170 - 274)	1	0	1
Giulianotti	2003	16	211 (90 - 360)	0		
Vibert	2003	3	380 (330 - 450)	0		
Weber	2002	2	284 (228 - 340)	0		
Hashizume	2002	3	260 (180 - 335)	0		

Table 2. Series of Robotic Surgery of the Colon

Also deserving mention is the role robotic technology plays in surgical training programs. Graduating surgeons must be familiar with modern techniques in order to remain relevant to contemporary practice. Although robotic surgery is not considered mainstream at the current time, being familiar with the technology and the opportunities it presents are important assets to have. Resident involvement in robotic surgery plays an important role at our institution. The residents participate in robotic cases starting their first year of training. During the first and second years of training the residents attend a half day course that includes didactic lectures on the history and development of robotic surgery. They also receive hands on instruction with the device regarding setup, instrument exchanges, robot positioning and troubleshooting. They then receive individual instruction while sitting at the surgeon's console with dexterity exercises and suturing. During this early stage the

resident assists the surgeon while standing at the operating table. Over time, according to training level, interest, and operative talent, the residents become more involved in performing more integral portions of the procedure from the surgeon’s console. Senior residents often do more than 90% of the case, while the attending surgeon remains as assistant and instructor at the operating table.

When looking at our data, we find that resident involvement in robotic cases increases throughout training (Table 3). The exception to this is the fourth year of training due to the increased time spent on trauma and night float rotations. As the resident advances, we also see that the number of cases in which he or she performs >90% of the procedure also increases, along with the total cases participated in. It has been the senior author’s observation that the formal incorporation of robotic training in the curriculum has allowed residents to learn robotic techniques in an effective manner. Most residents are able to adapt to the technology quickly, often with less difficulty than in traditional laparoscopic surgery. This involvement has an added benefit in the recruitment of future residents. Allowing significant resident involvement in robotic surgery reassures applicants that they are pursuing a program which will not only expose them to, but train them in cutting edge techniques with cutting edge technology. We see this technology, therefore, advancing within academic training centers, where new applications and adaptations to robotics can be developed and applied.

Resident involvement by training level

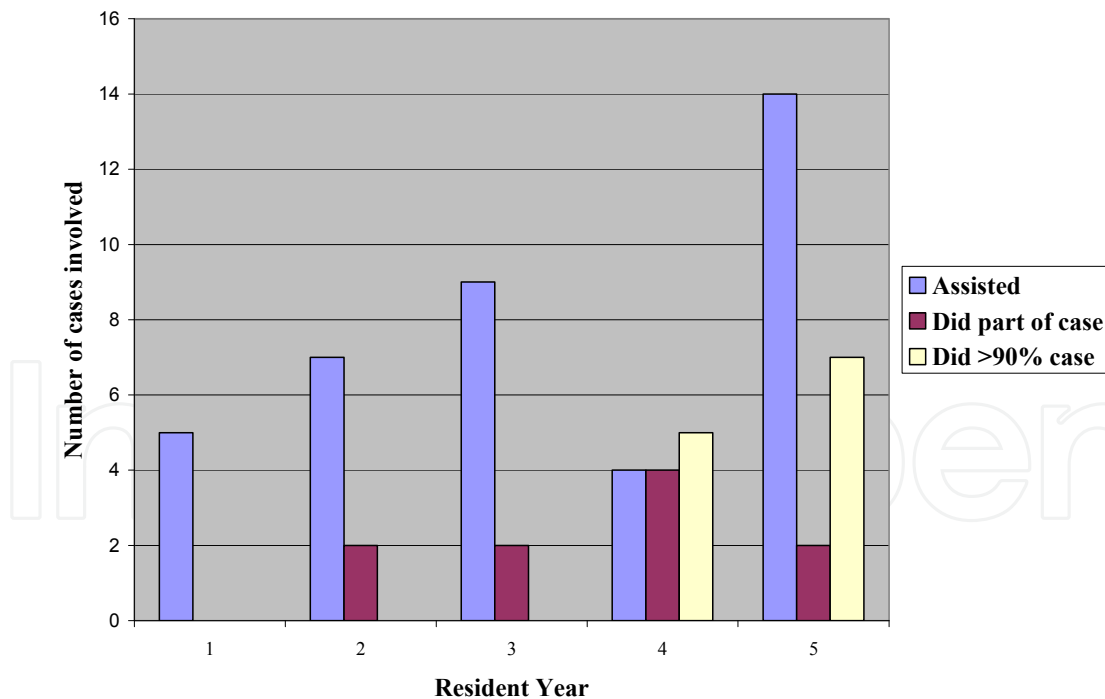


Table 3. Resident Involvement in Robotic Cases According to Training Level

6.1 Conclusion

Robotic technology has presented many opportunities and controversies for surgeons. Many are quick to adopt new technology, while others remain skeptical of the true benefits

of robotics in abdominal surgery. We have presented our experience with robotic surgery in order to further the discussion of this matter in regards to surgery of the colon. How robotics will continue to be employed in colonic procedures remains to be settled. Certainly, the technology will continue to evolve, and perhaps be adapted to take on different forms and purposes. As attention turns to natural orifice surgery and single incision laparoscopic procedures, robotic technology may provide solutions for limitations in these areas. Regardless of outcome, it is essential as surgeons and academicians, that we continue this debate for the purpose of enhancement of our profession and improvement in patient outcomes.

Illustrations by Steven Henriques, M.D.

7. References

- Anavari M, Birch, D, Bamehriz F, Gryfe R, Chapman T (2004) Robotic-assisted laparoscopic colorectal surgery. *Surgical Laparoscopy, Endoscopy and Percutaneous Techniques* 14(6): 311-15
- Anavari M, McKinley C, Stein H (2005) Establishment of the world's first telerobotic remote surgical service for provision of advanced laparoscopic surgery in a rural community. *Annals of Surgery* 241(3): 460-64
- Ayav A, Bresler L, Brunaud L, Boissel P (2004) Early results of one-year robotic surgery using the da vinci system to perform advanced laparoscopic procedures. *Journal of Gastrointestinal Surgery* 8(6): 720-26
- Ayav A, Bresler L, Hubert J, Brunaud L, Boissel P (2005) Robotic-assisted pelvic organ prolapse surgery. *Surgical Endoscopy* 19(9): 1200-03
- Baik SH, Ko YT, Kang CM, Lee WJ, Kim NK, Sohn SK, Chi HS, Cho CH (2008) Robotic tumor-specific mesorectal excision of rectal cancer: short-term outcome of a pilot randomized trial. *Surg Endosc* 22:1601-1608
- Baik SH, Kwon HY, Kim JS, Hur H, Sohn SK, Cho CH, Kim H (2009) Robotic versus laparoscopic low anterior resection of rectal cancer: short-term outcome of a prospective comparative study. *Ann Surg Oncol* 16:1480-1487
- Baik SH, Lee WJL, Rha KH, Kim NK, Sohn SK, Chi HS, Cho CH, Lee SK, Cheon JH, Ahn JB, Kim WH (2007) Robotic total mesorectal excision for rectal cancer using four robotic arms. *Surg Endosc* 22:792-797
- Ballantyne G, Merola S, Weger P, Wasielewski A (2001) Robotic solutions to the pitfalls of laparoscopic colectomy. *Osp Ital Chir* 7: 405-12
- Braumann, C, Jacobi C, Menenakos C, Borchert U, Rueckert J, Mueller J (2005) Computer-assisted laparoscopic colon resection with the da vinci system: our first experiences. *Diseases of the Colon and Rectum* 48(9): 1820-27
- Choi GS, Park IJ, Kang BM, Lim KH, Jun SH (2009) A novel approach of robotic-assisted anterior resection with transanal or transvaginal retrieval of the specimen for colorectal cancer. *Surg Endosc* 2009 May 14. (Epub ahead of print)
- D'Annibale A, Morpurgo E, Fiscon V, Trevisan P, Sovernigo G, Orsini C, Guidolin D (2004) Robotic and laparoscopic surgery for treatment of colorectal diseases. *Diseases of the Colon and Rectum* 47(12): 2162-68

- Delaney C, Lynch A, Senagore A, Fazio V (2003) Comparison of robotically performed and traditional laparoscopic colorectal surgery. *Dis Colon Rectum* 46: 1633-39
- DeNoto G, Rubach E, Ravikumar TS (2006) A standardized technique for robotically performed sigmoid colectomy. *J Laparoendosc Adv Surg Tech A* 16(6): 551-6
- Ewing DR, Pigazzi A, D'Annibale A, Morpurgo E, Fiscon V, Haag BL, Ballantyne GH (2004) Telerobotic laparoscopic colorectal surgery. In: Ballantyne GH, Marescaux J, Giulianotti P (eds) *Primer of robotic and telerobotic surgery*. Lippincott Williams and Wilkins, Philadelphia, pp 171-180
- Giulianotti P, Coratti A, Angelini M, Sbrana F, Cecconi S, Balestracci T, Caravaglio G (2003) Robotics in general surgery: personal experience in a large community hospital. *Archives of Surgery* 138(7): 777-84
- Hanly E, Talamini M (2004) Robotic abdominal surgery. *The American Journal of Surgery* 188(4A): 19S-26S
- Hashizume M, Shimada M, Tomikawa M, Ikeda Y, Takahashi I, Abe R, Foga F, Gotoh N, Konishi K, Maehara S, Sugimachi K (2002) Early experience of endoscopic procedures in general surgery assisted by a computer-enhanced surgical system. *Surgical Endoscopy* 16(8): 1187-91
- Hellan M, Anderson C, Ellenhorn JDI, Paz B, Pigazzi A (2007) Short-term outcomes after robotic-assisted total mesorectal excision for rectal cancer. *Annals of Surgical Oncology* 14(11): 3168-73
- Hubens G, Ruppert M, Balliu L, Vaneerdeweg W (2004) What have we learnt after two years working with the da vinci robot system in digestive surgery? *Acta chirurgica Belgica* 104(6): 609-14
- Huettner F, Rawlings AL, McVay WB, Crawford DL (2008) Robot-assisted laparoscopic colectomy: 70 cases - one surgeon. *J Robotic Surg* 2: 227-34
- Jacobs M, Verdeja J, Goldstein H (1991) Minimally invasive colon resection (laparoscopic colectomy). *Surg Laparosc Endosc* 1(3): 144-50
- Kelley W (2002) Robotic surgery: The promise and early development. *Laparoscopy* 1:6-10
- Luca F, Cenciarelli S, Valvo M, Pozzi S, Faso FL, Ravizza D, Zampino G, Sonzogni A, Biffi R (2009) Full robotic left colon and rectal cancer resection: technique and early outcome. *Ann Surg Oncol* 16:1274-78
- Oddsottir M, Birgisson G (2004) AESOP: A voice-controlled camera holder, In: *Primer of Robotic & Telerobotic Surgery*, Ballantyne G, Marescaux J, Gulianotti P. (Ed.), pp. 35-41, Lippincott Williams & Wilkins, ISBN 0-7817-4844-5, Philadelphia
- Rawlings AL, Woodland JH, Crawford DL (2006) Telerobotic surgery for right and sigmoid colectomies: 30 consecutive cases. *Surg Endosc* 20: 1713-18
- Rawlings AL, Woodland JH, Vegunta RK, Crawford DL (2007) Robotic versus laparoscopic colectomy. *Surgical Endoscopy* 21: 1701-08
- Spinoglio G, Summa M, Priora F, Quarati R, Testa S (2008) Robotic colorectal surgery: first 50 cases experience. *Dis Colon Rectum* 51: 1627-32
- Vibert E, Denet C, Gayet B (2003) Major digestive surgery using a remote-controlled robot: the next revolution. *Archives of Surgery* 138(9): 1002-06

- Weber P, Merola S, Wasielewski A, Ballantyne G (2002) Telerobotic-assisted laparoscopic right and sigmoid colectomies for benign disease. *Dis Colon Rectum* 45: 1689-1696
- Woeste G, Bechstein W, Wullstein C (2005) Does telerobotic assistance improve laparoscopic colorectal surgery? *Int J Colorectal Dis* 20(3):253-7

IntechOpen

IntechOpen



Robot Surgery

Edited by Seung Hyuk Baik

ISBN 978-953-7619-77-0

Hard cover, 172 pages

Publisher InTech

Published online 01, January, 2010

Published in print edition January, 2010

Robotic surgery is still in the early stages even though robotic assisted surgery is increasing continuously. Thus, exact and careful understanding of robotic surgery is necessary because chaos and confusion exist in the early phase of anything. Especially, the confusion may be increased because the robotic equipment, which is used in surgery, is different from the robotic equipment used in the automobile factory. The robots in the automobile factory just follow a program. However, the robot in surgery has to follow the surgeon's hand motions. I am convinced that this In-Tech Robotic Surgery book will play an essential role in giving some solutions to the chaos and confusion of robotic surgery. The In-Tech Surgery book contains 11 chapters and consists of two main sections. The first section explains general concepts and technological aspects of robotic surgery. The second section explains the details of surgery using a robot for each organ system. I hope that all surgeons who are interested in robotic surgery will find the proper knowledge in this book. Moreover, I hope the book will perform as a basic role to create future prospectives. Unfortunately, this book could not cover all areas of robotic assisted surgery such as robotic assisted gastrectomy and pancreaticoduodenectomy. I expect that future editions will cover many more areas of robotic assisted surgery and it can be facilitated by dedicated readers. Finally, I appreciate all authors who sacrificed their time and effort to write this book. I must thank my wife NaYoung for her support and also acknowledge MiSun Park's efforts in helping to complete the book.

How to reference

In order to correctly reference this scholarly work, feel free to copy and paste the following:

Steven S Tsoraidis, M.D., M.P.H., Franziska Huettner, M.D., P.h.D., Arthur L Rawlings M.D., M.Div. and David L Crawford, M.D. (2010). Robotic Surgery of the Colon: The Peoria Experience, Robot Surgery, Seung Hyuk Baik (Ed.), ISBN: 978-953-7619-77-0, InTech, Available from: <http://www.intechopen.com/books/robot-surgery/robotic-surgery-of-the-colon-the-peoria-experience>

INTECH
open science | open minds

InTech Europe

University Campus STeP Ri
Slavka Krautzeka 83/A
51000 Rijeka, Croatia
Phone: +385 (51) 770 447

InTech China

Unit 405, Office Block, Hotel Equatorial Shanghai
No.65, Yan An Road (West), Shanghai, 200040, China
中国上海市延安西路65号上海国际贵都大饭店办公楼405单元
Phone: +86-21-62489820

www.intechopen.com

Fax: +385 (51) 686 166
www.intechopen.com

Fax: +86-21-62489821

IntechOpen

IntechOpen

© 2010 The Author(s). Licensee IntechOpen. This chapter is distributed under the terms of the [Creative Commons Attribution-NonCommercial-ShareAlike-3.0 License](#), which permits use, distribution and reproduction for non-commercial purposes, provided the original is properly cited and derivative works building on this content are distributed under the same license.

IntechOpen

IntechOpen