

# We are IntechOpen, the world's leading publisher of Open Access books Built by scientists, for scientists

4,800

Open access books available

122,000

International authors and editors

135M

Downloads

Our authors are among the

154

Countries delivered to

TOP 1%

most cited scientists

12.2%

Contributors from top 500 universities



WEB OF SCIENCE™

Selection of our books indexed in the Book Citation Index  
in Web of Science™ Core Collection (BKCI)

Interested in publishing with us?  
Contact [book.department@intechopen.com](mailto:book.department@intechopen.com)

Numbers displayed above are based on latest data collected.

For more information visit [www.intechopen.com](http://www.intechopen.com)



# Robotic Assisted Colorectal Surgery

Seung Hyuk Baik, M.D.

*Department of Surgery, Yonsei University College of Medicine,  
Seoul, Korea*

## 1. Introduction

A robot is generally considered as a physical machine which can move around, operate a mechanical limb and exhibit intelligent and autonomous behavior in public. However, a surgical robot is not like the common robots which have the ability of autonomous action. A surgical robot is a collection of manipulators which just follow the surgeon's hand motions. The manipulators of a surgical robot receive a digitalized signal from the computer which interfaces the surgeon's hand motions with robotic manipulators. These are the important characteristics of a surgical robot, and we can consider it as a developed laparoscopic surgical instrument. Conversely, many patients think that a surgical robot as a robotic surgeon who can perform an operation with its own intelligence. The present surgical robot is just a servant. Thus, we have to understand the surgical robot from this concept. The whole robotic procedure is a robotic assisted procedure and the master surgeon decides the whole surgical procedure and performs the operation. The current surgical robot just helps the surgeon with its advanced technology during the surgical procedure.

The first surgical robot was the Automated Endoscopic System for Optimal Positioning (AESOP) (Computer Motion, Santa Barbara, CA, USA). In 1994, AESOP was approved for clinical use as a robotic camera holder by the Food and Drug Administration (FDA). After that, the Zeus surgical system was invented. However, the Zeus surgical system was approved by the FDA for use only as a surgical assistant. The da Vinci® robotic system (Intuitive Surgical Inc., Sunnyvale, CA, USA) is currently the most popular surgical robotic system. Thus, the manuscript is written based on the da Vinci® robotic system.

## 2. History of robotic assisted colorectal surgery and technical development

In 2002, Weber et al. used the robotic surgical system to perform a right colectomy and a sigmoid colectomy for benign diseases. Hashizume et al. (2002) reported three cases of robotic assisted colectomies. It is the first trial to apply the robotic assisted colectomy to malignant disease. In 2003, Vibert et al. reported three cases of robotic assisted colectomies and Delaney et al. reported the first comparative study between robotic assisted colectomy and conventional laparoscopic surgery. However, in this study, only six cases of robotic assisted colon surgery were compared. Giulianotti et al. (2003) reported on a series of 16 cases of robotic assisted colorectal surgery and six cases of anterior resection and two cases of abdominoperineal resection. A relatively large comparative study was conducted by D'Annibale et al. (2004). They compared 53 cases of robotic assisted colorectal surgery to 53 cases of conventional laparoscopic colorectal surgery. Twenty two malignant cases were

Source: Robot Surgery, Book edited by: Seung Hyuk Baik,  
ISBN 978-953-7619-77-0, pp. 172, January 2010, INTECH, Croatia, downloaded from SCIYO.COM

enrolled in the robotic group and forty two malignant cases enrolled in the laparoscopic group. It was the first comparative study with more than 50 cases. In 2005, Brauman et al. reported on robotic assisted cases of four sigmoid colectomies and one right hemicolectomy. Also, Ruurda et al. (2005) and Sebahang et al. (2005) reported twenty three and seven cases of robotic assisted colorectal surgery, respectively. In 2006, Pigazzi et al. compared six cases of robotic assisted low anterior resection to six cases of laparoscopic low anterior resection. They compared not only the short term outcomes but also the surgeon's fatigue level between both groups. They showed that robotic rectal surgery might cause less operator fatigue when compared with standard laparoscopic surgery. In the same year, De Noto et al. (2006) reported eleven cases of robotic assisted sigmoid colectomies. In 2007, Hellan et al. reported on a 39 case series and Rawlings et al. (2007) compared 30 cases of robotic assisted colectomy to laparoscopic colectomy. In 2008, Baik et al. described the robotic technique which used four robotic arms for mid or lower rectal cancer surgery and conducted the first randomized trial. In 2009, Ng et al. reported eight cases of robotic assisted low anterior resection for rectal cancer. A total robotic procedure for rectal cancer was shown by Park et al. (2009) and Hellan et al. (2009). Alberto et al. (2009) reported on laparoscopic and robot-assisted resection of colorectal cancer and of synchronous liver metastasis. Choi et al. (2009) showed the transanal or transvaginal retrieval of the resected specimen in robotic assisted colorectal cancer surgery. Baik et al. (2009) reported that the mesorectal grade in the robotic group was significantly better than the conventional laparoscopic group in the study which compared 56 cases of robotic assisted low anterior resection to 57 cases of laparoscopic low anterior resection.

### **3. Core technology related to colorectal surgery**

#### **3.1 Vision**

The robotic surgical system has three components. These components are the surgeon console, the robotic cart (patient-side cart) and the vision system (Fig. 1). The surgeon console is the place where the surgeon can perform the operation. This instrument provides an ergonomic position and three dimensional images. Three dimensional images help the surgeon to overcome visual limitation during the operation and also provide a similar vision like open surgery. The conventional laparoscopic surgery system only provides two dimensional visions. The most recent robotic surgical system is equipped with HD technology also with three dimensional images. Three dimensional HD images are the most optimal imaging technology in laparoscopic surgery and provide a direct hand-eye instrument alignment and a natural depth perception for precise operation near dangerous anatomical structures. In robotic assisted rectal cancer surgery, the surgeon can effectively recognize the hypogastric nerve plexus during dissection around an inferior mesenteric artery. Moreover, the inferior hypogastric nerve can be easily recognized during the pelvic dissection. These nerves are very important in the post operative quality of life. Nerve preservation surgery is essential because it is not necessary to sacrifice the nerve if the tumor did not directly invade the nerve. During laparoscopic surgery, major vessel damage is the common cause of open conversion. Thus, precise dissection is necessary around the major vessels. The three dimensional HD image may help with precise dissection.

Total mesorectal excision (TME) has been the golden standard of rectal cancer surgery (Heald et al., (1982), Enker et al., (1995), Havenga et al., (1996)). The exact recognition of the fascia structure around the rectum is mandatory to perform successful TME. Denonvillier's fascia separates the extraperitoneal rectum anteriorly from the prostate, the seminal

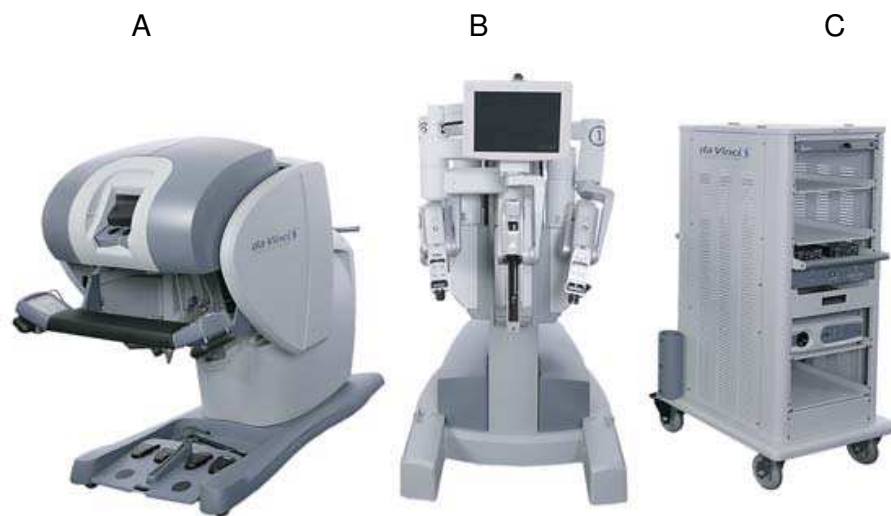


Fig. 1. The robotic surgical system: A) the surgeon console; B) the robotic cart (patient-side cart); C) the vision system

vesicles, or the vagina. A sharp dissection of Denonvillier's fascia is needed for TME. Excision of Denonvillier's fascia means exposure of the prostate and the seminal vesicle, and parasympathetic and sympathetic nerves related to voiding and sexual function are located near the prostate and the seminal vesicle. Thus, improper resection of Denonvillier's fascia is associated with postoperative sexual and voiding dysfunctions. The TME plane of the posterior and lateral side of the rectum is the natural space between the fascia propria of the rectum and the presacral fascia. If the surgeon cannot find the TME plane, the mesorectum or presacral structure may be injured. Mesorectal injury is associated with oncologic outcomes in rectal cancer surgery (Nagtegaal et al., 2002). The presacral fascia encloses the anterior side of the sacrum, the coccyx, the nerves, the middle sacral artery, and the presacral vein. During the dissection of the posterior side of the TME plane, presacral hemorrhage can occur. The reported incidence rate of presacral hemorrhage is from 4.6% to 7.0% during rectal dissection. The presacral vein is drained into the sacral foramen and has a high blood pressure which can reach hydrostatic pressures of 17-23 cm H<sub>2</sub>O, two to three times the normal pressure of the inferior vena cava (Bruce et al., 2007). Thus, presacral hemorrhage during rectal dissection is a troublesome and life threatening hemorrhage despite venous bleeding. The three dimensional HD image in the robotic system can be beneficial to prevent these critical complications related to the characteristic of the anatomical structure around the rectum.

The robotic surgical system is equipped with four arms. One arm is used for the endoscope holder and the other three arms are used for surgical arms which perform the operation. The robotic arm, which holds the endoscope provide a stable vision without unnecessary movement. If the endoscope is moving unnecessarily, it is like doing an operation in a

moving car or train. In conventional laparoscopic surgery, the assistant surgeon holds the endoscope and the vision provided by the assistant surgeon cannot be as stable as like the vision provided by the robotic arm. In the robotic assisted procedure, the master surgeon can move the vision according to their needs. This feature can make the operation run smoothly and the operation time shorter than conventional laparoscopic surgery.

Three dimensional images are created by two lenses (Fig. 2) in one endoscope. A discrepancy of lens focus between the two endoscope lenses can make a visual disturbance and can occur because the three dimensional visual system is so fine and it is a complex instrument. Moreover, the human eye can feel tiny discrepancies and it is uncomfortable to stare into the complex surgical field. This is a disadvantage and malfunction of the robotic surgical system which is equipped with a three dimensional visual system. However, there is no objective data related to the discrepancy of the lens because it is usually detected only by a master surgeon who remembers the most optimal three dimensional views in the complex surgical field. Other assistant staff and engineer may not recognize the tiny discrepancy of the lens focus between the two endoscope lenses.



Fig. 2. Endoscope which has two lenses

The robotic surgical system is not equipped with a fumes ventilator. Fumes occur after electric cauterization. Another port site is necessary to vent the fumes effectively. It is a considerable issue in rectal resection because the surgical space of rectal dissection is surrounded by a narrow and deep pelvic cavity. If the surgeon would not like another port for ventilation of the fumes, the valve in the endoscope port or the assistant port can be used to ventilate the fumes. However, this method needs a little time. Conventional laparoscopic instruments have an electric cautery which can perform dissection and ventilation simultaneously. The absence of a ventilation system in the robotic instrument is a drawback compared to the conventional laparoscopic instrument.

Acute and major bleeding can occur during colorectal surgery even though the surgeon performed careful dissection. The arterial bleeding from a major vessel can directly contaminate the endoscope lens. If this situation occurs, the whole surgical field is changed into a red world. This situation is so troublesome and stressful to the surgeon. Rapid separation of the endoscope from the robotic system should be performed and reinserted to

control the bleeding after cleaning both lenses. This procedure should be performed as soon as possible. If this procedure is delayed just a few seconds, bleeding control may be impossible due to profound bleeding in the surgical field and then open conversion must be followed as soon as possible. In this situation, the weight of the endoscope can delay the procedure of lens cleaning. Robotic surgery is a highly advanced technological procedure, whereas the cleaning of the lens is performed using water and a towel, and it is not a technological method. It is just time consuming. Thus, a more secure dissection is needed in robotic surgery because more time is needed to control acute bleeding or to convert it into an open procedure.

### 3.2 Function of articulation of the instrument tips

In the robotic surgical system, the tips of the instruments are designed to mimic the dexterity of the human hand and wrist. It allows seven degrees of freedom and 90 degrees of articulation even though it cannot be exactly similar with the dexterity of the human hand (Fig. 3). This is a very different technology compared with conventional laparoscopic instruments which have five degrees of freedom and is called an endowrist function. The endowrist function allows the surgeon to perform intracorporeal anastomosis such as an ileo-transverse anastomosis after a right hemicolectomy (Rawlings et al. 2006). However, intracorporeal anastomosis is not the commonly used method in colon surgery.

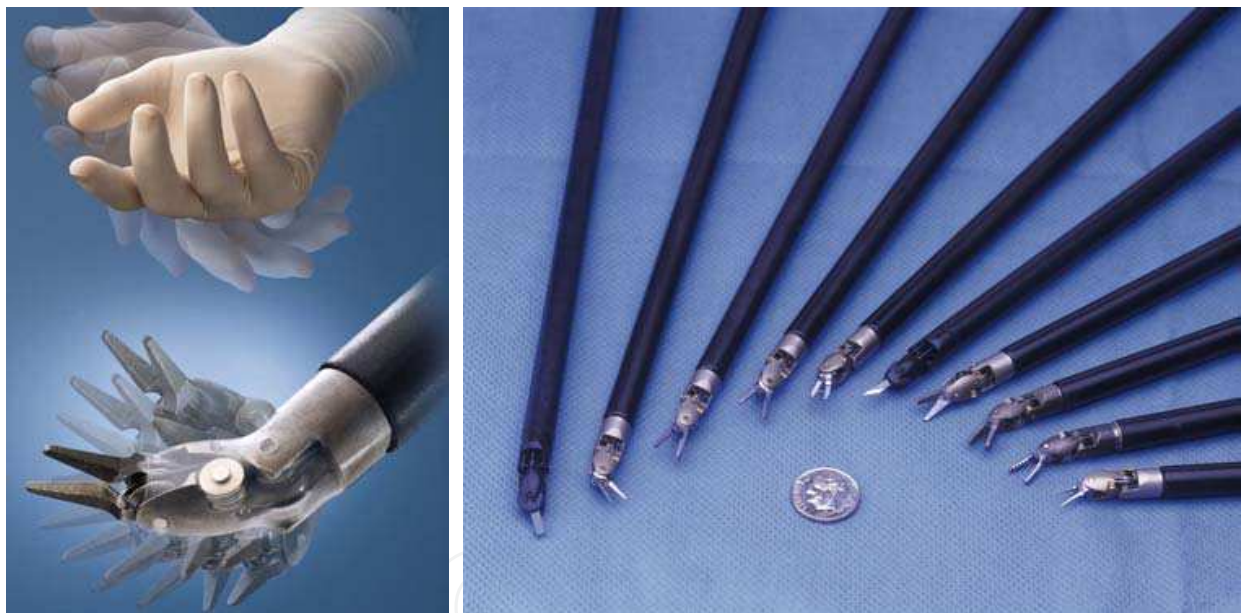

Fig. 3. The tip of the robotic instrument and the surgeon's hand

Extracorporeal anastomosis is commonly used in laparoscopic colon surgery because anastomosis can be easily performed using the specimen extraction site. In laparoscopic rectal surgery, an EEA stapler is used for colorectal anastomosis. Thus, the endowrist function may not often be used for anastomosis in colorectal surgery. However, the endowrist function is useful for posterior dissection of a vessel. The straight instruments of laparoscopic surgery cannot easily reach the posterior side of the vessel, such as the inferior mesenteric artery. The root of the inferior mesenteric artery is fixed on the abdominal aorta. Because of that, it cannot be moved by traction and its posterior side is blocked by itself. Thus, straight conventional instruments of laparoscopic surgery are not appropriate for dissection of the posterior side of the inferior mesenteric artery, whereas angulated tips of

the robotic instrument can reach the posterior side of the vessel of the inferior mesenteric artery. Thus, the dissection of this area can be performed easily and effectively.

Mesorectal transection is the procedure which is performed in upper rectal cancer surgery. It is a very difficult procedure because the surgical field is usually in the narrow pelvic cavity even though it is performed by the open method. In laparoscopic surgery, the axis of the rectum and the axis of the instrument tip make an acute angle. The instrument tip of conventional laparoscopic surgery can only reach the mesorectum obliquely. Precise dissection of the mesorectum at 4 cm below the tumor is absolutely necessary. However, the oblique approach of the laparoscopic instrument into the mesorectum is a technical demanding procedure to transect the mesorectum precisely. The surgery can be performed easily when the target organ and the instrument make a right angle. The angulated instrument of the robotic surgical system can make a right angle approach possible during the transection of the mesorectum. The angulated instrument of the robotic surgical system can also be the L-shape retractor. It can elevate the rectum upward effectively and can move the rectum laterally enclosing the rectum softly. These soft and effective tractions can make a proper surgical space between the fascia propria of the rectum and the presacral fascia. Upward traction of the prostate gland using the straight laparoscopic instrument usually doesn't frequently make a proper surgical space because the instrument can disturb the operation and block the surgical view. Meanwhile, the angulated instrument of the robotic system can make a little larger space, which is the triangle shaped space. The triangle shaped space is helpful to easily dissect in the narrow pelvic space (Fig. 4).

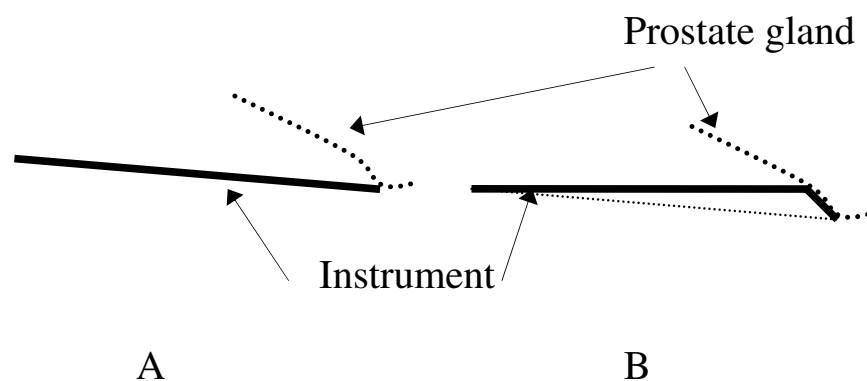


Fig. 4. A. Traction of the prostate using conventional laparoscopic surgery  
B. Traction using the robotic surgical system. The angular instrument tip makes a triangular space.

Ultrasonic devices can be used in the robotic surgical system. The major advantage of the ultrasonic devices is the hemostatic effect of a major vessel, and it can be used in a mesorectal transection. However, it cannot be angulated even though it is equipped in the robotic surgical system. If surgeons choose the ultrasonic device, they may sacrifice the advanced technology of the robotic surgical system because the movements of the ultrasonic device are not different between the robotic surgical system and conventional laparoscopic surgery.

### 3.3 Motion scaling and tremor elimination

Motion scaling is a characteristic of the robotic surgical system. The computer in the robotic surgical system can scale down a surgeon's hand movements into micromotions. Thus,

detailed surgery can be easily performed using the robotic surgical system. However, motion scaling is generally not proper for colorectal surgery because the surgical field and target organs are too large to scale down. But tremor reduction is one of the advanced technologies of the robotic surgical system. It may be helpful for the surgeon who has a hand tremor.

### 3.4 Ergonomic position

The surgeon performs the operation in an ergonomic position in the robotic surgical system. The most important ergonomic posture is the sitting position. The surgeon sits in the chair and grasps the master controls with the hands and wrists naturally positioned during the robotic assisted procedure. Pigazzi et al. (2006) reported that robotic rectal surgery might cause less operator fatigue when compared with conventional laparoscopic surgery and explained that the ergonomic position for the surgeon sitting at the console might be the important reason.

## 4. Surgical technique

### 4.1 General considerations

Robotic assisted surgery is the operation method of which the essential step is performed using the robotic surgical system. The following concepts are the general considerable issues related to robotic assisted surgery. A successful robotic assisted surgery is determined by the harmonious application of the specific standard procedures for each disease and the following considerations.

1. The robotic cart is located at the same side of the target organ.
2. The surgeon's right hand is the left arm of the robotic system. The signals of the surgeon's hand are conversely interfaced to the robotic arms.
3. The robotic endoscope arm should be aligned with the robotic cart and the endoscope port in a straight line (Fig. 5).

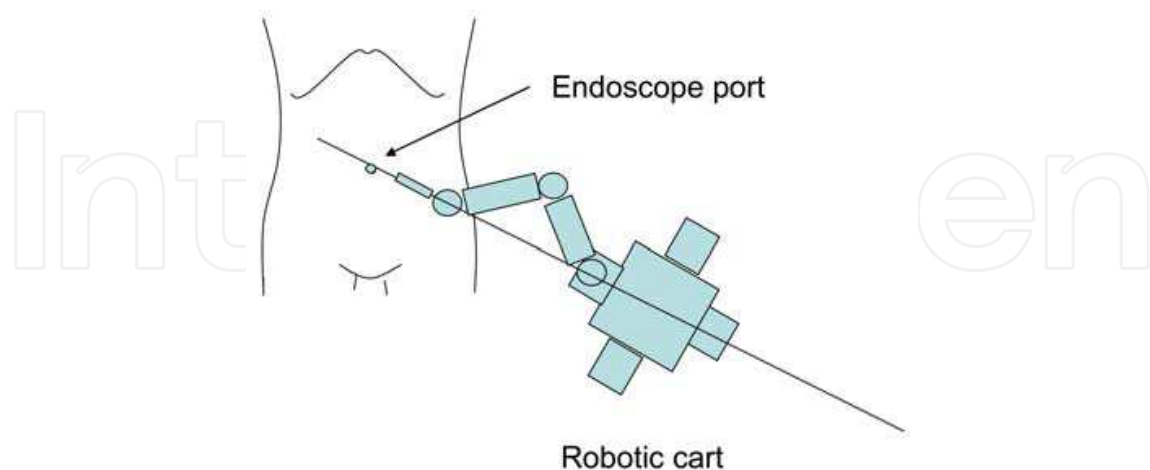


Fig. 5. Alignment between the patient's cart and the endoscope port

4. The distance between the ports should be larger than 7 cm.
5. All ports should be located as close as possible on the concentric circle which has an axis on the robotic cart.



6. The angle between the robotic arms should be as wide as possible. If the angle between the robotic arms become narrower, the chance of extracorporeal collision between the robotic arms are increased (Fig. 6).

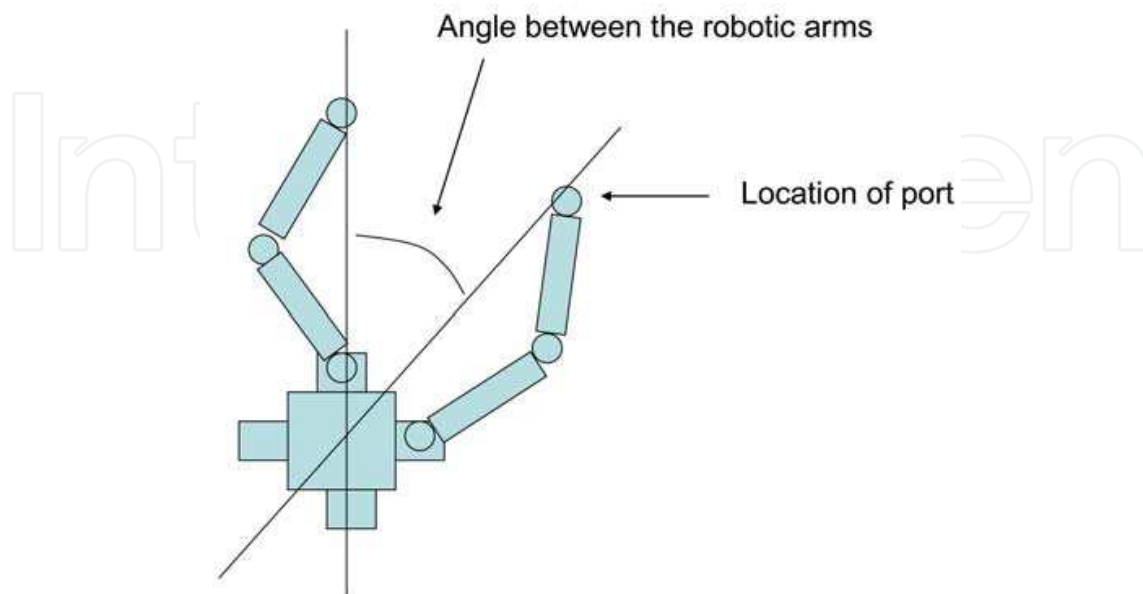


Fig. 6. Angle between the robotic arms

7. The robotic arms cannot cross each other.
8. The position of the patient cannot be changed after docking of the robotic cart.
9. The procedure is easy when the target organ is on a straight line from the robotic cart to the endoscope port.
10. If the target site of the operation becomes further from the straight line from the robotic cart to the endoscope port into both lateral sides, the chance of extracorporeal collision is increased.
11. The robotic arms don't interface the tactile sense and the tensile strength from the patient to the surgeon's hand. The surgeon has to recognize the tactile sense and the tensile strength by visual cue.
12. No. 1 arm is the right first arm which receives a signal from the surgeon's right hand. No. 2 arm is the left second arm which receives a signal from the surgeon's left hand. No. 3 arm is the left or right arm which can be switched with No. 1 or No. 2 arm (Fig. 7).
13. The procedures of robotic assisted colorectal surgery basically follow the procedures of standard laparoscopic colorectal surgery.

Until now, all published robotic assisted colorectal procedures needed an assistant surgeon. Hellan et al. (2009) insisted that the assistant surgeon plays an important role in providing additional countertraction and stapling of the inferior mesenteric vein and artery. It is difficult to understand because people expect the robotic surgical system to operate by itself without human assistance. Hellan et al.'s opinion (2009) implies that robotic assisted surgery of the present generation needs more technological developments.

The most important step in robotic assisted colorectal surgery is the design of the trocar position. Dislocation of the trocar is the main reason of extracorporeal collision between the robotic arms and if a collision occurs, further operation is not possible. In this situation, open or laparoscopic conversion is needed.

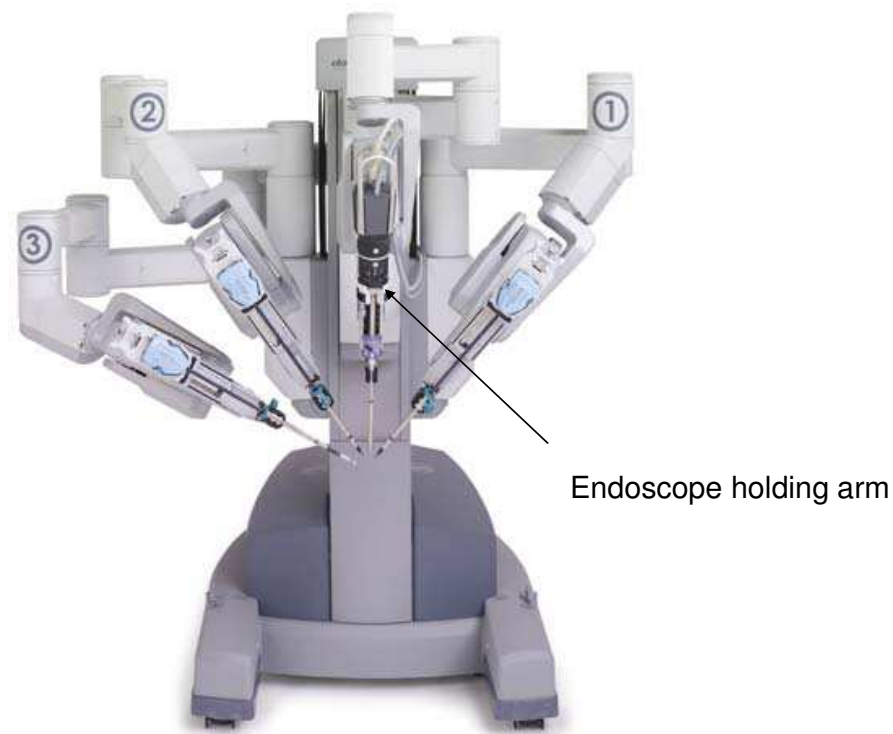

Fig. 7. Robotic cart has one endoscope holding arm and three surgical arms.

There are several trocar positions according to the surgeon's preference and another new design of the trocar position will be developed due to an increase of robotic assisted colorectal surgery. Thus, this description will provide a general technical method with several examples.

The endoscope trocar and the trocar for the endovascular stapler or endo-GIA are 12 mm in size. The robotic arm trocar is 8 mm or 5 mm. The assistant trocar is usually 5 mm. If the assistant trocar is used for endoclippping, a 10 mm size trocar should be used and for an endo-GIA, a 12 mm size trocar should be used.

#### 4.2 Right colectomy

The patient is placed supine on the surgical table. Both of the patient's arms are secured at the sides of the patient's trunk. Pneumoperitoneum was established using a Veress needle through the umbilicus. The endoscope trocar is inserted at the periumbilical area. Other robotic arms and assistant trocars are placed properly according to the general considerations. In the procedure which was reported by Rawlings et al. (2006), the robotic cart is located at the upper right side of the patient. The endoscope port is placed in the periumbilical area. The lower right and upper left quadrant ports are placed. These three trocars are occupied by the robotic arms. Additional upper left and lower left trocars are placed (Fig. 8A).

The author prefers that the robotic cart is located at the right side of the patient, which is the same level as the location of the endoscope port. The endoscope port is located at the supraumbilical area and the robotic cart. The upper left, lower left and suprapubic ports are used for the robotic arms. The left lateral port is used for the assistant surgeon (Fig. 8B).

After the placement of the trocars, the surgical table is tilted to the left to allow the small intestine to fall off from the surgical field. Then, the robotic cart is docked.

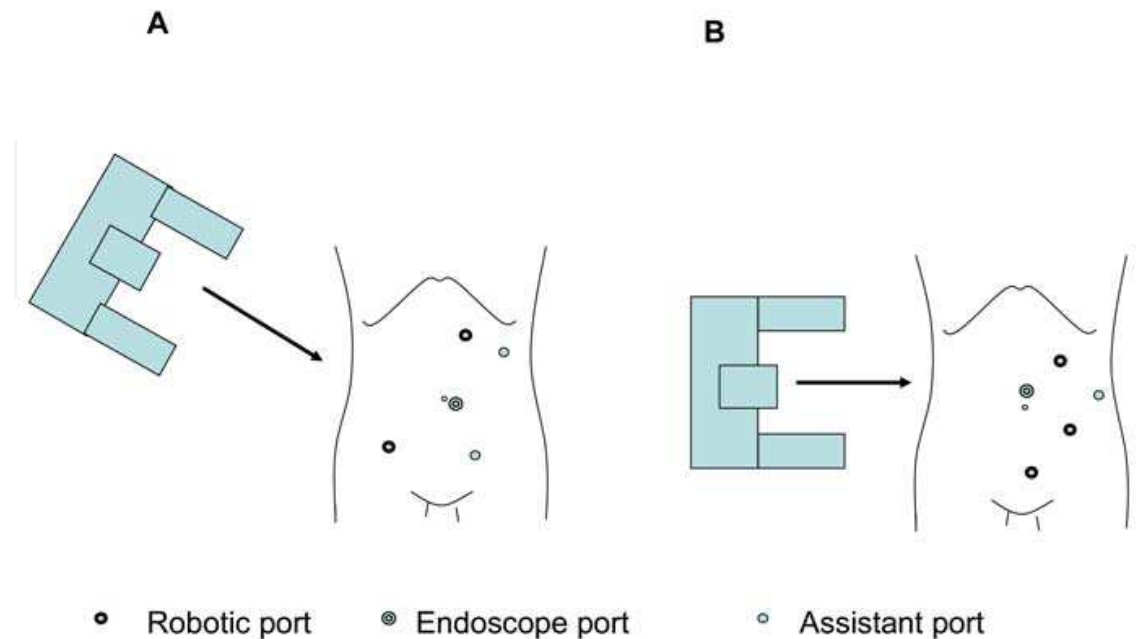


Fig. 8. The location of the ports and robotic cart for robotic assisted right colectomy: A) The right upper oblique location of the robotic cart; B) The right vertical location of the robotic cart

Careful examination of the abdomen and pelvic contents is performed. This examination can be performed before docking by manual manipulation of the robotic endoscope. The first right robotic arm uses the instrument which will dissect. The electric cautery, hook, scissors and ultrasonic device can be used at this step. The second left robotic arm uses the grasper. The bipolar grasper can also be used. The usual manner is the medial to lateral approach. The ileocolic vasculatures are dissected at the root level and ligated by an endoclip or a vascular stapler. This allows identification of the right colic artery and the dissection plane between the right colon mesentery and Gerota's fascia. The right colic artery and vein and the hepatic branch of the middle colic artery and vein are ligated.

The ileal mesentery is divided with an ultrasonic device or a vascular stapler. The hepatic flexure suspensory ligaments and the transverse mesocolon are divided with the same instruments. Then, the attached paracolic gutter is divided. Both intracorporeal and extracorporeal can be performed on the specimen resection. Intracorporeal resection and anastomosis can be performed using the robotic system. However, the author prefers extracorporeal resection of the specimen and anastomosis because it can shorten the total operation time and needs no additional wound extension compared to the method of intracorporeal anastomosis using the robotic system. In colon cancer surgery, oncologic principles should be followed.

#### 4.3 Sigmoid colectomy

The patient is placed supine in a modified lithotomy position with legs in adjustable stirrups. Both shoulder supporters are applied to prevent accidental movement of the patient on the surgical table. Both of the patient's arms are attached to both sides of the

trunk. The pneumoperitoneum is established using the Veress needle. The endoscope port is located at the periumbilical area. The first right robotic arm trocar is inserted at the lower right abdominal area and the second left robotic arm trocar is inserted at the upper right abdominal area. The third robotic arm trocar is inserted at upper left area and the assistant trocar is inserted at the right lateral area at the level of the umbilicus. A careful examination of the abdomen and pelvic contents is performed. The patient is tilted to the right in a Trendelenburg position. Then, the robotic cart is docked (Fig. 9B). The sigmoid mesocolon is divided from the right iliac crest area. The prominence of the right iliac artery is a good landmark to dissect. The inferior mesenteric artery (IMA) is carefully skeletonized at the origin without injuring the hypogastric nerve flexus by electric cautery or hook. Then, IMA is ligated by an endoclip or a vascular stapler. Medial to lateral dissection is performed in the left gutter. The remaining attachment between the left gutter and colon are divided by an electric cautery or hook. The splenic flexure is completely mobilized. Then, the upper rectal area is dissected in the same manner. The upper mesorectum is divided by the ultrasonic device or the electric cautery using an endoclip. The robot is disengaged, and the upper rectum is divided using an endo-GIA. Then, the specimen is externalized through the vertically extended endoscope port, which is protected with a polyurethane retrieval bag. The specimen is resected at the proximal part, and the EEA stapler anvil is introduced.

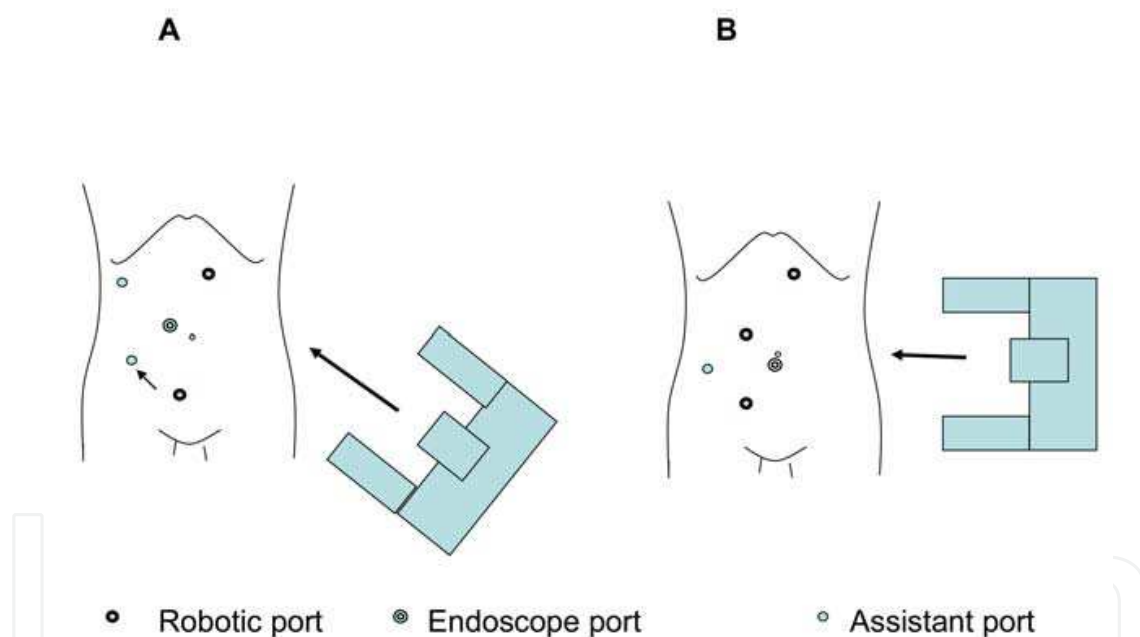


Fig. 9. The location of the ports and robotic cart for the robotic assisted sigmoid colectomy: A) The lower left oblique location of the robotic cart; B) The left vertical location of the robotic cart.

Then, the proximal colon is dropped back in the abdomen. The specimen extracted site is closed and the pneumoperitoneum is established again. The endoscope is introduced through the previous assistant trocar and a standard end to end anastomosis is performed using the EEA stapler.

In the robotic assisted sigmoid colectomy, the robotic cart can be brought from the lower left area (Fig. 9A). The procedure can be divided into two steps (Rawlings et al., 2006). At the first step, the endoscope port is located at the periumbilical area and the right robotic port and left robotic port are located at the suprapubic area and the upper left abdominal area.

The patient is tilted to the right and the reverse Trendelenburg position is added. It is better to perform the splenic flexure and upper left colon mobilization with a right tilt and the reverse Trendelenburg position. In this step, the splenic flexure is fully mobilized. Then, all the robotic arms are disengaged. The position of the patient is changed to the right tilt and the Trendelenburg position. Then, the robotic cart is docked again. However, the suprapubic robotic arm moves to the lower right abdominal trocar to prepare for an effective operation of the IMA area and the upper part of the rectum. A change in the robotic cart position is not needed in this situation. Only three robotic arms are adjusted as the patient is placed in a Trendelenburg position.

#### **4.4 Low anterior resection**

The low anterior resection is a technically demanding procedure in robotic assisted colorectal surgery because it needs not only the upper left quadrant approach for splenic flexure mobilization but also the lower left quadrant approach for total mesorectal excision in rectal cancer patients. However, the robotic surgical system is not appropriate for the multi quadrant approach because of its technological limitation. Thus, the robotic cart should be placed at the upper left side of the patient for splenic flexure mobilization, and it should be placed in front of the perineum between both legs for rectal dissection. However, the movement of the robotic cart is so complicated because of its large size and heavy weight. Moreover, more robotic arm ports are needed for two step robotic operations. Because of this reason, the hybrid method was developed. Left colon mobilization, splenic flexure mobilization and IMA ligation are performed using conventional laparoscopic instruments, and rectal dissection is performed using the robotic surgical system in the hybrid method. In the hybrid method, the technological advantage can concentrate on the total mesorectal excision, which is the golden standard procedure in rectal cancer surgery. In fact, splenic flexure mobilization and left colon mobilization is the procedure for reconstruction. Proper mobilization is necessary for tension free colorectal anastomosis. In rectal cancer surgery, the most important issue is how we can obtain a complete TME specimen. A complete TME specimen can be obtained from a secure dissection without any injury to the fascia propria of the rectum. Thus, the hybrid method, which mostly uses a robotic system for TME is reasonable. However, according to the development of the robotic surgical system, the range of the robotic arm motion is increasing and the instruments become longer. Also, the robotic arms are smaller. Thus, several authors reported on the full robotic procedure for rectal cancer surgery (Park et al., 2009, Luca et al., 2009, Hellan et al., 2009). In this chapter, both methods will be described.

##### **4.4.1 Hybrid method**

The patient is placed supine in a modified lithotomy position with legs in adjustable stirrups. Shoulder supporters are applied to both sides to prevent accidental movement of the patient on the surgical table. Both of the patient's arms are attached to both sides of the trunk. The pneumoperitoneum is established using the Veress needle. The endoscope port is located at the supraumbilical area. The first right robotic arm trocar is inserted at the lower right abdominal area which is at the midpoint on the line between the supraumbilical trocar and the right anterior superior iliac spine. The second and third robotic arm trocars are inserted in the one-third and two-thirds points on the line between the supraumbilical trocar and the left anterior iliac spine. The assistant trocar is inserted in the upper right abdominal

area on the midaxillary line to allow the surgeon access for mobilization of the left colon and the splenic flexure (Fig. 10A). A careful examination of the abdomen and pelvic contents are performed using an endoscope. Then, the patient is tilted to the right in a Trendelenburg position. The sigmoid mesocolon is divided from the right ileac crest area using conventional laparoscopic instruments. The surgeon stands on the right side of the patient. The main trocars in which the surgeon uses are the lower right and upper right trocars. IMA ligation, left colon mobilization and splenic flexure mobilization are performed in the same manner as the sigmoid colectomy using conventional laparoscopic instruments. Left colon mobilization is performed until the rectosigmoid junction. Then the robotic cart is brought from below. The robotic cart is placed in front of the perineal area between both legs. The first right robotic arm is inserted into the right robotic trocar. The second left robotic arm is inserted into the left robotic trocar near the endoscope trocar and the third robotic arm is inserted into the left lateral robotic trocar near the left anterior superior iliac spine. Rectal dissection is performed by the TME principle. If the mesorectum needs to be transected, it is performed using a bipolar grasper and an electric cautery. An ultrasonic device can be used at this step. However, the author does not prefer the ultrasonic device because it doesn't have an articulation function which is the core technology of the robotic surgical system. After full dissection of the rectum, the robotic cart is disengaged. Then, the lower right robotic trocar is changed to a 12 mm trocar to introduce the endo-GIA. The rectum is transected using an endo-GIA. Then, the left lateral robotic trocar extended 4 cm into the direction of the suprapubic area. This location of the wound is located below the patient's underpants. The following methods are the same with a sigmoid colectomy. According to the tumor location, coloanal anastomosis and abdominoperineal resection can be applied.

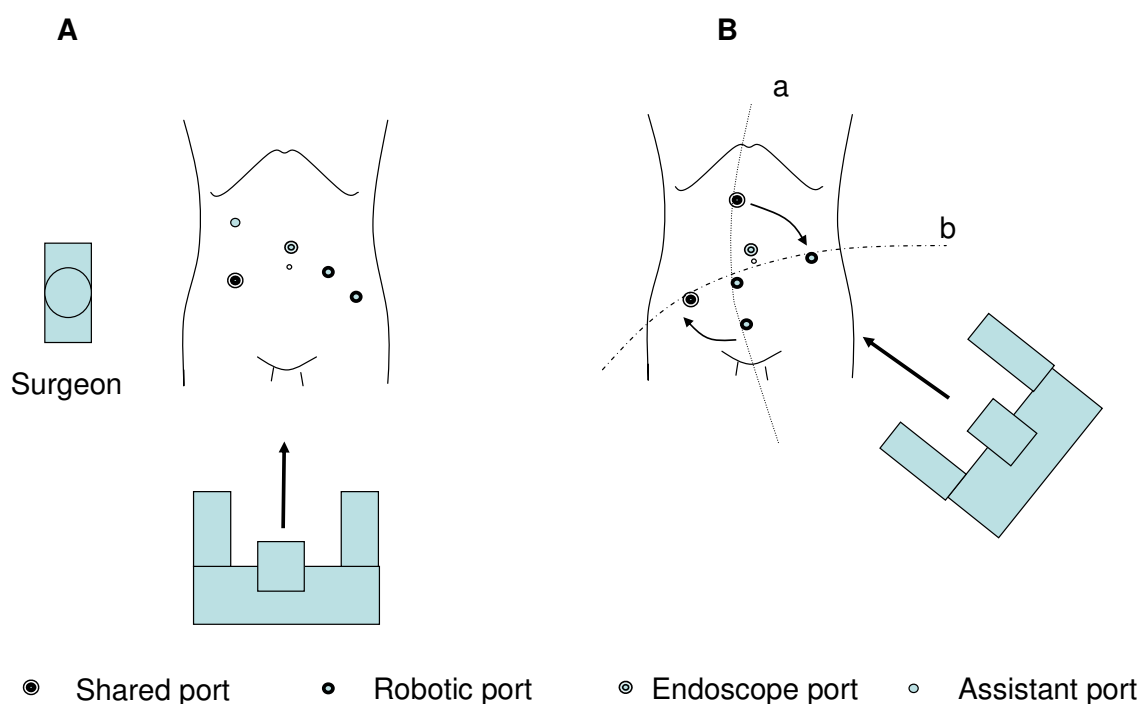


Fig. 10. The set up of the robotic cart and the location of the ports for low anterior resection: A) Hybrid method; B) Full robotic method.

#### 4.4.2 Full robotic method

The full robotic method of low anterior resection for rectal cancer surgery is composed of two steps. The first step is for IMA and IMV ligation, left and sigmoid colon mobilization and splenic flexure mobilization. The second step is for rectal dissection. In the first step, the whole robotic ports are in line a. The endoscope port is located at the supraumbilical area. The right first robotic arm is placed 7-8 cm apart between the endoscope port on the imaginary line between the endoscope port and the anterior superior iliac spine. The second robotic left arm is placed at the upper abdomen which is 1cm right lateral from the midline. The third robotic arm is at the right supra pubic area. These four robotic ports are used for the first step. In this step, the assistant port is placed at the lower right area on line b, and it is used for the third right robotic port in the second step. After the first step, the second left robotic arm is disengaged and moves to the left robotic port on line b. The third right robotic arm moves to the lower right robotic port on line b, which is used for the assistant port in the first step (Fig. 10B). Then, the specimen is externalized through the horizontally extended suprapubic port, which is protected with a polyurethane retrieval bag. The following procedure is similar with the hybrid method.

### 5. Outcomes of robotic assisted colorectal surgery

Laparoscopic colorectal surgery is increased due to several benefits such as reduced post operative pain, shorter hospital stay and better cosmetics compared to open surgery. A lot of single center studies (Hoffman et al., 1994, Liang et al., 2007) support these results and the COST trial (Nelson et al., 2004) confirmed not only the benefits of the short term outcomes but also the long term outcomes in laparoscopic colon surgery. However, laparoscopic rectal surgery has been apprehended in that inadequate laparoscopic resection of the rectum may influence poor oncologic outcomes. The CLASICC trial (Guillou et al., 2005) and several single center studies (Felicetti et al., 2003, Morino et al., 2003) reported the safety and the feasibility of laparoscopic rectal surgery.

However, the CLASICC trial (Guillou et al., 2005) insisted that the laparoscopic approach should be set against the slightly raised risk of a positive circumferential resection margin (CRM). This is a really important issue in rectal cancer surgery even though the CLASICC trial (Jayne et al., 2007) reported a higher positivity of CRM seen after laparoscopic anterior resection had not resulted in an increased incidence of local recurrence.

Most surgeons agree that there is a risk of an increasing rate of CRM involvement rate in laparoscopic surgery because rectal dissection is a technically demanding procedure and the laparoscopic procedure is a minimal invasive surgery which means that there are several technical limitations to perform the surgery compared to open surgery. Thus, until now there is no definite evidence of oncologic safety, which is confirmed by large scale prospective randomized multicenter trials, in laparoscopic dissection for rectal cancer patients.

Robotic assisted colorectal surgery can be considered as laparoscopic surgery. Their clinical application can be justified by the evidence of conventional laparoscopic colorectal surgery. Robotic assisted colorectal surgery has been performed continuously since Weber et al. (2002) performed the first two cases of robotic assisted colectomies. However, the majority of published papers are technical notes and comparative studies with a small number of patients. Systemic analysis is limited.

### 5.1 Operation time

Robotic assisted colorectal surgery needs a set up time for the robotic system. The time was reported from 15 min to 50 min (Rawlings et al., 2006, D'Annibale et al., 2004). It makes the total operation time longer than the conventional laparoscopic operation. The robotic system set up time is especially longer in the first few cases in the learning period and decreases according to accumulation of operating experiences. It also can be decreased by a developed robotic system model. The operation time of the robotic system is the summation of the set up time, robotic time and non robotic time.

Authors	No. of patients	Procedures (No.)	Mean Op time (min)	Malignancy (No.)
Giulianotti et al., (2003)	16	RHC(5) / ICR(2) / SC(1) / LAR(6) / APR(2)	172 / 150 / 240 / 270 / 180	14
Ruurda et al., (2005)	23	RP(16) / ICR(5) / SCS(2)	150 / 95 / 75	-
DeNoto et al., (2006)	11	SC (11)	196.7	-
Hellan et al., (2007)	39	LAR(33) / APR (6)	285	39
Park et al., (2009)	45	LAR(42) / APR (3)	293.8	45
Luca et al., (2009)	55	LAR(21) / APR (7) / LHC(27)	290	55
Choi et al., (2009)	13	LAR(11) / SC(2)	260.8	13

RHC; Right hemicolectomy, ICR; Ileocecal resection, LHC; Left hemicolectomy, LAR; Low anterior resection, APR; Abdominoperineal resection. RP; Rectopexy, SCS; Sigmoid colectomy, SC; Sigmoid colectomy

Table 1. Case series of robotic assisted colorectal surgery with at least 10 patients.

Rawlings et al. (2006) reported that total operation time of a robotic assisted right hemicolectomy was  $218.9 \pm 44.6$  min (range, 167 - 340 min). The total operation time of a robotic assisted sigmoid colectomy was  $225.2 \pm 37.1$  min (range, 147 - 283 min).

D'Annibale et al. (2004) did not differentiate the operation time according to the type of operation. Then the overall robotic assisted colorectal operation time was  $222 \pm 77$  min. Park et al. (2009) reported the operation time of the total robotic assisted low anterior resection for rectal cancer as  $293.8 \pm 79.7$  min. Luca et al.(2009) reported the operation of the total robotic assisted colorectal resection as  $290 \pm 69$  min (range 164 - 487 min). In this study, the operation time was the mean of the operation time of robotic assisted abdominoperineal resection, anterior resection of the rectum and left hemicolectomy. Hellan et al. (2007) reported that the operation time of a robotic assisted low anterior resection was 285 min (range 180 - 540 min) in a 39 case series.

In comparative studies, the robotic assisted operation time was longer than conventional laparoscopic surgery. Spinoglio et al. (2008) reported that the operation time was 383.8 min in robotic assisted colorectal resections (n=50) and 266.3 min in conventional laparoscopic colorectal resections (n=161). The operation time in the robotic group was significantly longer than the conventional laparoscopic group ( $P < 0.001$ ). Rawlings et al. (2007) also reported the operation time of a robotic assisted right hemicolectomy was significantly



longer than a conventional laparoscopic right hemicolectomy. The operation time of the robotic group was  $218.9 \pm 44.6$  min and the operation time of the laparoscopic group was  $169.2 \pm 37.5$  min ( $P=0.002$ ). In the same study, the operation time of a robotic assisted sigmoid colectomy was  $225.2 \pm 37.1$  min and it was also longer than the operation time of a laparoscopic sigmoid colectomy ( $199.4 \pm 44.5$  min) even though it did not reach a significant difference ( $P=0.128$ ). Woeste et al. (2005) compared 4 cases of the robotic assisted sigmoid colectomy to 23 cases of the conventional laparoscopic colectomy for diverticulitis. The operation time was  $236.7 \pm 5.8$  min and  $172.4 \pm 38$  min, respectively. The operation time of the robotic group was significantly longer than the laparoscopic group ( $P=0.05$ ). However, Baik et al. (2009) reported a similar operation time in the study which compared the robotic assisted low anterior resection to the conventional laparoscopic low anterior resection for rectal cancer patients. The operation time was  $190 \pm 45$  min (range 120 min – 315 min) in the robotic group and  $191.1 \pm 65.3$  min (range 100 min – 360 min) in the laparoscopic group and there was no statistical difference between the groups ( $P=0.924$ ).

Rawlings et al. (2007) commented on the etiology of the longer operation time of robotic assisted right hemicolectomy was due to intracorporeal anastomosis instead of extracorporeal anastomosis. However, they did not show the exact robotic intracorporeal anastomosis time. The reason of the longer operation time of robotic assisted colorectal surgery has not been defined until now. The absence of tactile sense may be a reason. The surgeon can feel the tactile sense from the instrument tips during laparoscopic surgery even though it was remarkably decreased than open surgery. The tactile sense allows little movement of the instrument tips outside of the laparoscopic view area because the surgeon can immediately stop when resistance is felt from something outside of the laparoscopic view. However, the surgeon cannot absolutely feel tactile sense in robotic assisted surgery. Thus, the instrument cannot be manipulated outside the laparoscopic view. The endoscope must always be moved appropriately to see the instrument. Then the instrument can be manipulated. These consecutive movements are a time consuming procedure. Also, the robotic arm movements cannot follow the speed of experienced surgeon's hands in the abdominal operative field until now.

However, in Baik et al.'s (2009) study, there was no difference in the operation time between the robotic and conventional laparoscopic surgeries. The operation method in the robotic group was the hybrid method. Left colon mobilization and ligation of the inferior mesenteric artery and vein were performed using conventional laparoscopic instruments. The rectal dissection procedures were performed by the robotic surgical system. During pelvic dissection, the necessity of the movement of the endoscope is needed less than colon surgery because the surgical space is confined by the narrow pelvic cavity. The advanced technology in the robotic surgical system may shorten the time of rectal dissection. Also, the surgeon's experience may influence and shorten the operation time because the present generation robotic surgical system just follows the surgeon's hand motions and decisions. The robotic surgical system is upgrading rapidly and continuously. Thus, it cannot be declared that the operation time of robotic colorectal surgery is longer than the operation time of conventional laparoscopic procedure.

## 5.2 Short term outcomes

D'Annibale et al. (2004) compared the first day to diet, the first day to bowel function recovery and the period of hospital stay of 53 cases of robotic assisted colorectal surgery to

the results of 53 cases of conventional laparoscopic colorectal surgery. The first day to diet was  $3 \pm 2$  in the robotic group and  $3 \pm 1$  in the laparoscopic group. The first day to bowel function recovery was the same as  $4 \pm 2$  in both groups. The period of hospital stay was  $10 \pm 4$  days and  $10 \pm 6$  days, respectively. These parameters were not significantly different between the groups. Blood loss was  $21 \pm 80$  ml and  $37 \pm 102$  ml, respectively. It also was not significantly different between the groups. The complications were intestinal obstruction, bowel injury, cerebrovascular accident and wound infection in the robotic group.

Authors	First flatus/ Length of stay (day)	Blood loss (ml)	Conversion No. (%)	Complication No. (%)
DeNoto et al., (2006)	- / 3.4	-	1 (9.1)	0 (0.0)
Hellan et al., (2007)	- / 4	200	1 (2.6)	15 (38.5)
Park et al., (2009)	- / 9.8	-	1 (2.2)	5 (11.1)
Luca et al., (2009)	2.02 / 7.5	68	0 (0.0)	12 (21.8)
Choi et al., (2009)	- / 7	-	0 (0.0)	3 (23.1)

Table 2. Short term outcomes of case series studies with at least 10 patients

Rawlings et al. (2007) reported the comparison results between 30 cases of robotic assisted colectomies and 27 cases of laparoscopic assisted colectomies. They compared the length of hospital stay, estimated blood loss and conversion rate. The cases of the robotic group were divided into 17 cases of robotic assisted right hemicolectomy and 13 cases of robotic assisted sigmoid colectomy. In the subgroup analysis of the right hemicolectomy, the length of hospital stay was  $5.2 \pm 5.8$  days in the robotic group and  $5.5 \pm 3.4$  days in the laparoscopic group ( $P=0.862$ ). Estimated blood loss was  $40.4 \pm 24.9$  ml,  $66.3 \pm 50.7$  ml, respectively ( $P=0.067$ ). In the subgroup analysis of the sigmoid colectomy, the length of hospital stay was  $6.0 \pm 7.3$  days in the robotic group and  $6.6 \pm 8.3$  days in the laparoscopic group ( $P=0.854$ ). The estimated blood loss was  $90.4 \pm 60.0$  ml and  $65.4 \pm 52.1$  ml, respectively ( $P=0.280$ ). Conversion occurred in two cases of the laparoscopic right hemicolectomies and in two cases of robotic assisted sigmoid colectomies. In these analyses, there were no significant differences of short term clinical outcomes between the robotic assisted colectomy and the laparoscopic colectomy.

Spinoglio et al. (2008) compared the first 50 consecutive cases of robotic assisted colorectal surgery to 161 cases of laparoscopic colorectal surgery. The first day to diet was 1.04 day in the robotic group and 1.08 day in the laparoscopic group ( $P=0.603$ ). The first day to passing flatus was 1.48 day and 1.67 day, respectively ( $P=0.704$ ). The length of hospital stay was 8.31 days and 7.74 days, respectively ( $P=0.928$ ). Complications occurred in 7 cases (14%) of the robotic group and in 27 cases (17%) in the laparoscopic group ( $P=0.489$ ). The conversion rate also was not different between group ( $P=0.603$ ). Two cases (4%) were converted in the robotic group and 4 cases (4%) were converted in the laparoscopic group. In the conversion cases of the robotic group, one case was converted to standard laparoscopic procedure and the other case was converted to the open procedure.

Baik et al. (2009) analyzed 56 homogenous cases of robotic assisted low anterior resection for rectal cancer. They showed a significant shorter length of hospital stay of the robotic group than the laparoscopic group. The length of hospital stay was  $5.7 \pm 1.1$  days in the robotic

group and  $7.6 \pm 3.0$  days in the laparoscopic group ( $P=0.001$ ). Also, the serious complication rate was 5.4% in the robotic group and 19.3% in the laparoscopic group, and it reached a statistical significance ( $P=0.025$ ). They postulated that the technical advantage of the robotic surgical system might decrease the serious complication rate and it was related to the shorter length of hospital stay.

	D'Annibale (2004)	Rawlings (2007)	Spinoglio (2008)	Baik (2009)
	Robotic assisted surgery / Laparoscopic surgery			
No. of patients	53 / 53	30 / 27	50 / 161	56 / 57
Malignancy (No.)	22 / 42	5 / 8	44 / 128	56 / 57
Procedure (No.)				
RHC	10 / 13	17 / 15	18 / 50	0 / 0
LHC	17 / 17	0 / 0	10 / 73	0 / 0
SC	11 / 4	13 / 12	0 / 0	0 / 0
LAR	10 / 15	0 / 0	19 / 26	56 / 57
APR	1 / 0	0 / 0	1 / 7	0 / 0
Others	4 / 6	0 / 0	2 / 5	0 / 0
Conversion (No.) (%)	6(11.3)/ 3(5.6)	2(6.6)/2(7.4)	2(4) / 4(4)	0(0.0) / 6(10.5)*
Mean Op time (min)	240 / 222	†218.9/169.2* ‡225.2/199.4	383.8/ 266.3*	190.1 / 191.1
Length of stay (day)	NA	†5.2/5.5 ‡6.0/6.6	7.7 / 8.3	5.7 / 7.6*
First flatus (day)		NA	1.67 / 1.48	1.9 / 2.1
Blood loss (ml)	21 / 37	†40.0/66.3 ‡90.4/65.4	NA	NA
Complication(No.)(%)	4(7.5)/ 9(17.0)	5(16.7)/4(14.8)	7(14.0) / -	6(10.7)/11(19.3)
Mortality (No.)	0 / 0	0 / 0	0 / 0	0 / 0
DRM (cm)	NA	NA	7.3 / 7.9	4.0 / 3.6
CRM positivity (No.)	NA	NA	NA	4 / 5
No.of Harvested LN	17 / 16	NA	22.03 / 22.85	18.4 / 18.7

RHC; Right hemicolectomy, LHC; Left hemicolectomy, SC; Sigmoid colectomy, LAR; Low anterior resection, APR; Abdominoperineal resection, PRM; Proximal resection margin, DRM; Distal resection margin, CRM; Circumferential resection margin, LN; Lymph node, NA; not available, † Cases of right hemicolectomy, ‡ Cases of sigmoid colectomy, \* Statistically significant parameter

Table 3. Comparative studies comparing robotic assisted to laparoscopic colorectal surgery with at least 10 patients

There were no conversion cases in the robotic group and six conversion cases in the laparoscopic group. The reasons for the conversions in the laparoscopic group were severe

hemorrhage from the lateral pelvic wall, severe narrow pelvic cavity, and rectal perforation. They thought that these reasons for conversion could be overcome by the advanced technology of the robotic surgical system such as the ability for fine dissection in a narrow surgical field. This study showed firstly the better short term outcomes of robotic colorectal surgery than laparoscopic colorectal surgery. However, it was a single surgeon's experience and a comparative study with a small number of cases.

In 2009, several authors reported cases of a series of robotic assisted colorectal surgery with new technical procedures (Park et al. (2009), Patrity et al. (2009), Choi et al. (2009), Ng et al. (2009)). The common results of these studies were the safety and feasibility of robotic assisted colorectal surgery.

### 5.3 Oncologic outcomes

Robotic colorectal surgery has not only been used in benign diseases but also in malignant diseases. Spinoglio et al. (2008) reported that there was no significant difference of the number of harvested lymph nodes between robotic assisted and laparoscopic colorectal surgery in the study which contained 44 malignant cases in the robotic group and 128 malignant cases in the laparoscopic group.

The important issue for better oncologic outcomes in colorectal cancer is a curative resection which means proper lymph node dissection. In rectal cancer surgery, the golden standard procedure is total mesorectal excision (TME) (Heald et al., 1982, Enker et al., 1995, Havenga et al., 1996). A complete TME procedure requires a precise dissection of loose avascular areola tissue between the fascia propria of the rectum and the presacral fascia without any injury to the fascia propria of the rectum. The macroscopic completeness of the fascia propria of the rectum is scored into three grades (complete, nearly complete, incomplete) and is a predictive factor of the patient's prognosis (Nagtegaal et al., 2002). In Baik et al.'s study (2007), the pathologic results with macroscopic grades were excellent. These results could be the reason for decreasing the local recurrence rate and improving long term survival rates in rectal cancer patients. The technological advantages of the surgical system may influence the results of the excellent mesorectal grade of robotic assisted TME. In 2009, Baik et al. reported that the mesorectal grade after robotic assisted low anterior resection was significantly better than the mesorectal grade after conventional laparoscopic low anterior resection in their comparative study. This data supports that robotic assisted low anterior resection may be better than laparoscopic assisted low anterior resection for rectal cancer patients in terms of oncologic outcomes. However, the circumferential resection margin (CRM) involvement rate was not different between the robotic assisted low anterior resection group and the laparoscopic low anterior resection group. Involvement of CRM is influenced by the tumor location from the fascia propria of the rectum and the quality of rectal dissection. The advanced robotic technology influences the quality of rectal dissection and did not influence the location of the tumor. The different results between the CRM involvement rate and mesorectal grade could be explained by the above reason.

In colon cancer surgery, the laparoscopic procedure has been increased because it improves the quality of life and there are no adverse effects of laparoscopic surgery in survival (COST trial, 2004). These results mean that laparoscopic colon resection fulfills the concept of oncologic resection with a proper resection margin and lymph node dissection similar to the open procedure. Thus, there is no further prospect to improve survival in minimally invasive procedures such as laparoscopic or robotic assisted colon cancer surgeries.

Until now, there is no comparable oncologic data between robotic assisted colorectal surgery and laparoscopic or open colorectal surgery. Future large scale prospective randomized trials are necessary.

## 6. Conclusions

Improvements of the robotic surgical system are continuously being made to overcome the technical limitations and disadvantages found during the surgeries. So detailed operation methods are newly designed to adapt to the upgraded model of the robotic surgical system. The major core technologies of the robotic surgical system are a three dimensional image of the surgical field and a function of articulation of the instruments tips compared to conventional laparoscopic instruments. With the help of these technologies, the incidence of robotic assisted colorectal surgery is somewhat increased for the cure of not only benign diseases but also malignant diseases with the rapidly developing technology of the robotic surgical system. However, most studies have reported only on the feasibility and the safety of the robotic assisted colorectal surgery. Moreover, oncologic outcomes have not been reported until now even though the robotic surgical system has been used for colorectal cancer. Thus, future studies should be performed not only to find the validity to use the robotic surgical system but also to establish the benefits of its use.

## 7. Acknowledgement

The author would like to acknowledge Mrs. MiSun Park for her dedicated assistance of manuscript editing and English revision.

## 8. References

- Anvari M., Birch D.W., Bamehriz F., Gryfe R., Chapman T. (2004). Robotic-assisted laparoscopic colorectal surgery. *Surg Laparosc Endosc Percutan Tech*, 14, 311-315.
- Baik S.H., Lee W.J., Rha K.H., et al. (2007). Robotic total mesorectal excision for rectal cancer using four robotic arms. *Surg Endosc*, 22, 792-797.
- Baik S.H., Ko Y.T., Kang C.M., et al. (2008). Robotic tumor-specific mesorectal excision of rectal cancer: short-term outcome of a pilot randomized trial. *Surg Endosc*, 22, 1601-1608.
- Baik S.H., Kwon H.Y., Kim J.S., et al. (2009). Robotic versus laparoscopic low anterior resection of rectal cancer: short-term outcome of a prospective comparative study. *Ann Surg Oncol*, 16, 1480-1487.
- Braumann C., Jacobi C.A., Menenakos C., et al. (2005). Computer-assisted laparoscopic colon resection with the da Vinci system: our first experiences. *Dis Colon Rectum*, 48, 1820-1827.
- Bruce G.W., Fleshman J.W., Beck D.E., et al. (2007), *The ASCRS textbook of colon and rectal surgery*, NY, USA, Springer.
- D'Annibale A., Morpurgo E., Fisco V., et al. (2004). Robotic and laparoscopic surgery for treatment of colorectal disease. *Dis Colon Rectum*, 47, 2162-2168.
- Delaney C.P., Lynch A.C., Senagore A.J., Fazio V.W. (2003). Comparison of robotically performed and traditional laparoscopic colorectal surgery. *Dis Colon Rectum*, 46, 1633-1639.

- DeNoto G., Rubach E., Ravikumar T.S. (2006). A standardized technique for robotically performed sigmoid colectomy. *J Laparoendosc Adv Surg Tech A*, 16, 551-556.
- Enker W., Thaler H.T., Cranor M.L., Polyak T. (1995). Total mesorectal excision in the operative treatment of carcinoma of the rectum. *J Am Coll Surg*, 181, 335-346.
- Feliciotti F., Guerrieri M., Paganini A.M., DeSanctis A., et al. (2003). Long term results of laparoscopic vs open resections for rectal cancer for 124 unselected patients. *Surg Endosc*, 17, 1530-1535.
- Giulianotti P.C., Coratti A., Angelini M., et al. (2003). Robotics in general surgery: personal experience in a large community hospital. *Arch Surg*, 138, 777-784.
- Guillou P.J., Quirke P., Thorpe H., et al. (2005). Short-term endpoint of conventional versus laparoscopic-assisted surgery in patients with colorectal cancer (MRC CLASICC trial): multicenter, randomized controlled trial. *Lancet*, 365, 1718-1726.
- Hashizume M., Shimada M., Tomikawa M., et al. (2002). Early experiences of endoscopic procedures in general surgery assisted by a computer-enhanced surgical system. *Surg Endosc*, 16, 1187-1191.
- Havenga K., DeRuiter M.D., Enker W.E., Welvaart K. (1996). Anatomic basis of autonomic nerve preserving total mesorectal excision for rectal cancer. *Br J Surg*, 83, 384-388.
- Heald R.J., Husband E.M., Ryall R.D. (1982). The mesorectum in rectal cancer surgery - clue to pelvic recurrence? *Br J Surg*, 69, 613-616.
- Hellan M., Anderson C., Ellenhorn J.D.I., Paz B., Pigazzi A. (2007). Short-term outcomes after robotic-assisted total mesorectal excision for rectal cancer. *Ann Surg Oncol*, 14, 3168-3173.
- Hoffman GC, Baker JW, Fitchett CW, Vansant JH. (1994). Laparoscopic-assisted colectomy: initial experience. *Ann Surg*, 219, 732-740.
- Jayne D.G., Guillou P.J., Thorpe H., et al. (2007). Randomized trial of laparoscopic-assisted resection of colorectal carcinoma: 3-year results of the UK MRC CLASICC trial group. *J Clin Oncol*, 25, 3061-3068.
- Liang JT, Lai HS, Lee PH. (2007). Laparoscopic medial to lateral approach for the curative resection of right sided colon cancer. *Ann Surg Oncol*, 14, 1878-1879.
- Liang JT, Huang KC, Lai HS, Lee PH, Sun CT. (2007). Oncologic results of laparoscopic D3 lymphadenectomy for male sigmoid and upper rectal cancer with clinically positive lymph nodes. *Ann Surg Oncol*, 14, 1980-1990.
- Morino M., Parini U., Giraudo G., et al. (2003). Laparoscopic total mesorectal excision: a consecutive series of 100 patients. *Ann of Surg*, 237, 335-342.
- Nagtegaal I.D., Van de Velde C.J., Van der Worp E., Kapiteijn E., Quirke P., Van Krieken J.H. Cooperative Clinical Investigators of the Dutch Colorectal Cancer Group (2002). Macroscopic evaluation of rectal cancer resection specimen: clinical significance of the pathologist in quality control. *J Clin Oncol*, 20, 1729-1734.
- Nelson H., Sargent D.J., Wienad H.S., et al. (2004). A comparison of laparoscopically assisted and open colectomy for colon cancer. *N Engl J Med*, 350, 2050-2059.
- Pigazzi A., Ellenhorn J.D.I., Ballantyne G.H., Paz I.B. (2006). Robotic-assisted laparoscopic low anterior resection with total mesorectal excision for rectal cancer. *Surg Endosc*, 20, 1521-1525.
- Rawlings A.L., Woodland J.H., Vegunta R.K., Crawford D.L. (2007). Robotic versus laparoscopic colectomy. *Surg Endosc*, 21, 1701-1708.

- Rawlings A.L., Woodland J.H., Crawford D.L. (2006). Telerobotic surgery for right and sigmoid colectomies: 30 consecutive cases. *Surg Endosc*, 20, 1713-1718.
- Ruurda J.P., Draaisma W.A., Van Hillegesberg R., et al. (2005). Robot-assisted endoscopic surgery: a four-year single-centre experience. *Dig Surg*, 22, 313-320.
- Sebajang H., Trudeau P., Dougall A., Hegge S., Mckinley C., Anvari M. (2006). The role of telementoring and telerobotic assistance in the provision of laparoscopic colorectal surgery in rural areas. *Surg Endosc*, 20, 1389-1393.
- Spinoglio G., Summa M., Piora F., et al. (2008). Robotic colorectal surgery: first 50 cases experience. *Dis Colon Rectum*, 51, 1627-1632.
- Vibert E., Denet C., Gayet B. (2003). Major digestive surgery using a remote-controlled robot: the next revolution. *Arch Surg*, 138, 1002-1006.
- Weber P.A., Merola S., Wasieleswski A, Ballantyne G.H. (2002). Telerobotic-assisted laparoscopic right and sigmoid colectomies for benign disease. *Dis Colon Rectum*, 45, 1689-1694.
- Woeste G., Bechstein W.O., Wullstein C. (2005). Does telerobotic assistance improve laparoscopic colorectal surgery? *Int J Colorectal Dis*, 20, 253-257.

IntechOpen



## **Robot Surgery**

Edited by Seung Hyuk Baik

ISBN 978-953-7619-77-0

Hard cover, 172 pages

**Publisher** InTech

**Published online** 01, January, 2010

**Published in print edition** January, 2010

Robotic surgery is still in the early stages even though robotic assisted surgery is increasing continuously. Thus, exact and careful understanding of robotic surgery is necessary because chaos and confusion exist in the early phase of anything. Especially, the confusion may be increased because the robotic equipment, which is used in surgery, is different from the robotic equipment used in the automobile factory. The robots in the automobile factory just follow a program. However, the robot in surgery has to follow the surgeon's hand motions. I am convinced that this In-Tech Robotic Surgery book will play an essential role in giving some solutions to the chaos and confusion of robotic surgery. The In-Tech Surgery book contains 11 chapters and consists of two main sections. The first section explains general concepts and technological aspects of robotic surgery. The second section explains the details of surgery using a robot for each organ system. I hope that all surgeons who are interested in robotic surgery will find the proper knowledge in this book. Moreover, I hope the book will perform as a basic role to create future prospectives. Unfortunately, this book could not cover all areas of robotic assisted surgery such as robotic assisted gastrectomy and pancreaticoduodenectomy. I expect that future editions will cover many more areas of robotic assisted surgery and it can be facilitated by dedicated readers. Finally, I appreciate all authors who sacrificed their time and effort to write this book. I must thank my wife NaYoung for her support and also acknowledge MiSun Park's efforts in helping to complete the book.

### **How to reference**

In order to correctly reference this scholarly work, feel free to copy and paste the following:

Seung Hyuk Baik and M.D. (2010). Robotic Assisted Colorectal Surgery, Robot Surgery, Seung Hyuk Baik (Ed.), ISBN: 978-953-7619-77-0, InTech, Available from: <http://www.intechopen.com/books/robot-surgery/robotic-assisted-colorectal-surgery>

**INTECH**  
open science | open minds

#### **InTech Europe**

University Campus STeP Ri  
Slavka Krautzeka 83/A  
51000 Rijeka, Croatia  
Phone: +385 (51) 770 447  
Fax: +385 (51) 686 166

#### **InTech China**

Unit 405, Office Block, Hotel Equatorial Shanghai  
No.65, Yan An Road (West), Shanghai, 200040, China  
中国上海市延安西路65号上海国际贵都大饭店办公楼405单元  
Phone: +86-21-62489820  
Fax: +86-21-62489821



[www.intechopen.com](http://www.intechopen.com)

IntechOpen

IntechOpen

© 2010 The Author(s). Licensee IntechOpen. This chapter is distributed under the terms of the [Creative Commons Attribution-NonCommercial-ShareAlike-3.0 License](#), which permits use, distribution and reproduction for non-commercial purposes, provided the original is properly cited and derivative works building on this content are distributed under the same license.

IntechOpen

IntechOpen