

We are IntechOpen, the world's leading publisher of Open Access books Built by scientists, for scientists

4,800

Open access books available

122,000

International authors and editors

135M

Downloads

Our authors are among the

154

Countries delivered to

TOP 1%

most cited scientists

12.2%

Contributors from top 500 universities



WEB OF SCIENCE™

Selection of our books indexed in the Book Citation Index
in Web of Science™ Core Collection (BKCI)

Interested in publishing with us?
Contact book.department@intechopen.com

Numbers displayed above are based on latest data collected.

For more information visit www.intechopen.com



Robot Attack on Vascular Surgery

Petr Štádlér

Na Homolce Hospital, Department of Vascular Surgery and Department of Cardiovascular Surgery, Charles University, First Medical Faculty and General Teaching Hospital, Prague Czech Republic

1. Introduction

Over the past few years, technological developments in global medicine have given rise to a whole series of new surgical techniques, particularly in minimally invasive surgery (Dion et al., 1996). Few people can now imagine general surgery or gynaecology without laparoscopic techniques, although this was not initially the case. Laparoscopic interventions reduce patient trauma, lower treatment and recovery times and, finally, also reduce overall treatment costs. Major developments in laparoscopic surgery in the 1990s have had an impact on vascular surgery. Minimally invasive approaches used in general surgery have gradually become a novel technique used in vascular surgery. Laparoscopy was introduced into vascular surgery much later than other areas and was approached with far greater apprehension, as well as with limited interest, by a number of renowned vascular surgeons, who were censorious of it from the very beginning (Dion et al., 1998). The main reasons for this lack of interest in laparoscopic vascular surgery were the difficulties associated with suturing of the vascular anastomosis, the long clamping times and complications in accessing the aorta and pelvic arteries, which are located low down next to the spine. On an imaginary scale of difficulty, vascular laparoscopic techniques would score extremely high, vascular surgeons in general have very little experience of laparoscopy and the learning curve is a long one. These are probably the main reasons preventing the further expansion of vascular laparoscopy, although there are centres in both Europe and the United States that are actively using vascular laparoscopic methods. Total laparoscopic aortoiliac surgery can be performed on patients with occlusive diseases and aneurysms.

Robotics, which began to appear in 2000, is a state-of-the-art surgical technology (Marescaux et al., 2001). The Department of Vascular Surgery at Prague's Na Homolce Hospital has been performing laparoscopic reconstructions since 2003 and these have been robot-assisted since the end of 2005. Under the direction of Dr. Petr Štádlér, the robotic vascular team has not only created its own modified transperitoneal approach for these interventions, but has catapulted Czech robotic vascular surgery to the forefront of this modality worldwide. (Fig. 1. Robotic master console).

Source: Medical Robotics, Book edited by Vanja Bozovic, ISBN 978-3-902613-18-9, pp.526, I-Tech Education and Publishing, Vienna, Austria

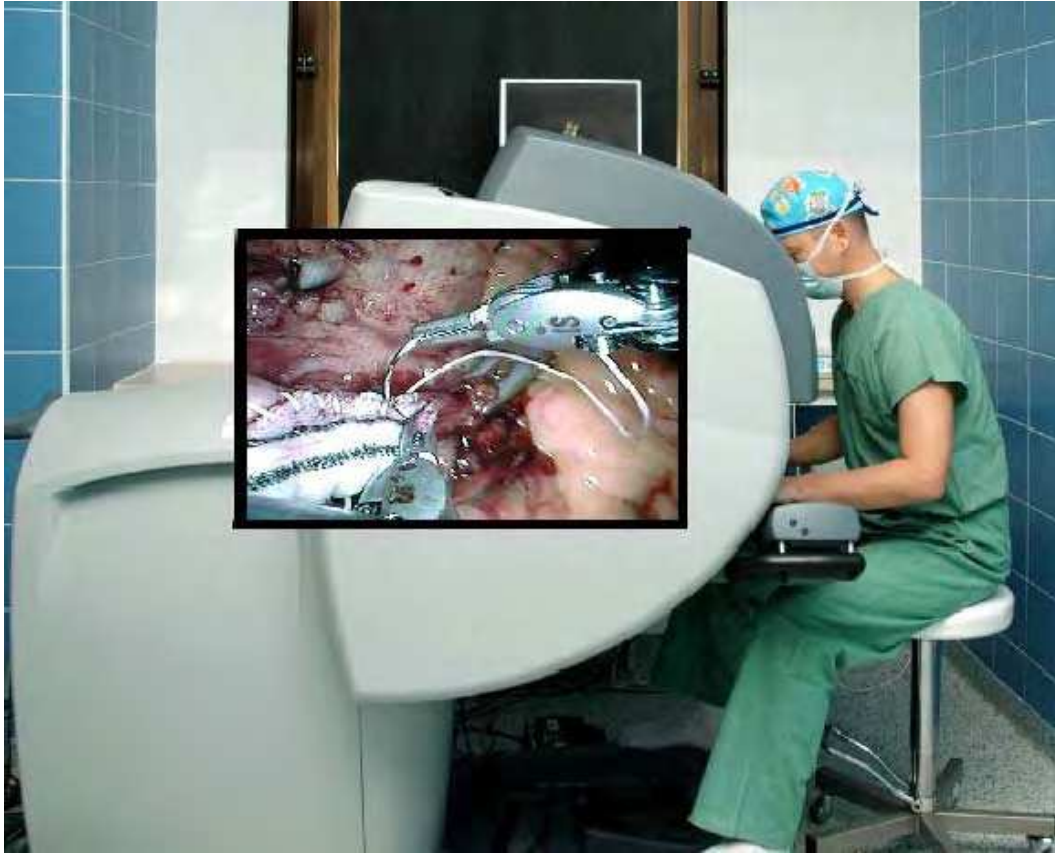

Figure 1. Robotic master console

2. Robotic Surgery and Medical Simulation

Robotic surgery and medical simulation have much in common: both use a mechanized interface that provides feedback from the patient to the health care professional, or physician, both use monitors to visualize the performance of the procedure, and both use computer software applications through which the physician interacts. Both technologies are experiencing rapid adoption and are viewed as modalities that allow physicians to perform increasingly complex minimally invasive procedures while enhancing patient safety.

The growing experience of physicians with medical simulation and robotic surgery brings new benefits (O'Toole et al., 1999). The increasing success and use of robotics will lead to a growth in the need for trained physicians with the appropriate licence to provide patients with complex medical services. The role played by simulation in the certification of these professionals also forms an important part of medical training programmes. Many professional medical societies and training programmes use this type of technology to assess the ability of health care professionals during the certification procedure.

2.1 Robotic Surgery

Robotic surgery can be characterized as an operation that uses a computer-controlled robotic system. The advantage of this technique is that it does not require direct contact between the patient and surgeon, while also significantly enhancing the precision of the surgery by eliminating tremor from the surgeon's hands and providing perfect 3D visualization. It is

also now possible to perform surgical interventions in places that would be hard to access using classical surgical or laparoscopic techniques. This means that this type of operation can significantly enhance patient safety (Talamini et al., 2003).

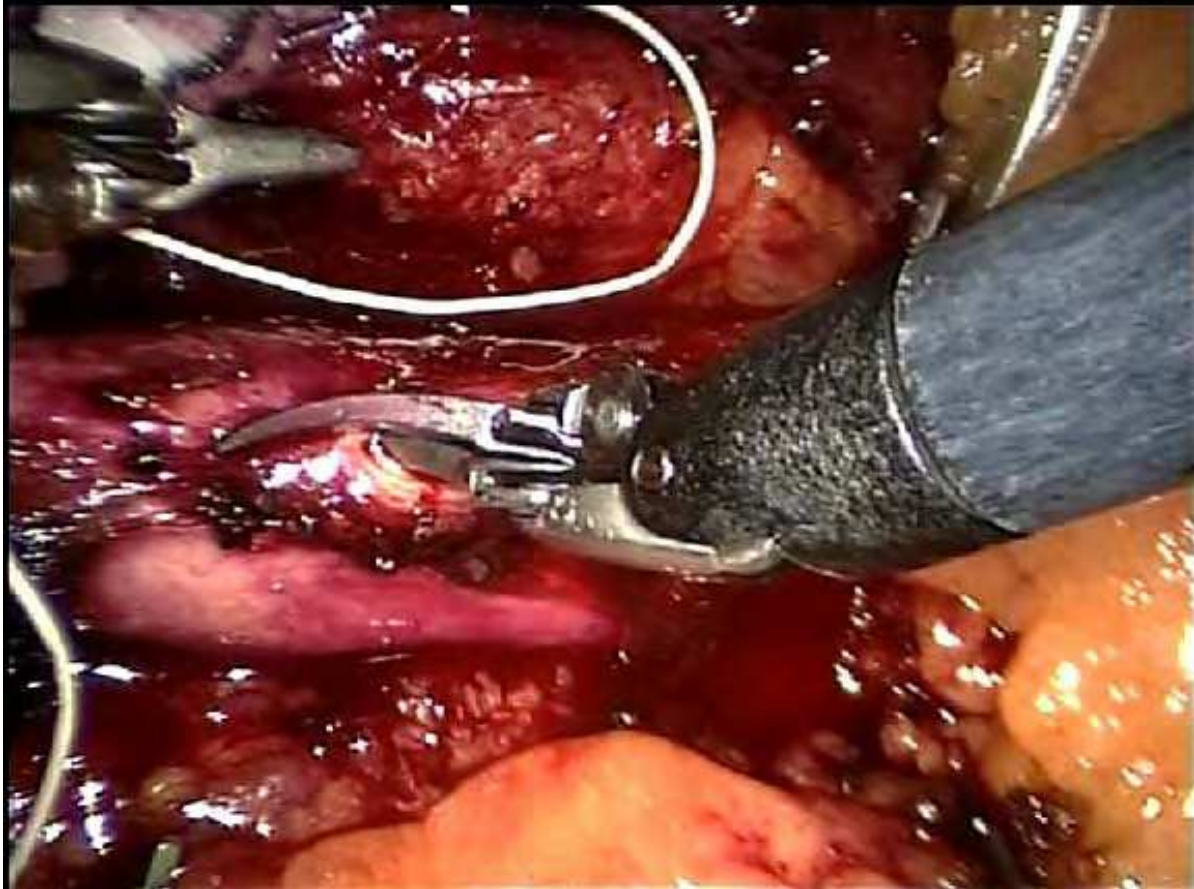


Figure 2. Robotic scissors - aortotomy

2.2 The da Vinci Robotic System

The da Vinci surgical robot is a system with multiple arms and composed of three principal parts. The first is the patient-side cart, which can have three or even four arms. The second part is the instrument tower and the third the surgeon's console, from which the arms and instruments are operated and where the 3D visualization provides the surgeon with a perfect view of the operative field in the patient's body. Other surgical team members can follow the procedure on television screens located in the operating theatre itself. A powerful computer is an essential part of the system.

Unlike laparoscopic instruments, which do not have flexible ends, robotic instruments copy the movements of the human hand (using the Endo-Wrist® technology) and are easy to manipulate, even in more inaccessible areas. The computer adjusts all movements in order to enhance the safety and precision of the surgical instruments in the patient's body. This, together with the elimination of tremor from the surgeon's hands, significantly reduces the risks associated with surgery (Nio et al., 2005).

The da Vinci robot was originally developed by NASA for the American army to use on aircraft carriers or during space flights, enabling surgeons to perform remote interventions from base. The civilian version of the robot has been available for use by physicians since 2000.

This is not a classical robot in the narrower sense of the word, as the procedure is performed by a surgeon who uses the technology to enhance his/her surgical skills. The robot cannot perform the intervention itself and simply translates the movements of the surgeon's hands. Robot-assisted surgery has raised laparoscopic surgery to a higher level of quality and, given the almost perfect movements of the instruments, the system inflicts less damage on the surrounding tissues. The successful use of robotics in surgery depends on an understanding of all the technical functions of the robotic equipment, sufficient experience of classical laparoscopy and teamwork. No less important is the improved orientation of the surgeon in the operative field, with the new opportunities afforded by the robotic visualization and instrument flexibility. (Fig. 2. Robotic scissors - aortotomy).

In the USA and the western states of the European Union, a highly efficient training course has been developed for robotic surgical teams, which is required as part of the delivery package for robotic surgery centres.

The first level prioritises the understanding of all the technical functions of the equipment, coordination and teamwork, and preparing patients for the procedure, while the second stage focuses on the surgeon's orientation in the operating field using the new options offered by robotic visualization and the mobility of the equipment. During the third stage, which is seen as building additional endoscopic skills, the surgeon is shown clinically tested procedures that are robotically assisted in his/her area of specialization.

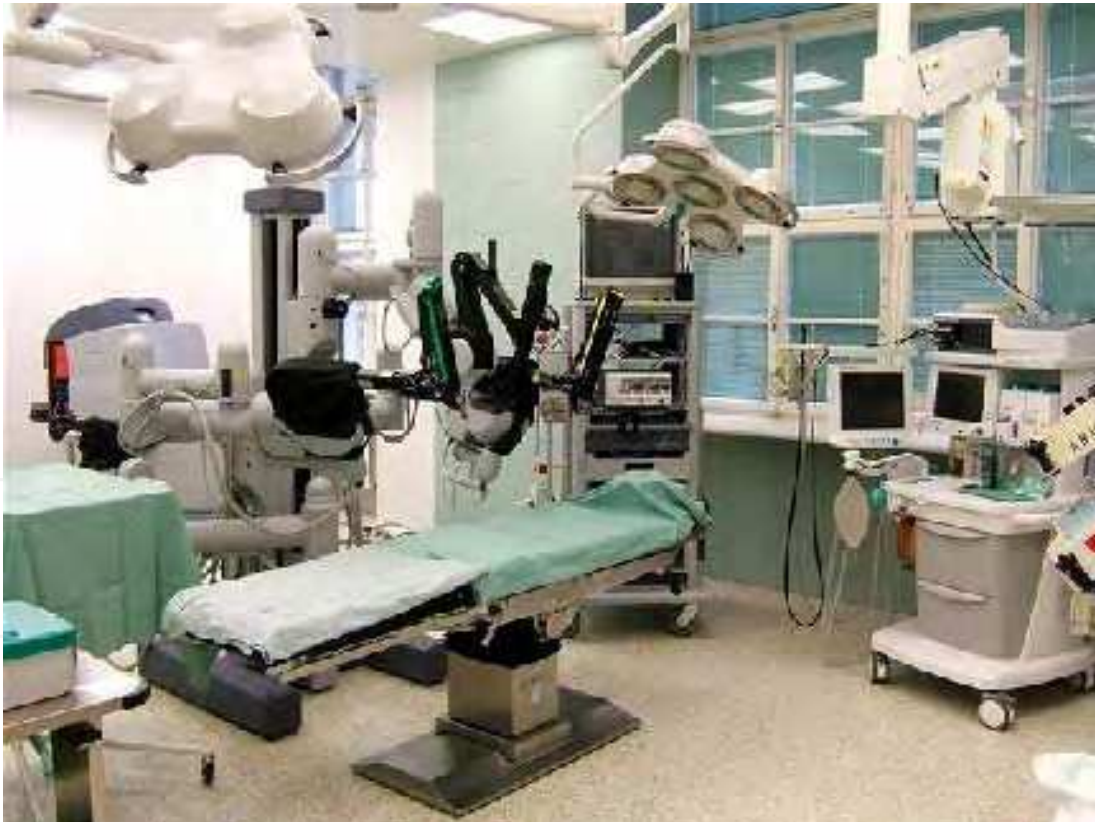

Figure 3. Robotic Surgery Centre

2.3 The Multidisciplinary Robotic Surgery Centre

Robotic surgery today is developing into a multidisciplinary modality used by surgical departments that deal with the soft tissue structures in the abdominal or thoracic cavities. It

also uses all the advantages of minimally invasive methods. It is specifically used for general abdominal surgery, gynaecology, urology, oncosurgery, thoracic surgery, vascular surgery and cardiac surgery. (Fig. 3. Robotic surgery centrum).

Robotic surgery centres are generally established as a separate multidisciplinary operating theatre, shared among the individual specialists to perform field-specific procedures. Over time, a number of these multidisciplinary centres have become characterized by dominant specialities led by individuals who have achieved exceptional outcomes in robotic surgery, often becoming single-disciplinary specialized robotic units, which may often require a separate robotic system to be established in the same health care facility. This leads to a concentration of highly specialized care and an increase in the number of procedures from a wider catchment area. The final outcome of this process is a dramatic rise in the quality of care, as a correlation of the number of interventions performed.

2.4 The Introduction of Robotics into Vascular Surgery

The introduction of robotics has led to a fundamental turning point for laparoscopic vascular surgery, which has always entailed relatively difficult manipulation with instruments and required a long time to construct the anastomosis, leading to long aortal clamping times. The robotic system removes these fundamental disadvantages of laparoscopy and opens up the possibility of expanding robot-assisted laparoscopic surgery in this area (Wisselink et al., 2002).

At the present time, the Department of Vascular Surgery at Na Homolce Hospital performs a range of vascular reconstructions of the pelvic arteries and abdominal aorta. This has ranked the hospital alongside a small number of centres worldwide, these can be counted on the fingers of one hand, where robotic-assisted vascular reconstructions are routinely performed. Our physicians are planning future expansion of the “range” of these procedures to include other types of vascular reconstructions (Štádler et al., 2006,b).

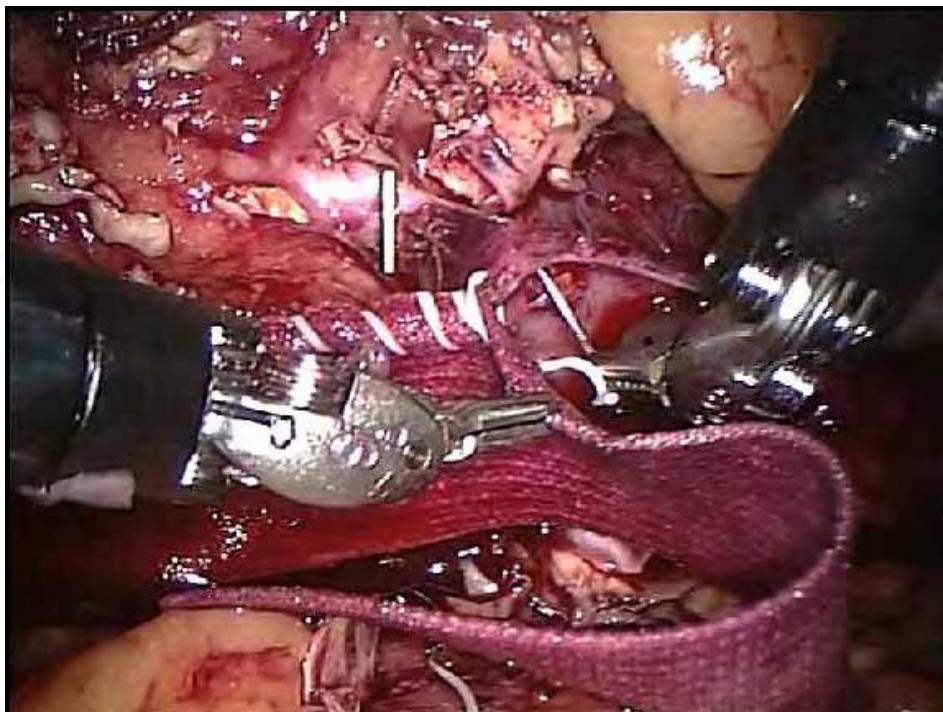


Figure 4. Aortoiliac prosthetic patch

Thanks to the early introduction of robotic surgery in the Czech Republic and the progressive nature of the robotic team, the opportunity has arisen, with the support of the manufacturer, to create another training centre for central and eastern European states in the Czech Republic. We should not fail to mention the international recognition achieved by the vascular robotic team at Prague's Na Homolce Hospital, a team that, through its perseverance and excellent medical outcomes, is training new teams in countries such as the USA, the country that originated robotic surgery. As an example, the first robotic-assisted abdominal aortal reconstruction was performed in the first week of February 2007 by a team of surgeons from the Baptist Memorial University Hospital in Memphis in the American state of Tennessee, under the direction of Dr. Petr Štádl from Na Homolce Hospital in Prague.

3. Robotic Surgery in the Czech Republic

November 2005 saw the beginning of an era of robot-assisted minimally invasive surgery in the Czech Republic. The first facilities to decide to install a Centre of Robotic Surgery with the da Vinci robotic system have now taken a wide lead. They are lecturing on their successes both at home and abroad, attend courses abroad not only as trainees but now also as trainers, even in the da Vinci robotic system's country of origin. These centres are negotiating with professional associations, health insurance companies and political representatives and are creating the environment for those who are now deciding to introduce robotic surgery.

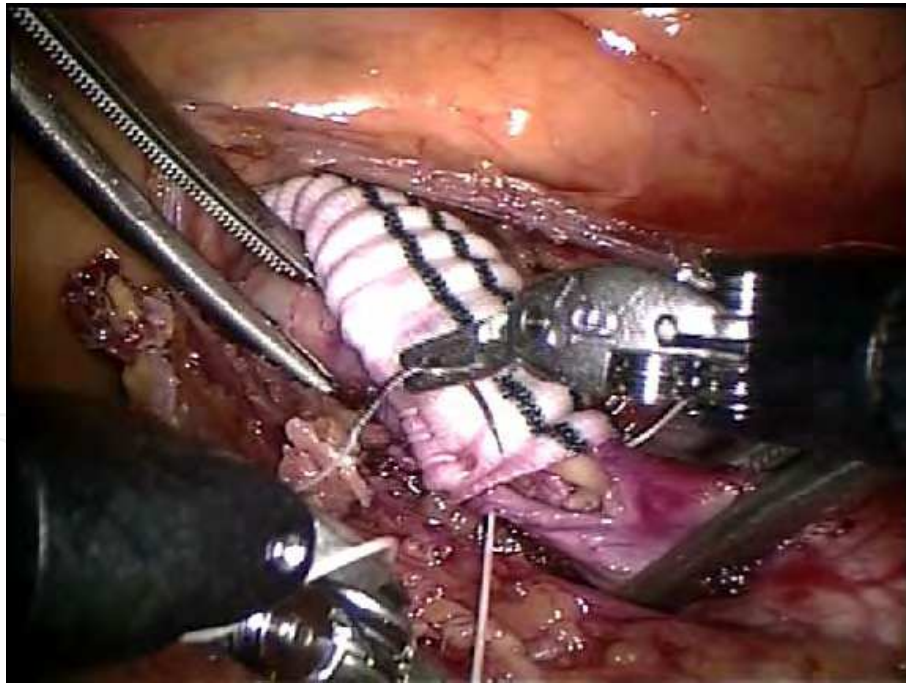


Figure 5. Central anastomosis of a right iliofemoral bypass

3.1 Robotic Vascular Surgery in Na Homolce Hospital, Prague

The da Vinci 1200 robotic system has been used in Na Homolce Hospital, Prague for a range of surgical disciplines since November 2005. The hospital's robotic vascular surgery achievements rank it among the world-class institutions performing these procedures and,

in terms of their number and outcomes, would be at the top of an imaginary ladder of globally renowned centres. Some of these procedures have been performed for the first time ever with robotic assistance (an operation on an isolated common pelvic arterial aneurysm or the reconstruction of the abdominal aorta by prosthetic patch). (Fig. 4. Aortoiliac prosthetic patch). The fact that the experience of the Homolka vascular robotic team is accepted, not only by Czech centres, but that there is also great interest in its work from abroad, is evidenced by the number of international lectures and publications they produce. To date, over 70 robotic-assisted arterial reconstructions have been performed in the aortoiliac area and a total of over 120 general laparoscopic vascular procedures (including robot-assisted). Experience of laparoscopic vascular surgery is seen as a prerequisite for performing robot-assisted vascular operations.

The robotic vascular surgery team in Prague's Na Homolce Hospital, led by Dr. Petr Štádler, has developed surgical procedures for aorto- and ilio- femoral bypasses, endarterectomies of the abdominal aorta and resection and replacement of abdominal aortal aneurysms, which are now performed as standard practice. (Fig. 5. Central anastomosis of a right iliofemoral bypass, Fig. 6. Aortoiliac thromboendarterectomy, Fig. 7. Distal anastomosis of AAA). The physicians have been able to find optimal locations for ports to facilitate the use of the robotic system in vascular surgery. The basis for robotic vascular reconstruction is the modified transperitoneal approach, a description of which was published in Europe and in the USA.

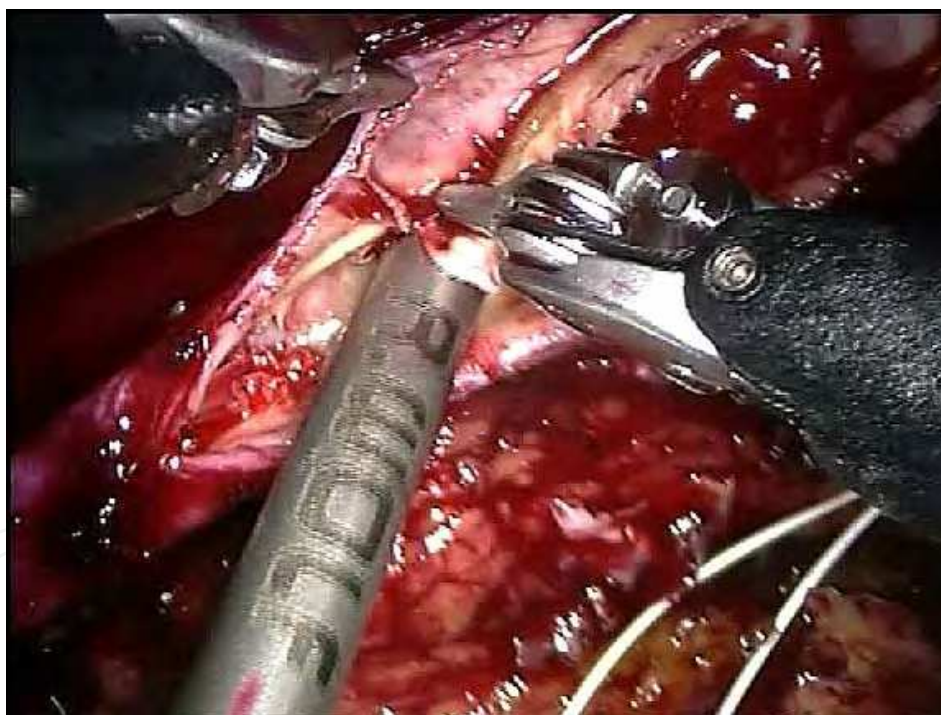

Figure 6. Aortoiliac thromboendarterectomy

3.2 A Modified Technique of Transperitoneal Direct Approach

This modified procedure is offered to all robot-assisted patients. The da Vinci robotic system is positioned for use on the patient's right side. The patient is placed on his or her right side at a 30-45° angle, in a mild Trendelenburg position (10° to 15°), with the left arm lying along the length of the body. Trocar positioning is slightly different from conventional laparoscopy because of the volume of the articulating robotic arms. The pneumoperitoneum

is secured via a minor left subcostal incision with an abdominal pressure of 12 mm Hg. An 12-mm trocar for the robotic arm is introduced. The next three 12-mm trocars are inserted below the costal margin for the laparoscopic instruments during the first part of operation and for the robotic arms, for the assistant's port and the robotic camera in the second part. Two 12-mm ports are inserted on the midline for the central and distal aortic or pelvic clamp. (Fig. 8. Position of trocars). Dissections of the aorta and iliac arteries are performed laparoscopically. The retroperitoneum is opened on the left side of the aorta from its bifurcation to the left renal vein alongside the left gonadal vein. The posterior peritoneum with preaortic fat and ganglia is liberated as necessary up to the right aortic wall and stitched up to the parietal peritoneum (Štádlér et al., 2006,a). Thus, mobilization of the entire descending colon is not required. (Fig. 9. Fixed posterior peritoneum - perioperative view) The subrenal aorta and both common iliac arteries are exposed, and the inferior mesenteric artery is usually temporarily clipped except for abdominal aortic aneurysm (AAA) resection. In patients who have had an AAA, the inferior mesenteric artery is interrupted and visible lumbar arteries are clipped. After the aneurysmal sac is opened, the robotic technique is used to internally control the remaining lumbar arteries with free 4-0 shortened polytetrafluoroethylene stitches. Tunnelling is performed from one or two groins under the direct view of the laparoscopic video camera using a long DeBakey aortic vascular clamp. A conventional knitted Dacron vascular prosthesis (Albograft, Sorin Biomedica Cardio, SpA, Saluggia, Italy), with attached shortened 3-0 or 4-0 Gore-Tex suture (W. L. Gore & Associates, Flagstaff, Ariz) is inserted into the abdomen through an 12-mm trocar. The robotic system is used to construct the central anastomosis (twice for both anastomoses in the case of tube grafts), to perform a thromboendarterectomy, and mostly for posterior peritoneal suturing. The role of the assistant at the patient's side is limited to exposure, assisting in the dissection, haemostasis, and maintaining traction on the running sutures performed by the robot.

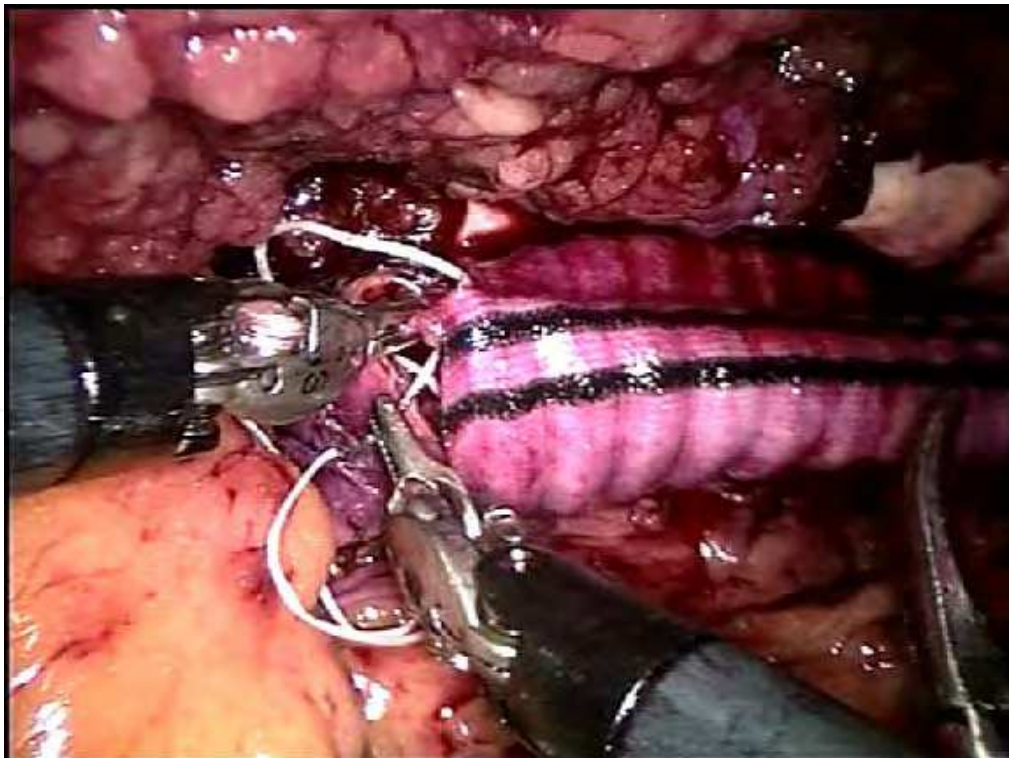


Figure 7. Distal anastomosis of AAA

3.3 Advantages and Disadvantages of the Robot-Assisted Vascular Procedure

From a practical point of view, the greatest advantage of the robot-assisted procedure has proved to be the speed of construction of the vascular anastomosis. This has helped to eliminate the largest disadvantage of laparoscopic vascular reconstruction – lengthy clamping time. Reducing the time needed to construct the anastomosis also shortens the period of ischaemia temporary of the lower limbs while the aortal clamps are being placed. This represents a significant reduction in the level of stress placed on the heart and muscular reperfusion and leads to better post-operative results, including morbidity and mortality. These times are now comparable to those of standard vascular surgery, and provide all the advantages of minimally invasive surgical techniques. Patients mainly benefit through shorter hospitalization periods and an early return to their normal activities and working life, which, in most cases, is not significantly restricted. Another important factor is the excellent cosmetic result. A further advantage of this method is that it can also be used with obese patients, where standard interventions are technically demanding and often involve problems with the healing of wounds after laparoscopy. The main disadvantage is still the high price, not only of the robotic system, but also of the individual instruments, which have a pre-determined life expectancy, and in the case of vascular surgery, the need to combine robotic and standard laparoscopy.

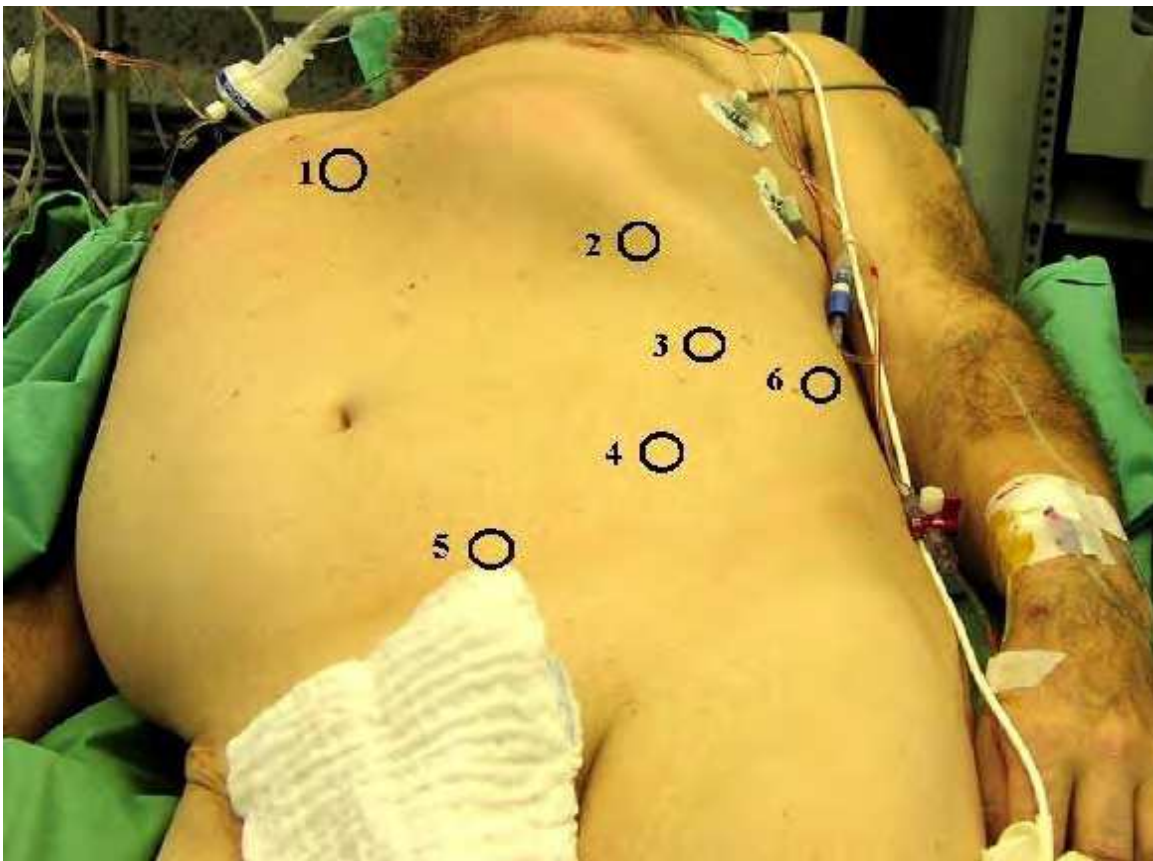


Figure 8. Position of trocars (1, central clamp; 2, and 4, robotic arms; 3, robotic camera; 5, distal clamp; 6, assistant's port)

When this method was being introduced, particularly at the beginning, mostly younger patients, with no associated disorders, were being indicated. Alongside the increasing

experience of the team, the circle of suitable candidates for robotic-assisted procedures is constantly being widened. However, operations on the abdominal aorta are generally extremely traumatic for patients and are associated with a high level of risk, particularly for polymorbid patients with more serious forms of ischaemic heart disease and failing renal and respiratory functions. Patients suffering from acute forms of obstructive pulmonary disease are not suitable for either laparoscopic or robot-assisted procedures, given the need for a capnoperitoneum. A contraindication for capnoperitoneum automatically entails a contraindication for laparoscopic-robotic vascular procedures. On the other hand, physicians from Prague had a successful experience with two patients with severe left ventricular dysfunction after myocardial infarction (25 and 29%). They performed robot-assisted procedures with low pressure pneumoperitoneum (8-10 mm Hg).

Neither may patients be indicated for these interventions after major intra-abdominal operations with numerous peritoneal accretions, but adhesions after previous laparotomy may sometimes help to create a clear working field. Obesity is no longer a major contraindication.

3.4 Results of our own Robot-Assisted Vascular Procedures

Robot-assisted vascular surgery can be of value in overcoming the long learning curve for laparoscopic suturing of vascular anastomoses. In the reported total laparoscopic procedures by Štádlér team, the mean operating time was 259 minutes (range, 150 to 420 minutes), and the clamping time was 69 minutes (range, 35 to 150). When compared with our robot-assisted vascular procedures, the times for laparoscopic procedures and aortoiliac cross-clamping were longer.

From November 2005 to June 2007, 70 robot-assisted aortoiliac reconstructions were performed at the Department of Vascular Surgery, Na Homolce Hospital in Prague, Czech Republic. They included 3 aortoiliac thromboendarterectomies with prosthetic patch, and 12 iliofemoral, 28 aortounifemoral, and 20 aortobifemoral bypasses. Six patients were treated for AAA and one for common iliac artery aneurysm (CIAA). Among these patients, there were 56 men and 14 women, with a mean age of 61 years (range, 38 to 78 years). Mortality in the cohort mentioned above was 0%. In three cases (4.3%) conversion to mini or full laparotomies was required and two patients (2.8%) experienced nonlethal post-operative complications. The duplex scans demonstrated 100% graft patency.

Conversion to mini-laparotomy occurred in one patient, because difficulties were encountered with the Endo Gia stapler during the exclusion of CIAA after completion of the robotic anastomosis. The second conversion to a full laparotomy was required on the first postoperative day because of a haemoperitoneum, caused by bleeding from a clipped lumbar artery. The third conversion to mini-laparotomy was caused by prolonged bleeding from lumbar arteries after robotic creation of a central anastomosis of an aortic tube graft. The first converted patient had postoperative fever and methicillin-resistant *Staphylococcus aureus* (MRSA) was detected from the central venous catheter and haemoculture. In this case antibiotics were applied over the six weeks. One patient had an incisional hernia in the port nine months after the first operation, which was treated under local anaesthesia.

Median operating time was 238 minutes (range, 150 to 360 minutes), with a median clamp time of 52 minutes (range, 25 to 120 minutes). Median anastomosis time was 27 minutes

(range, 12 to 60 minutes). Median blood loss was 420 mL (range, 50 to 1500 mL), median intensive care unit (ICU) stay was 1.7 days (range, 1 to 5 days), median ventilator support was 6 hours (0 to 48 hours), and median hospital stay was 5.2 days (range, 4 to 10 days). Nearly all patients began a liquid diet 1 day after surgery and a solid diet after 2.5 days.

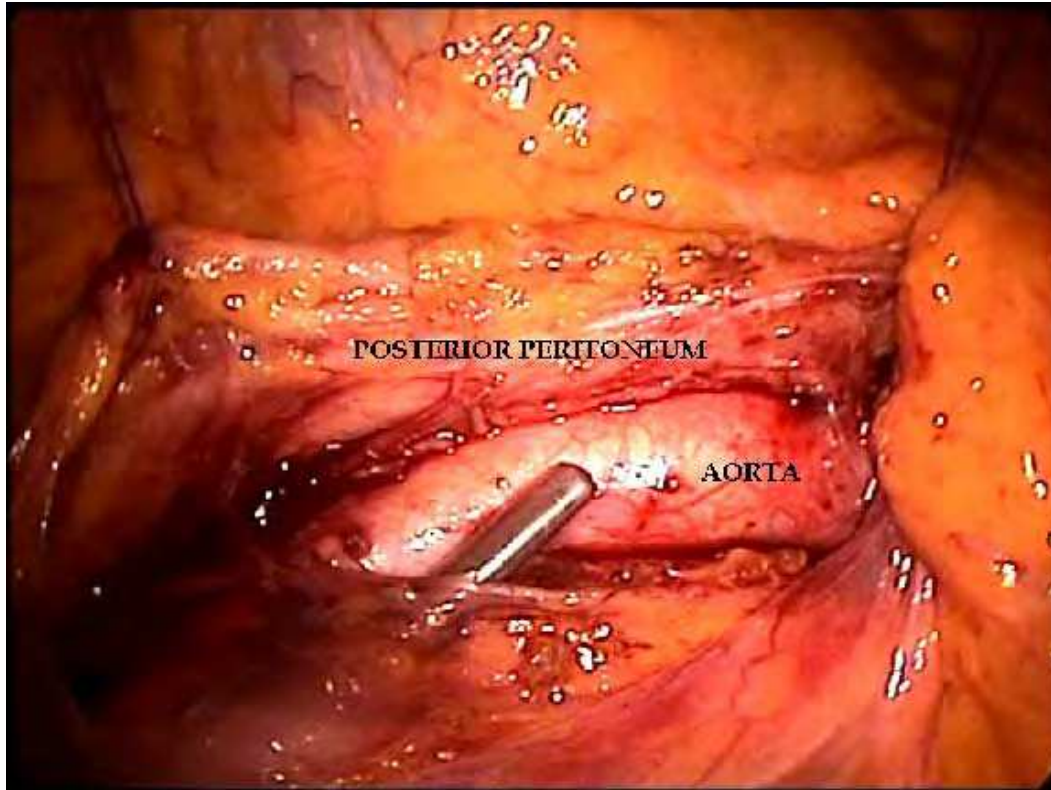


Figure 9. Fixed posterior peritoneum - perioperative view

4. The Future of Robotic Vascular Surgery

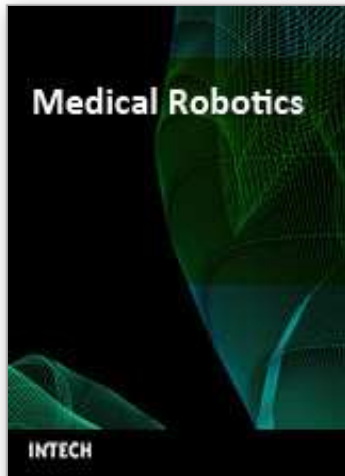Robot-assisted surgery was first introduced in cardiac surgery. Although the da Vinci system has been used by a variety of disciplines for laparoscopic procedures, including cholecystectomies, mitral valve repairs, radical prostatectomies, reversal of tubal ligations, and many gastrointestinal surgeries, nephrectomies, and kidney transplantations, the use of robots in vascular surgery is still relatively unique.

In the view of Dr. Petr Štádler, robot-assisted vascular procedures represent a modality that has a great future. Major benefits can be expected from their introduction into hybrid procedures, primarily on the abdominal and thoracic aorta. In robotic vascular surgery, Na Homolce Hospital in Prague is ranked among the world-class centres that are intensively involved in cutting-edge technology in the field of vascular surgery. The patients are the first to profit from these minimally invasive procedures. On the other hand, it is obviously necessary to underline the economic cost of this new technology and the need for accurate indications. The number of robotic systems established throughout the world must also be calculated in order to ensure that they are used to maximum effect. We hope that in the future robotic procedures will be less financially burdensome and that, given the funds saved in post-operative care and the low numbers of demanding complications requiring treatment, these new methods will prove to be economically profitable.

Because robot-assisted aortoiliac procedures have to be combined with conventional laparoscopic surgery, previous experience of conventional laparoscopic vascular surgery is very important. By combining robotic technology with surgical skills, the da Vinci Surgical System can allow the performance of more precise and more types of minimally invasive procedures in vascular surgery.

5. References

- Dion, Y. M.; Gracia, C. R. & Demalsy, J. C. (1996). Laparoscopic aortic surgery. *Journal of vascular surgery*, Vol. 23, No. 3, (539), ISSN 0741-5214.
- Dion, Y. M.; Gracia, C. R.; Estakhri, M.; Demalsy, J. C.; Douville, Y.; Piccinini, E. et al. (1998). Totally laparoscopic aortobifemoral bypass: A review of 10 patients. *Surgical laparoscopy & endoscopy*, Vol. 8, No. 3, (165-170), ISSN 1051-7200.
- Marescaux, J.; Smith, M. K.; Folscher, D. et al. (2001). Telerobotic laparoscopic cholecystectomy: Initial clinical experience with 25 patients. *Annals of surgery*, Vol. 234, No. 1, (1-7), ISSN 0003-4932.
- Nio, D.; Diks, J.; Linsen, M. A. M.; Cuesta, M. A.; Gracia, C.; Rauwerda, J. A. & Wisselink, W. (2005). Robot-assisted laparoscopic aortobifemoral bypass for aortoiliac occlusive disease: Early clinical experience. *European journal of vascular and endovascular surgery*, Vol. 29, No. 6, (586-590), ISSN 1078-5884.
- O'Toole, R. V.; Playter, R. R.; Krummel, T. M.; Blank, W. C.; Cornelius, N. H.; Roberts, W. R.; Bell, W. J. & Raibert, M. (1999). Measuring and developing suturing technique with a virtual reality surgical simulator. *Journal of the American College of Surgeons*, Vol. 189, No. 1, (114-127), ISSN 1072-7515.
- Štádlér, P.; Šebesta, P.; Vitásek, P.; Matouš, P. & El Samman, K. (2006, a). A modified technique of transperitoneal direct approach for totally laparoscopic aortoiliac surgery. *European journal of vascular and endovascular surgery*, Vol. 32, No. 5, (266-269), ISSN 1078-5884.
- Štádlér, P.; Matouš, P.; Vitásek, P. & Špaček M. (2006, b). Robot-assisted aortoiliac reconstruction: A review of 30 cases. *Journal of vascular surgery*, Vol. 44, No. 5, (915-919), ISSN 0741-5214.
- Talamini, M. A.; Chapman, S.; Horgan, S. et al. (2003). A prospective analysis of 211 robotic-assisted surgical procedures. *Surgical endoscopy*, Vol. 17, No. 10, (1521-1524), ISSN 0930-2794.
- Wisselink, W.; Cuesta, M. A.; Gracia, C. & Rauwerda JA. (2002). Robot-assisted laparoscopic aortobifemoral bypass for aortoiliac occlusive disease: A report of two cases. *Journal of vascular surgery*, Vol., 36, No. 5, (1079-1082), ISSN 0741-5214.



Medical Robotics

Edited by Vanja Bozovic

ISBN 978-3-902613-18-9

Hard cover, 526 pages

Publisher I-Tech Education and Publishing

Published online 01, January, 2008

Published in print edition January, 2008

The first generation of surgical robots are already being installed in a number of operating rooms around the world. Robotics is being introduced to medicine because it allows for unprecedented control and precision of surgical instruments in minimally invasive procedures. So far, robots have been used to position an endoscope, perform gallbladder surgery and correct gastroesophageal reflux and heartburn. The ultimate goal of the robotic surgery field is to design a robot that can be used to perform closed-chest, beating-heart surgery. The use of robotics in surgery will expand over the next decades without any doubt. Minimally Invasive Surgery (MIS) is a revolutionary approach in surgery. In MIS, the operation is performed with instruments and viewing equipment inserted into the body through small incisions created by the surgeon, in contrast to open surgery with large incisions. This minimizes surgical trauma and damage to healthy tissue, resulting in shorter patient recovery time. The aim of this book is to provide an overview of the state-of-art, to present new ideas, original results and practical experiences in this expanding area. Nevertheless, many chapters in the book concern advanced research on this growing area. The book provides critical analysis of clinical trials, assessment of the benefits and risks of the application of these technologies. This book is certainly a small sample of the research activity on Medical Robotics going on around the globe as you read it, but it surely covers a good deal of what has been done in the field recently, and as such it works as a valuable source for researchers interested in the involved subjects, whether they are currently “medical roboticists” or not.

How to reference

In order to correctly reference this scholarly work, feel free to copy and paste the following:

Petr Stadler (2008). Robot Attack on Vascular Surgery, Medical Robotics, Vanja Bozovic (Ed.), ISBN: 978-3-902613-18-9, InTech, Available from:

http://www.intechopen.com/books/medical_robotics/robot_attack_on_vascular_surgery

INTECH
open science | open minds

InTech Europe

University Campus STeP Ri
Slavka Krautzeka 83/A
51000 Rijeka, Croatia
Phone: +385 (51) 770 447

InTech China

Unit 405, Office Block, Hotel Equatorial Shanghai
No.65, Yan An Road (West), Shanghai, 200040, China
中国上海市延安西路65号上海国际贵都大饭店办公楼405单元
Phone: +86-21-62489820

www.intechopen.com

Fax: +385 (51) 686 166
www.intechopen.com

Fax: +86-21-62489821

IntechOpen

IntechOpen

© 2008 The Author(s). Licensee IntechOpen. This chapter is distributed under the terms of the [Creative Commons Attribution-NonCommercial-ShareAlike-3.0 License](https://creativecommons.org/licenses/by-nc-sa/3.0/), which permits use, distribution and reproduction for non-commercial purposes, provided the original is properly cited and derivative works building on this content are distributed under the same license.

IntechOpen

IntechOpen