

We are IntechOpen, the world's leading publisher of Open Access books Built by scientists, for scientists

4,800

Open access books available

122,000

International authors and editors

135M

Downloads

Our authors are among the

154

Countries delivered to

TOP 1%

most cited scientists

12.2%

Contributors from top 500 universities



WEB OF SCIENCE™

Selection of our books indexed in the Book Citation Index
in Web of Science™ Core Collection (BKCI)

Interested in publishing with us?
Contact book.department@intechopen.com

Numbers displayed above are based on latest data collected.

For more information visit www.intechopen.com



Nerve Sparing Axillary Dissection using the da Vinci Surgical System

Susan M L Lim, Cheng-Kiong Kum and Foong-Lian Lam
*Centre for Breast Screening and Surgery, Centre for Robotic Surgery
 Singapore*

1. Abstract

We would like to describe a new minimally invasive method of axillary dissection via a periareolar incision and an 8mm incision in the axilla using the da Vinci Surgical System. The ten times (10X) magnification and three dimension (3D) image, together with the versatility and precision of the robotic telemanipulators has enabled us to perform nerve-sparing axillary dissection in 14 patients with carcinoma of the breast with lymph node metastases undergoing segmental mastectomy or total mastectomy and requiring level I and II axillary dissection. The time for the robotic axillary dissection ranged from 25 to 110 minutes with an average of 53 minutes. The average number of lymph nodes retrieved was 18 (range from 8 to 28). Postoperatively all patients recovered well. The robotic system can enhance the surgeon's ability by providing a high-definition, magnified, three-dimensional view of the operative field, intuitively controlled articulating instruments, and elimination of tremors, and has potential benefits for the patient.

2. Introduction

For women with breast cancer, the status of axillary node involvement is the single best predictor of survival, and important treatment decisions are based on this information. (Bland et al., & Maibenc et al., 1999) While much progress and innovation has been made in the surgical approach to the breast (Veronesi et al., 1994), there has been less progress made in the surgical approach to the axilla. For women with breast cancer, the presence of metastatic disease in the regional basin significantly decreases five-year survival. (Schottenfeid et al., 1976) A level I and II axillary dissection is recommended for staging purposes as well as for local control. (Recht et al., & Houlihan, 1995) However, axillary dissection has been associated with significant morbidity which includes pain, paresthesia, swelling, shoulder dysfunction, and lymphoedema. Multiple reports have shown that axillary dissection was associated with paresthesia (60%), pain (45%), weakness (40%), swelling (26%), stiffness (12%) and lymphoedema in up to 43% of patients. (Taylor & Armer, 2004) The logical step in the advancement of breast cancer surgery would be to decrease the morbidity of the axillary dissection without necessarily sacrificing on lymph node retrieval for accurate staging. Less invasive treatment modalities have been evaluated in order to lower the morbidity of axillary lymph node dissection. These have included the sentinel node biopsy (Veronesi et al., 2003) (SLNB) and endoscopic axillary lymph node dissection. (Tsangaris et al., 1999; Paepke et al., 2003; Kuehn et al., 2001; Brunt et al., 1998; Avrahami et al., 1998) SLNB

Source: Medical Robotics, Book edited by Vanja Bozovic, ISBN 978-3-902613-18-9, pp.526, I-Tech Education and Publishing, Vienna, Austria

in particular is rapidly being accepted by many centres as a low morbidity method of identifying possible spread to the axilla. Since March 2003, we performed minimal access axillary dissection in patients with breast cancer, and noted significant patient benefits in terms of less pain and paresthesia, and improved shoulder mobility (unpublished results). However, the procedure itself was cumbersome and non-ergonomic, given the reduced range of motion and instrument dexterity of the standard laparoscopic instrument, and 2-dimensional view of the operative field. In recent years, there has been a rapid growth of surgical procedures performed using the da Vinci Surgical System (Intuitive Surgical, Sunnyvale, CA, USA). (Hazy & Meivin., 2004; Bodner et al., 2004; Undre et al., 2004; Menon et al., 2003) The system uses a master-slave robot concept where the surgeon controls telemanipulators to perform the operation, hence the commonly used term 'robotic surgery'. The advantages of robotic surgery using this system include 10X magnification, three-dimensional vision, elimination of tremor, use of instruments with seven degrees of freedom (d.o.f.) of movement, and the ability of the surgeon to perform the procedure comfortably seated with armrests for support. Procedures demanding superior visualization or requiring complex reconstruction obtain the greatest benefit from robotics over conventional laparoscopy. This is our report of 14 patients with carcinoma of the breast and lymph node metastases who underwent a level I and II axillary dissection using the da Vinci Surgical System. The objective was to develop a technique of axillary dissection which could visualize the cutaneous nerves and lymphatics in the axilla, and aid in fine dissection with preservation of the nerves.

3. Patients and Methods

Between 19 November 2004 and 15 November 2006, 14 robotic axillary dissections using the da Vinci Surgical System (Intuitive Surgical, Sunnyvale, CA, USA) were successfully performed on 14 patients with carcinoma of the breast and lymph node metastases who underwent segmental mastectomy or total mastectomy. All patients were comprehensively informed about the technique, and signed informed consent. The age range was 32-74 years. The tumour size ranged from 1.5 cm to 8.0 cm. The tumour location was in the upper, outer quadrant (6 patients), upper inner quadrant (2 patients), lower outer quadrant (1 patient), upper half of breast (3 patients) and lateral half of breast (1 patient). One patient only had axillary dissection as her mastectomy had been performed at another medical facility. General anaesthesia with endotracheal intubation was employed and the patient was positioned supine with the arm abducted to 120 degrees. A large soft roll was positioned under the side of the patient to elevate that side from the table 30 degrees. Segmental excision of the tumour was first performed through a periareolar incision. Following the excision of the tumour with clear margins, the breast cavity was washed with saline, and hemostasis achieved prior to commencement of the axillary dissection. The axillary space was created as follows: the clavipectoral-axillary fascia was gently opened by blunt dissection and a "closed-open" scissors introduced gently into the axillary space through the opening. This opening provided the working space and access to the axilla for the endoscope and instrument arm of the surgical system. The surgical cart of the da Vinci Surgical System containing the camera arm and the left and right instrument arms, was positioned over the shoulder. A zero degree 3D endoscope (InSite™ Vision System, Intuitive Surgical, Sunnyvale, USA) was placed through the periareolar incision and targeted toward the axillary vein. A bi-polar coagulating forceps, placed in the left arm of the robot, was also positioned through the same incision. A cautery hook or cautery spade, connected to

unipolar diathermy was placed in the contralateral arm of the robot and inserted through an 8mm incision in the axilla. A self-retaining retractor was placed in the incision to maintain the axillary space. In the 7 cases of total mastectomy procedures, the access of the robotic instruments and camera was through the mastectomy incision (circumareolar, skin sparing). Once the axillary space was achieved with good visuals, axillary dissection was performed. Once all three nerves (intercostobrachio-cutaneous, long thoracic, thoracodorsal) had been identified and dissected free from the axillary contents, the axillary fat pad was dissected in a lateral and inferior direction to the anterior border of the latissimus dorsi muscle, and divided. Hemostasis was achieved with uni- or bi-polar coagulation. The specimen and lymph nodes contained within were extracted through the breast incision and submitted to pathology. The breast incision was closed with 4/0 vicryl and steristrips. No surgical drainage was required for the axilla. The stab incision in the axilla was closed with steristrips. All patients were admitted following surgery. For patients with tumour in the lateral quadrants of the breast, oncoplastic reconstruction of the lumpectomy defect was performed using a flap of fatty tissue overlying the serratus anterior muscle, supplied by a branch of the thoracodorsal artery which was identified and preserved. (Denewer & Farouk ,2007) This is a very useful thin fascial flap for distant coverage. The thoracodorsal artery is identified proximally, and branches coursing medially toward the serratus are identified and preserved. The fascial flap to be elevated is then outlined and incised. This is a very thin flap that is dissected off the underlying serratus anterior muscle. Dissection continues from distal to proximal and includes the branches of the thoracodorsal artery. Branches extending into the serratus muscle are cauterized with the bipolar electrocoagulation unit. Care should be taken to preserve the long thoracic nerve. The fascia is dissected away, leaving the nerve intact (see figure 1).

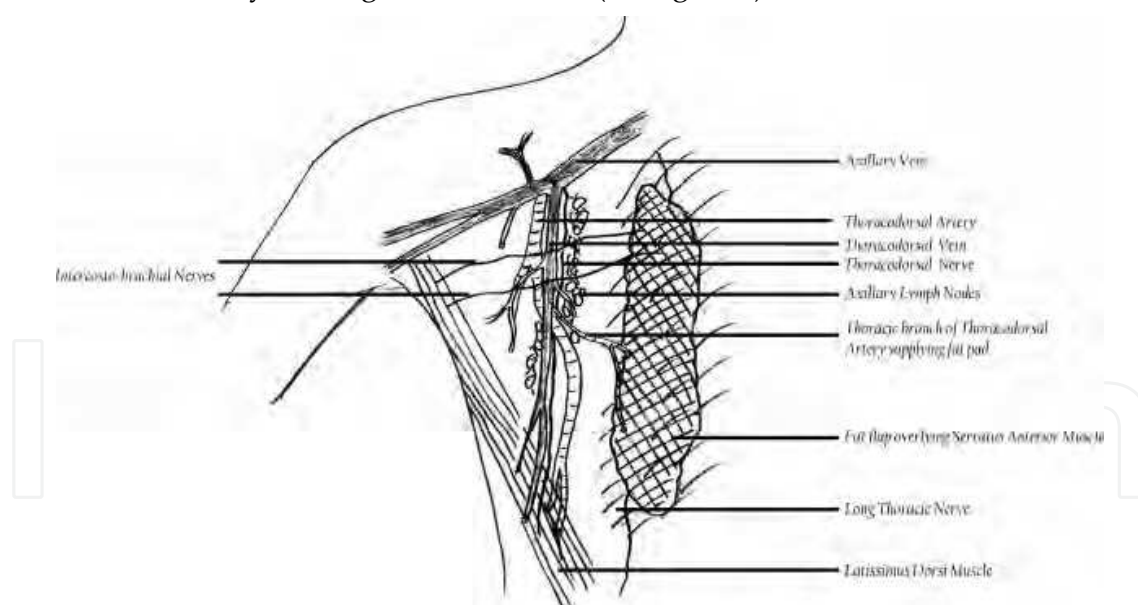


Figure 1. Contents of Axilla

4. Results

14 patients underwent robotic axillary dissection following segmental mastectomy or total mastectomy for carcinoma of the breast. The set up times for the da Vinci system ranged from 3 to 20 minutes, mean operative duration for the robotic axillary dissection was 53

minutes (range from 20 to 110 minutes); and the mean total operative time for both the breast and axillary surgery (measured from the time of the initial skin incision to the last subcutaneous stitch was completed) was 149 minutes (range 105-240 minutes). There were no intraoperative technical failures of the da Vinci telemanipulator system. Blood loss was negligible in all cases. In patients who had segmental mastectomy performed (6 patients), the margins of resection of the breast tissue were free of tumour in all patients. The average number of lymph nodes removed was 18 (range from 8 to 28). In those patients who underwent oncoplastic reconstruction using the flap of fatty tissue overlying the serratus anterior muscle, the branch of the thoracodorsal artery was easily identified in all cases and preserved. All patients were hospitalized following surgery. There were no intra- or post-operative complications such as hematoma, wound infection, or injury to nerves and vessels. Out of the 14 patients operated upon, 2 had no seroma formation post-operatively. 8 patients had seroma formation for 2 weeks and 4 patients for one month documented on ultrasound. In all these patients, the seroma resolved over time. Axillary pain and paresthesia of upper arm were also noted to be minimal, with the major advantage, often realized by the patient and surgeon immediately after surgery, being the improved mobility of the operated arm. The patients reported full range of movement of the upper limb without any stiffness or pain. The patients who had the oncoplastic reconstruction performed using the flap of fatty tissue overlying the serratus anterior muscle supplied by the branch of the thoracodorsal artery had excellent cosmesis post-operatively.

5. Discussion

Improved surgical techniques in breast cancer surgery have evolved over the years, which include skin and areolar-sparing mastectomy, segmental mastectomy, oncoplastic breast procedures, and reconstructive options. (Simmons et al., 2003; Gerber et al., 2003) This increased use of breast-conserving therapy for treatment of breast cancer has nearly eliminated the major morbidity of loss of the breast. The present focus of postoperative morbidity has shifted to the axillary dissection, a procedure which for many women has become the major cause of long-term morbidity after local therapy for breast cancer. (Harris et al., 1999) In the surgical approach to the axilla however, apart from the sentinel node biopsy, there have been few innovations in techniques to spare the common complications of an axillary dissection, which range from seroma or hematoma formation to injury to the nerves that course through the axilla. Injury to the long thoracic nerve may result in a winged scapula or palsy of the serratus anterior muscle and occurs in approximately 10% of cases, (Bennion & Love, 1997) while injury to the thoracodorsal nerve will lead to weakness of the latissimus dorsi muscle. Injury to the intercostobrachial nerve may cause permanent numbness in the lateral axilla and medial portion of the upper arm. These injuries, while distressing to patients, are probably underestimated, as they are not life-threatening and do not require hospitalization. (Ivens et al., 1992) In this report, we have shown that axillary lymph node dissection with the da Vinci Surgical System is a precise, gentle, and safe alternative to lymphadenectomy performed via a standard axillary incision. The authors embarked on this technique after finding that the robotic approach yielded better precision and visualisation that could result in less morbidity following axillary dissection. This ergonomic master-slave system offered three-dimensional visualization, wristed instrumentation, intuitive finger-controlled movements and a comfortable seated position for the surgeon. While the increase in operating time reflects the initial small learning curve, the advantages of dissection using telemanipulators were striking to the surgeon and appeared to

have significant positive impact on patient outcome. Surgeon advantages included a 3D view of the axilla, 10X magnification, and an ergonomical operating position with seven d.o.f. of movement of the instruments with elimination of tremor. A potential disadvantage of this technology is the added cost, and the lack of tactile sensation, but three-dimensional visualization compensated for this handicap. Patient outcome may be improved as the enhanced view facilitates identification and preservation of the nerves in the axilla; the long thoracic nerve on the medial wall, thoracodorsal nerve on the posterior wall, and especially the intercostobrachial nerves which course through the axilla. In addition, lymph nodes and lymphatic channels are better visualized, adding to the completeness of the lymphatic dissection. The reason for minimal seroma is probably due to the better visualisation and more meticulous and precise dissection using a 'no-touch' technique i.e. the tissues were only handled with the robotic instruments. The aesthetic result was also better as a separate axilla incision was avoided. The 10X magnification also enabled the fat overlying the serratus anterior muscle to be harvested as a flap with its own blood supply from the thoracic branch of the thoracodorsal artery. The harvested fat flap allows for immediate reconstruction of the segmental mastectomy defect in patients with tumours located in the lateral quadrants of the breast. Sentinel lymph node biopsy remains a good management option for patients with early breast cancer, with low morbidity. We believe that robotic axillary dissection is a useful complement to this technique when there is an oncological requirement for a complete axillary dissection. There are distinct advantages with robotic axillary dissection and this could be added to the repertoire of procedures in a hospital that has purchased the robot for use in other types of surgery.

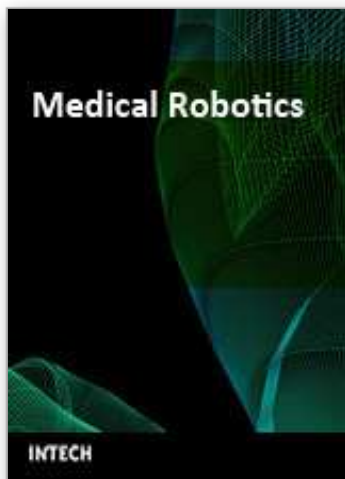6. Conclusion

Nerve-sparing axillary dissection with the da Vinci Surgical System is feasible and can be performed within the current oncological standards. Access to the axillary space is obtained through the initial incision for breast tumour removal and eliminates the necessity for a second main axillary incision. The three dimensional view, magnified 10X, and the robotic telemanipulators can enhance the surgeon's ability with better vision, intuitive instrument control and depth perception, and elimination of tremors, and can possibly reduce postoperative complications for the patient. We conclude that robotic axillary lymph node dissection can be safely and selectively introduced into a breast cancer surgery program.

7. References

- Armer J, Fu MR, Wainstock JM, Zagar E, Jacobs LK (2004): Lymphedema following breast cancer treatment, including sentinel lymph node biopsy. *Lymphology. Jun*; 37(2): 73-91.
- Avrahami R, Nudelman I, Watenberg S, Lando O, Hiss Y, Lelchuk S (1998): Minimally invasive surgery for axillary dissection. Cadaveric feasibility study. *Surg Endosc May*; 12(5):466-8.
- Bennion RS, Love SM (1997): Treatment of breast disease. In *Diagnosis of diseases of the breast. WB Saunders Company*; 521-45.
- Bland KI et al (1999): Axillary dissection in breast-conserving surgery for stage I and II breast cancer: a National Cancer Data Base study of patterns of omission and implications for survival. *JAm Coll Surg Jun*; 188(6):586 - 95.
- Bodner J, Wykypiel H, Wetscher G, Schmid T (2004): First experiences with the da Vinci operating robot in thoracic surgery. *Eur J Cardiothorac Surg. May*; 25(5): 844-51

- Brunt LM, Jones DB, Wu JS, Brunt EM, Radford DM (1998): Endoscopic axillary lymph node dissection: an experimental study in human cadavers. *J Am Coll Surg. Aug*; 187(2):158-63.
- Denewer A, Farouk O (2007): Can Nipple-sparing Mastectomy and Immediate Breast Reconstruction with Modified Extended Latissimus Dorsi Muscular Flap Improve the Cosmetic and Functional Outcome among Patients with Breast Carcinoma? *World J Surg; Jun*; 31(6):1169-1177
- Gerber B, Krause A, Reimer T, et al (2003): Skin-sparing mastectomy with conservation of the nipple-areola complex and autologous reconstruction is an oncologically safe procedure. *Ann Surg Jul*; 238(1):120-7.
- Giuliano AE, Jones RC, Brennan M, et al (1997): Sentinel lymphadenectomy in breast cancer. *Clin Oncol Jun*; 15(6):2345-2350.
- Harris JR, Lippman ME, Morrow M, et al (1999): Diseases of the breast. 2nd ed., Baltimore, *Lippincott Williams & Wilkens*, p 403-406,1999.
- Hazey JW, Melvin WS (2004): Robot-assisted general surgery. *Semin Laparosc Surg. Jun*; 11(2): 107-12
- Hidalgo DA (1998): Aesthetic refinement in breast reconstruction: complete skin-sparing mastectomy with autogenous tissue transfer. *Plast Reconstr Surg Jul*;102(1):63-7.
- Ivens D, Hoe AL, Podd TJ, et al (1992): Assessment of morbidity from complete axillary dissection. *Br J Cancer Jul*; 66(1):136-8.
- Kuehn T, Santjohanser C, Grab D, Klauss W, Koretz K, Kreienberg R (2001): Endoscopic axillary surgery in breast cancer. *Br J Surg May*; 88(5):698-703.
- Maibenco DC et al (1999): Axillary lymph node metastases associated with small invasive breast carcinomas. *Cancer Apr 1*; 85(7):1530 -6.
- Menon M, Hemal AK, Tewari A, Shrivastava A, Shoma AM, El-Tabey NA, Shaaban A, Abol-Enein H, Ghoneim MA (2003): Nerve-sparing robot-assisted radical cystoprostatectomy and urinary diversion. *BJU Int Aug*; 92(3):232-6.
- Paepke S, Schwarz-Boeger U, Kiechle M, Jacobs VR (2003): Axillary dissection with access minimized: a new technique for lymph node dissection in conservative surgery for breast cancer. *Int J Fertil Womens Med Sep Oct*; 48(5): 232-237.
- Recht A, Houlihan MJ (1995): Axillary lymph nodes and breast cancer: a review. *Cancer Nov 1*; 76 (9):1491-512
- Schottenfeld D et al (1976): Ten year results of the treatment of primary operable breast cancer. *Cancer 1976*; 38:1001-7. Recht A, Houlihan MJ: Axillary lymph nodes and breast cancer: a review. *Cancer Aug*; 76(2):1491-1512.
- Simmons RM, Hollenbeck ST, LaTrenta GS (2003): Areola-sparing mastectomy with immediate breast reconstruction. *Ann Plast Surg Dec*; 51(6):547-1.
- Taylor KO (2004): Morbidity associated with axillary surgery for breast cancer. *ANZ J Surg. May*; 74(5): 314-7.
- Tsangaris TN, Trad K, Brody FJ, et al (1999): Endoscopic axillary exploration and sentinel lymphadenectomy. *Surg Endosc Jan*; 13(1):43-47.
- Undre S, Munz Y, Moothy K, Martin S, rockall T, Vale J, Darzi A (2004): Robot-assisted laparoscopic adrenalectomy: preliminary UK results. *BJU Int. Feb*; 93 (3): 357-9
- Veronesi U et al (1994): Conservative approaches for the management of stage I/II carcinoma of the breast: Milan Cancer Institute trials. *World J Surg Jan-Feb*; 18(1):70-5.
- Veronesi U, Paganelli G, Viale G, et al (2003): A randomized comparison of sentinel node biopsy with routine axillary dissection in breast cancer. *N Engl J Med Aug 7*, 349(6):546-53.



Medical Robotics

Edited by Vanja Bozovic

ISBN 978-3-902613-18-9

Hard cover, 526 pages

Publisher I-Tech Education and Publishing

Published online 01, January, 2008

Published in print edition January, 2008

The first generation of surgical robots are already being installed in a number of operating rooms around the world. Robotics is being introduced to medicine because it allows for unprecedented control and precision of surgical instruments in minimally invasive procedures. So far, robots have been used to position an endoscope, perform gallbladder surgery and correct gastroesophageal reflux and heartburn. The ultimate goal of the robotic surgery field is to design a robot that can be used to perform closed-chest, beating-heart surgery. The use of robotics in surgery will expand over the next decades without any doubt. Minimally Invasive Surgery (MIS) is a revolutionary approach in surgery. In MIS, the operation is performed with instruments and viewing equipment inserted into the body through small incisions created by the surgeon, in contrast to open surgery with large incisions. This minimizes surgical trauma and damage to healthy tissue, resulting in shorter patient recovery time. The aim of this book is to provide an overview of the state-of-art, to present new ideas, original results and practical experiences in this expanding area. Nevertheless, many chapters in the book concern advanced research on this growing area. The book provides critical analysis of clinical trials, assessment of the benefits and risks of the application of these technologies. This book is certainly a small sample of the research activity on Medical Robotics going on around the globe as you read it, but it surely covers a good deal of what has been done in the field recently, and as such it works as a valuable source for researchers interested in the involved subjects, whether they are currently “medical roboticists” or not.

How to reference

In order to correctly reference this scholarly work, feel free to copy and paste the following:

Susan M. L. Lim, Cheng-Kiong Kum and Foong-Lian Lam (2008). Nerve Sparing Axillary Dissection Using the da Vinci Surgical System, Medical Robotics, Vanja Bozovic (Ed.), ISBN: 978-3-902613-18-9, InTech, Available from:

http://www.intechopen.com/books/medical_robotics/nerve_sparing_axillary_dissection_using_the_da_vinci_surgical_system

INTECH
open science | open minds

InTech Europe

University Campus STeP Ri
Slavka Krautzeka 83/A

InTech China

Unit 405, Office Block, Hotel Equatorial Shanghai
No.65, Yan An Road (West), Shanghai, 200040, China

51000 Rijeka, Croatia
Phone: +385 (51) 770 447
Fax: +385 (51) 686 166
www.intechopen.com

中国上海市延安西路65号上海国际贵都大饭店办公楼405单元
Phone: +86-21-62489820
Fax: +86-21-62489821

IntechOpen

IntechOpen

© 2008 The Author(s). Licensee IntechOpen. This chapter is distributed under the terms of the [Creative Commons Attribution-NonCommercial-ShareAlike-3.0 License](https://creativecommons.org/licenses/by-nc-sa/3.0/), which permits use, distribution and reproduction for non-commercial purposes, provided the original is properly cited and derivative works building on this content are distributed under the same license.

IntechOpen

IntechOpen