

False vocal cord perforation with abscess treated by negative pressure wound therapy

SAGE Open Medical Case Reports
Volume 8: 1–5
© The Author(s) 2020
Article reuse guidelines:
sagepub.com/journals-permissions
DOI: 10.1177/2050313X20915415
journals.sagepub.com/home/sco



Seiichiro Makihara¹ , Shin Kariya² , Tomoyuki Naito¹,
Kensuke Uraguchi³, Junya Matsumoto¹, Yohei Noda²,
Mitsuhiro Okano^{2,4} and Kazunori Nishizaki²

Abstract

Perforation of the larynx is very rare but may result in severe airway complications that include pneumothorax, pneumonia, mediastinitis, and retropharyngeal abscess. If conservative treatment fails, aggressive treatments including reconstructive surgery with pedicle flap are considered. Negative pressure wound therapy has been used for large skin defects, necrotizing fasciitis, pharyngocutaneous fistula, stoma dehiscence, osteoradionecrosis of the mandible, chyle fistula, flap failure, and lymphangioma in the field of head and neck surgery. We report a case of false vocal cord perforation with abscess successfully treated by negative pressure wound therapy after abscess treatment. The result suggests that negative pressure wound therapy can be an alternative or adjunctive approach for larynx perforation when the perforation is difficult to close after conservative therapy.

Keywords

Negative pressure wound therapy, false vocal cord perforation, deep neck abscess, larynx perforation, head and neck fistula

Date received: 12 April 2019; accepted: 26 February 2020

Introduction

Perforation of the larynx is very rare and happens after electrical burn,¹ cancer treatment,² trauma,³ or other such incidents. Yii et al.⁴ reported a case of life-threatening necrotizing fasciitis of the neck with acute pharyngeal perforation following a parapharyngeal abscess caused by tonsillitis, but pharyngeal perforation caused by a deep neck abscess is generally very rare. Furthermore, no perforation of the larynx caused by deep neck abscess has ever been reported.

Perforation of the upper aerodigestive system may result in severe airway complications that include pneumothorax, pneumonia, mediastinitis, and retropharyngeal abscess,⁵ which is why management of the perforation is very important. If conservative treatment fails, aggressive treatments including reconstructive surgery with pedicle flap are considered.

Negative pressure wound therapy (NPWT) has been widely used on various complicated wounds, such as diabetic foot ulcers, open abdomen, pressure ulcers, open fractures, sterna wounds, grafts, and flaps in recent history.^{6,7} Head and neck wounds including pharyngocutaneous fistula are also known to be treated by NPWT.

We report a case of false vocal cord perforation with abscess successfully treated by NPWT after abscess treatment.

Case report

A 53-year-old male complained of a sore throat and visited a primary care doctor. Although antibiotics were prescribed, the sore throat was worse 1 day later. He denied ingesting

¹Department of Otolaryngology-Head & Neck Surgery, Kagawa Rosai Hospital, Kagawa, Japan

²Department of Otolaryngology-Head & Neck Surgery, Graduate School of Medicine, Dentistry and Pharmaceutical Sciences, Okayama University, Okayama, Japan

³Department of Otolaryngology, Kochi Health Sciences Center, Kochi, Japan

⁴Department of Otorhinolaryngology, School of Medicine, International University of Health and Welfare, Narita, Japan

Corresponding Author:

Shin Kariya, Department of Otolaryngology-Head & Neck Surgery, Graduate School of Medicine, Dentistry and Pharmaceutical Sciences, Okayama University, 2-5-1 Shikata-cho, Kita-ku, Okayama 700-8558, Japan.
Email: skariya@cc.okayama-u.ac.jp



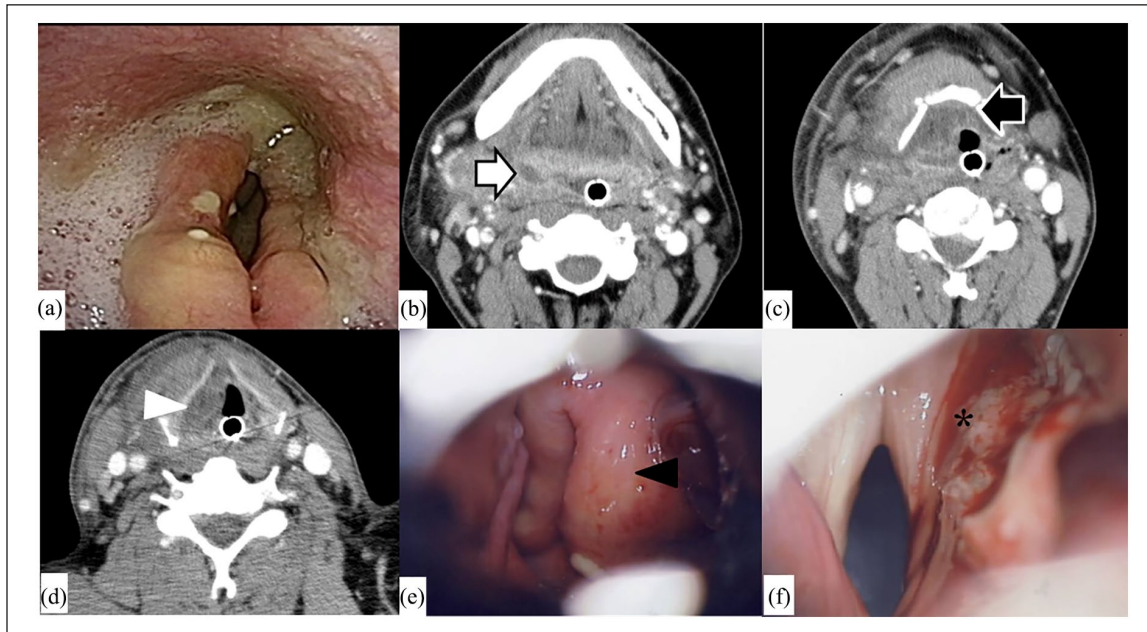


Figure 1. (a) Fibroscopic examination before the first surgery, showing swelling of the epiglottis and arytenoid region on both sides and pooling of saliva from the posterior part of the tongue to both sides of the piriform sinus. (b)–(d) Contrast-enhanced computed tomography (CT) before the first surgery, showing a low-density area (LDA) that was thought as abscess formation in the caudal region of the right tonsil, right false vocal cord, epiglottis, and right arytenoid region ((b) white arrow: LDA in the caudal region of right tonsil, (c) black arrow: LDA from epiglottis to right arytenoid region, and (d) white arrowhead: LDA in right false vocal cord). (e) and (f) Direct laryngoscopy during the first surgery, showing an abscessed epiglottis, especially in the right side ((e) black arrowhead), and a necrotic region in the right false vocal cord ((f) asterisk) at the first surgery.

any foreign body as well as any trauma and dental discomfort. He was admitted to the hospital of the primary care doctor and received ceftriaxone intravenously. He had a medical history of diabetes, diabetic renal failure requiring dialysis, and hypertension.

He was transported to our hospital by ambulance 2 days after admission to the hospital of the primary care doctor, due to dyspnea, severe sore throat, and difficulty swallowing. The initial laboratory data revealed white blood cell count, C-reactive protein (CRP) concentration, hemoglobin, blood urea nitrogen, and creatinine at 16,500/ μL , 29.9 mg/dL, 9.9 g/dL, 113 mg/dL, and 15.11 mg/dL, respectively. A flexible direct laryngoscopic examination showed swelling of the epiglottis and arytenoid region on both sides and pooling of saliva from the posterior part of the tongue to both sides of the piriform sinus (Figure 1(a)). There was no paralysis of the vocal cord. To avoid the danger of suffocation, an anesthesiologist intubated his trachea.

Contrast-enhanced computed tomography (CT) revealed a low-density area (LDA) that was thought as abscess formation in the caudal region of the right tonsil, right false vocal cord, epiglottis, and right arytenoid region (Figure 1(b)–(d)). Emergency surgery was planned at the diagnosis of epiglottic abscess and peritonsillar abscess. The surgery was performed under general anesthesia. An inferior tracheotomy was performed on the patient, who then underwent an abscess tonsillectomy and drainage of the abscess in the

epiglottis and right arytenoid region under direct laryngoscopy (Figure 1(e)). The abscess had a greenish color and foul odor, and the pus was cultured. Necrosis of the right false vocal cord was identified during direct laryngoscopy (Figure 1(f)). After the surgery, he was taken to the intensive care unit, put on a mechanical ventilator, and administered intravenous broad-spectrum antibiotics. The culture results showed *Streptococcus intermedius* and *Klebsiella pneumoniae*. The results of a biopsy of tissue from the right false vocal cord, which was thought to have necrosis, showed necrotic tissue.

On the fourth day after admission, the patient's vital signs were stable, and the CRP concentration had gradually decreased. He also underwent follow-up contrast-enhanced CT. In CT images, there was an LDA that was thought as abscess formation under the right anterior neck region (Figure 2(a)–(d)). The necrotic region of the right false vocal cord also had an LDA, and it was difficult to determine differences between the necrosis and abscess. The abscess was drained through a transverse incision between the right posterior margin of the sternocleidomastoid muscle and the lateral side of the hyoid bone, where, under direct laryngoscopy, the necrotic region of the right false vocal cord was debrided and finally a drainage tube was inserted. After the second surgery, saline irrigation in the wound was started (Figure 2(e)), and the CRP concentration continued to decrease gradually.

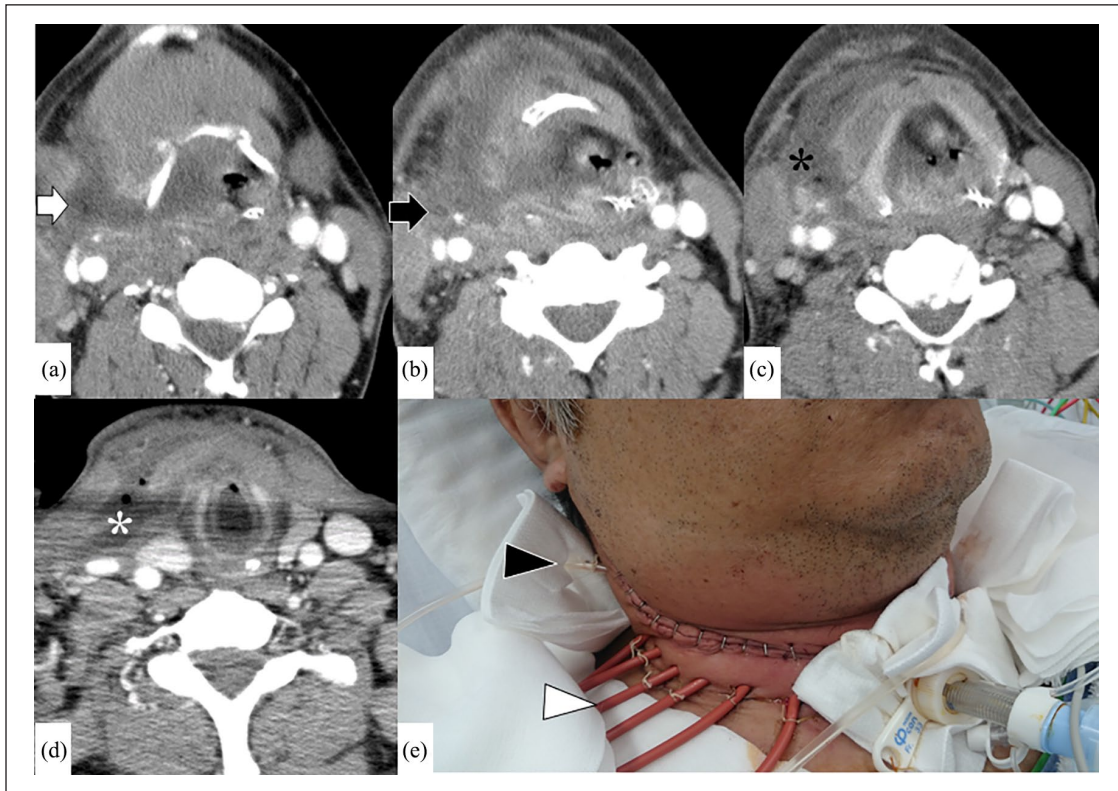


Figure 2. (a)–(d) Contrast-enhanced computed tomography (CT) before the second surgery, showing a low-density area (LDA) that was thought as abscess formation in the right anterior neck region (white arrow, black arrow, black asterisk, and white asterisk). (e) Right neck after the second surgery on the fourth day after admission (white arrowhead: tubes for saline irrigation; black arrowhead: silicon vacuum drain).

On the ninth day after admission, the patient underwent follow-up contrast-enhanced CT again, and the LDA that was in the necrotic region of the right false vocal cord remained in the CT images (Figure 3(a)–(c)). The LDA around the drainage tube which had a possibility of abscess remained too, and the abscess was drained again using the transverse incision from the previous surgery. A small abscess around the drainage tube was drained, and a perforation of about 1 cm to the right false vocal cord was found between the right carotid sheath and right lateral part of the thyroid cartilage. The perforation was confirmed under direct laryngoscopy by flushing colored water from the neck wound to the right false vocal cord (Figure 3(d) and (e)). Since it was difficult to perform the primary closure of the perforation site, we started to use NPWT for the intractable false vocal cord perforation. At the end of the surgery, V.A.C.® GranuFoam™ dressing (Kinetic Concepts, Inc., San Antonio, TX, USA) was applied. The V.A.C. dressing was joined to a vacuum pump (Figure 3(f)) to obtain a negative pressure of around 50 mmHg. The dressing was changed every 36–48 h.

On the 16th day after admission, the wound on the false vocal cord and the neck had granulation tissue (Figure 3(g)),

and the exudate fluid to the vacuum pump decreased; that is why the use of the V.A.C. dressing was ended.

On the 31st day after admission, the tracheal tube was removed, the patient started an oral diet, and the meal courses at the hospital were uneventful.

On the 39th day after admission, he had no difficulty swallowing and was discharged. The wound on the right false vocal cord gradually healed (Figure 3(h)) but had not yet completely epithelized by the end of 1 year after the discharge (Figure 3(i)), which is why outpatient follow-ups were still continuing.

Discussion

NPWT promotes wound healing by delivering negative pressure at the wound site through a patented dressing, which helps draw wound edges together, remove infectious materials, and actively promote granulation at the cellular level.⁸ Orgill and Bayer⁹ reviewed the most recent peer-reviewed literature investigating negative pressure therapy and categorized the mechanisms into five major physiologic categories: fluid removal, blood flow changes, microdeformation, macrodeformation, and maintenance of wound hemostasis.

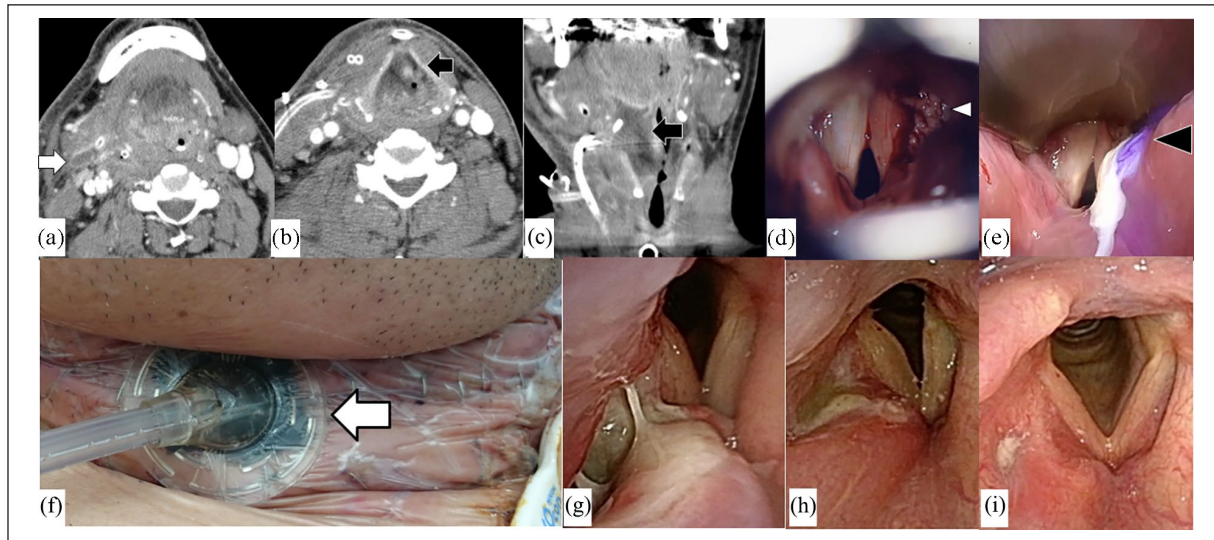


Figure 3. (a)–(c) Contrast-enhanced computed tomography (CT) before the third surgery, showing a low-density area (LDA) that was thought as abscess formation in the right anterior neck region ((a) white arrow) and as a necrotic region in the right false vocal cord ((b) and (c) black arrow). (d) and (e) Direct laryngoscopy during the third surgery, showing a necrotic region in the right false vocal cord ((d) white arrowhead), and the perforation was confirmed by flushing colored water from the neck wound to the right false vocal cord ((b) black arrowhead). (f) Right neck with the V.A.C. dressing (white arrow) after the third surgery. (g)–(i) Laryngoscopy gradually showing the granulated false vocal cord wound (pictures taken on specific days after admission: (g) 10th day, (h) 30th day, and (i) 210th day).

In addition, starting from 2010 in Japan, NPWT has been covered under national health insurance.

NPWT has been used not only for various complicated wounds, such as diabetic foot ulcers, open abdomen, pressure ulcers, open fractures, sterna wounds, grafts, and flaps, but also in the field of head and neck surgery for large skin defects, necrotizing fasciitis, pharyngocutaneous fistula, stoma dehiscence, osteoradionecrosis of the mandible, chyle fistula, flap failure, and lymphangioma.¹⁰

Peritonsillar abscess was reported as the most common deep neck infection in adolescents.¹¹ In these cases, it was thought that peritonsillar abscess spread in the potential spaces between the layers of deep cervical fascia. Deep neck infections require prompt treatment. Treatment of deep neck abscess consists of ensuring adequate ventilation by securing the airway, broad-spectrum antibiotics, eradicating the source of infection, and early surgical decompression or drainage if necessary.¹² Sealing up the wound area by NPWT can make infection worse, which is why the patient underwent abscess drainage and debridement of necrotic tissue first, and then we controlled infection and started to use NPWT. The NPWT dressing was changed every 36–48 h, and there was no exacerbation of the deep neck abscess. For inflammation wounds, it was reported that NPWT could be used safely by changing the dressing more often than every 48–72 h.⁶ Contrarily, other reports pointed out the possibility of inflammation wounds getting worse from the use of NPWT.^{13,14} If NPWT is used for an inflammation wound, abscess drainage and debridement of necrotic tissue should

be done in advance, and the condition of the inflammation wound should be observed carefully. If the inflammation worsens, we should consider additional debridement of necrotic tissue, NPWT dressing changes at a shorter interval, and saline irrigation in the wound.

In the laryngopharynx field, there is a possibility that leakage of saliva would prevent NPWT from continuously maintaining negative pressure. However, in this case, NPWT could continue to be used, and the adhesion of the wound resulted in a low amount of saliva drainage. Andrews et al.¹⁵ considered that the tissue at the fistula site would collapse due to the negative pressure, and that was why a vacuum-assisted closure system was a feasible treatment option for closing head and neck fistulas. A more standard treatment for laryngeal perforation or pharyngocutaneous fistula with abscess might include drainage of the abscess, debridement, packing the wound with iodoform or plain gauze, and fistula closure by a skin flap after controlling infection.⁴ NPWT has a great advantage in the possibility of fistula closure without reconstructive surgery using a skin flap, and that is why we chose NPWT. There was a report that cervical esophageal perforation with abscess formation could be treated by NPWT.⁷ All of this suggests that NPWT might be an alternative or adjunctive tool for the treatment of cervical esophageal perforation with abscess formation when closure of the perforation is intractable or delayed.

Yoon et al.⁷ decided to start using NPWT with a pressure of 125 mmHg, but their patient experienced severe neck pain, so the pressure was modified to the lower level of

70–100 mmHg. As it turned out, they were able to continue to use NPWT without the patient experiencing intolerable pain. The optimal NPWT pressure recommended by Argenta and Morykwas⁶ was 125 mmHg below ambient pressure. Since the foam for NPWT was inserted between the pharynx and carotid sheath, high pressure inducing severe pain could be dangerous. To prevent carotid artery rupture and neck pain, we used NPWT with a pressure of 50 mmHg. There was a report that –45 mmHg also had a positive effect, although wound edge microvascular blood flow changed gradually when the negative pressure was increased.¹⁶

To the best of our knowledge, using NPWT in the management of false vocal cord perforation with abscess intractable to conservative management has not been reported. Our findings suggest that NPWT can be an alternative or adjunctive approach for larynx perforation when the perforation is difficult to close. However, the use of NPWT is contraindicated when the perforation of the larynx is too big to maintain negative pressure and when the foam for NPWT might come in direct contact with the carotid artery.

Conclusion

We have shown false vocal cord perforation with abscess safely and effectively treated by NPWT after conservative therapy. This therapy needs careful monitoring of inflammation exacerbation and foam contact with the carotid artery, either of which would require an aggressive surgical procedure.

Declaration of conflicting interests

The author(s) declared no potential conflicts of interest with respect to the research, authorship, and/or publication of this article.

Ethical approval

Ethical approval to report this case was obtained from Ethical Committee of Kagawa Rosai Hospital.

Funding


The author(s) disclosed receipt of the following financial support for the research, authorship, and/or publication of this article: This work was supported by JSPS KAKENHI (Grants-in-Aid for Scientific Research from the Ministry of Education, Culture, Sports, Science and Technology of Japan) under Grant Numbers JP16K20249, JP17K11329, and JP19K09869.

Informed consent

Written informed consent was obtained from the patient for their anonymized information to be published in this article.

ORCID iDs

Seiichiro Makihara  <https://orcid.org/0000-0002-4191-5229>

Shin Kariya  <https://orcid.org/0000-0002-7810-5844>

References

1. Sharma RK and Shrikant R. Laryngeal fistula following electrical burn. *Burns* 1997; 23(3): 265–267.
2. Costa DJ, Varvares MA and Bieneman BK. Fistula between the carotid artery and larynx in a 67-year-old man. *Ear Nose Throat J* 2009; 88(8): 1030–1032.
3. Kolber MR, Aspler A and Sequeira R. Conservative management of laryngeal perforation in a rural setting: case report and review of the literature on penetrating neck injuries. *CJEM* 2011; 13(2): 127–132.
4. Yii NW, Quinn SJ, Andersson LC, et al. Cervical necrotising fasciitis with pharyngeal perforation: treatment and reconstruction. *Br J Plast Surg* 1996; 49(4): 237–241.
5. Heater DW and Haskvitz L. Suspected pharyngoesophageal perforation after a difficult intubation: a case report. *AANA J* 2005; 73(3): 185–187.
6. Argenta LC and Morykwas MJ. Vacuum-assisted closure: a new method for wound control and treatment: clinical experience. *Ann Plast Surg* 1997; 38(6): 563–576; discussion 577.
7. Yoon BW, Yi KI, Kang JH, et al. Negative pressure wound therapy for cervical esophageal perforation with abscess. *Auris Nasus Larynx* 2015; 42(3): 254–257.
8. Gallo O, Deganello A, Meccariello G, et al. Vacuum-assisted closure for managing neck abscesses involving the mediastinum. *Laryngoscope* 2012; 122(4): 785–788.
9. Orgill DP and Bayer LR. Update on negative-pressure wound therapy. *Plast Reconstr Surg* 2011; 127(Suppl. 1): 105S–115S.
10. Andrews BT, Smith RB, Goldstein DP, et al. Management of complicated head and neck wounds with vacuum-assisted closure system. *Head Neck* 2006; 28(11): 974–981.
11. White CB and Foshee WS. Upper respiratory tract infections in adolescents. *Adolesc Med* 2000; 11(2): 225–249.
12. Motahari SJ, Poormoosa R, Nikkhah M, et al. Treatment and prognosis of deep neck infections. *Indian J Otolaryngol Head Neck Surg* 2015; 67(Suppl. 1): 134–137.
13. Weed T, Ratliff C and Drake DB. Quantifying bacterial bioburden during negative pressure wound therapy: does the wound VAC enhance bacterial clearance. *Ann Plast Surg* 2004; 52(3): 276–279; discussion 279–280.
14. Saeed MU and Kennedy DJ. A retained sponge is a complication of vacuum-assisted closure therapy. *Int J Low Extrem Wounds* 2007; 6(3): 153–154.
15. Andrews BT, Smith RB, Hoffman HT, et al. Orocutaneous and pharyngocutaneous fistula closure using a vacuum-assisted closure system. *Ann Otol Rhinol Laryngol* 2008; 117(4): 298–302.
16. Borgquist O, Ingemansson R and Malmsjo M. Wound edge microvascular blood flow during negative-pressure wound therapy: examining the effects of pressures from –10 to –175 mmHg. *Plast Reconstr Surg* 2010; 125(2): 502–509.