



Submitted: 3.12.2019
 Accepted: 4.3.2020
 Conflict of interest
 None.

Linear patterns of the skin and their dermatoses

**Sonja Senner¹, Laurie Eicher¹,
 Suzan Nasifoglu¹, Andreas
 Wollenberg^{1,2}**

(1) Department of Dermatology and
 Allergology, Ludwig Maximilian
 University, Munich, Germany

(2) Department of Dermatology I,
 Munich Medical Center, Munich,
 Germany

Section Editor
 Prof. Dr. D. Nashan, Dortmund

Summary

Knowledge about the linear patterns of the skin is a key competence of dermatologists. Four major groups of linear patterns can be distinguished: Langer lines, dermatomes, Blaschko lines and exogenous patterns. Langer lines run in the direction of the underlying collagen fibers (least skin tension) and play an important diagnostic role for some exanthematous skin diseases. In the thoracodorsal region, the distribution of the Langer lines gives rise to what is referred to as a 'Christmas tree pattern'. A dermatome is an area of skin that is supplied by a single spinal nerve. Disorders with a neuronal origin follow this pattern of distribution. The lines of Blaschko delineate the lines of migration of epidermal cells during embryogenesis. Exogenous linear patterns are caused by external factors.

The present CME article will highlight important skin disorders that primarily present in the form of one of the aforementioned patterns. In addition, we will also address skin conditions that may secondarily follow with these patterns (or distinctly not do so) as the result of various mechanisms such as the Koebner phenomenon, reverse Koebner phenomenon, and Wolf's isotopic response.

Introduction

The eye is one of the most effective and at the same time one of the most cost-efficient tools dermatologists have at their disposal for the diagnosis of skin diseases. Intuitive analysis of the type and distribution pattern of skin lesions by an experienced dermatologist is the first step in developing a list of possible differential diagnoses. The subsequent diagnostic workup, including imaging studies, histological examination and lab tests, allows for these diagnoses to be either supported or ruled out.

Most skin diseases show neither even nor random distribution, but are characterized by typical predilection sites. Some dermatoses occur in an even more localized fashion, as they follow certain linear patterns. These patterns can be categorized into four major groups (Langer lines, dermatomes, Blaschko lines and exogenous patterns) as well as additional patterns that are associated with one of the major groups (e.g., 'Christmas tree pattern', stretch-mark pattern).

Moreover, differential diagnostic considerations must also include skin diseases that usually manifest themselves with diffusely distributed lesions or as a rash, as they may adopt atypical distribution patterns as a result of various mechanisms.

Propaedeutics

Given that the four linear skin patterns are associated with specific mechanisms of development, it is possible to tentatively distinguish skin diseases with hematogenous, neuronal, embryonic or exogenous origin merely based on their clinical presentation and the linear pattern involved (Figure 1) [1].

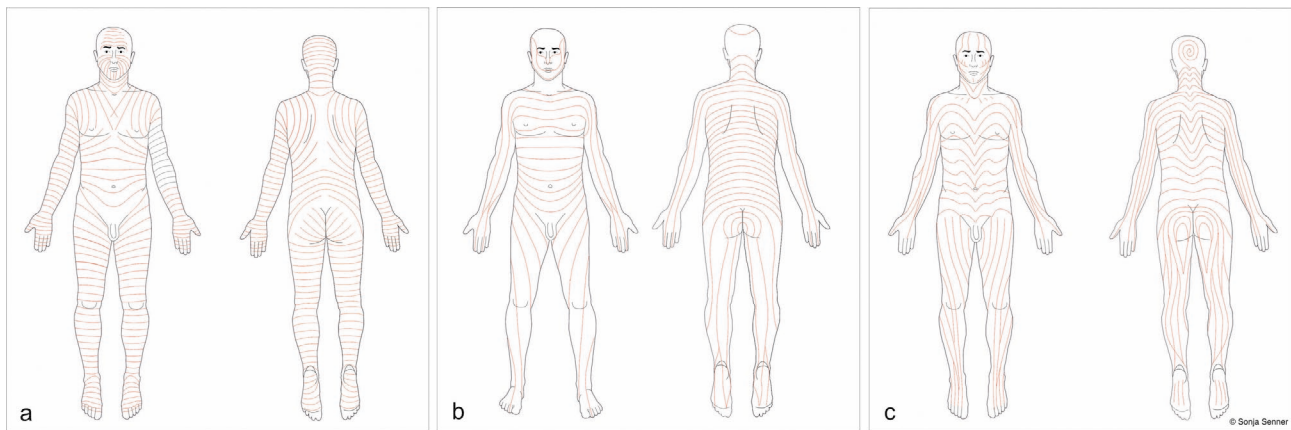


Figure 1 Three clinically relevant linear patterns cover the human body: Langer lines (a), dermatomes (b), Blaschko lines (c).

In 1861, Karl Langer (Austrian professor of anatomy; 1819–1887) was the first to describe the tension lines of the skin, although he himself ascribed the discovery of the underlying phenomenon to Baron Dupuytren. This discovery was based on the observation that circular holes punched into the skin of corpses took on an ellipsoid shape. Based on the varying orientation of the longitudinal axes of these holes, which corresponds to the direction of the underlying collagen fibers, Langer was able to deduce a pattern that is today referred to as ‘skin tension lines’ or ‘cleavage lines’. This fundamental discovery plays an important role not only for categorizing linear skin patterns but also in dermatologic surgery, as it is well known that surgical incisions placed along these lines (also designated as ‘relaxed skin tension lines’ by surgeon Albert Borges) will heal better due to decreased tension [2]. A common feature of dermatoses that follow the skin tension lines is that they spread throughout the body hematogenously [1]. As the exact location/direction of these lines on the extremities differs in various publications, we will refer to the pattern described by Braun-Falco [3]. Moreover, there are various other concepts of ‘mechanical’ lines [4].

On the back, Langer lines follow a pattern referred to as ‘Christmas tree pattern’.

A useful aid in the clinical diagnosis, the diagonal direction of the Langer lines in the thoracodorsal region was first described as ‘Christmas tree pattern’ in 2002 [5]. It is important to note that there is no association with the pattern of hair loss observed in women with androgenetic alopecia referred to by the same name.

The ‘stretch-mark pattern’ is a special form associated with Langer lines. It is characterized by skin lesions that – on the abdomen in particular – develop orthogonally to these lines and are thus perpendicular to the vector of highest tension. The best-known examples of such lesions are striae gravidarum, or polymorphic eruption of pregnancy (PEP) lesions, which may develop therein.

Dermatomes are clearly demarcated, band-like areas of skin (especially in the thoracic region) that are supplied by a single spinal nerve root. They were first described in 1892 by the English neurologist Sir Henry Head (1861–1940) [6]. Herpes zoster is the best-known example for a skin disease usually confined to certain dermatomes.

Based on own observations of 170 patients with epidermal nevi, in 1901 the German dermatologist Alfred Blaschko (1858–1922) was the first to describe a specific linear pattern of genetic skin diseases manifesting themselves on the trunk. However, Blaschko never defined the corresponding lines in the cephalic region.

Blaschko lines are based on epidermal, embryonic mosaicism.

This was done by Happle et al. one hundred years later (2001) [7]. Many people confuse the lines of Blaschko with dermatomes, and genetic mosaicisms may be erroneously described as ‘zosteriform’. This pattern is based on mosaicism of ectodermal cells that migrate ventrally from the dorsal midline during embryogenesis. Mutations may cause differences in color or differentiation of these cells, thus giving them a different clinical appearance than the surrounding skin; on the skin, these genetic mosaics follow the lines of Blaschko. In this context, a distinction is made between streaks (e.g., incontinentia pigmenti) and bands (e.g., McCune-Albright syndrome).

The last group of linear patterns consists of skin disorders caused by exogenous factors, including bedbugs (multiple grouped bites arranged in a linear fashion) or (photo)contact dermatitis due to (photo)allergens (streaky erythematous lesions).

The exact biological bases of linear skin patterns, especially in terms of their molecular structures, are subject to current research efforts [8].

Mechanisms of association

Various mechanisms may cause dermatoses usually characterized by diffusely distributed lesions to manifest themselves in a specific linear pattern, or alternatively, they may distinctly spare such a linear pattern. This phenomenon may both facilitate and complicate the diagnosis of skin diseases. There are three such mechanisms every dermatologist should be familiar with: Koebner phenomenon, reverse Koebner phenomenon, and Wolf’s isotopic response. As scratch marks are usually linear in shape, koebnerized dermatoses primarily manifest themselves in a linear pattern. In addition, certain skin diseases such as psoriasis may present with a linear pattern of distribution, irrespective of the Koebner phenomenon.

Koebner phenomenon: Nonspecific local trauma triggers a specific skin disease.

Koebner phenomenon, the first such mechanism of association, describes the triggering of a specific chronic-inflammatory skin disease by nonspecific (usually mechanical) trauma. Also referred to as ‘isomorphic response’, this phenomenon was first described in 1872 by the German dermatologist Heinrich Koebner (1838–1904) who had noted that nonspecific skin irritation in psoriasis patients resulted in typical psoriatic lesions [9].

Reverse Koebner (Renbök) phenomenon: A localized skin disease protects the patient from a different skin disease at the same site.

In 1991, the German dermatologist Rudolf Happle described the inverse Koebner phenomenon: Patients with both psoriasis and alopecia areata universalis showed normal hair growth in the areas affected by psoriasis. He termed this phenomenon – a preexisting skin disease protecting the patient from the manifestation of another skin disease – Renbök phenomenon. ‘Renbök’, of course, is ‘Köbner’ spelled backwards (in German) [10].

Isotopic response: A skin disease follows in the footsteps of another dermatosis.

The third mechanism, isotopic response, was first described by the Israeli dermatologist Ronni Wolf in 1985. Here, a pathogenetically unrelated skin disease develops at the site of an entirely different, previously healed skin disease [11]. To give an example, lichen planus may develop at the same site previously affected by herpes zoster.

While we still do not fully understand the exact pathogenesis of any of the three mechanisms, there is a number of different theories [8].

Skin diseases along the skin tension lines

In the following, we will present a number of skin diseases that occur along the skin tension lines. A list of other such dermatoses can be found in Table 1.

Table 1 Skin diseases that may follow the Langer lines.

Kaposi sarcoma
Leser-Trélat sign
Stage 2 syphilis
Mycosis fungoides
Parapsoriasis
Pityriasis lichenoides chronica
Pityriasis rosea
Guttate psoriasis

Guttate psoriasis

Guttate psoriasis (Figure 2) describes the eruption of small psoriatic lesions across the trunk and proximal extremities. While the disease may have an acute onset, it can also run a chronic recurrent course. Especially in children, guttate psoriasis may be the initial manifestation of plaque psoriasis.

The condition is characterized by multiple erythematous oval plaques with central scaling whose longitudinal axes follow the direction of the Langer lines. The face and mucous membranes are not affected. Scale removal elicits the various typical signs (e.g., Auspitz sign) associated with psoriasis, and the Koebner phenomenon may be positive. If the clinical presentation is not straightforward, a biopsy may be diagnostically useful.

A comprehensive diagnostic workup should always include the search for possible triggers, streptococcal infections in particular [12]. Roughly 60 % of all pediatric cases are triggered by streptococcal infections, especially of the tonsils and perianal region. Molecular mimicry between streptococcal antigens and

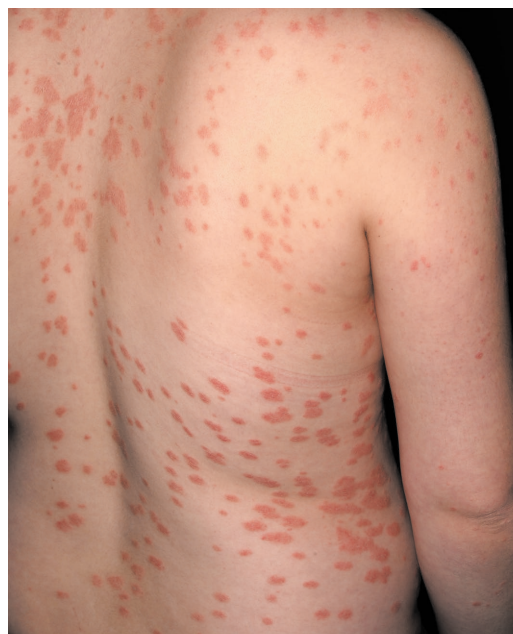

Figure 2 Guttate psoriasis. Disseminated grayish-red papules and plaques with firmly adhering scales, measuring up to 1 cm in size.

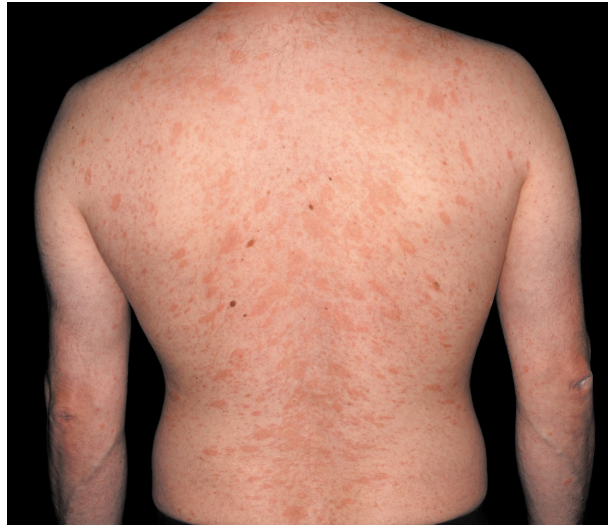

Figure 3 Pityriasis rosea. Salmon-colored, oval macules with collarette-like scales following the Langer lines.

keratinocyte antigens is thought to be responsible [13]. In the early stages, it may be difficult to differentiate guttate psoriasis from pityriasis rosea or stage 2 syphilis, as the characteristic morphology of individual lesions may not yet be discernible.

Treatment of guttate psoriasis is usually aimed at treating the underlying infection, in addition to topical corticosteroids and phototherapy.

Pityriasis rosea

A common and benign disease, pityriasis rosea (Figure 3) runs an acute, self-limiting course. Lesions typically develop along the skin tension lines and consist of multiple oval, sharply demarcated erythematous papules and plaques, especially on the trunk (usually < 1 cm in diameter). They show collarette-like scaling and form a characteristic 'Christmas tree pattern' on the back. Whole-body inspection frequently reveals a larger primary lesion – referred to as herald patch – that measures 2–10 cm in diameter; this finding supports the tentative diagnosis. While few patients develop flu-like symptoms, the majority of those affected show no systemic symptoms. Lab tests should be performed to rule out stage 2 syphilis, and histology may be required to rule out mycosis fungoides in patients with disease duration > 12 weeks [1]. There appears to be an association with viral infections (HHV6/HHV7), as it has been shown that antiviral treatment (acyclovir) shortens the duration of clinical symptoms [14].

Pityriasis rosea presents with a 'Christmas tree pattern'.

In most cases, pityriasis rosea does not require treatment, and symptoms will resolve spontaneously after 6–12 weeks.

Parapsoriasis and mycosis fungoides

Parapsoriasis is a chronic idiopathic dermatosis characterized by orange-red, digitate, rarely pruritic macules that are, in some cases, covered with fine, whitish-yellowish scales. Especially on the trunk, these lesions follow the skin tension lines (Figure 4). Early-stage mycosis fungoides (MF) may have the same clinical and histological presentation as parapsoriasis, and it has not been unequivocally elucidated whether these two disorders are in fact two genuinely different entities [15]. The

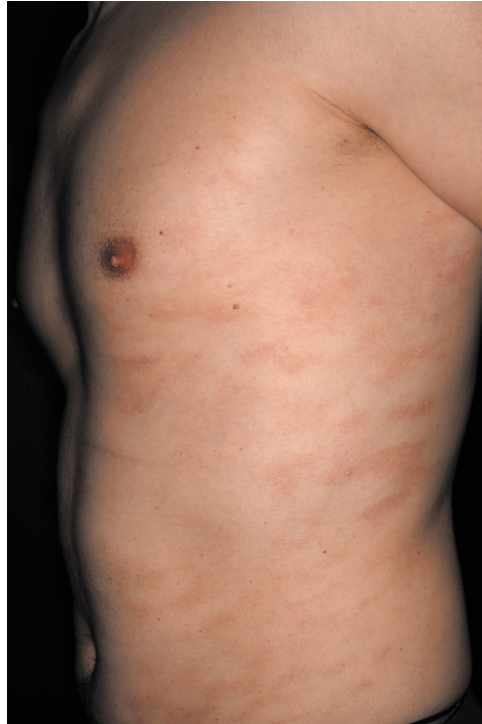

Figure 4 Parapsoriasis. Light-red and brown-yellowish digitiform patches and plaques following the Langer lines.

classic arrangement of MF lesions along the cleavage lines is observed in stage 1 and 2 disease in particular (Figure 5), with well-demarcated erythematous macules and plaques that primarily affect the trunk and the flexor aspects of the extremities. The clinical picture ranges from homogeneous, erythematous scaly plaques to a poikilodermatous appearance with white, red and brown components within the same lesion [15].

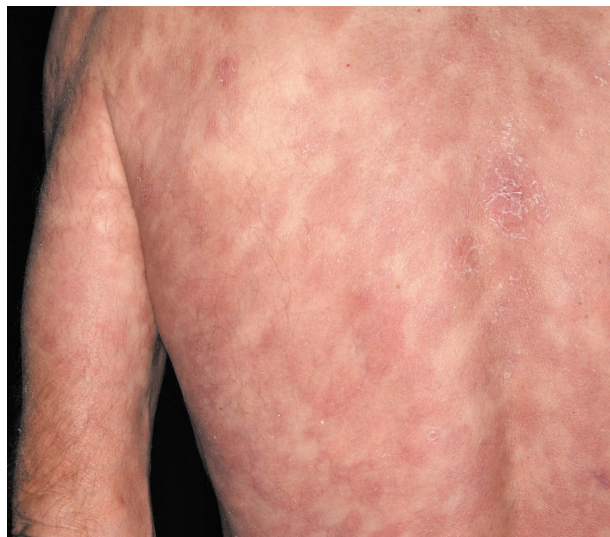

Figure 5 Mycosis fungoides. Multiple, partially confluent, scaly, erythematous patches and plaques.

The clinical presentation of early-stage mycosis fungoides may resemble that of parapsoriasis.

Diagnosis is based on clinical presentation and histological findings, which shows focal spongiosis and parakeratosis as well as perivascular inflammatory infiltrates. Follow-up biopsies may be required.

Treatment primarily consists of phototherapy (narrowband UVB) and topical corticosteroids [16].

Kaposi sarcoma

The lesions of disseminated Kaposi sarcoma may follow the skin tension lines. Kaposi sarcoma (KS) is a rare, primarily cutaneous, angioproliferative neoplasm caused by human herpesvirus 8 (HHV8). It is associated with HLA-DR5 and may secondarily affect other organs as well.

There are four different disease variants: classic KS, endemic/African KS, iatrogenic KS (in immunocompromised patients) and HIV-related KS. Clinically, KS is characterized by brownish, round to oval lesions along the cleavage lines, frequently arising on the lower extremities. Classic KS predominantly occurs in elderly men of Southeast European descent. The oral mucosa and the gastrointestinal tract may also be affected [17].

Patients with Kaposi sarcoma must be tested for HIV.

The diagnosis is made on histological grounds, showing proliferation of endothelial spindle cells and extravasation of red blood cells. There are various therapeutic options, depending on the overall situation.

Eruptive seborrheic keratoses and Leser-Trélat sign

Eruptive seborrheic keratoses are common, and they frequently follow the skin tension lines. The Leser-Trélat sign (LTS) was named after a German (Leser 1828–1916) and a French (Trélat 1828–1890) surgeon who were credited with having published the first reports independently from each other. It later turned out that both had actually described cases of senile hemangioma. Around 1900, Eugen Holländer was in fact the first to report on the association between malignancy and seborrheic keratoses [18]. This association is marked by the explosive onset of multiple seborrheic keratoses along the cleavage lines on the trunk, which may be indicative of an underlying malignancy. However, given that seborrheic keratoses often present as multiple lesions, the clinical validity of LTS as a facultative paraneoplastic condition is rather low. Malignancies reported to be associated with LTS primarily include gastrointestinal adenocarcinomas (e.g., stomach, liver, colon, pancreas). Cases of breast cancer, lung cancer, lymphoproliferative disorders and melanoma have also been described [19]. While the exact pathogenesis of LTS remains unclear, increased production of growth factors (epidermal and transforming growth factor alpha) are thought to play a role [20].

In cases of eruptive onset of seborrheic keratoses, a diagnostic workup to rule out malignancy should be considered.

Coincidence of LTS and acanthosis nigricans has been reported [21]. The latter is characterized by hyperpigmented plaques in intertriginous areas and is associated with obesity and diabetes. While both of the aforementioned skin lesions are benign, their sudden onset should prompt a comprehensive diagnostic workup.

Pityriasis lichenoides chronica

Pityriasis lichenoides chronica (PLC) is a very rare, chronic erythematous-squamous dermatosis without systemic symptoms. Only rarely does it present with pruritus. Clinically, PLC is characterized by generalized, salmon-colored scaly papules arranged along the skin tension lines; the central scales are easily removable. PLC may occur de novo or may develop from the acute disease variant (pityriasis

Patients with pityriasis lichenoides chronica should be followed up closely.

lichenoides et varioliformis acuta, PLEVA). The condition is frequently associated with infections [22].

As there have been reports of PLC progressing to MF, follow-up biopsies are required in cases marked by a protracted disease course, lack of remission or development of larger macules and plaques [23].

Aside: Wolf's isotopic response

We would like to illustrate a case of Wolf's isotopic response in a patient who developed indeterminate cell histiocytosis at the site of previously healed pityriasis rosea lesions: A 15-year-old girl was admitted with an 18-month history of skin lesions (predominantly) on the trunk that had been refractory to UV therapy and topical corticosteroids. The patient had initially (18 months earlier) been diagnosed with 'pityriasis rosea' based on her clinical presentation with erythematous plaques along the skin tension lines and a clearly discernible herald patch. Given the recalcitrance of the condition, she eventually underwent a biopsy. Histology showed a lymphohistiocytic infiltrate in the upper dermis. The histiocytic cells were positive for S100, CD68, factor XIIIa and CD1a; however, no Birbeck granules were detected on electron microscopy.

These findings led to the diagnosis of 'indeterminate cell histiocytosis', which had developed at the site of the previously healed pityriasis rosea lesions (isotopic response). The patient subsequently experienced spontaneous remission, with only few pale-red macules remaining after three years [5].

Special variant – stretch-mark pattern

Linear PEP lesions following a stretch-mark pattern

Polymorphic eruption of pregnancy (PEP; also known as pruritic urticarial papules and plaques of pregnancy, PUPPP) may show a highly variable clinical presentation: pruritic urticarial papules and plaques, erythematous patches, vesicles and target-like skin lesions have all been described as being associated with PEP [24]. These lesions predominantly occur on the trunk (usually sparing the umbilicus) in the area of preexisting striae gravidarum; they are therefore perpendicular to Langer's lines. While this stretch-mark pattern is primarily seen on the trunk, the buttocks, thighs and upper arms may also be affected. PEP may be easily distinguished from pemphigoid gestationis, as immunofluorescence studies are always negative.

The pathogenesis of PEP is thought to involve alterations in collagen fibers due to increased cutaneous distension of the abdomen and breasts in late pregnancy [25]. While PEP almost exclusively occurs late in the third trimester, when abdominal circumference is largest, some patients may develop the condition postpartum. Primigravidas and multiparas are predisposed. Fortunately, recurrence in subsequent pregnancies is very rare [26]. Symptomatic treatment of this self-limiting disease usually consists of topical corticosteroids and antihistamines [27]. In addition, it is essential to explain to pregnant women that there is no risk for themselves or their children.

Polymorphic eruption of pregnancy (PEP) presents with a stretch-mark pattern.

Skin diseases limited to dermatomes

Herpes zoster

One of the most common skin diseases, herpes zoster is caused by endogenous re-activation of the varicella zoster virus. Prior to the onset of skin lesions, patients

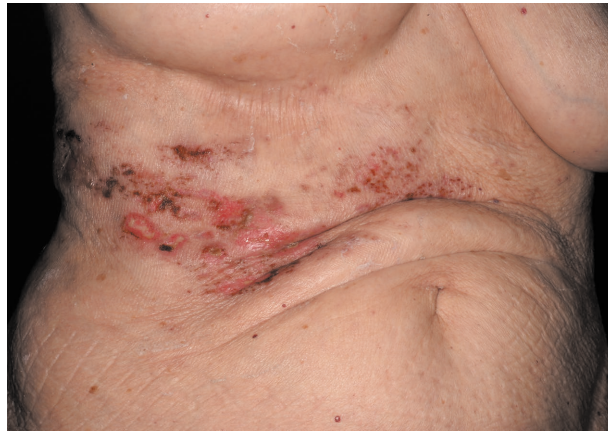

Figure 6 Herpes zoster (T6/7). Grouped vesicles on an erythematous base with signs of impetiginization.

frequently experience prodromal symptoms for a few days, such as a tingling or burning sensation and, in some cases, even lancinating pain.

Initial lesions consist of well-demarcated, erythematous, occasionally confluent macules that are limited to a specific dermatome. Within the following roughly 24 hours, the typical herpes zoster rash develops with grouped vesicles on an erythematous base, which subsequently becomes pustular (Figure 6). Rarely, the condition may affect two or multiple dermatomes; in the latter case, the dermatomes involved do not necessarily have to be adjacent. If the clinical presentation is ambiguous, the diagnosis can be confirmed by polymerase chain reaction (PCR) [28].

As herpes zoster is very common and given that the dermatome pattern is very characteristic, conditions that present with the above-mentioned mechanisms of association are observed particularly frequently.

Aside: Koebner phenomenon

The following example illustrates the Koebner phenomenon in a case of granulomatosis with polyangiitis (GPA; formerly known as Wegener's granulomatosis) triggered by herpes zoster: A 68-year-old man with a four-year history of GPA on maintenance therapy with cyclophosphamide and systemic corticosteroids presented with typical lesions of herpes zoster ophthalmicus. The diagnosis of GPA had been confirmed serologically by detection of antineutrophil cytoplasmic antibodies (c-ANCA) and anti-serine protease 3 (PR3) antibodies. While the facial lesions initially showed clinical improvement after 14 days of oral brivudine therapy, the patient subsequently developed necrotic ulcers consistent with GPA in the area previously affected by herpes zoster. Histology showed noncaseating granulomas with a neutrophilic infiltrate; PCR testing for varicella zoster virus was negative. A subsequent increase in the corticosteroid dose and the addition of infliximab led to a good clinical response [29].

Aside: Reverse Koebner phenomenon

The following case describes the reverse Koebner phenomenon in a patient with graft-versus-host disease (GvHD) following herpes zoster: A 34-year-old man had developed typical herpes zoster lesions (T6–8) one year earlier, shortly after

undergoing successful allogenic bone marrow transplantation for acute myeloid leukemia. The skin lesions had resolved completely with intravenous acyclovir. The patient now presented with chronic cutaneous GvHD and a maculopapular rash that distinctly spared the T6–8 dermatomes previously affected by herpes zoster [29].

Aside: Wolf's isotopic response

The following two cases are examples of Wolf's isotopic response following herpes zoster:

The clinical presentation of lichen planus may be atypical, i.e. limited to a certain dermatome, if associated with an isotopic response.

A 68-year-old man presented with herpes zoster (T10–11) while on chemotherapy. After seven days of intravenous acyclovir therapy, the pain had completely resolved but the skin lesions showed no signs of healing. Although treatment was subsequently switched to oral valacyclovir for another seven days, the skin lesions persisted. Histology showed hypergranulosis, orthohyperkeratosis, degeneration of the basal layer and a band-like lymphocytic infiltrate. The patient was diagnosed with lichen planus. The condition was strictly limited to the dermatomes previously affected by herpes zoster and were consistent with an isotopic response [29].

An 87-year-old woman developed tense blisters in the area affected by herpes zoster (C7–8) two months earlier. Histology showed subepidermal clefting; ELISA (enzyme-linked immunosorbent assay) was positive for BP180 and BP230. The patient was diagnosed with bullous pemphigoid. Consistent with an isotopic response, the disease occurred in the area previously affected by herpes zoster [30].

Skin diseases following the lines of Blaschko

The pattern associated with the lines of Blaschko is based on embryonic mosaicism of epidermal cells that migrate from the dorsal midline during embryogenesis. This form of cutaneous mosaicism has also been described in chicken [31].

Aside: Cutaneous mosaicism

According to Happle et al., from a genetic point of view, cutaneous mosaicism can be categorized as either epigenetic or genomic mosaicism [32].

Epigenetic mosaics are characterized by the fact that all cells contain the same genomic information. Gene expression can be turned on and off through (de) methylation caused by retrotransposons (retroviral particles from plant or animal genomes) [33]. As early as during embryogenesis, these epigenetic factors may cause two functionally different cell clones to form that contain the same genomic information. Such functional mosaicism may affect both autosomes and X chromosomes. Thus, the Blaschko line pattern might be caused by autosomal epimutation [32]. The pattern itself is likely to occur through the formation of two functionally different cell clones during embryogenesis [32].

Unlike epigenetic mosaicism, genomic mosaicism usually shows no familial clustering [32]. However, one important exception to this rule is type 2 segmental mosaicism in some autosomal dominant skin diseases. Autosomal dominant dermatoses may manifest two different types of mosaic distribution. Type 1 segmental mosaicism results from an early postzygotic mutation in an initially healthy embryo. Type 2 segmental mosaicism, on the other hand, results from a postzygotic mutation in a heterozygous embryo and leads to the loss of the corresponding wild-type

Table 2 Clinical classification of cutaneous mosaicism (modified after R. Happle [32]).

Clinical classification of cutaneous mosaicism according to R. Happle	
<i>I. Nonsegmental mosaicism</i>	
<i>Pattern</i>	<i>Example</i>
Single-point mosaicism	Solitary neoplasms such as trichoepithelioma, syringoma, seborrheic keratosis
Disseminated mosaicism	Neurofibromatosis, trichoepitheliomatosis, leiomyomatosis
Patchy mosaicism without midline separation	Giant melanocytic nevus
<i>II. Segmental mosaicism</i>	
<i>Pattern</i>	<i>Example</i>
Type 1a: Blaschko lines, narrow bands	Incontinentia pigmenti; pigmentary mosaicism, Ito type; various epidermal nevi
Type 1b: Blaschko lines, broad bands	McCune-Albright syndrome
Type 2: Checkerboard pattern	Nevus spilus, Becker nevus
Type 3: Phylloid (leaf-like) pattern	Phylloid hypomelanosis
Type 4: Lateralization pattern	CHILD syndrome, neurocutaneous melanosis

allele. Clinical manifestations of type 2 are typically quite severe and superimpose the rather diffuse phenotype otherwise observed. Type 2 segmental mosaicism is associated with a 50 % risk of passing the gene on to the next generation [34, 35]. This novel genetic concept has been confirmed on a molecular genetic level in a patient with Hailey-Hailey disease presenting with a superimposed linear pattern [36].

From a clinical point of view, a distinction is made between nonsegmental and segmental mosaicism (Table 2). “Segmental” signifies that one or more areas of the body are affected, usually in an asymmetrical pattern that respects the midline [32].

The group of nonsegmental mosaics includes single-point mosaicism, disseminated mosaicism and patchy mosaicism without midline separation. Single-point mosaicism is by far the most common type (e.g., solitary seborrheic keratosis). Disseminated mosaicism is predominantly found in autosomal dominant tumor syndromes such as neurofibromatosis. Giant melanocytic nevus is an example of patchy mosaicism without midline separation. It cannot be classified as segmental, as the lesion crosses the midline.

Segmental mosaicism is comparatively rare and can be divided into four different types: Type 1a: Blaschko lines, narrow bands; type 1b: Blaschko lines, broad bands; type 2: checkerboard pattern; type 3: phylloid pattern; type 4: lateralization pattern.

Blaschko lines presenting as narrow bands are common in mosaic disorders (e.g., incontinentia pigmenti). Type 1b Blaschko lines are so broad that it is sometimes difficult to even identify a linear pattern (e.g., McCune-Albright syndrome). The checkerboard pattern is characterized by a rectangular pattern with sharp demarcation at the midline (e.g., Becker nevus). The phylloid pattern has a leaf-like appearance (e.g., phylloid hypomelanosis). Lateralization is marked by involvement of only one side of the body, with sharp demarcation along the ventral midline (e.g., CHILD syndrome) [32].

In addition, polygenic dermatoses such as psoriasis or atopic dermatitis may also present with a linear or otherwise segmental pattern. Such segmental

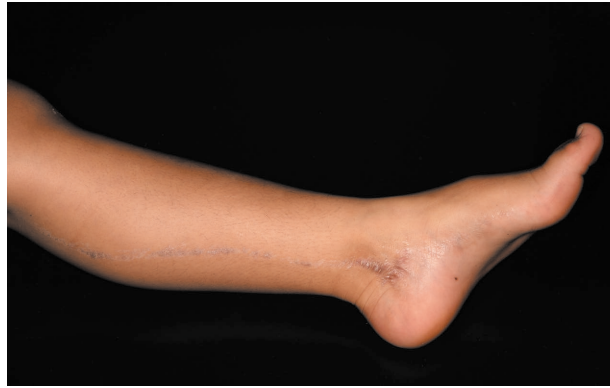

Figure 7 Lichen striatus. Small red-brownish, lichenoid, flat papules coalescing to a streak along the lines of Blaschko.

involvement may be associated with nonsegmental, bilateral lesions of the same disorder and has therefore been referred to as “superimposed segmental manifestation of polygenic skin disorders” [37].

The present article highlights only the most important skin diseases that follow the lines of Blaschko.

Lichen striatus

Lichen striatus is the most common dermatosis associated with a blaschkoid distribution. Predominantly affecting children, the condition is characterized by sudden onset of small, pink or hypopigmented lichenoid papules arranged in a linear fashion; nail involvement is possible (Figure 7).

Histology reveals superficial lichenoid dermatitis and a deep lymphohistiocytic infiltrate. Patients with an atopic diathesis are more commonly affected. While there may initially be disease progression for a few weeks or months, the disease always runs a self-limiting course. Topical corticosteroids may be considered in cases associated with severe pruritus [38].

Inflammatory linear verrucous epidermal nevus (ILVEN) is an important differential diagnosis, usually characterized by more severe inflammation and hyperkeratosis.

Epidermal nevi

Epidermal nevi are the result of cutaneous mosaicism. They may be present at birth or manifest themselves in early childhood. While some lesions occur sporadically, others are part of various epidermal nevus syndromes. A distinction is made between soft and hard lesions. Clinically, epidermal nevi may present as (in some cases) inflammatory, reddish-brown lesions, either with a soft and papillomatous texture or a hard and verrucous appearance (Figure 8).

Histology of soft lesions shows orthohyperkeratosis, papillomatosis and acanthosis, whereas hard lesions are primarily characterized by hyperkeratosis. Besides the epidermis, epidermal nevi may also affect adnexal structures; such lesions are referred to as organoid nevi. Epidermolytic variants have also been described. The offspring of patients thus affected has an increased risk of developing epidermolytic ichthyosis [39].

Lichen striatus is the most common dermatosis associated with a blaschkoid distribution.

Epidermal nevi are the result of cutaneous mosaicism.

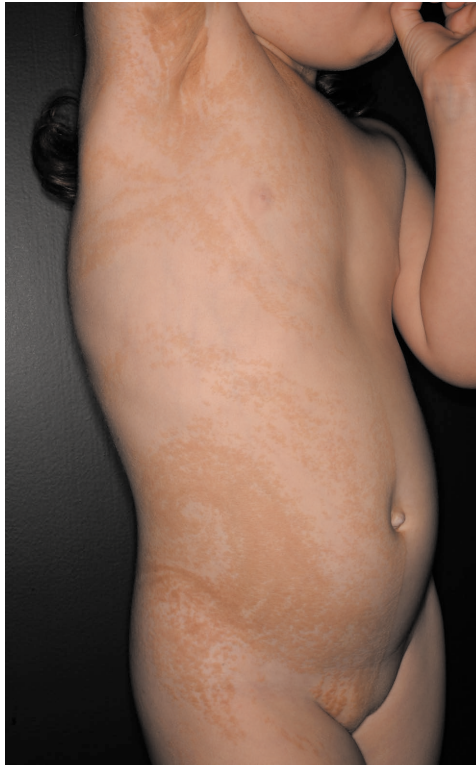

Figure 8 Epidermal nevus. Small, bizarrely shaped, coalescing brown macules and plaques with a verrucous surface arranged in a linear pattern.

Inflammatory linear verrucous epidermal nevus (ILVEN)

Frequently associated with severe pruritus, ILVEN presents with erythematous papules that often coalesce to form plaques, which may take on a psoriasiform, lichenoid or verrucous appearance. Unlike lichen striatus, inflammatory hyperkeratosis is more severe. Treatment with corticosteroids or calcipotriene may be attempted. Spontaneous resolution may occur in rare cases [40, 41].

Linear nevus sebaceus

Usually occurring on the scalp, linear nevus sebaceus is a common hamartoma that presents as a hairless, waxy, yellowish, verrucous plaque. Histology shows immature hair follicles with groups of mature sebaceous glands; an increased number of apocrine sweat glands are frequently seen. Linear nevus sebaceus may occur as part of various syndromes. The disease is caused by polyzygotic HRAS- (95 %) or KRA (5 %) mutations [42]. Given the frequent occurrence of various benign and malignant neoplasms in nevus sebaceus lesions (e.g., trichoblastoma or syringocystadenoma papilliferum), excision is usually indicated after puberty [43].

In adult patients, malignant transformation of linear nevus sebaceus lesions may occur.

Syndromes with linear nevi

Various syndromes are associated with epidermal nevi, which are summarized in Table 3. One such example is phacomatosis pigmentokeratolica, characterized by the rare concurrence of nevus spilus (checkerboard pattern) and nevus sebaceus (Blaschko pattern). The condition is therefore also referred to as 'didymosis

Table 3 Select syndromes associated with epidermal nevi.

Select epidermal nevus syndromes				
<i>Syndrome</i>	<i>Gene</i>	<i>OMIM</i>	<i>Cutaneous findings</i>	<i>Extracutaneous findings</i>
Schimmelpenning-Feuerstein-Mims syndrome	<i>HRAS, KRAS</i>	163200	Nevus sebaceus along the lines of Blaschko	Mental retardation, epilepsy, iris coloboma
Phacomatosis pigmentokeratolica	<i>HRAS, KRAS</i>	No entry	Nevus sebaceus and nevus spilus along the lines of Blaschko	CNS involvement, including epilepsy and deafness
Nevus comedonicus syndrome	<i>NEK-9</i>	617025	Nevus comedonicus along the lines of Blaschko	Ipsilateral cataract, epilepsy, skeletal deformities
Becker nevus syndrome	<i>ACTB</i>	604919	Pigmented epidermal nevus with hypertrichosis in the scapular area; checkerboard pattern	Ipsilateral hypoplasia of the pectoral muscle, skeletal deformities
Proteus syndrome	<i>AKT1</i>	176920	Epidermal nevus along the lines of Blaschko; subcutaneous hamartomas; vascular anomalies	Macrodactyly, hemimegalencephaly
CHILD syndrome (congenital hemidysplasia with ichthyosiform nevus and limb defects)	<i>NSDHL</i>	308050	Lateralization and Blaschko lines	Ipsilateral limb defects
CLOVES syndrome	<i>PIK3CA</i>	612918	Soft keratinocyte nevus along the lines of Blaschko	Lateralized port-wine stains; lipomas; vascular malformations

spilosebacea' (Figure 9). CNS involvement, including epilepsy and deafness, is possible [42]. The syndrome is caused by a postzygotic activating mutation in the RAS signaling pathway of a multipotent ectodermal progenitor cell; however, there is no germline mutation. Similar to patients with non-syndromic nevus sebaceus, individuals with phacomatosis pigmentokeratolica may likewise develop various

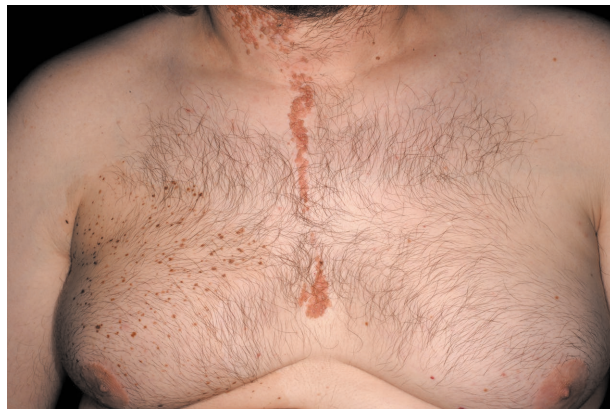

Figure 9 Phacomatosis pigmentokeratolica. Brownish-reddish papules and nodules with a verrucous surface. The lesions coalesce to form a linear plaque (nevus sebaceus). In addition, there is a light-brown patch with dark-brown specks (nevus spilus).

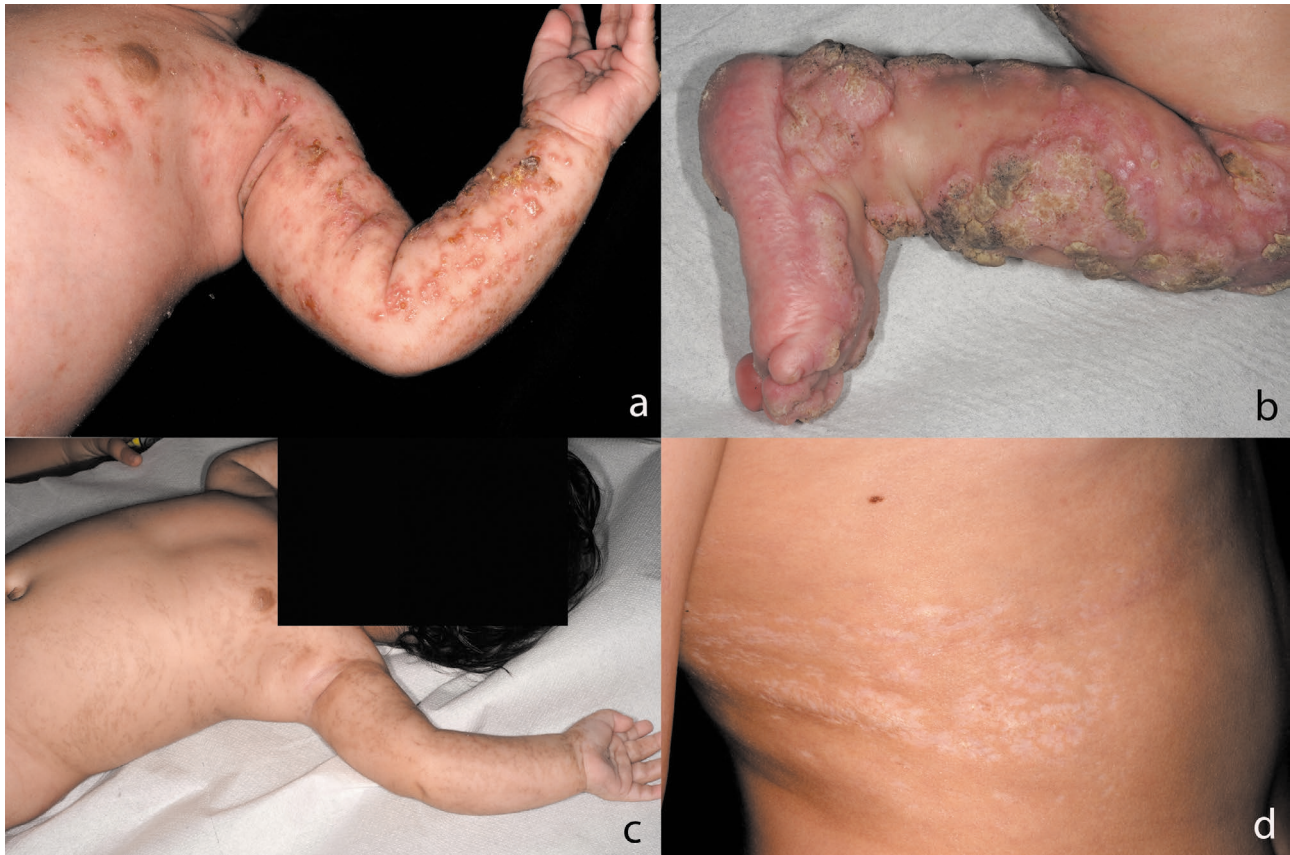

Figure 10 Incontinentia pigmenti. Inflammatory stage characterized by grouped blisters and erosions arranged in a serpiginous pattern (a). Verrucous stage showing hyperkeratotic papules and nodules with a verrucous surface arranged in a serpiginous pattern along the lines of Blaschko (b). Hyperpigmented stage. Hyperpigmentation along the lines of Blaschko (c). Hypopigmented stage. Hypopigmentation along the lines of Blaschko (d).

Phacomatosis pigmentokeratotica describes the concurrence of nevus spilus and nevus sebaceus.

other tumors within these preexisting lesions. Close clinical follow-up is urgently recommended.

Incontinentia pigmenti (Bloch-Sulzberger syndrome)

Incontinentia pigmenti is an X-linked dominant genodermatosis. Spontaneous mutations are rare. The disease goes through various stages: the first stage (in utero until six months after birth) is characterized by vesicles arranged along the Blaschko lines; these lesions are frequently associated with infections, and infants often show blood eosinophilia. In the second stage, the lesions become more verrucous, but will usually resolve within the first year of life. The third stage (usually until the age of 12) is characterized by patchy hyperpigmentation. The fourth stage, which will persist into adulthood, shows linear hypopigmentation with alopecia, especially on the calves (Figure 10a–d).

Depending on disease stage, histology reveals spongiosis with eosinophilia (inflammatory stage), papillomatosis with dyskeratosis (verrucous stage), melanophages (pigmentation) or atrophy with a decrease in the number of melanocytes (hypopigmentation). As the condition is usually lethal for male embryos, girls are almost exclusively affected. Given that mutations in the *IKBKG* gene lead to uncontrolled apoptosis, females only survive because of X chromosome mosaicism.

In cases of suspected incontinentia pigmenti, the mother should also be examined.

In patients with morphea-like skin lesions without inflammation/induration, linear atrophoderma of Moulin should be considered.

Furocoumarins can cause phototoxic dermatitis.

In most cases, the mother is also affected and frequently shows linear hypopigmentation. Associated extracutaneous findings involve the teeth, eyes and CNS [44].

Treatment is symptomatic, and the prognosis depends on the comorbid diseases [45].

Linear atrophoderma of Moulin

In 1992, Moulin et al. described a form of hyperpigmented atrophoderma that follows the lines of Blaschko and occurs without preceding inflammation, induration or morphea. Disease onset is during childhood or adolescence. The condition is not associated with any other symptoms or laboratory changes [46].

Histology shows mild epidermal atrophy, focally swollen collagen fibrils and a perivascular lymphocytic infiltrate. As the prognosis is good, no treatment is required [47].

Linear patterns due to exogenous factors

Exogenous factors, too, may cause linear skin patterns. The location and pattern of these lines may point to the diagnosis.

Phyto-photodermatitis

Phyto-photodermatitis is caused by the action of an exogenous photosensitizer (such as furocoumarin) in combination with light exposure. Contact with the photosensitizer may thus give rise to linear skin lesions. Within hours after exposure to UV light, patients develop sharply demarcated linear or reticular erythema, which may be associated with blistering, pruritus or burning (Figure 11). If, after contact with the photosensitizer, the skin is only exposed to a weak UVA dose, patients may skip the inflammatory stage and merely develop linear hyperpigmentation after 1–2 weeks (pigmentary phyto-photodermatitis). Common triggers include furocoumarins, which can be found in creams or face lotions containing bergamot oil as well as in a number of plants such as the giant hogweed.

Diagnosis is usually made based on clinical grounds. If the clinical presentation is ambiguous, histology may be required, showing UV-damaged cells with increased pigment [48]. The differential diagnosis primarily includes photoallergic dermatitis. Here, lesions may spread beyond the UV-exposed areas.

The mainstay of treatment is identification and elimination of possible triggers. Rigorous use of unscented sunscreen is recommended. Lesions will heal with hyperpigmentation, which may be addressed with retinoic acid, hydroquinone or corticosteroids.

Contact dermatitis

One example of contact dermatitis presenting with a linear pattern is the reaction to paraphenylenediamine (PPD) contained in so-called ‘temptoos’ (a neologism derived from “temporary” and “tattoo”) (Figure 12). Also known as “false henna” or “black henna”, PPD is a highly potent allergen that is commonly used in a number of countries frequented by vacationers. Depending on the quantity of PPD contained in the temporary tattoo, contact dermatitis may occur even with first-time use. There have been numerous reports of severe contact dermatitis following exposure to PPD [49].

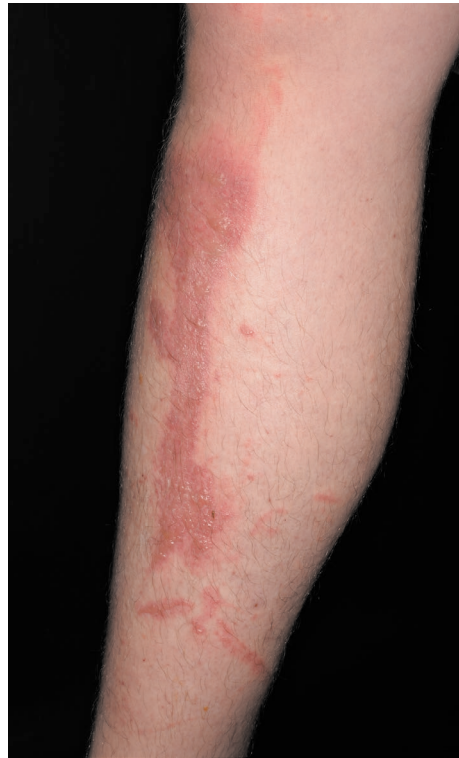

Figure 11 Phototoxic dermatitis. Serpiginous erythema with blistering after exposure to giant hogweed (*Heracleum giganteum*).




Figure 12 Erythema with blistering confined to the area of a “fake henna tattoo” in a patient with contact dermatitis to paraphenylenediamine.

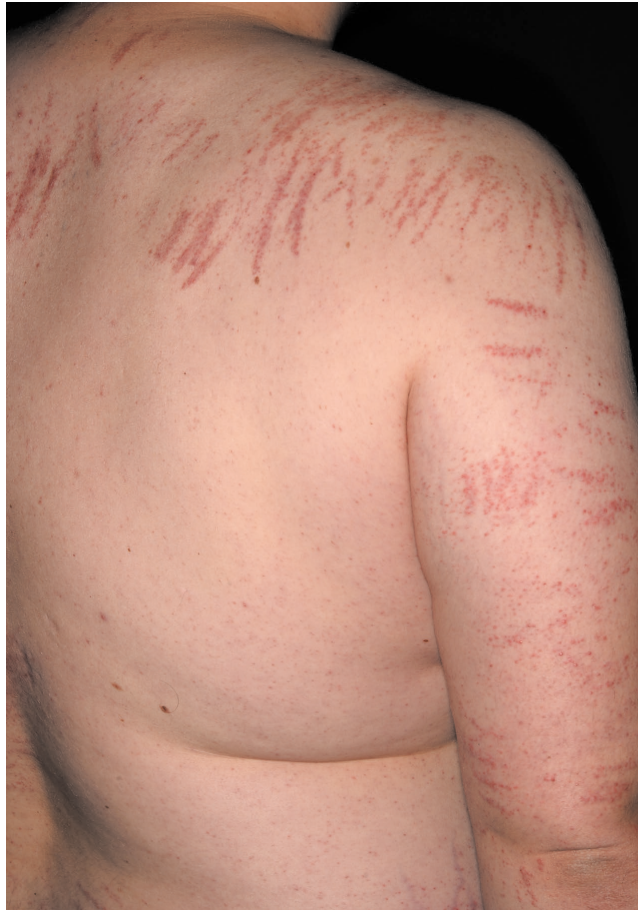

Figure 13 Sharply demarcated erythematous streaks in a patient with flagellate dermatitis.

Paraphenylenediamine is a highly potent contact allergen in *temptoos* and may cause contact dermatitis with a linear pattern.

By contrast, the allergen found in the henna tree (*Lawsonia inermis*) is actually a very weak contact allergen, which has only rarely been reported to cause contact dermatitis.

Flagellate dermatitis

The term “flagellate dermatitis” derives from medieval penitents who practiced self-flagellation. The condition is characterized by linear, intensely pruritic papules with an urticarial appearance and surrounding erythema. The lesions look like scratch marks and frequently arise on the trunk (Figure 13). The scalp and face are spared.

This disease is not well understood. Pathogenetically, it has been proposed that exogenous damage to the epidermis and type IV hypersensitivity to fungal antigens play a key role. Flagellate dermatitis may be caused both by lentinan, a thermosensitive substance found in raw shiitake mushrooms (*Lentinus edodes*), as well as by bleomycin, a chemotherapeutic agent derived from *Streptomyces verticillus* [50]. Diagnosis is usually made clinically and is supported by a detailed history (bleomycin treatment, long-distance travel, visits to Asian restaurants).

Treatment is guided by the clinical presentation and includes corticosteroids and antipruritic agents [51].

Flagellate dermatitis shows a linear pattern resembling a whiplash.

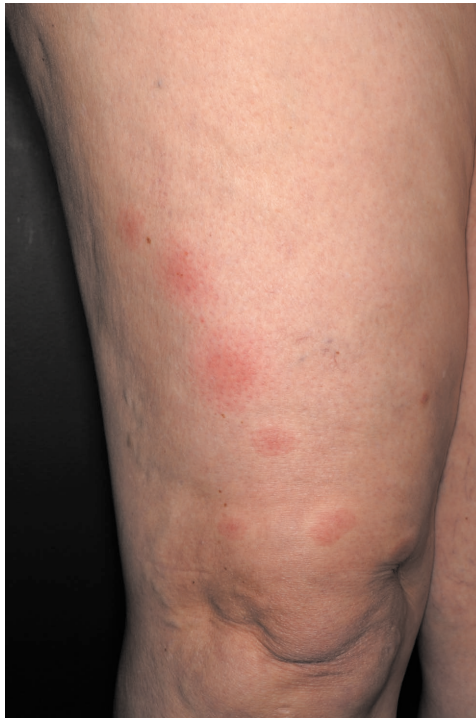

Figure 14 Grouped, light-red papules with an urticarial appearance (and a central bite site) arranged in a linear manner in a patient bitten by bedbug.

Urticarial papules arranged in a linear fashion are suspicious for bedbug bites.

Bedbugs

Onset of an intensely pruritic dermatosis overnight, with lesions that are initially urticarial, subsequently become papular and that are arranged in a linear fashion, is highly suspicious for bedbug bites. The urticarial papules with a central hemorrhagic bite site (Figure 14) are caused by the blood-sucking bedbug *Cimex lectularis* whose saliva contains the allergen nitrophenol. Pustules and blisters may subsequently develop. Sites primarily affected are those that are not covered by nightclothes, including hands, arms and face. It has been shown that the lesions are triggered by IgE-mediated delayed-type hypersensitivity to nitrophenol [52]. Pest control exterminators are frequently required to get rid of the problem. Treatment is symptomatic.

Cutaneous larva migrans

Cutaneous larva migrans describes the penetration of larvae of various parasites into the skin. Larvae are contracted most frequently in subtropical regions following contact with contaminated soil or sand. Skin lesions are associated with severe pruritus and present as serpiginous, edematous papulovesicles whose distribution follows the tracks of the larvae. The feet and the gluteal region are predilection sites, as they are most commonly exposed to larvae-infested sand. Impetiginization may render it difficult to identify the tracks as such.

Migration of parasitic larvae through the skin leaves erythematous tracks.

Diagnosis is based on clinical presentation and occupational/travel history. A biopsy will show the epidermal tunnel, an eosinophilic infiltrate or even larvae. In Europe, cutaneous larva migrans is most commonly caused by the hookworm *Ancylostoma duodenale*. Treatment is usually symptomatic and includes albendazole, ivermectin or physical modalities [53].

Other skin diseases presenting with a linear pattern

There are also skin diseases that occur along blood or lymphatic vessels:

Sporotrichosis is caused by the fungus *Sporothrix schenckii* and its subsequent spread along lymphatic vessels. The primary lesion develops at the portal of entry and presents as an ulcerated nodule. The occurrence of similar "satellite lesions" along the draining lymphatic vessels points to the diagnosis. Regional lymphadenopathy is common.

Atypical mycobacteriosis, too, is characterized by spread of the causative agent along lymphatic vessels. Individual lesions are arranged in a sporotrichoid pattern and present as painless red nodules.

Lymphangitis describes the inflammation of dermal and subcutaneous lymphatic vessels, usually caused by bacteria or noxious agents. Clinically, it is typically characterized by a painful erythematous streak.

Conclusion

Numerous skin diseases may present with a linear pattern. Identification and differentiation of the various linear skin patterns and their associated dermatoses play an important diagnostic role and constitute a key competence of dermatologists.

References

- 1 Wollenberg A, Eames T. Skin diseases following a Christmas tree pattern. *Clin Dermatol* 2011; 29: 189–94.
- 2 Wilhelmi BJ, Blackwell SJ, Phillips LG. Langer's lines: to use or not to use. *Plast Reconstr Surg* 1999; 104: 208–14.
- 3 Plewig G, Ruzicka T, Kaufmann R et al. *Braun-Falco's Dermatologie, Venerologie und Allergologie*. Berlin, Springer, 2018.
- 4 Carmichael SW. The tangled web of Langer's lines. *Clin Anat* 2014; 27: 162–8.
- 5 Wollenberg A, Burgdorf WH, Schaller M et al. Long-lasting "Christmas tree rash" in an adolescent: isotopic response of indeterminate cell histiocytosis in pityriasis rosea? *Acta Derm Venereol* 2002; 82: 288–91.
- 6 Greenberg SA. The history of dermatome mapping. *Arch Neurol* 2003; 60: 126–31.
- 7 Happle R, Assim A. The lines of Blaschko on the head and neck. *J Am Acad Dermatol* 2001; 44: 612–5.
- 8 Chuong CM, Dhouailly D, Gilmore S et al. What is the biological basis of pattern formation of skin lesions? *Exp Dermatol* 2006; 15: 547–64.
- 9 Köbner H. Zur Ätiologie der Psoriasis. *Vjschr Dermatol* 1876; 3: 559.
- 10 Happle R. The Renbök phenomenon. An inverse Köbner reaction observed in alopecia areata. *Eur J Dermatol* 1991; 2: 39–40.
- 11 Wolf R, Brenner S, Ruocco V et al. Isotopic response. *Int J Dermatol* 1995; 34: 341–8.
- 12 Eslick GD. Atypical pityriasis rosea or psoriasis guttata? Early examination is the key to a correct diagnosis. *Int J Dermatol* 2002; 41: 788–91.
- 13 Diluvio L, Vollmer S, Besgen P et al. Identical TCR β -chain rearrangements in streptococcal angina and skin lesions of patients with psoriasis vulgaris. *J Immunol* 2006; 176(11): 7104–11.
- 14 Drago F, Vecchio F, Rebora A. Use of high-dose aciclovir in pityriasis rosea. *J Am Acad Dermatol* 2006; 54: 82–5.
- 15 Pimpinelli N, Olsen E, Santucci M et al. Defining early mycosis fungoides. *J Am Acad Dermatol* 2005; 53: 1053–63.
- 16 Aydogan K, Karadogan SK, Tunali S et al. Narrowband UVB phototherapy for small plaque parapsoriasis. *J Eur Acad Dermatol Venereol* 2006; 20: 573–7.
- 17 Schulz T, Cesarman E. Kaposi Sarcoma-associated Herpesvirus: mechanisms of oncogenesis. *Curr Opin Virol* 2015; 14: 116–28.

Correspondence to

Andreas Wollenberg, MD, PhD
 Department of Dermatology and
 Allergology
 Ludwig Maximilian University
 Frauenlobstraße 9–11
 80337 Munich, Germany
 E-mail: andreas.wollenberg@med
 .uni-muenchen.de

- 18 Holländer E. Beiträge zur Frühdiagnose des Darmcarcinoms (Hereditätsverhältnisse und Hautveränderungen). *Dtsch med Wschr* 1900; 26: 483–5.
- 19 Siedek V, Schuh T, Wollenberg A. Leser-Trelat sign in metastasized malignant melanoma. *Eur Arch Otorhinolaryngol* 2009; 266(2): 297–9.
- 20 Barth G, Basten O, Rüschoff J et al. Klinische und histopathologische Charakteristika des initialen Leser-Trélat-Syndroms. *Hautarzt* 2001; 52: 649–52.
- 21 Onajin O, Comfere NI. Co-occurrence of malignant acanthosis nigricans and the Leser-Trelat sign in a patient with hepatocellular carcinoma. *Int J Dermatol* 2015; 54: e146–8.
- 22 Ersoy-Evans S, Greco M, Mancini A et al. Pityriasis lichenoides in childhood: a retrospective review of 124 patients. *J Am Acad Dermatol* 2007; 56: 205–10.
- 23 Zaaroura H, Sahar D, Bick T et al. Relationship between pityriasis lichenoides and mycosis fungoides: a clinicopathological, immunohistochemical, and molecular study. *Am J Dermatopathol* 2018; 40: 409–15.
- 24 Rudolph C, Al-Fares S, Vaughan-Jones S et al. Polymorphic eruption of pregnancy: clinicopathology and potential trigger factors in 181 patients. *Br J Dermatol* 2006; 154: 54–60.
- 25 Ambros-Rudolph CM, Mullegger RR, Vaughan-Jones SA et al. The specific dermatoses of pregnancy revisited and reclassified: results of a retrospective two-center study on 505 pregnant patients. *J Am Acad Dermatol* 2006; 54: 395–404.
- 26 Ambros-Rudolph CM. Dermatoses of pregnancy. *J Dtsch Dermatol Ges* 2006; 4: 748–59.
- 27 Hale E, Pomeranz M. Dermatologic agents during pregnancy and lactation: an update and clinical review. *Int J Dermatol* 2002; 41: 197–203.
- 28 Fatahzadeh M, Schwartz RA. Human herpes simplex virus infections: epidemiology, pathogenesis, symptomatology, diagnosis, and management. *J Am Acad Dermatol* 2007; 57: 737–63.
- 29 Kroth J, Tischer J, Samtleben W et al. Isotopic response, Kobner phenomenon and Renbok phenomenon following herpes zoster. *J Dermatol* 2011; 38: 1058–61.
- 30 Böhmer D, Seegräber M, Horváth O et al. Bullöses Pemphigoid auf einem ausgeheilten Zoster thoracalis. *Hautarzt* 2020; 71(1): 53–6.
- 31 Widelitz RB, Baker RE, Plikus M et al. Distinct mechanisms underlie pattern formation in the skin and skin appendages. *Birth Defects Res C Embryo Today* 2006; 78: 280–91.
- 32 Happle R. The categories of cutaneous mosaicism: A proposed classification. *Am J Med Genet A* 2016; 170A: 452–9.
- 33 Gimelbrant A, Hutchinson JN, Thompson BR et al. Widespread monoallelic expression on human autosomes. *Science* 2007; 318: 1136–40.
- 34 Happle R. Superimposed segmental manifestation of both rare and common cutaneous disorders: a new paradigm. *Actas Dermosifiliogr* 2009; 100 (Suppl 1): 77–85.
- 35 Happle R. Progressive osseous heteroplasia is not a Mendelian trait but a type 2 segmental manifestation of GNAS inactivation disorders: A hypothesis. *Eur J Med Genet* 2016; 59: 290–4.
- 36 Poblete-Gutierrez P, Wiederholt T, König A et al. Allelic loss underlies type 2 segmental Hailey-Hailey disease, providing molecular confirmation of a novel genetic concept. *J Clin Invest* 2004; 114: 1467–74.
- 37 Happle R. Superimposed segmental manifestation of polygenic skin disorders. *J Am Acad Dermatol* 2007; 57: 690–9.
- 38 Fantl G. Lichen striatus: Beitrag zur Kenntnis der strichförmigen Hauterkrankungen. *Dermat Wschr* 1914; 58: 539.
- 39 Happle R, Rogers M. Epidermal nevi. *Adv Dermatol* 2002; 18: 175–201.
- 40 Mitsuhashi Y, Katagiri Y, Kondo S. Treatment of inflammatory linear verrucous epidermal naevus with topical vitamin D₃. *Br J Dermatol* 1997; 136: 134–5.
- 41 Vissers W, Muys L, Van Erp P et al. Immunohistochemical differentiation between inflammatory linear verrucous epidermal nevus (ILVEN) and psoriasis. *Eur J Dermatol* 2004; 14: 216–20.
- 42 Groesser L, Herschberger E, Ruetten A et al. Postzygotische HRAS und KRAS Mutationen verursachen Nevi sebacei und Schimmelpennyng Syndrome. *Nat Genet* 2012; 44: 783.

- 43 Hgel H, Requena L. Ductal carcinoma arising from a syringocystadenoma papilliferum in a nevus sebaceus. *Am J Dermatopath* 2003; 25: 490–3.
- 44 Conte MI, Pescatore A, Paciolla M et al. Insight into IKBKG/NEMO locus: report of new mutations and complex genomic rearrangements leading to incontinentia pigmenti disease. *Hum Mutat* 2014; 35: 165–77.
- 45 Yang Y, Guo Y, Ping Y et al. Neonatal incontinentia pigmenti: Six cases and a literature review. *Exp Ther Med* 2014; 8: 1797–806.
- 46 Wollenberg A, Baumann L, Plewig G. Linear atrophoderma of Moulin: a disease which follows Blaschko's lines. *Br J Dermatol* 1996; 135: 277–9.
- 47 Rompel R, Mischke A, Langner C et al. Linear atrophoderma of Moulin. *Eur J Dermatol* 2000; 10: 611–3.
- 48 Kaddu S, Kerl H, Wolf P. Accidental bullous phototoxic reactions to bergamot aromatherapy oil. *J Am Acad Dermatol* 2001; 45: 458–61.
- 49 Werfel S, Przybilla B, Wollenberg A. Schwere allergische Kontaktdermatitis durch temporäre Henna-Tätowierungen. *Allergo J* 2002; 11: 325–30.
- 50 Mowad C, Nguyen T, Elenitsas R et al. Bleomycin-induced flagellate dermatitis: a clinical and histopathological review. *Br J Dermatol* 1994; 131: 700–2.
- 51 Hiernickel C, Metz S, Elsner P. Shiitake-Dermatitis: Ein eindrcklicher Fallbericht. *J Dtsch Dermatol Ges* 2015; 5: 455–6.
- 52 Leverkus M, Jochim RC, Schad S et al. Bullous allergic hypersensitivity to bed bug bites mediated by IgE against salivary nitrophenol. *J Invest Dermatol* 2006; 126: 91–6.
- 53 Fischer S, Nenoff P. Larva migrans cutanea: Erfolgreiche topische Behandlung mit Ivermectin – eine Kasuistik. *J Dtsch Dermatol Ges* 2016; 14: 622.

[CME-Questions/Lernerfolgskontrolle]

1. Zu den Dermatosen, die in den Blaschko-Linien verlaufen, gehört **nicht?**

- a) Polymorphe Schwangerschaftsdermatose (PUPPP)
- b) Inflammatorischer linearer verruköser Epidermalnaevus (ILVEN)
- c) Incontinentia pigmenti
- d) Atrophoderma linearis Moulin
- e) Streifen- und wirbelförmige nävöide Hypermelanose

2. Welche Antwort ist richtig?

- a) Die Spaltlinien entstehen aufgrund eines genetischen Mosaiks.
- b) Die Blaschko-Linien werden insbesondere in der Dermatochirurgie herangezogen, da sie angeben, wo die Haut am besten heilt.
- c) Dermatome entstehen durch hämatogene Aussaat.
- d) Eine Kontaktdermatitis weist nie ein lineares Muster auf.
- e) Blaschko-Linien sind kutane Manifestationen genetischer Mosaik, die während der Embryogenese entstehen.

3. Welche Aussage zum Renbök-Phänomen ist falsch?

- a) Das Renbök-Phänomen wird auch als inverser Köbner-Effekt bezeichnet.
- b) Das Renbök-Phänomen bezeichnet eine spezifische Reaktion, die durch ein unspezifisches Trauma getriggert wird.
- c) Das Renbök-Phänomen wurde von Rudolf Happle erstmals beschrieben.
- d) Das Renbök-Phänomen beschreibt das Aussparen einer generalisierten Hauterkrankung im Bereich einer vorbestehenden, unabhängigen, umschriebenen Hauterkrankung.
- e) Renbök ist das Palindrom des Wortes Köbner.

4. Welche Antwort ist richtig?

- a) Durch Mechanismen der Anbindung können Dermatosen, die typischerweise diffus auftreten, in einem spezifischen linearen Muster auftreten.
- b) Der Köbner-Effekt wurde erstmals von Ronni Wolf beschrieben.
- c) Die isotope Reaktion beschreibt eine durch starkes Kratzen auftretende Hautveränderung.
- d) Tritt eine unabhängige Erkrankung im Areal einer vorbestehenden Hauterkrankung auf, wird dies als Renbök-Phänomen bezeichnet.
- e) Erstbeschreiber der Langer-Linien war Sir Henry Head.

5. Welche Aussage zu Dermatosen in den Spaltlinien ist richtig?

- a) Die Blaschkitis ist die häufigste Form der linearen Dermatosen in den Spaltlinien.
- b) Die Pityriasis rosea ist eine häufige, gutartige, akut auftretende und selbst limitierende Dermato- se mit Manifestation in den Blaschko-Linien.
- c) Bei der linearen polymorphen Schwangerschaftsdermatose (PUPPP) treten die Hautveränderungen bevorzugt in den Striae distensae und unter Aussparung des Bauchnabels auf.
- d) Das Leser-Trélat-Syndrom weist immer auf einen Tumor hin und ist deshalb ein sehr guter paraneoplastischer Marker.
- e) Die Latenz zwischen Medikameneinnahme und Exanthem beim DRESS ist mit etwa 2 bis 6 Stunden ungewöhnlich kurz.

6. Welche Antwort ist falsch?

- a) Ein Lichen ruber kann sich im Rahmen einer isotopen Reaktion in einem Dermatom manifestieren.
- b) Eine großflächige dermale Graft-versus-Host-Erkrankung

kann sich unter Aussparung eines Dermatoms manifestieren (Renbök-Phänomen).

- c) Die Atrophoderma linearis Moulin geht typischerweise mit starker Entzündung, Induration und Sklerose einher.
- d) Die Hautveränderungen der streifen- und wirbelförmigen nävöiden Hypermelanose folgen den Blaschko-Linien.
- e) Epidermale Naevi sind Ausdruck eines genetischen Mosaiks.

7. Welche Antwort ist falsch?

- a) Die Phakomatosis pigmentokeratocica Happle beschreibt die seltene Kombination eines Naevus spilus (Schachbrett-Muster) und eines Naevus sebaceus (Blaschko-Muster).
- b) Bei der Phakomatosis pigmentokeratocica Happle ist eine Nachsorge nicht nötig, da es nie zur Entartung kommt.
- c) Der Inflammatorische lineare verruköse Epidermalnaevus (ILVEN) geht typischerweise mit Juckreiz einher.
- d) Lichen striatus bildet sich in der Regel spontan zurück.
- e) Sekundärtumoren auf Nävi sebacei wurden häufig beschrieben, insbesondere das Trichoblastom und das Syringocystadenoma papilliferum.

8. Welche Antwort ist richtig?

- a) Eine phototoxische Dermatitis entsteht durch das Einwirken eines Photosensibilisators und UV-Exposition.
- b) Die Furocumarine stellen keine wichtigen Photosensibilisatoren dar.
- c) Die Flagellanten-Dermatitis manifestiert sich überwiegend palmoplantar.
- d) Kontaktdermatitiden auf Lawson im "echten/roten" Henna sind weitaus häufiger beschrieben als auf

Paraphenyldiamin im "falschen/schwarzen" Henna.

- e) Die Shiitake-Dermatitis tritt nur auf, wenn der Pilz gekocht wurde.

9. Welche Antwort ist richtig?

- a) Bei atypisch langem Verlauf einer Pityriasis rosea ist an eine Mycosis fungoides zu denken.
- b) Die Mycosis fungoides zeigt sich klassischerweise in den Blaschko-Linien.
- c) Die durch den Pilz *Sporothrix schenckii* verursachte Sporotrichose entsteht durch die Verbreitung des Erregers entlang der Blutgefäße.
- d) Bei Incontinentia pigmenti spielt die Anamnese und Untersuchung der Mutter keine Rolle.

- e) Das *christmas tree pattern* beschreibt den umbilikalen Anteil der Blaschko-Linien.

10. Welche Aussage ist falsch?

- a) Die Substanz Nitrophenol wurde als relevantes Allergen der Spättypreaktion auf Wanzenstiche herausgestellt.
- b) Bei der Incontinentia pigmenti sind alle weiblichen und männlichen Embryonen lebensfähig.
- c) Die Atrophoderma linearis Moulin weist im Regelfall eine gute Prognose auf, sodass zumeist keine Therapie erforderlich ist.
- d) Beim Köbner-Phänomen triggert ein unspezifisches Trauma eine spezifische, chronisch-entzündliche Hauterkrankung

- e) Bei Pityriasis rosea ist die Durchführung einer Immunfluoreszenz-Untersuchung zur Diagnosesicherung nicht notwendig.

Liebe Leserinnen und Leser, der Einsendeschluss an die DDA für diese Ausgabe ist der 12. Juni 2020. Die richtige Lösung zum Thema „Vulvamalignome: eine interdisziplinäre Betrachtung“ in Heft 12 (Dezember 2019) ist: (1b, 2d, 3b, 4c, 5a, 6d, 7d, 8c, 9c, 10e).

Bitte verwenden Sie für Ihre Einsendung das aktuelle Formblatt auf der folgenden Seite oder aber geben Sie Ihre Lösung online unter <http://jddg.akademie-dda.de> ein.
