



# International Journal of Applied Sciences and Biotechnology

A Rapid Publishing Journal

ISSN 2091-2609



**Available online at:**

<http://www.ijasbt.org>

&

<http://www.nepjol.info/index.php/IJASBT/index>

## **Indexing and Abstracting**

CrossRef, Google Scholar, Global Impact Factor, Genamics, Index Copernicus, Directory of Open Access Journals, WorldCat, Electronic Journals Library (EZB), Universitätsbibliothek Leipzig, Hamburg University, UTS (University of Technology, Sydney): Library, International Society of Universal Research in Sciences (EyeSource), Journal Seeker, WZB, Socolar, BioRes, Indian Science, Jadoun Science, Jour-Informatics, Journal Directory, JournalTOCs, Academic Journals Database, Journal Quality Evaluation Report, PDOAJ, Science Central, Journal Impact Factor, NewJour, Open Science Directory, Directory of Research Journals Indexing, Open Access Library, International Impact Factor Services, SciSeek, Cabell's Directories, Scientific Indexing Services, CiteFactor, UniSA Library, InfoBase Index, Infomine, Getinfo, Open Academic Journals Index, HINARI, etc.

**CODEN (Chemical Abstract Services, USA): IJASKD**

Vol-2(2) June, 2014

IC Value: 4.37





Research Article

## HEPATOPROTECTIVE EFFECT OF *ALCHORNEA CORDIFOLIA* LEAF ON LIVER DAMAGE IN ALBINO RATS

J. M. Jacob<sup>1</sup>, M. T. Olaleye<sup>2</sup> and J. A. O. Olugbuyiro<sup>3\*</sup>

<sup>1</sup>Department of Chemistry, University of Agriculture, Abeokuta, Nigeria

<sup>2</sup>Department of Biochemistry, Federal University of Technology, Akure, Nigeria

<sup>3</sup>Department of Chemistry, Covenant University, P. M. B. 1023, Ota, Nigeria

Corresponding author email: joseph.olugbuyiro@covenantuniversity.edu.ng

### Abstract

**Ethnopharmacological relevance:** The dry leaf of *Alchornea cordifolia* (AC) is used, in traditional medicine in the S Nigeria, for the preparation of blood tonic, remedies for urinary, respiratory, liver and gas intestinal disorders. **Aim of the study:** This study investigated the protective property of AC leaf against liver damage in animals with a view to exploring its use for the treatment of hepatotoxicity in humans. **Material and methods:** Ethanol extract of *A. cordifolia* was used to study the hepatoprotective activity in acetaminophen-induced Albino rats (150-200g). Animals in Group 1 served as vehicle control, Group 2 served as hepatotoxin (Acetaminophen 2g/kg treated) group, Groups 3 and 4 served as positive control (Vitamin E and Curcumin 100 mg/kg bw respectively) groups, and Groups 5-8 served as (200-500mg/kg bw) AC leaf extract treated groups while Group 9 served as normal group (AC extract only 300 mg/kg bw). **Results:** The hepatotoxic group showed hepatocytic necrosis, cellular infiltration and inflammation in the liver. The treatment group restored the liver cells to their normal lobular architecture in a dose dependent manner. The protection offered by the plant extract compared well with the standard antioxidant agents (Curcumin and Vitamin E). Tannins, flavonoids, alkaloids and saponins were detected in the phytochemical screening. **Conclusion:** Our findings suggest *Alchornea cordifolia* ethanol leaf extract as promising herpatoprotective herb and give credence to the folkloric use of this plant for the treatment of liver problems.

**Key words:** *Alchornea cordifolia*, Acetaminophen-induced liver, Hepatoprotective plants.

### Introduction

*Alchornea cordifolia* belongs to the family of Euphobiaceae. It is commonly called Christmas bush and also known as “Pepe” or “Ijan” in western part of Nigeria. It is a shrub that grows to 8 meters tall with brown stem and heart shaped leaves. It grows extensively in open places with good sunlight especially in the forest. It is widely distributed throughout tropical Africa where it is used extensively in traditional medicine for the treatment of diseases (Ogungbamila, 1990). Some of its traditional uses include treatment of cancer, yaws, gum inflammatory and conjunctivitis, ulcers and wounds (Burkill, 1994; Neuwinger, 2000). *Alchornea cordifolia* plant is of great importance to the health of individuals and communities. It is used in the preparation of remedies for vomiting, purge, toothache and wounds (Iwu, 1993). The dry leaves combined with other plants are used to produce blood tonic. It is also used in the preparation of remedies for urinary, respiratory, liver and gas intestinal disorders (Iwu, 1993). Its antibacterial activity on *staphylococcus aureus* and *Escherichia coli* was attributed to isopentenyl guanidine (Lamikara et al., 1990). Other conditions for which the plant

has enjoyed wide use are cough, gonorrhoea, rheumatic pains, fever and bronchial troubles (Ogungbamila, 2004).

Drug-induced liver toxicity is a common cause of liver injury. It accounts for approximately one-half of the cases of acute liver failure and mimics all forms of acute and chronic liver disease (Kaplowitz, 2001). Different types of drugs such as acetaminophen, chloroquine and isoniazid are inducing toxicity in humans (Tasduq et al., 2005). Acetaminophen (Paracetamol) has been linked with hepatotoxicity when doses are high and this leads to liver damage. The analgesic acetaminophen causes a potentially fatal, hepatic centrilobular necrosis when taken in overdose (James et al., 2003). There is a growing interest in herbal remedies because of their effectiveness, minimal side effects in clinical experience and relatively low cost. This study evaluated the hepatoprotective effect of *Alchornea cordifolia* leaf on acetaminophen-induced liver toxicity in albino rats.

### Materials and Methods

#### Plant material

The fresh green leaves of *Alchornea cordifolia* were collected from uncultivated farm land located at Obaekere, off FUTA south gate in Akure, Ondo State. The plant

samples were identified and authenticated by Mr. Aduloju in the Department of crop Science and Pest Management, Federal University of Technology in Akure, Nigeria. Voucher Specimen (no. AC2005) are kept in the Biochemistry laboratory. The plant leaves were air-dried at room temperature and ground into mesh size of 1 mm using Thomas Wiley milling machine. The plant extract was prepared by cold maceration of 1.0 kg of dried powdered sample in 4.5 L of ethanol for 3 days. It was filtered and evaporated *in vacuo* at 45°C. The ethanol extract was weighed and kept in the refrigerator for further analyses.

#### Phytochemical screening

Phytochemical investigation of the plant leaf was carried out by the standard procedures (Harborne, 1984 and Evans, 1996).

#### Animals

Wistar male albino rats (150-200g) were used for the animal models. They were obtained from the Department of Animal Production and Health, Federal University of Technology, Akure. They were housed individually in cages, fed with standard rat pellets and water was allowed *ad libitum*. All animals were cared for by a veterinarian in

accordance with the “Guide for the Care and Use of Laboratory Animals” (NIH publication 85-23, revised 1985; EEC Directive of 1986; 86/609/EEC). Forty five animals were used and they were randomly divided into nine sub-groups of five each (Table 1).

#### Induction of hepatotoxicity

Hepatotoxin (acetaminophen, 2 g/kg bw) solution was prepared in sterile distilled water and administered to all the groups except control followed by the plant extract (PE) of varying dosages (200-500 mg/kg bw) which was administered to all the groups except the intoxicated control (acetaminophen only). Vitamin E and curcumin (100 mg/kg bw) were used as standard drugs in this study for a period of 15 days.

#### Histopathological studies

Rats were sacrificed 24 hours after administration on day 15. The livers were excised quickly and fixed in 10% formalin and stained with haematoxylin and eosin and then observed under microscope for degeneration, fatty changes, necrotic changes and evidence of hepatotoxicity if any. The sectioning method described by Lamb (1991) was used for the histological examination.

**Table 1:** Experimental design

S.N.	Group	No. of rats	Treatment
1.	Control	5	Normal saline
2.	Hepatotoxic control	5	Hepatotoxin (Acetaminophen 2 g/kg)
3.	Standard group	5	Toxin + Vitamin E (100 mg/kg)
4.	Standard group	5	Toxin + Curcumin (100mg/kg)
5.	Treatment group	5	Toxin + Plant extract (200mg/kg)
6.	Treatment group	5	Toxin + Plant extract (300mg/kg)
7.	Treatment group	5	Toxin + Plant extract (400mg/kg)
8.	Treatment group	5	Toxin + Plant extract (500mg/kg)
9.	Normal group	5	Plant extract only (300mg/kg)

**Table 2:** Screened natural products from *Alchornea cordifolia* leaf

Class	Intensity
Tannins	+++
Phlobatannins	-
Flavonoids	++
Alkaloids	++
Anthraquinones	-
Saponins	+

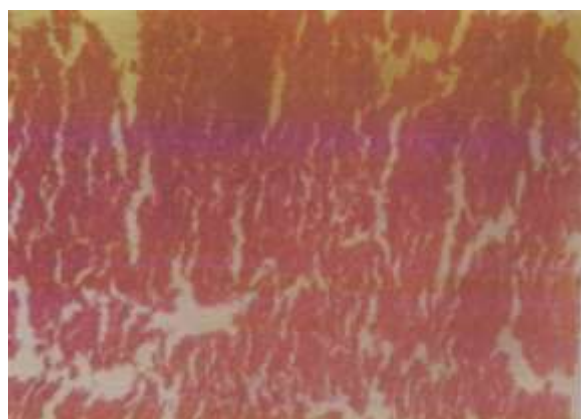
Key: +++ = high, ++ = moderate, + = mild, -- = absent

**Table 3:** Histopathological results of the livers of albino rats treated with *Alchornea cordifolia*, compared with controls

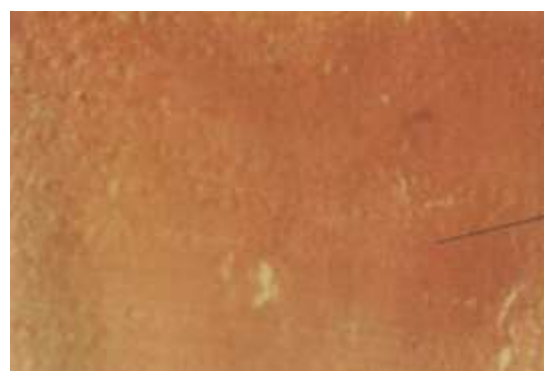Group	Description	Observation
1	Control	Normal
2	Hepatotoxin (2g/kg of paracetamol)	Cellular infiltration, necrosis, disorientation of parenchyma tissue of liver, vacuolar formation in the parenchyma
3	Toxin + Vitamin E (100mg/kg)	Normal orientation
4	Toxin + Curcumin (100mg/kg)	Normal
5	Toxin + Plant extract (200mg/kg)	Some level of cellular infiltration and vacuolar formation features
6	Toxin + Plant extract (300mg/kg)	Normal
7	Toxin + Plant extract (400mg/kg)	Normal
8	Toxin + Plant extract (500mg/kg)	Normal
9	Plant extract only (300mg/kg)	Normal

## Results

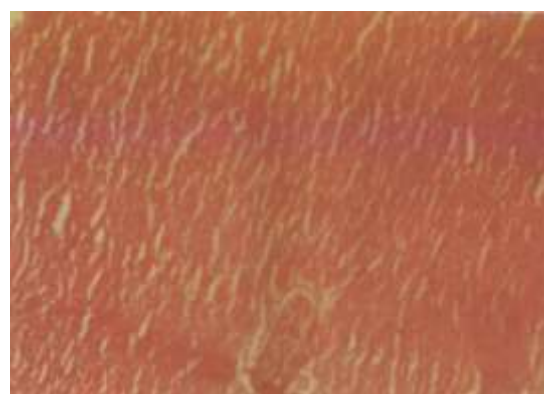The classes of compounds detected in the *Alchornea cordifolia* leaf are displayed in Table 2. Results of the histopathological studies are shown in Table 3 and the Figures (1-9). In Table 3, the hepatocytes of the normal control group showed a normal lobular architecture of the liver (Fig. 1). In the hepatotoxin control (Group 2), the liver showed hepatocytic necrosis and vacuolar formation was also observed in the parenchyma of the liver (Fig. 2). The group treated with 200 mg/kg plant extract (PE) showed minimal inflammation with moderate lobular architecture (Fig. 5). Vitamin E and curcumin treated groups (Fig. 3 and Fig. 4) showed normal hepatocytes and their lobular architecture was normal. Other test groups (Groups 6-9, Fig 6-9) demonstrated good healing property on the liver damage by restoring their lobular architecture to normal without any trace of inflammation.



**Fig. 1:** Hepatocytes of the normal control group showed normal lobular architecture of the liver.




**Fig. 2:** Hepatocytes of the 2 g/kg Acetaminophen treated group showed liver cell necrosis and inflammation with disorientation of parenchyma tissue of the liver.

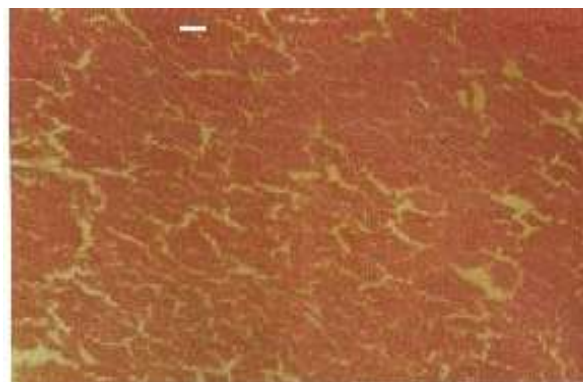


**Fig. 3:** Hepatocytes of the 100 mg/kg Vitamin E pretreated group showed normal hepatocytes and their lobular architecture was normal.

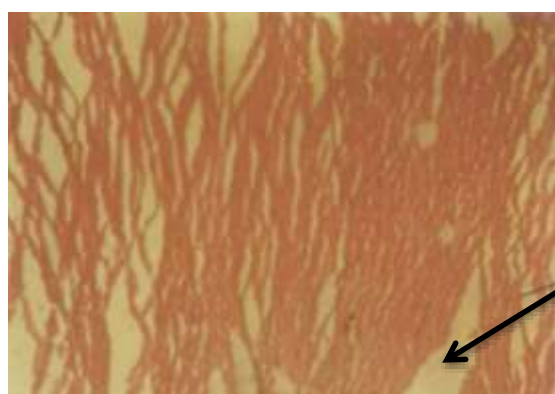




**Fig. 4:** Hepatocytes of the 100 mg/kg Curcumin pretreated group showed normal hepatocytes and their lobular architecture was normal..



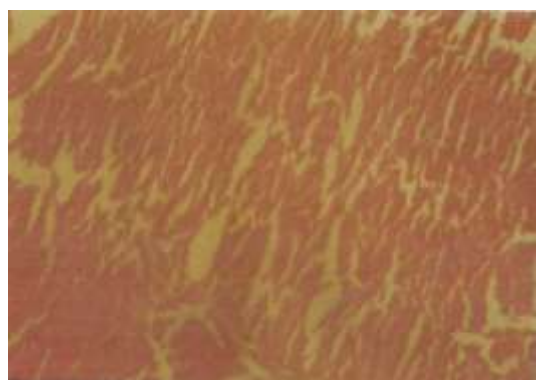
**Fig. 8:** Hepatocytes of the 500 mg/kg PE pretreated group showed normal lobular architecture




**Fig. 5:** Hepatocytes of the 200 mg/kg PE pretreated group showed some level of cellular



**Fig 9:** Hepatocytes of the 300 mg/kg PE only treated group showed normal lobular architecture of the liver



**Fig. 6:** Hepatocytes of the 300 mg/kg PE pretreated group showed normal lobular architecture of the liver.



**Fig. 7:** Hepatocytes of the 400 mg/kg PE pretreated group showed normal lobular architecture

## Discussion

Acetaminophen causes hepatic necrosis in high doses. The US Food and Drug Administration (FDA), concerned about the incidence of acute liver failure due to acetaminophen (Tylenol) overdose, has mandated new labeling on acetaminophen packaging. It has also considered reducing the maximum daily dose from 4 g possibly to 3,250 mg (Schilling *et al.*, 2010). The hepatotoxicity of acetaminophen is due to the induction of the action of promoters in the epidermis. Free radicals cause cell damage through mechanisms of covalent binding and pre-oxidation with subsequent tissue injury. Higher percentage of paracetamol molecules are oxidized to highly reactive N-acetyl-p-benzoquinoneimine which can covalently bind to macromolecules of cellular membrane and increase lipid peroxidation resulting in the liver damage (Diadelis *et al.*, 1995). Phenolic compounds like ellagic acid and protocatechuic acid have been identified as parts of the constituents of *Alchornea cordifolia* (Ogungbamila and Samuelsson, 1990; Lamikara *et. al*; 1990; Banzouzi *et. al*, 2002). Phenolics and flavonoids have been proved to possess antioxidant property (Hagase and Kato, 1984; Yen and Duh, 1993).

Therefore, the presence of phenolics and flavonoids in the ethanol leaf extract of *Alchornea cordifolia* could be

responsible for the hepatoprotective activity. Hepatocellular disintegrate and the inflammation in the liver was observed in the centrilobular region by histopathological examination in paracetamol induced toxic group. However, administration of ethanolic extracts at doses 200-500 mg/kg prevented the induction of histopathological injuries in paracetamol pretreated animals.

## Conclusion

The hepatotoxic protection offered by the *Alchornea cordifolia* leaf extract was strong and compared well with the standard antioxidant agents (Vitamin E and Curcumin). The findings support the folkloric use of *A. cordifolia* for the treatment of liver problems. Further work is in progress to purify the crude drug for possible enhancement of the potency and reduction in the dosage.

## Conflict of interest

We declare that we have no conflict of interest.

## Acknowledgments

We thank Mr. Aduloju in the Department of Crop Science and Pest Management, Federal University of Technology, Akure, for help to identify and authenticate the plant. We also appreciate Dr. Osho and Mr. Adesida in the Department of Animal Production and Health, for technical support.

## References

- Banzouzi JT, Prado R, Menan H, Valentin A, Roumestan C, Malle M, Pallissier, Y, Blache, Y, 2002 *In vitro* antiplasmodia activity of extracts of *Alchornea cordifolia* and identification of active constituents; ellagic acid. *Journal of Ethnopharmacology*. **81**: 399-400. DOI: 10.1016/S0378-8741(02)00121-6
- Burkill HM (1994) The useful plants of West Tropical Africa, third ed. Vol. 2. Royal Botanic Gardens, Kew.
- Diadelis R, Jan NM, Commandeur ED, Groot N and Vermeulen PE (1995) Mechanism of protection of lobenzarit against paracetamol-induced toxicity in rat hepatocytes. *European Journal of Pharmacology: Environmental Toxicology and Pharmacology*. **293**: 301-308. DOI: 10.1016/0926-6917(95)90049-7
- Evans WC (1996) Trease and Evans' pharmacognosy fourteenth ed. W.B. Saunders Co, Singapore.
- Harborne JB (1984) Phytochemical methods second ed. Chapman & Hall, London. DOI: 10.1007/978-94-009-5570-7
- Hayes F and Kato H (1984) Antioxidative components of sweet potatoes. *Journal of Nutritional Science and Vitaminology*. **30**: 37-46. DOI: 10.3177/jnsv.30.37
- James LP, Mayeux PR and Hinson JA (2003) Acetaminophen-induced hepatotoxicity. *Drug metabolism and Disposition*. **31**: 1499-1506. DOI: 10.1124/dmd.31.12.1499
- Kaplowitz N (2001) Drug-induced liver disorders: implications for drug development and regulation. *Drug Safety*. **24**: 483-90. DOI: 10.2165/00002018-200124070-00001
- Lamb GM (1991) Manual of Veterinary Laboratory Techniques in Kenya. CIBA-CEGY, Kenya.
- Lamikar A, Ogundani AO and Ogungbamila FO (1990) Antibacterial constituents of *Alchornea cordifolia*. *Phytotherapy research*. **4**: 198-200. DOI : 10.1002/ptr.2650040508
- Madani H, Talebolhosseini M, Asgary S and Nader GH (2008) He-patoprotective activity of *Silybum marianum* and *Cichorium intybus* against thioacetamide in rat. *Pak J Nutrition*. **7**: 172-176. DOI: 10.3923/pjn.2008.172.176
- Neuwinger HD (2000) African Traditional Medicine- A dictionary of plant use and Applications. Stuttgart, Germany.
- Ogungbamila FO and Samuelsson G (1990) Smooth muscle relaxing flavonoids from *Alchornea cordifolia*. *Acta Pharmaceutica Nordica*. **2**: 421-422.
- Schilling A, Corey R, Leonard M and Eghtesad B (2010) Acetaminophen old drug, new warnings. *Cleveland Clin J Med*. **77**: 19-27. DOI: 10.3949/ccjm.77a.09084
- Tasduq SA, Peerzada K, Koul S, Bhat R and Johri RK (2005) Biochemical manifestation of anti-tuberculosis drugs induced hepatotoxicity and the effect of Silymarin. *Hepatology Research*. **31**: 132-135. DOI: 10.1016/j.hepres.2005.01.005
- Yen GC and Duh PD (1993) Ant oxidative properties of metabolic extracts from peanuts hulls. *Journal of the American Oil Chemists' Society*. **70**: 383-386.