

ORIGINAL ARTICLE

PROTECTIVE EFFECT OF AQUEOUS EXTRACTS OF *AFRAMOMUM MELEGUETA* ON γ -RADIATION-INDUCED LIVER DAMAGE IN MALE WISTAR RATS

Nwozo S. O.¹✉, Yakubu O. F.¹, Oyinloye B. E.^{1,2}

¹ Nutritional and Industrial Research Laboratories, Department of Biochemistry, Faculty of Basic Medical Science, College of Medicine, University of Ibadan, Ibadan, Nigeria

² Department of Biochemistry, College of Science, Afe Babalola University, Ado Ekiti, Nigeria

Received 2nd February 2013.

Revised 20th August 2013.

Published 6th September 2013.

Summary

This study was carried out to evaluate the radioprotective potential of aqueous extract of seeds of *Aframomum melegueta* (A.M.) against gamma radiation-induced (6Gy) liver damage in male Wistar rats. Thirty male rats were randomly distributed into six groups of five animals each and aqueous extract of A.M. was administered at a dose of 200 or 400 mg/kg b. wt., orally for 2 weeks prior to irradiation and 4 weeks after irradiation, when they were sacrificed. The hepatic antioxidant status; reduced glutathione (GSH), catalase (CAT) and glutathione peroxidase (GPx) as well as the extent of lipid peroxidation (LPO) were estimated. The activities of serum alanine aminotransferase (ALT) and aspartate aminotransferase (AST) were determined and histological examination was carried out. Exposure of animals to irradiation significantly increased LPO levels in comparison with the normal control group, reduced the level of GSH as well as CAT and GPx activity. On the other hand, there was a significant elevation in the activities of serum ALT and AST after irradiation exposure. Administration of aqueous extract of A.M. at a dose of 200 or 400 mg/kg before and after irradiation significantly decreased the elevated levels of LPO, restored GSH level near normal and enhanced CAT and GPx activities as well as significantly decreasing the elevated levels of serum ALT and AST activities. The histological examination and results from this study collectively indicate that aqueous extracts of A.M. could protect the liver from radiation-induced damage probably by enhancing the hepatic antioxidant defense mechanism in rats.

Key words: Aframomum melegueta; antioxidants; gamma radiation; oxidative stress; radioprotection.

INTRODUCTION

Exposure to ionizing radiation, either accidentally, intentionally for therapeutic purposes, occu-

pational hazard or as warfare threat, is of deep concern to mankind. The adverse effects of radon, uranium on miners, especially with reference to lung cancer, lymphatic and hematopoietic tissue malignancies are well documented in the literature [1, 2]. Also, a lot of interest has been generated worldwide in the area of radioprotection for the first responders whenever they are on the site emergencies. A chief modality in radiotherapy for the treatment of cancer faces major drawbacks mainly due to the severe side effects generated as a result

✉ University of Ibadan,
Department of Biochemistry, Ibadan, Nigeria
sonwozo@yahoo.com
234-802-3658-268
234-2-810-3043

of normal-tissue damage [3]. Most radiation-induced changes arise from an interaction of free radicals with biological molecules. Molecules with the ability to scavenge free radicals can therefore serve as radioprotective molecules in preventing radiological damage [4 - 8].

Aframomum melegueta is a tropical herbaceous perennial plant of the genus *Aframomum* belonging to the family zingiberaceae (ginger family). Some common names are Grains of paradise, Melegueta pepper, Alligator pepper, Guinea grains or Guinea pepper and in South east of Nigeria, it is called Osei-oji. The dark brown seeds engulfed in fleshy pods have pungent peppery taste due to aromatic ketones [9]. The nutritional, antinutrients and antimicrobial studies of some of the Nigerian spices has been done [10 - 12]. Antimicrobial activity of the seed of *Aframomum melegueta* has been attributed to the presence of phenolic compounds and remain the standard with which other bactericides are compared [13]. Extracts from *Aframomum melegueta* have been used to treat wounds and prevent infections [14]. The present study investigates the radioprotective potentials of *Aframomum melegueta* on γ -radiation-induced liver damage in male Wistar rats.

MATERIALS AND METHOD

Preparation of plant extracts

Freshly harvested seeds of *Aframomum melegueta* were obtained from Ojoo market, in Ibadan, Nigeria and were identified and authenticated in the Herbarium of the Botany Department, University of Ibadan. Seeds were air dried in the laboratory at ambient conditions; two kilograms of the seeds were pulverized into powder using a manual Corona hand grinder in the laboratory. One kilogram from crushed seeds was extracted with 1500 ml of distilled water by being macerated for 72 hours using distilled water. The aqueous seed extract was concentrated on a Buchi Rotavap R114 at 60°C under reduced pressure. The percentage yield was 4.9%. The extract was dissolved in normal saline and aliquots of different concentrations were given orally by gavage.

Chemicals

Thiobarbituric acid (TBA), Ellmans reagent (DTNB), glutathione (GSH) and bovine serum

albumin (BSA) were purchased from Sigma Chemical (St Louis, MO, USA). Randox alanine aminotransferase (ALT), aspartate aminotransferase (AST), and triglyceride (TG) assay kits were purchased from ABJ Chemicals (Lagos, Nigeria). All other chemicals were commercially available at the highest purity.

Animals

Thirty male Wistar rats weighing between 173-225 g were purchased from the Animal House of the Physiology Department, University of Ibadan, (Ibadan, Nigeria). The animals were housed in well ventilated cages at room temperature, were maintained on normal laboratory chow (Ladokun Feeds, Ibadan, Nigeria) and water *ad libitum*.

Irradiation

The animals were exposed to a single dose of 600 rads (6 Gy) of whole-body gamma radiation from a ⁶⁰Co source gamma chamber (Model 220, Atomic Energy of Canada Ltd.) used in the Radiotherapy unit of the University College Hospital (Ibadan, Nigeria). Unanaesthetized rats were kept immobilized in a specially designed well-ventilated acrylic container and irradiated in a group of 5 rats which was arranged in a way that ensured each received equal unilateral exposure; the source to skin distance was 70cm.

Experimental design

The rats were randomly distributed into six groups of 5 animals each. Group I (CL) served as a negative control and received saline solution only; Group II (RA) was a positive control irradiated by 6Gy, Group III (A.M. 200 mg/kg b. wt) was administered with A.M. extract 200 mg/kg b. wt, Group IV (RA + A.M. 200 mg/kg b. wt) was irradiated by 6Gy and treated with A.M. extract 200 mg/kg b. wt, Group V (A.M. 400 mg/kg b. wt) received A.M. 400 mg/kg b. wt while; Group VI (RA + A.M. 400 mg/kg b. wt) was irradiated by 6Gy and applied with A.M. 400 mg/kg b. wt. The rats were weighted prior to the commencement of the experiment and at the end of the experiment.

Preparation of serum, tissue and histological samples for analysis

Twenty eight days after irradiation, the animals were sacrificed 24 hours after the last dose of the extract by cervical dislocation. Blood samples were

collected into plain centrifuge tubes (obtained from ABJ Chemicals, Lagos, Nigeria) by heart puncture and were allowed to stand for 1 hour for complete clotting. The clotted samples were centrifuged at 3,000 g for 15 minutes to separate the serum, which was subsequently used for the assays. Liver samples were quickly incised and washed in ice-cold 1.15% KCl (Sigma Chemical, St Louis, MO, USA) solution, dried using filter paper and weighed. The incised tissues were then homogenized in 4 volumes of 56 mM Tris-HCl (Sigma Chemical, St Louis, MO, USA) buffer (pH 7.4) containing 1.15% KCl, and then centrifuged at 10,000 g for 15 minutes. The supernatants were collected and stored at -20 C until analyzed. Small pieces of liver sections were fixed in with 10% neutral buffered formalin (ABJ Chemicals, Lagos, Nigeria) for histological assessment which was carried out in the Department of Veterinary Anatomy, University of Ibadan, (Ibadan).

Biochemical assays

Quantification of the protein was performed by Biuret method [15] with bovine serum albumin (Sigma Chemical, St Louis, MO, USA) (BSA) as standard. Lipid peroxidation was assayed by measuring thiobarbituric acid reactive substances (TBARS) as described by Varshney and Kale [16], Catalase (CAT) activity was done by measuring the rate of decomposition of hydrogen peroxide

at 570 nm as described by Sinha, [17]. Reduced glutathione (GSH) level was determined by measuring the rate of formation of chromophoric product in a reaction between DTNB (Sigma Chemical, St Louis, MO, USA) (5,5'-dithiobis- (2-nitrobenzoic acid) and free sulphhydryl groups at 412 nm [18]. GPx was determined by the method by Hafeman et al. [19] based on the degradation of H₂O₂ (Sigma Chemical, St Louis, MO, USA) in the presence of GSH.

Statistical analysis

All values were expressed as the mean ± S.D. Data were analyzed using One-way analysis of variance (ANOVA) followed by the post-hoc LSD test for analysis of biochemical data using SPSS (Statistical Package for the Social Sciences®; SPSS Inc, Chicago, IL) version 10.0 statistical software. P < 0.05 was considered statistically significant.

RESULT

No animal died prior to scheduled sample collection. Group II (positive control) showed significantly decreased body weight as well as a significant decrease in protein contents (serum and liver) as compared to group I (negative control, Table 1).

Table 1. Effect of A.M. on Body Weight, Serum and Liver protein (mean ± S.D., n = 5)

Groups	Percentage body weight Increase (%)	Protein, mg/g	
		Serum	Liver
Group I	12.11	6.17 ± 0.30 ^b	2.47 ± 0.27 ^b
Group II	-11.57	4.79 ± 0.61 ^a	1.84 ± 0.20 ^a
Group III	11.94	4.87 ± 0.19 ^a	2.24 ± 0.25 ^{a,b}
Group IV	8.50	5.35 ± 0.30 ^a	2.58 ± 0.24 ^{a,b}
Group V	10.26	5.55 ± 0.29 ^{a,b}	2.63 ± 0.23 ^{a,b}
Group VI	6.71	4.75 ± 0.18 ^b	2.34 ± 0.15 ^{a,b}

Mean differences are significant (P<0.05) when compared with: a control group (CL), b irradiated group (RA)

Exposure to radiation caused a significant increase in lipid peroxidation levels (group II) compared with the negative control group. Administration of varying dose of A.M. before and after radiation (group III – VI) revealed significant reduction in lipid peroxidation levels when compared with the positive control, but still, the values were higher than in negative control animals (Table 2).

In the same manner, data on ALT and AST activity revealed that radiation exposure resulted in a significant elevation of activities of both in serum compared with the negative control, while treatment with varying dose of A.M. before and after radiation (group III –VI) led to a significant reduction in the elevated levels of ALT and AST activities compared with the positive control (Table 2).

Table 2. Effect of A.M. on hepatic LPO levels and serum ALT and AST activities (mean ± S.D., n = 5)

Groups	LPO (nmol/mg/protein)	ALT (UI/L)	AST (UI/L)
Group I	6.02 ± 0.80	18.21 ± 1.01 ^b	24.33 ± 2.08 ^b
Group II	12.38 ± 0.23 ^a	32.00 ± 0.7 ^a	51.00 ± 1.41 ^a
Group III	6.81 ± 0.6 ^b	20.45 ± 0.63 ^{a,b}	26.67 ± 0.58 ^b
Group IV	8.48 ± 0.48 ^{a,b}	27.20 ± 1.19 ^{a,b}	31.5 ± 1.73 ^b
Group V	6.46 ± 0.20 ^b	20.00 ± 1.01 ^{a,b}	26.33 ± 0.58 ^b
Group VI	8.16 ± 0.19 ^{a,b}	22.91 ± 0.27 ^{a,b}	28.00 ± 1.4 ^b

Mean differences are significant (P<0.05) when compared with: a control group (CL), b irradiated group (RA)

Furthermore, a significant reduction was observed in GSH level as well as CAT and GPx activities of irradiated animals compared with the negative control. Interestingly, A.M.

supplementation before and after radiation showed a significant elevation in the GSH level as well as CAT and GPx activities when compared with the positive control group (Table 3).

Table 3. Effect of A.M. on hepatic antioxidant system (mean ± S.D., n = 5)

Groups	GSH (nmol/mg protein)	CAT (U/mg protein)	GPx (nmol/mgprotein/min)
Group I	23.30 ± 0.86	298.00 ± 18.37 ^b	95.45 ± 3.85 ^b
Group II	10.75 ± 0.59 ^a	222.82 ± 8.37 ^a	90.55 ± 0.18 ^a
Group III	22.67 ± 0.38 ^b	301.18 ± 1.93 ^b	94.20 ± 4.06 ^b
Group IV	19.67 ± 0.52 ^{a,b}	291.70 ± 27.51 ^b	92.43 ± 1.80 ^b
Group V	26.5 ± 0.94 ^b	301.17 ± 12.37 ^b	95.10 ± 4.31 ^b
Group VI	23.50 ± 0.66 ^b	292.27 ± 17.26 ^b	94.50 ± 3.91 ^b

Mean differences are significant (P<0.05) when compared with: a control group (CL), b irradiated group (RA)

The histological examination of H&E stained tissue sections showed that animals pre-treated with the varying dose of A.M. following radiation exposure showed minimal damage with a recovery pattern in a dose-dependent manner compared with radiation-exposed animals (Fig. 1)

DISCUSSION

Exposure to radiation generates reactive oxygen species (such as superoxide radicals, hydroxyl radicals, iron oxygen complexes, hydrogen peroxide and lipid peroxides) resulting in oxidative damage to cell membranes, disturbance in metabolism as well as in structure and function of body organs [20 - 22]. Different medicinal plants have been evaluated for

their potential effects as a radioprotective agent. To our knowledge, no studies have been done to investigate the protective role of aqueous extract of *Aframomum melegueta* against a gamma radiation (6Gy) induced liver damage.

The observed changes in body weight of the rats given the plant extract prior to irradiation and after irradiation shows the aqueous extract of *Aframomum melegueta* has a significant effect of controlling the loss of body weight which is caused during irradiation. Membrane lipids succumb easily to deleterious actions of reactive oxygen species (ROS). [23] (Reiter, 1995). It is an established fact that increases in ROS generation as a result of radiation exposure may adversely interfere with protein metabolism probably by inhibiting the synthesis of proteins such as albumin in the liver.

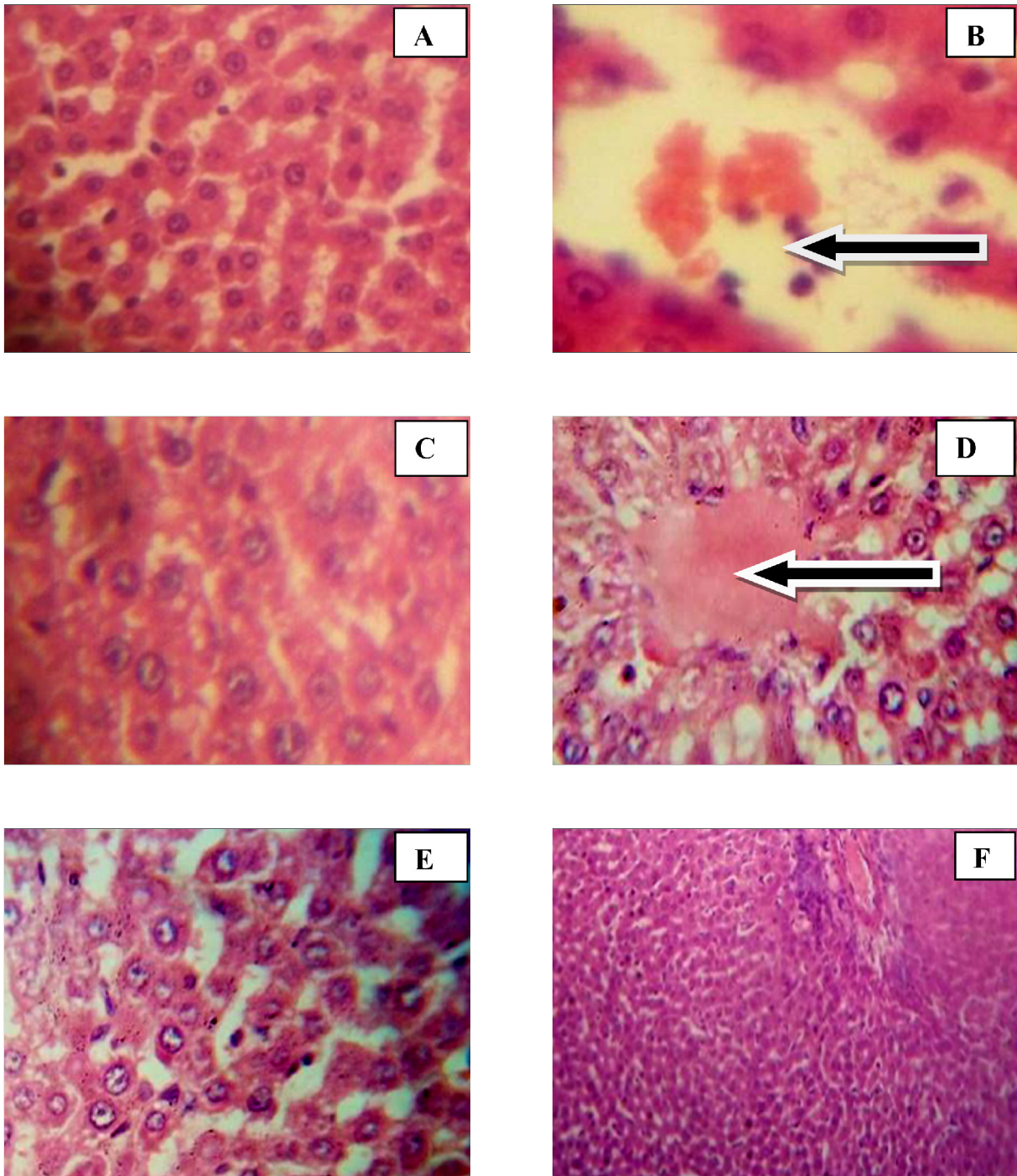


Figure 1. Histological analysis of liver sections. Liver tissues were stained with H&E ($\times 400$).

- A. Group 1: showing normal liver histology, no abnormalities was seen.
- B. Group 2: showing massive and severe sinusoid infiltration by inflammatory cells.
- C. Group 3: showing normal liver histology.
- D. Group 4: showing mild congestion in the venule and fat deposit.
- E. Group 5: showing normal liver histology.
- F. Group 6: showing mild infiltration of inflammatory cells, fair normal histology.

Therefore, decrease in serum and liver protein might be a result of excessive free radicals generated during exposure and subsequent changes in the permeability of the liver cells [24, 25].

Results from the present study demonstrated that exposure to radiation led to an increase in the level of lipid peroxidation. This is an indication that there was an overwhelming effect of the pro-oxidant on the endogenous antioxidant system which resulted in oxidative stress. Inhibition of lipid peroxidation observed when animals were treated with A.M. extract could be attributed to the presence to the free radical scavenging properties and the antioxidant activities of the extract that decreased the overload on the endogenous body antioxidants. The observed result is in agreement with earlier studies [26, 27].

In the present study, exposure to gamma radiation (6 Gy) induced hepatotoxicity as manifested by increase in serum ALT and AST. The marked elevation in the levels of serum ALT and AST as a result of exposure to radiation might be due to the release of these enzymes from the cytoplasm into the blood circulation rapidly after rupture of the plasma membrane and cellular damage [28, 29]. The significantly decreased ALT and AST activities in animals treated with varying dose of A.M. extract suggests that the extract is not toxic or does not compromise the integrity of the liver but is possibly hepatoprotective [30, 31]

On the other hand, irradiation caused a decrease in the level of hepatic GSH as well as CAT and GPx activity. Our results confirm those previously reported [32 - 34]. The liver is a vital organ of the body which reflects radiation-induced changes. GSH plays an important role in the antioxidant effects, nutrient metabolism and regulation of cellular events [35]. Perturbation of the GSH status of a biological system has been reported to have deleterious effect [36]. Decrease in level of GSH reduces the capacity of the antioxidative systems and increases the vulnerability of hepatic tissue, particularly to oxidative stress.

GSH effectively scavenges free radicals and other oxygen species through nonenzymatic and enzymatic process. GPx utilizes it for the decomposition of lipid hydroperoxides and other reactive oxygen species (ROS) and glutathione-S-transferase (GST) maximizes the conjugation of free radicals and various lipid hydroperoxides to GSH to form water-soluble products that can be easily excreted out, [34].

Consistently with our biochemical findings, results obtained from the histological examinations suggest that treatment with A.M. extract prior and after irradiation ameliorate the extent of hepatocellular damage as a result of radiation exposure.

Taken together, administration of *Aframomum melegueta* at a dose of 200 or 400 mg/kg showed a general protective and ameliorative effect of gamma radiation-induced liver damage. 400 mg/kg would be recommended for future use since there is no evidence of toxicity at this dose. The protective and ameliorative effect of *Aframomum melegueta* could be attributed to the bioactive constituents present in the extract which possibly acts as a free radical scavenger.

REFERENCES

1. Guseva Canu, I.; Jacob, S.; Cardis, E.; Wild, P.; Caer, S.; Auriol, B.; Garsi, J.P.; Tirmarche, M.; Laurier, D. Uranium carcinogenicity in humans might depend on the physical and chemical nature of uranium and its isotopic composition: results from pilot study of French Nuclear workers. *Cancer Causes Control*. **2011**, 20 (11), 1563 - 1573.
2. Miller, A.C.; Cohen, S.; Stewart, M.; Rivas, R.; Lison, P. Radioprotection by the histone deacetylated inhibitor phenylbutyrate. *Radiat Environ biophys*. **2011**, 50 (4), 585 - 596.
3. Mauch, C.; Krieg, T.; Bauer, E.A. Role of the extracellular matrix in the degradation of connective tissue. *Arch Dermatol Res*. **1994**, 287, 107 - 114.
4. Tiwari, P.; Kumar, A.; Ali, M.; Mishra, K.P. Radioprotection of plasmid and cellular DNA and Swiss mice by silibinin. *Mutat Res*. **2010**, 695 (1-2), 55 - 60.
5. Alcaraz, M.; Acevedo, C.; Castillo, J.; Benavente-Garcia, O.; Armero, D.; Vicente, V.; Canteras, M. Liposoluble antioxidants provide an effective radioprotective barrier. *Br. J Radiol*. **2009**, 82 (979), 605 - 609.
6. Rubiolo, J.A.; Vega, F.V. Resveratrol protects primary rat hepatocytes against necrosis induced by reactive oxygen species. *Biomed Pharmacother*. **2008**, 62 (9), 606 - 612.
7. De la Lastra, C.A.; Villegas, I. Resveratrol as an antioxidant and pro-oxidant agent: mechanisms and clinical implications. *Biochem Soc Trans*. **2007**, 35 (5), 1156 - 1160.

8. Weiss, J.F.; Landauer, M.R. Radioprotection by antioxidants. *Ann NY Acad Sci.* **2000**, 899, 44 - 60.
9. Galal, A.M. Antimicrobial activity of 6-paradol and related compounds. *Int J Pharmacog.* **1996**, 31, 64 - 69.
10. Oboh, G.; Ekperigin, M.M. Nutritional evaluation of some Nigerian wild seeds. *Nahrung.* **2004**, 48 (2), 85 - 87.
11. Mbosso, E.J.; Ngouela, S.; Nguedia, J.C.; Beng, V.P.; Rohmer, M.; Tsama, E. In vitro antimicrobial activity of extracts and compound of some selected medicinal plants from Cameroon. *J Ethnopharmacol.* **2010**, 128 (2), 476 - 481.
12. Uhegbu, F.O.; Iweala, E.E.J.; Kanu, I. Studies on the chemical and antinutritional content of some Nigerian spices. *Int Journal of Nutrition and Metabolism.* **2011**, 13 (6), 72 - 76.
13. Okwu, D.E. Phytochemicals and vitamin content of Indigenous spices of South Eastern Nigeria. *J. Sustain. Agric. Environ.* **2004**, 6, 30 - 34.
14. Oladunmoye, M.K.; Dada, E.O. Comparative studies on the Antimicrobial activity of leaf extracts from *Aframomum melegueta*. *Research Journal of Botany.* **2007**, 2 (2), 95 - 107.
15. Gornall, A.C.; Bardawill, E.J.; David, M.M.; Determination of serum proteins by means of Biuret reaction. *J Biol Chem.* **1949**, 177, 364 - 365.
16. Varshney, R.; Kale, R.K.; Effects of Calmodulin Antagonists on Radiation- induced Lipid Peroxidation in Microsomes. *Int J Radiat Biol.* **1990**, 58, 733 - 43.
17. Sinha, A.K. Colorimetric assay of catalase. *Anal. Biochem.* **1972**, 47, 389 - 394.
18. Beutler, E. Improved method of determination of blood glutathione. *J Lab Clin Med.* **1963**, 61, 882 - 890.
19. Hafeman, D.G.; Sunde, R.A.; Hoekste, W.G. Effect of dietary selenium on erythrocyte and liver glutathione peroxidase in the rat. *J. Nutr.* **1974**, 104, 580 - 587
20. Refaie, F.M.; Abdel-Hamid, F.M.; Yousri, R.M. Effects of irradiation on liver and kidney functions in rats subjected to cadmium or mercury injection. *Isotope Rad Res.* **1993**, 25, 19-26.
21. Kanshala, P. Cell membrane oxidative damage induced by γ -radiation and apoptotic sensitivity. *J. Environ Pathol Toxicol Oncol.* **2004**, 23, 1-7
22. Mantena SK, Unnikrishnan MK, Joshi R. In vivo radioprotection by 5-aminosalicylic acid. *Mutat Res.* **2008**, 650, 63 - 79.
23. Reiter, R. J. Oxidative processes and antioxidative defuse mechanisms in the aging brain. *Faseb.* **1995**, 9: 526-533.
24. Kafafy, Y.; Ashry, O. Antioxidant potential of parsley on gamma irradiated rats. *Egypt J Rad Sci,* **2001**, 14, 25-42
25. Ramadan, F. Evaluation of the synergistic effect of danazol and radiation exposure on some biochemical functions in female albino rats. *Egypt J Hosp Med.* **2007**, 27, 255 - 262
26. Nwozo, S.O.; Okameme, P. E.; Oyinloye, B.E. Potential of *Piper guineense* and *Aframomum longiscapum* to reduce radiation induced hepatic damage in Male Wistar rats. *Radiats Biol Radioecol.* **2012**, 52 (4), 363 - 369.
27. Hari Kumar, K.B.; Kuttan, R. Protective effect of an extract of *Phyllanthus amarus* against radiation induced damage in mice. *J. Rad. Res.* **2004**, 45, 133 - 139.
28. Sallie, R; Tredger, R, Williams, R. Drugs and the liver. *Biopharm. Drug. Dispos.* **1991**, 12, 251 - 259.
29. kafafy, Y. Protective effect of cytoeime and vitamin E on gamma irradiation injury in rats. *Egypt. J. Rad. Sci. Applic.* **2000**, 13 (2), 17 - 25.
30. Ramadan, L.A.; Roushdy, H.M.; Abu Senna, G.M.; Amin, N.E.; El Deshw, O.A. Radioprotective effect of silymarin against radiation induced hepatotoxicity. *Pharmacol Res.* **2002**, 45, 447 - 454.
31. Ali, S.A.; Fadda, L.M.; Elebiary, H.; Soliman, M. Evaluation of the radioprotective action of anserine along with zinc in albino rats exposed to gamma radiation. *J of Appl Pharmaceutical Sci.* **2012**, 2, 115 - 122.
32. Bhatia AL, Jain M. *Spinacia oleracea* L. Protects against gamma radiations: a study on glutathione and lipid peroxidation in mouse liver. *Phytomedicine* **2004**; 11: 607-615.
33. Hamzaa, R.G.; El Shahat, A.N.; Mekawey, H.M.S. The Antioxidant Role of Mulberry (*Morus alba* L.) Fruits in Ameliorating the Oxidative Stress Induced in γ -Irradiated Male Rats. *Biochem Anal Biochem.* **2012**, 1, 122.
34. Wu, G.; Fang, Y.Z.; Yang, S.; Lupton, J.R.; Turner, N.D. Glutathione metabolism and its implications for health. *J Nutr.* 134, **2004**, 489 - 492.
35. Sreepriya, M.; Devaki, T.; Balakrishnana, K.; Apparanantham, T. Effect of *Indigofera tinctoria* Linn. on liver antioxidant defense system during D galactosamine / endotoxin-induced acute hepatitis in rodents. *Indian J Exp Biol.* **2001**, 39, 181 - 4.
36. Ahmed, S.; Rahman, A.; Alam, A.; Saleem, M.; Athar, M.; Sultana, S. Evaluation of the efficacy of *Lawsonia alba* in the alleviation carbon tetrachloride induced oxidative stress. *J Ethnopharmacol.* **2000**, 69, 157 - 64.