

## RESEARCH

# Cherubism: panoramic and CT features in adults

M Redfors<sup>\*,1,2</sup>, J L Jensen<sup>3</sup>, K Storhaug<sup>2</sup>, T Prescott<sup>4</sup> and T A Larheim<sup>1</sup>

<sup>1</sup>Department of Maxillofacial Radiology, Faculty of Dentistry, University of Oslo, Blindern, Oslo, Norway; <sup>2</sup>National Resource Centre for Oral Health in Rare Medical Conditions, Lovisenberg Diakonale Hospital, Oslo, Norway; <sup>3</sup>Department of Oral Surgery and Oral Medicine, Faculty of Dentistry, University of Oslo, Oslo, Norway; <sup>4</sup>Department of Medical Genetics, Oslo University Hospital, Nydalen, Oslo, Norway

**Objectives:** To describe the panoramic radiographic and CT features of cherubism in an unselected series of 15 adults.

**Methods:** In this cross-sectional study, 15 individuals aged 29–84 years with familial non-syndromal molecularly confirmed cherubism were examined with panoramic radiography and CT. Bone abnormalities were analysed and described.

**Results:** 11 (73%) of the 15 adults had mandibular abnormalities. These abnormalities ranged from subtly detectable to severe, and were less prevalent and expansive but could be rather similar to the characteristic image features in children. Unilocular radiolucencies were more common than multilocular radiolucencies, and a specific feature of these abnormalities was that they were exclusively found in the anterior mandible.

**Conclusions:** The radiographic and CT abnormalities of cherubism in adults were frequent and extremely heterogeneous, with some distinct features.

*Dentomaxillofacial Radiology* (2013) **42**, 20130034. doi: 10.1259/dmfr.20130034

**Cite this article as:** Redfors M, Jensen JL, Storhaug K, Prescott T, Larheim TA. Cherubism: panoramic and CT features in adults. *Dentomaxillofac Radiol* 2013; **42**: 20130034.

**Keywords:** cherubism; radiology; computed tomography; genetics

## Introduction

Cherubism is a rare autosomal dominantly inherited benign regional bone disorder and was first described in 1933 as fibrous dysplasia restricted to the jaws.<sup>1</sup> The major gene associated with cherubism, *SH3BP2*, was reported in 2001.<sup>2</sup> Mutations in the *SH3BP2* gene affect bone remodelling. Normal bone architecture is replaced by fibrous tissue proliferation, including a large number of osteoclasts, and the resulting bone septa give the characteristic multilocular appearance on radiographs.<sup>3</sup> Symmetrical bilateral bone abnormalities vary from minor involvement limited to the rami of the mandible to expansion of both jaws with elevation of the orbital floor.<sup>4,5</sup> Severely affected individuals were originally described as having a “cherubic appearance” with full rounded cheeks and upward gaze deviation. Cherubism

is primarily considered a paediatric disorder, which first manifests around 3 years of age, progresses until puberty and then typically regresses.<sup>6,7</sup> Cherubism is generally considered a self-limiting condition.

To our knowledge, there were only four studies before 2012 in which more than ten individuals were well characterized for cherubism.<sup>7–10</sup> Although these studies included children and adults, they focused mostly on children. Furthermore, diagnostic imaging is generally restricted to panoramic radiography to evaluate bone abnormalities, and only single case reports on comprehensive imaging are available.<sup>11–13</sup> In an article based on a consensus meeting in 2010, it was noted that in severe cases, abnormalities do not always involute during adulthood. On the other hand, it was also shown that abnormalities are frequently undetectable at the age of 30 years.<sup>14</sup>

No comprehensive study of cherubism in an unselected series of individuals seems to have been available until a recently published study on a Norwegian cohort.<sup>15</sup> Because it has been emphasized that an improved understanding of the long-term evolution of

\*Correspondence to: Dr Maria Redfors, Department of Maxillofacial Radiology, Faculty of Dentistry, University of Oslo, PO Box 1109 Blindern, 0317 Oslo, Norway. E-mail: [e.m.c.redfors@odont.uio.no](mailto:e.m.c.redfors@odont.uio.no)

Received 25 January 2013; revised 8 September 2013; accepted 9 September 2013

the disease is required to obtain better prognostic and therapeutic recommendations,<sup>13</sup> thorough investigations of patients with a long history of the disease should be performed. Thus, the aim of the present study is to describe the panoramic radiographic and CT features of cherubism in an unselected series of adults with molecularly confirmed cherubism.

## Materials and methods

A Norwegian cohort of individuals with cherubism was reported recently.<sup>15</sup> The study was approved by the Regional Medical Ethical Committee, South-East B, Norway (S-08864b). Written informed consent was provided by the participants, all of whom had a molecularly confirmed diagnosis.<sup>15</sup> The 15 adults (7 females and 8 males) aged 29–84 years (mean age, 50 years) in this series, belonging to three different families, with a different disease-associated mutation in exon 9 of *SH3BP2* in each family, constituted the sample population of the present study.

Individuals were evaluated using panoramic radiography and CT. The CT examinations were performed using a LightSpeed™ Ultra scanner (GE Medical Systems, Milwaukee, WI) with thin sections of 0.625–1.25 mm, a bone algorithm, and a low current of 40–90 mA. These were viewed in an axial plane and reformatted in oblique-coronal and oblique-sagittal planes and in three-dimensional reconstructions. All panoramic and CT images were studied by two maxillofacial radiologists (TAL and MR) and a consensus image interpretation was made.

To define the localization of bone abnormalities, we divided the jawbones into eight anatomical areas, four in each jaw. The lower molar region, angles of the mandible and ascending rami with coronoid processes were considered as one region. The premolar region and forward in the mandibular body, the premolar region and forward in the alveolar ridge and the condyles constituted the remaining three regions. The maxillary bone was divided into tuber regions, alveolar ridge and palate, maxillary sinuses and maxillary bone in the orbital floors.

Bone abnormalities were defined as multi- or unilocular radiolucencies, with or without expansion, thinning or perforation of the cortical bone. In addition, in areas without radiolucencies, cortical abnormalities such as deformation/irregular outline or thickening and areas of trabecular osteosclerosis were noted.

We classified all individuals according to a well-known and frequently used grading system but had to make a modification. The grading system describes three grades based on the anatomical location and extent of bone abnormalities.<sup>4</sup> In Grade 1, “the lesions are confined to the lower molar region and backward to the coronoid processes”. In Grade 2, “in addition to the lesions of Grade 1, other lesions appear farther forward in the mandible or in the maxillary tuberosities”.

In Grade 3, “both jaws are diffusely affected”. During our image analyses, we found that many lesions occurred predominantly or exclusively in the anterior part of the mandible. Such abnormalities did not fit into the established grading system, and the present authors modified Grade 1 by adding “or only anteriorly in the mandible”.

## Results

Of the 15 adults, 11 (73%) had bone abnormalities (Table 1); these consisted of bilateral abnormalities in 7 cases and unilateral abnormalities in 4. The heterogeneity of bone abnormalities was marked, ranging from small non-expanding unilocular radiolucencies to large expanding multilocular radiolucencies. Abnormalities involved the cortical bone and thinning and/or perforations were seen in all 11 patients, and expansions in 5 of them (Figure 1). In addition, areas of trabecular osteosclerosis were seen in 11 patients and cortical abnormalities in 7, a thick cortical lining in 5 and irregular cortical outlines in 2. The findings are summarised in Table 2.

Two females showed severe abnormalities in the mandible and the maxilla (Figure 2). In one of them, the mandibular condyles were partially involved (Figure 3). This 32 year old patient also had a unilateral multilocular process in the anterior part of the maxilla, extending into the maxillary sinus. The second patient, a 49 year old female, had bilateral multilocular abnormalities in the tuber areas and further anteriorly expanding into the maxillary sinuses and orbits (Figure 4).

The anterior part of the mandible was involved in 9 of the 11 patients with abnormalities, with 5 patients showing abnormalities exclusively in the anterior part. The molar region was involved posteriorly towards the coronoid process in 6 of the 11 patients. Thus, only two patients had involvement exclusively in the posterior part of the mandible.

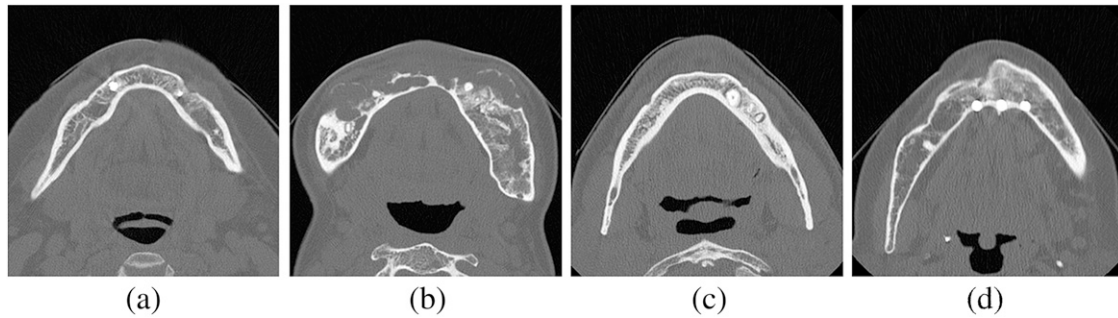
The CT examinations clearly improved the interpretation of bone abnormalities compared with the panoramic examinations. This was particularly true for the anterior region of the mandible and in the tuber regions, maxilla and the orbits. Cortical bone abnormalities could predominantly be evaluated using CT.

Only 3 males aged 49 years, 60 years and 84 years and 1 female aged 70 years showed no signs of jaw bone abnormalities either on the panoramic or on the CT images.

**Table 1** Grading based on the localisation of bone abnormalities in 15 adults with molecularly confirmed cherubism

Grade of cherubism by Seward and Hankey <sup>4</sup>	No. of women (n = 7)	No. of men (n = 8)	Total (n = 15)
1 <sup>a</sup>	4	3	7
2	0	2	2
3	2	0	2
No bone abnormalities	1	3	4

<sup>a</sup>Grade modified: “or only anteriorly in the mandible” added to the original version.



**Figure 1** Axial CT scans of adults aged 32–60 years showing bone abnormalities in the mandible. (a) Small non-expanding unilocular radiolucencies. (b) Large expanding multilocular bone abnormalities perforating and thinning the cortical border. (c) Thick cortical lining and areas of osteosclerosis. (d) Expanded and deformed/irregular cortical outline

### Discussion

To the best of our knowledge, this is the first study of an unselected series of adults with molecularly confirmed cherubism in which comprehensive imaging, *i.e.* panoramic radiography supplemented with CT, has been systematically applied and analysed. In our series of 15 adults who were 29 years or older, bone abnormalities were found in 11, *i.e.* in almost 3 of 4. Bone abnormalities varied substantially, from small unilocular to large multilocular radiolucencies and from unilateral to bilateral abnormalities. In general, bone abnormalities were considerably less pronounced than in the children of the cohort, where the mean grades of involvement<sup>4</sup> were 3.0 for female patients and 2.0 for male patients.<sup>15</sup> However, two females older than 30 years in the present adult series showed massive bone abnormalities, *i.e.* Grade 3,<sup>4</sup> rather similar to but less expansive than those seen in the children. These findings are in contrast to a 36 year long-term follow-up study concluding that the bone structures were predominantly normal in all patients older than 30 years,<sup>7</sup> and the statement in a review article that “at the age of 30 the lesions are frequently not detectable”.<sup>14</sup>

Besides being less severe and less prevalent, the characteristics of bone abnormalities also differed from those in children. Unilocular radiolucencies were more common than multilocular, and the expansion of the cortical border related to the radiolucent area was only noted in five patients and was not as extensive as that found in children. Abnormalities were frequently (more than one-third) asymmetric and characterized by areas of thick cortical bone and osteosclerosis. We are not aware of any other study demonstrating such details of bone abnormalities in a group of adult patients with cherubism.

A specific feature in the adults was the high frequency of abnormalities in the anterior part of the mandible. Such involvement was seen in more than 80% of the individuals with bone abnormalities, and in half of these, exclusively in the anterior mandible. This pattern was not seen in the children of the cohort,<sup>15</sup> and as far as we know, has not been reported by others, except in a case report of a 27 year old female patient.<sup>16</sup> In our experience, this seems to be a rather common finding in adults.

The observation may reflect the healing/remodelling process in these individuals, suggesting that the regression of bone abnormalities starts in the posterior parts of the jaw. However, we cannot exclude that new bone abnormalities might have developed during adulthood, not only in the anterior parts of the mandible but also in the posterior parts of the jaw. A case of an adult female patient who developed new bone abnormalities in the orbital floors has been reported.<sup>17</sup> Bone abnormalities in the anterior mandible may have been underdiagnosed or missed in previous studies because the jaw imaging is usually restricted to panoramic radiography. The anterior part of the mandible is much better evaluated using CT. Our understanding of the natural course of cherubism can only be further clarified by longitudinal studies. Therefore, our intention is to follow individuals prospectively in this cohort.<sup>15</sup>

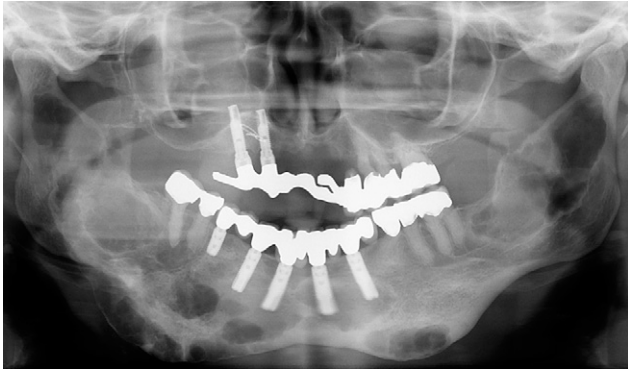
In the present study, we used the grading system published in 1957 by Seward and Hankey.<sup>4</sup> In the literature, we found a widespread incorrect citation in the definition of Grade 2. The original definition says: “In Grade 2 in addition to the lesions of Grade 1, other lesions appear farther forward in the mandible or in the maxillary tuberosities”. Many authors have substituted “or” with “as well as”, which would have meant that Grade 2 always includes abnormalities in the tuber regions. However, a patient classified with Grade 2 does not necessarily have maxillary involvement. In our group of adults, almost all individuals had involvement

**Table 2** Radiographic characteristics of bone abnormalities in 11 adults with molecularly confirmed cherubism<sup>a</sup>

Radiographic characteristics	No. of patients
Multilocular radiolucencies ≥10 mm	2
Multilocular radiolucencies <10 mm	3 <sup>b</sup>
Unilocular radiolucencies ≥10 mm	5 <sup>b</sup>
Unilocular radiolucencies <10 mm	2
Bilateral occurrence	7
Unilateral occurrence	4
Areas with osteosclerosis	11
Areas with cortical abnormalities (thickening or deformation)	7
Areas with cortical expansion	5

<sup>a</sup>Four adults had no bone abnormalities.

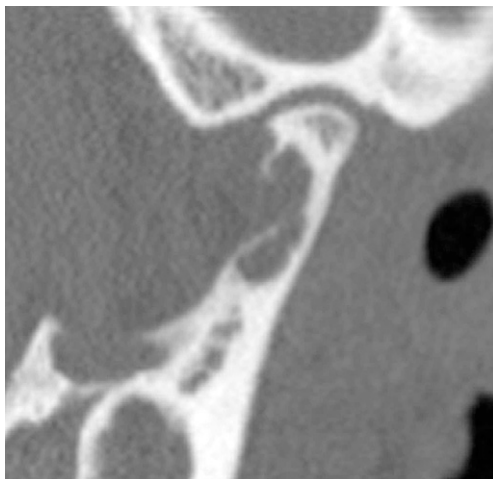
<sup>b</sup>One adult had both unilocular and multilocular radiolucencies.



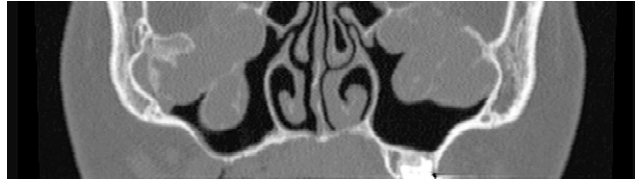
**Figure 2** Panoramic radiograph of a 49 year old female showing severe bone abnormalities in the mandible and in the maxilla

in the anterior part of the mandible, whereas only one had involvement in the tuber area. These would be classified as Grade 2 if they had the involvement of the posterior part of the mandible whether the maxilla was involved or not. However, the subgroup of individuals with abnormalities only in the anterior mandible, which constituted a rather large proportion (one-third), could not be graded according to the grading system used. Traditionally, adults have kept the grade they were given as children.<sup>7,10</sup> Obviously, this does not reflect the dynamic nature of the disease, *i.e.* possible changes from childhood to adulthood. In our opinion, there seems to be a need for a grading system that includes specific abnormalities that may occur in adults. Such a grading system may be useful to predict regression and the possible consequences of the disease.

There are many differential diagnoses that should be considered in patients with suspected cherubism because of multilocular radiolucencies in the jaws. One such condition is Gorlin–Goltz syndrome.<sup>18</sup> The keratocystic odontogenic tumours of this syndrome may be located in both the mandible and the maxilla, bilaterally; they



**Figure 3** Oblique sagittal CT image of a 32 year old female showing bone abnormalities in condylar neck



**Figure 4** Coronal CT image of a 49 year old female showing multilocular bone abnormalities in the maxillary sinuses, elevating the orbital floor bilaterally

may be multilocular and, thus, very similar to cherubism. However, such abnormalities are most often less expansive than those in cherubism. With MRI, one should be able to differentiate between the conditions because the lesions are solid in cherubism, whereas they are cystic in Gorlin–Goltz syndrome.

Another condition with bilateral radiolucencies is Noonan syndrome, which is a well-delineated genetic condition. In the Norwegian cohort of cherubism, one patient identified with the syndrome was excluded after genetic testing.<sup>15</sup>

In cases without a family history and no maxillary involvement, it is impossible to clinically and histologically differentiate between central giant cell granulomas and sporadic cases of cherubism.<sup>19</sup> We would like to add in cases with bilaterality. Multiple central giant cell granulomas of the jaws have been reported as multilocular radiolucencies but are extremely rare and may be caused by hyperparathyroidism, which is associated with elevated levels of serum calcium and parathyroid hormone.<sup>20,21</sup>

In adult patients without a family history, there are a number of odontogenic and non-odontogenic conditions that should be considered as differential diagnoses. These include uni- or multicystic benign tumours (ameloblastomas, myxomas and keratocystic tumours), even radicular cysts.<sup>22</sup> This is particularly important in adults where the radiolucencies may be unilateral or occur only in the anterior part of the mandible, as found in the present study. Even bilateral radiolucencies such as multiple radicular cysts can be difficult to differentiate from adult cherubic bone abnormalities, and the morphology of the involved teeth in cherubism is often atypical and difficult to interpret. This can lead to unnecessary root canal treatment. On the other hand, infected teeth may be ignored if periapical radiolucencies are misinterpreted as cherubic abnormalities. Clinical and radiological follow-ups are necessary for such cases.

In adults with radiolucencies mixed with radiopaque areas, osseous dysplasia should, in our experience, be taken into differential diagnostic consideration. In osseous dysplasia, the radiolucencies seem to be filled with sclerotic bone, in contrast to cherubism, where the osteosclerotic areas are often diffusely delineated and not present within the radiolucent areas. However, florid osseous dysplasia can be extensive and merely radiolucent during the early phase of this disorder. This makes imaging differentiation from cherubism difficult, in

particular if the condition is located in the anterior part of the mandible.

In 2000, it was suggested that CT should be used only in severe Grade 3 cases,<sup>7</sup> *i.e.* in those cases involving both the mandible and the maxilla. In the present study, CT was clearly a supplement to the panoramic examination in characterizing bone abnormalities even in individuals with less severe conditions, such as those with abnormalities limited to the anterior mandible. There has been tremendous improvement in radiographic technology and software support in both digital panoramic radiography and CT, with multiplanar reformation and three-dimensional reconstruction features.<sup>13</sup>

Our CT examinations were performed at a low patient dose (low milliamperere), but we still obtained high-quality bone images. Cone beam CT (CBCT) scanning can even operate at lower milliamperes and smaller fields of view and should therefore be used whenever possible. The CBCT apparatus from our department is operating with fields too small for examining the facial structures in these patients. Many patients with cherubism are in need of treatment, surgical correction of the contours of jaws, removal of displaced or retained teeth, orthodontics and implant treatment. We suggest that the use of advanced modalities should be restricted to situations where it is crucial to ensure optimal treatment for the patient. In

our opinion, it may be appropriate (although not as a routine procedure) to use low-dose CT or CBCT at least once for patients with cherubism to obtain a comprehensive diagnosis. The repeated use of advanced radiology as a routine examination should be avoided. Panoramic examination should be the first choice at follow-up.

In conclusion, this seems to be the first study of a large series of adults with molecularly confirmed cherubism where CT has been systematically used. Imaging features of cherubism occurred in almost 3 of 4 adults aged 29 years to 84 years and were extremely heterogeneous, ranging from subtle to severe bone abnormalities affecting both jaws. In general, the abnormalities were clearly less pronounced than in children. A rather large proportion (one-third) with abnormalities only in the anterior mandible did not fit into the grading system that is frequently applied. Such abnormalities may present with other differential diagnostic problems than are usually thought of in patients with cherubism.

## Funding

The work is funded solely through the University of Oslo, the TAKO Centre, and the University Hospital of Oslo. No external funding was received.

## References

1. Jones WA. Familial multilocular cystic disease of the jaws. *Am J Cancer* 1933; **17**: 946–948.
2. Ueki Y, Tiziani V, Santanna C, Fukai N, Maulik C, Garfinkle J, et al. Mutations in the gene encoding c-Abl-binding protein SH3BP2 cause cherubism. *Nat Genet* 2001; **28**: 125–126. doi: [10.1038/88832](https://doi.org/10.1038/88832)
3. Ayoub AF, el-Mofty SS. Cherubism: report of an aggressive case and review of literature. *J Oral Maxillofac Surg* 1993; **51**: 702–705.
4. Seward GR, Hankey GT. Cherubism. *Oral Surg Oral Med Oral Pathol* 1957; **10**: 952–974.
5. Beaman FD, Bancroft LW, Peterson JJ, Kransdors MJ, Murphy MD, Menke DM. Imaging characteristics of cherubism. *AJR Am J Roentgenol* 2004; **182**: 1051–1054. doi: [10.2214/ajr.182.4.1821051](https://doi.org/10.2214/ajr.182.4.1821051)
6. Caffey J, Williams JL. Familial fibrous swelling of the jaws. *Radiology* 1951; **56**: 1–14.
7. Von Wowern N. Cherubism: a 36-year long-term follow-up of 2 generations in different families and review of the literature. *Oral Surg Oral Med Oral Pathol Oral Radiol Endod* 2000; **90**: 765–772.
8. Peters WJ. Cherubism: a study of twenty cases from one family. *Oral Surg Oral Med Oral Pathol* 1979; **47**: 307–311.
9. Meng XM, Yu SF, Yu GY. Clinicopathologic study of 24 cases of cherubism. *Int J Oral Maxillofac Surg* 2005; **34**: 350–356. doi: [10.1016/j.ijom.2004.09.006](https://doi.org/10.1016/j.ijom.2004.09.006)
10. Roginsky VV, Ivanov AL, Ovtchinnikov IA, Khonsari RH. Familial cherubism: the experience of the Moscow Central Institute for Stomatology and Maxillo-Facial Surgery. *Int J Oral Maxillofac Surg* 2009; **38**: 218–223. doi: [10.1016/j.ijom.2008.10.010](https://doi.org/10.1016/j.ijom.2008.10.010)
11. Bianchi SD, Boccardi A, Mela F, Romagnoli R. The computed tomographic appearances of cherubism. *Skeletal Radiol* 1987; **16**: 6–10.
12. Özan B, Muğlali M, Celenk P, Günhan O. Postpubertal non-familial cherubism and teeth transposition. *J Craniofac Surg* 2010; **21**: 1575–1577.
13. Holst AI, Hirschfelder U, Holst S. Diagnostic potential of 3D-data-based reconstruction software: an analysis of the rare disease pattern of cherubism. *Cleft Palate Craniofac J* 2009; **46**: 215–219. doi: [10.1597/07-015.1](https://doi.org/10.1597/07-015.1)
14. Papadaki ME, Lietman SA, Levine MA, Olsen BR, Kaban LB, Reichemberger EJ. Cherubism: best clinical practice. *Orphanet J Rare Dis* 2012; **7**: 1–14. doi: [10.1186/1750-1172-7-S1-S6](https://doi.org/10.1186/1750-1172-7-S1-S6)
15. Prescott T, Redfors M, Rustad CF, Eiklid KL, Geirdal AØ, Storhaug K, et al. Characterization of the Norwegian cherubism cohort; molecular genetic findings, oral manifestations and quality of life. *Eur J Med Genet* 2013; **56**: 131–137. doi: [10.1016/j.ejmg.2012.12.008](https://doi.org/10.1016/j.ejmg.2012.12.008)
16. Kalantar Motamedi MH. Treatment of cherubism with locally aggressive behavior presenting in adulthood: report of four cases and a proposed new grading system. *J Oral Maxillofac Surg* 1998; **56**: 1336–1342.
17. Schultze-Mosgau S, Holbach LM, Wiltfang J. Cherubism: clinical evidence and therapy. *J Craniofac Surg* 2003; **14**: 201–206.
18. Kiwilsza M, Sporniak-Tutak K. Gorlin-Golz syndrome—a medical condition requiring a multidisciplinary approach. *Med Sci Monit* 2012; **18**: RA145–RA153.
19. de Lange J, van Maarle MC, van den Akker HP, Redeker EJ. DNA analysis of the SH3BP2 gene in patients with aggressive central giant cell granuloma. *Br J Oral Maxillofac Surg* 2007; **45**: 499–500. doi: [10.1016/j.bjoms.2006.03.017](https://doi.org/10.1016/j.bjoms.2006.03.017)
20. Orhan E, Erol S, Deren O, Sevin A, Ekici O, Erdoğan B. Idiopathic bilateral central giant cell reparative granuloma of jaws: a case report and literature review. *Int J Pediatr Otorhinolaryngol* 2010; **74**: 547–552. doi: [10.1016/j.ijporl.2010.02.006](https://doi.org/10.1016/j.ijporl.2010.02.006)
21. De Lange J, Van den Akker HP. Clinical and radiological features of central giant-cell lesions of the jaw. *Oral Surg Oral Med Oral Pathol Oral Radiol Endod* 2005; **99**: 464–470. doi: [10.1016/j.tripleo.2004.11.015](https://doi.org/10.1016/j.tripleo.2004.11.015)
22. Carvalho Silva E, Carvalho Silva GC, Vieira TC. Cherubism: clinicoradiographic features, treatment, and long-term follow-up of 8 cases. *J Oral Maxillofac Surg* 2007; **65**: 517–522. doi: [10.1016/j.joms.2006.05.061](https://doi.org/10.1016/j.joms.2006.05.061)