

Tears of the rotator cuff

Diagnosis, treatment and symptomatic status



By

STEFAN MOOSMAYER

Department of Orthopaedic Surgery

Martina Hansen's Hospital

Bærum 2010

© **Stefan Moosmayer, 2010**

*Series of dissertations submitted to the
Faculty of Medicine, University of Oslo
No. 1033*

ISBN 978-82-8264-104-3

All rights reserved. No part of this publication may be reproduced or transmitted, in any form or by any means, without permission.

Cover: Inger Sandved Anfinsen.
Printed in Norway: AiT e-dit AS.

Produced in co-operation with Unipub.
The thesis is produced by Unipub merely in connection with the thesis defence. Kindly direct all inquiries regarding the thesis to the copyright holder or the unit which grants the doctorate.

Contents

1. Preface	3
2. Acknowledgements	5
3. Abbreviations	7
4. List of papers	8
5. Introduction	9
5.1 Anatomy of the rotator cuff.....	9
5.2 Function of the rotator cuff.....	14
5.3 Tears of the rotator cuff.....	17
▪ Prevalence and pathogenesis.....	17
▪ Classification.....	18
▪ Clinical aspects.....	18
5.4 Diagnostic imaging of the rotator cuff.....	19
5.5 Treatment methods for rotator cuff tears.....	22
6. Aims of the research	27
7. Methods	28
7.1 Imaging methods.....	28
▪ Sonography.....	28
▪ Magnetic resonance imaging.....	29
7.2 Therapeutic methods.....	30
▪ Tendon repair.....	30
▪ Physiotherapy.....	31
7.3 Outcome measures.....	33
▪ Constant score.....	33
▪ ASES score.....	33
▪ SF-36 health survey.....	33
7.4 Statistical methods.....	34
8. Summary of papers	36
9. General discussion	42
9.1 Diagnosis of rotator cuff tears.....	42
9.2 Treatment of rotator cuff tears.....	46
9.3 Asymptomatic rotator cuff tears.....	52
10. Contributions to existing knowledge	58
11. Future research	60
12. References	61
13. Papers	77

1. Preface

Already in the beginning of the 20th century, the rotator cuff was recognized as an important contributor to normal shoulder function, and tears of the rotator cuff as a possible cause of shoulder pain and dysfunction. The classical work of Codman of 1934 (1), which was based on the clinical experience of this orthopaedic surgeon, represents an early and still pertinent documentation of this knowledge. Since then, our understanding of the rotator cuff and its pathologies has been broadened by extensive basic and clinical research. With the introduction of new diagnostic methods, including sonography and MRI, therapeutic decisions can now be based on visualization of the soft parts of the shoulder. Another important development has been the introduction of shoulder arthroscopy. This was initially used as a diagnostic method allowing direct visualization of the intraarticular structures of the glenohumeral joint, but improvements in technology and surgical skills have made it a useful therapeutic tool, and arthroscopic surgery is now widely used in the treatment of pathologies of the rotator cuff.

However, in spite of substantial progress in several fields, some important clinical questions remain unanswered. The place of the different diagnostic techniques in a diagnostic algorithm of rotator cuff pathology is still being discussed. Many of the methods currently used in the treatment of rotator cuff tears have never been tested in high-quality trials, and consequently, scientific support for therapeutic decisions is weak. Little knowledge exists about the natural course of rotator cuff tears, and why some of them are asymptomatic while others cause symptoms. The work presented in this thesis is an exploration of some of these questions.

Papers I and II deal with diagnostic studies. In Paper I we assessed the early learning curve for the detection of full-thickness and partial-thickness tears of the rotator cuff by sonography. Results obtained by an orthopaedic surgeon with little sonographic experience were compared with surgical findings. In Paper II, our aim was to exclude the effects of informational bias on the results of sonographic rotator cuff examination by blinding the sonographer for clinical findings. In Paper III we compared the treatment effects of tendon repair and physiotherapy for full-thickness tears of the rotator cuff up to 3 cm in diameter in a randomized controlled study. Papers IV and V are studies of asymptomatic rotator cuff

tears. In Paper IV we performed a sonographic assessment of the prevalence of asymptomatic rotator cuff tears in a general population without shoulder problems. In Paper V the aim was to isolate tear characteristics associated with symptoms from rotator cuff tears by comparing MRI findings from subjects with and without tear symptoms.

2. Acknowledgments:

Already during my medical training at the Albert-Ludwig University in Freiburg, Germany, where I was first introduced into clinical research, I realised that research might be an alternative to clinical practice for me. During the following years, however, clinical work as an orthopaedic surgeon was exciting enough, and time for realising scientific ambitions was lacking. It was not until 2002, when an appropriate position was advertised at Martina Hansen's Hospital, Bærum, that it became possible for me to develop my interest in research.

My deepest thanks therefore go to the director of Martina Hansen's Hospital and head of the Orthopaedic Department, Dr Arne Ekeland, for choosing me for this position and allowing me to spend a significant number of working hours on clinical research.

I would also like to express my deepest gratitude to my supervisor, Professor Hans-Jørgen Smith, head of the Radiologic Department, Oslo University Hospital, Rikshospitalet, for sharing his extensive knowledge and experience with me, for always finding time in a busy schedule and for his very effective way of finding solutions when I got stuck. His calm and friendly way of guiding me through the pitfalls of medical research is highly appreciated.

I would also like to thank all staff members of the Orthopaedic Department for their contributions, support, encouragement and invaluable discussions. Special thanks go to:

- Gerty Lund, Unni Seljom, Ida Svege and Benjamin Haldorsen of the Department of Physiotherapy for contributing their professional skills and for showing me the possibilities of conservative treatment for shoulder patients,
- Toril Hennig of the Department of Occupational Therapy for her extraordinary reliability and flexibility during follow-up of our patients,
- All my co-authors for contributing their time, knowledge and experience. Working with them has been a great learning experience.

I would like to express my gratitude to Dr Kjell Griegel and Dr Bernd Salkowitsch, who introduced me to the art of orthopaedic surgery at Namsos Hospital, and to all other colleagues who have contributed to my training as an orthopaedic surgeon.

I would like to thank Dr Christoph Kunz, who taught me about musculoskeletal ultrasound and offered me a place in his excellent course in sonography of the shoulder in Germany, which was the starting point for the first paper of this thesis.

I would also like to thank the radiologists Dr Rana Tariq and Dr Morten Stiris for their high-quality analyses of an enormous number of MRI scans, which were done in their free time. Thank you for your helpful attitude and for sharing with me your extensive knowledge of MRI of the shoulder.

I am very grateful to our biostatistician, Dr Ingar Holme, for help with and interesting discussions about statistical analyses.

Furthermore I would like to thank the University of Oslo for its outstanding programme of research education courses. Attending these courses always left me with inspiration and enthusiasm.

Special thanks go to all my study patients for their time, patience and willingness to participate in clinical trials. This work would not have been possible without them.

Most of all I would like to acknowledge my gratitude to my family. To my parents who gave me and continue to give me far more than they know or what I can express in words. To my wife Marta, who fills my life with wisdom and beauty, and to our sons Jonas, Martin and Simon. Allowing me to be a part of your life is the greatest gift you can give me.

3. Abbreviations:

ANCOVA	Analysis of covariance
ASES	American shoulder and elbow surgeons shoulder scale
C	Cervical nerve root
CI	Confidence interval
CSA	Cross-sectional area
CT	Computed tomography
EMG	Electromyography
FOV	Field of view
MHz	Megahertz
MRI	Magnetic resonance imaging
NEX	Number of excitations
OR	Odds ratio
ROM	Range of movement
SD	Standard deviation
SF-36	Short form 36 health survey
SPSS	Statistical package for the social sciences
T	Tesla
TR	Repetition time
TE	Echo time
TSE	Turbo spin echo
VAS	Visual analogue scale

4. List of Papers

Paper I

Moosmayer S, Smith HJ: Diagnostic ultrasound of the shoulder – a method for experts only? *Acta Orthop* 2005;76:503-508.

Paper II

Moosmayer S, Heir S, Smith HJ: Ultrasonography of the rotator cuff in painful shoulders performed without knowledge of clinical information – Results from 58 ultrasound examinations with surgical correlation. *J Clin Ultrasound* 2007;35:20-6.

Paper III

Moosmayer S, Lund G, Seljom U, Svege I, Hennig G, Tariq R, Smith HJ. Comparison between surgery and physiotherapy in the treatment of small and medium-sized tears of the rotator cuff. A randomised controlled study of 103 patients with one year follow-up. *J Bone Joint Surg Br* 2010;92:83-91.

Paper IV

Moosmayer S, Smith HJ, Tariq R, Larmo A: Prevalence and characteristics of asymptomatic tears of the rotator cuff: An ultrasonographic and clinical study. *J Bone Joint Surg Br* 2009;91:196-200.

Paper V

Moosmayer S, Stiris M, Tariq R, Smith HJ. MRI of symptomatic and asymptomatic full-thickness rotator cuff tears: A comparison of findings in 100 subjects. *Acta Orthop* 2010;81(3):361-6.

5. Introduction

5.1 Anatomy of the rotator cuff

The rotator cuff is composed of four muscles, the subscapularis, the supraspinatus, the infraspinatus and the teres minor. From separate origins at the posterior (supraspinatus, infraspinatus and teres minor) and anterior (subscapularis) surfaces of the scapula they run laterally and fuse together with the articular capsule into a common insertion on the tuberosities of the humerus, which is known as the footprint of the rotator cuff (Figure 1) (2).

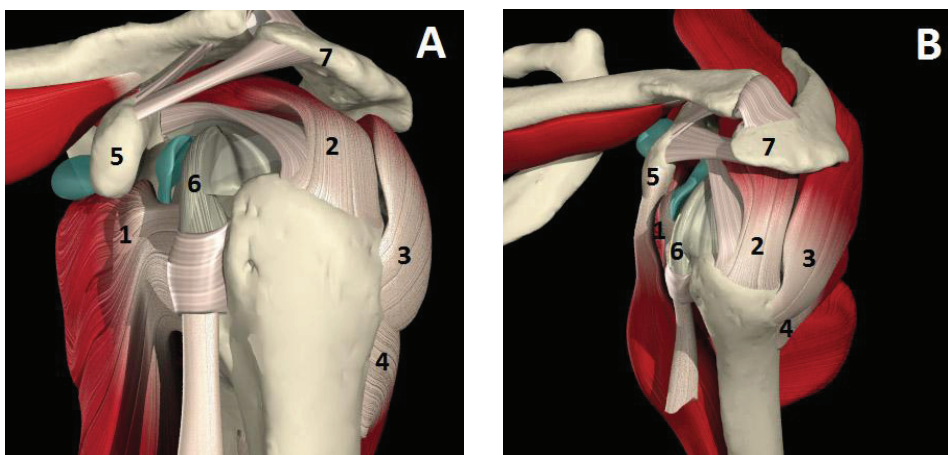


Figure 1. Anatomy of the rotator cuff. True lateral (A) and oblique superior view (B) of the shoulder. 1 = subscapularis muscle, 2 = supraspinatus muscle, 3 = infraspinatus muscle, 4 = teres minor muscle, 5 = coracoid process 6 = long head of the biceps tendon, 7 = acromion (Reproduced after permission from 3D anatomy images, Primal Pictures Ltd., www.primalpictures.com)

Subscapularis muscle

The subscapularis forms the most anterior part of the rotator cuff. It arises from the anterior surface of the scapula. Its muscle belly runs laterally beneath the coracoid process and converges into a tendinous portion at the level of the glenoid, where it also merges with the articular capsule. The subscapularis insertion on the lesser tuberosity is comma-shaped, with measurements of its maximum superior-to-inferior length varying between studies

from 24.3 mm to 40 mm and those of its maximum medial-to-lateral width varying from 16 mm to 20 mm (3-5). It consists of a purely tendinous and intraarticular upper part and a purely muscolocapsular lower part (4). Fibres from the tendinous part extend into the bicipital groove, where they join with fibres from the supraspinatus tendon to form the floor of the bicipital sheath (2). The subscapularis muscle is innervated by the subscapular nerve (C5 – C7).

Supraspinatus muscle

The supraspinatus muscle lies in the supraspinatus fossa of the scapula and forms the superior part of the rotator cuff. It arises from the medial portion and the base of the fossa, passes beneath the acromion and converges into a tendinous portion that merges with the infraspinatus and the articular capsule at its insertion on the anterior part of the greater tuberosity (2). A tendinous slip extends from the anterior-most portion of the supraspinatus and contributes to the roof of the bicipital sheath (2). In about 20% of cases this extension bridges the bicipital groove and inserts on the lesser tuberosity (6;7). The supraspinatus insertion has been found to be triangular, with measurements of its maximum medial-to-lateral length varying between studies from 6.9 to 12.7 mm and for those of its maximum anterior-to-posterior width varying from 12.6 to 25.0 mm (3;7;8). The supraspinatus muscle is innervated by the suprascapular nerve (C4 – C6).

Infraspinatus muscle

The infraspinatus muscle arises from the infraspinatus fossa and from the inferior surface of the spine of the scapula. Together with the teres minor muscle it forms the posterior-inferior part of the rotator cuff. Its distal insertion is on the posterior facet of the greater tuberosity, where it merges and overlaps with the fibres of the supraspinatus and the teres minor. After removal of overlying tissue and thorough dissection, separate footprint areas for each muscle can be defined (4;7). For the infraspinatus, a trapezoidal shaped insertion has been found. Close to its insertion the anterior part of the tendon overlaps the posterolateral part of the supraspinatus and inserts more laterally and anteriorly on the tuberosity (4;7). Measurement results for the insertional footprint of the infraspinatus vary between studies from 10.2 to 13.4 mm in the medial-lateral plane and from 16.4 to 32.7 mm in the anterior-posterior plane (3;7). The infraspinatus muscle is innervated by the suprascapular nerve (C4 – C6).

Teres minor muscle

The teres minor arises from the axillary border of the scapula and inserts together with the capsule into the inferior facet of the tuberosity. Both functionally and anatomically it is intimately associated with the infraspinatus muscle. Its insertional area on the greater tuberosity has been found to be 11.4 mm in the medial-lateral plane and 20.7 mm in the anterior-posterior plane (3). In contrast to the superior part of the rotator cuff, which inserts close to the articular cartilage edge of the humerus (3;8), there is a bare area between the cartilage and the medial border of the insertion of the teres minor and the infraspinatus. The medial-lateral dimension of the bare area has been found to be 13.9 mm at the most inferior aspect of the teres minor insertion (3). The teres minor muscle is innervated by the axillary nerve (C4 – C6).

Rotator interval, reflection pulley and long head of the biceps tendon

Whereas the supraspinatus, the infraspinatus and the teres minor muscles are intimately associated to each other, there is a definite interval between the superior border of the subscapularis, the anterior border of the supraspinatus and the lateral border of the coracoid, the last of which emerges from between the two muscle bellies. This area is termed the “rotator interval” (Figure 2).

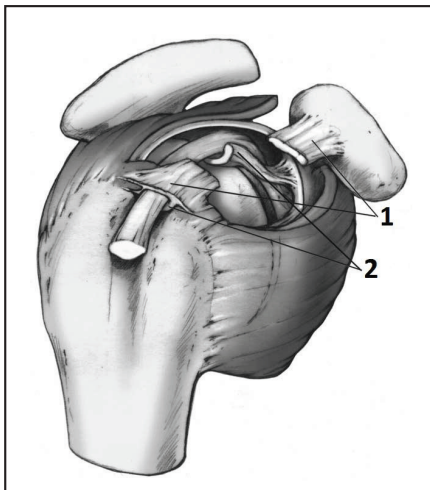


Figure 2. Anatomy of the rotator interval and the biceps outlet. 1 = coracohumeral ligament, 2 = superior glenohumeral ligament (Reproduced after permission from (9)).

The interval is covered by thin elastic tissue and reinforced on the bursal side by the coracohumeral ligament and on the articular side by the fibrous capsule and the superior glenohumeral ligament. The coracohumeral ligament has its origin on the dorsolateral aspect of the coracoid process, from which it courses laterally, covers the rotator interval and envelops the anterior border of the supraspinatus. Towards its insertion on the humerus it divides into two bands, one that inserts on the greater tuberosity and the anterior edge of the supraspinatus, and the other one on the lesser tuberosity and the superior border of the subscapularis. The superior glenohumeral ligament arises from the supraglenoid tubercle in the form of an internal thickening of the articular capsule. It crosses the floor of the rotator interval and inserts on the lesser tuberosity, where it fuses with the coracohumeral ligament. At their insertion the two ligaments, together with fibres from the supraspinatus and the subscapularis, form the reflection pulley, a tendoligamentous sling that stabilizes the long head of the biceps tendon before it enters the bicipital groove (Figure 2) (2;9-16). The long head of biceps originates from the supraglenoid tubercle and the superior glenoid labrum and runs laterally beneath the rotator interval. On its way from intra- to extraarticular it courses through the pulley and the bicipital groove together with an enveloping outpouching of the synovial membrane of the joint (16;17).

Vascular supply and microanatomy of the footprint area

As tears of the rotator cuff typically begin close to the insertional area of the supraspinatus, vascularization and microanatomy of the footprint have been subject for extensive investigations. Vascularization of the rotator cuff is performed by branches originating from the axillary artery. Vascular supply to the muscle bellies of the rotator cuff is mainly given by the suprascapular and subscapular arteries. The tendinous parts of the rotator cuff are mainly vascularized by the anterior and posterior circumflex humeral arteries and the thoracoacromial and suprahumeral arteries (18;19). Whereas a large number of arterial anastomoses occur between muscular vessels and tendon vessels on the subscapularis, infraspinatus and teres minor, a critical zone of hypovascularity has been identified on the supraspinatus tendon about 1 cm proximal to its insertion on the humerus (18-21). This zone corresponds to the convergence zone between ascendant vessels from the osteotendinous attachment and vessels descending from the muscle bellies, and coincides with the common site of tendon degeneration. Other studies, however, have questioned the existence of this critical zone of hypovascularity (22;23). According to these studies the critical zone represents a region of hypoperfusion rather than true hypovascularity and can

only be demonstrated in the adducted position of the shoulder when the humerus exerts upward pressure on the supraspinatus tendon and “wings out” the vessels in the critical zone (22).

Histologic examination of the area just proximal to the insertion of the supraspinatus tendon has shown a five-layer structure of the cuff-capsule complex (2). The first, most superficial layer consists of fibres of the coracohumeral ligament. The second layer consists of large bundles of closely packed parallel tendon fibres coursing from the muscle belly to the insertion on the humerus. In the third layer smaller fascicles from the supraspinatus intermingle with fibres from the adjacent subscapularis and infraspinatus, forming a network where fibres cross each other at an angle of 45°. The fourth layer consists of loose connective tissue containing thick bands of collagen fibres. Along the anterior edge of the supraspinatus this layer merges with the coracohumeral ligament. The fifth layer is formed by the glenohumeral joint capsule (2). In the interval between the fourth and fifth layers, about 1.5 cm medial from the insertion of the fibres, a strip of fibrous tissue extends from the coracohumeral ligament and runs perpendicular to the long axes of the tendons towards the posterior edge of the infraspinatus tendon. This structure is referred to as the rotator cable (2;24-26). Together with the area of thinner cuff tissue localized lateral to the cable, it has been termed the cable-crescent complex. According to Burkhart et al. (24) the cable can have a significant influence on shoulder mechanics by transferring stress from medial tendon fibres through the loaded cable to the humerus and by stress-shielding the crescent tissues.

Histologic examination of the supraspinatus tendon attachment to bone has shown a fibrocartilaginous insertion consisting of tendon, layers of fibrocartilage and calcified fibrocartilage, and bone (27). Whereas tendon fibres at the medial part of the footprint insert almost perpendicularly into a thick layer of fibrocartilage, insertion is at more acute angles into a thinner layer of fibrocartilage laterally. The functional significance of this fibrocartilaginous transition zone may be to avoid a direct tendon-to-bone interface and to protect the tendon insertion from wear caused by bending and twisting forces (27).

5.2 Function of the rotator cuff

Shoulder function has been described as a perfect compromise between mobility and stability (28). Shoulder movement results from the concerted motion of the sternoclavicular, acromioclavicular, glenohumeral and scapulothoracic articulations. Large ROM is possible because of few bony restraints and a wide glenohumeral joint capsule which does not restrict movement until an extreme of motion occurs. Stability at the end-range of motion is maintained by static stabilizers, including the capsule and the glenohumeral ligaments. Mid-range stability is achieved dynamically by muscle activity across the joint. The system complex of the shoulder depends on a precisely coordinated interaction between muscular and capsuloligamentous structures. A delicate balance exists between the opposing forces of agonists and antagonists, which results in net forces of motion and stability. The rotator cuff plays an important role in this system, both as a mover and as a stabilizer of the shoulder. Individual rotator cuff muscles act as prime movers of the glenohumeral joint, and simultaneous activation of the rotator cuff muscles contributes to mid- and end-range stability of the glenohumeral joint (29). The relative importance of each individual rotator cuff muscle for shoulder motion and stability varies according to the position of the glenohumeral joint.

Strength of the rotator cuff

Analysis of the contribution of each rotator cuff muscle to the overall strength of the rotator cuff has been performed isometrically and isokinetically. Isometric strength measurements with the arm in neutral abduction and rotation have demonstrated contributions of 53% from the subscapularis, 14% from the supraspinatus, 22% from the infraspinatus and 10% from the teres minor (30). Isokinetic analysis during abduction and external rotation at 90° per second showed an average contribution from the supraspinatus together with the infraspinatus of 50% to maximum shoulder abduction torque and 38% to maximum external rotation shoulder torque (31).

Active shoulder motion

The rotator cuff muscles, together with the pectoralis major, the latissimus dorsi, the teres major and the three portions of the deltoid, are considered to act as prime movers of the glenohumeral joint. The individual contribution of each of the rotator cuff muscles to shoulder motion has been investigated in a large number of studies, and inconsistent and even contradictory results have been found, especially for the infraspinatus and the

subscapularis muscle. This lack of agreement may be due to the fact that most studies were performed on cadavers, to technological limitations and/or to substantial differences in study protocols. Because of their broad origins, functional differences between the upper and lower parts of the subscapularis and the infraspinatus have been discussed: whether the upper parts play a more important role as a mover and the lower parts a more important role as a stabilizer.

The greatest agreement between studies has been found on the role of the supraspinatus muscle during glenohumeral abduction and elevation in the scapular plane (a plane angled 30° to 45° anterior to the coronal plane). In most studies a large moment arm was demonstrated during the lower part of the arc of motion, with decreasing but still significant values during the upper part. This reflects the importance of this muscle as an initiator of glenohumeral abduction and elevation (32-34). Together with the deltoid, the supraspinatus is considered to be the strongest abductor and elevator of the upper extremity (33;34).

The subscapularis and the infraspinatus have been shown to have a biphasic function during abduction and elevation, with the muscles acting either as movers or depressors (stabilizers) depending on the position of the humerus. For the subscapularis, Kuechle et al. (33) described a negative moment arm (depressor function) in the initial phase of elevation and a positive moment arm (elevator function) in the later phase. This is in contrast to the results of Liu et al. (34) who found the subscapularis to have a small but positive moment arm up to 60° of elevation, but a neutral or negative moment arm above this value. In addition to its action during abduction and elevation, the subscapularis has been shown to be the strongest internal rotator of the glenohumeral joint both with the arm abducted or adducted (35-37).

As for the subscapularis, conflicting results have been found concerning the biphasic action of the infraspinatus during abduction and elevation in the scapular plane. Kuechle et al. (33) found a positive elevation moment arm during the first 30° to 50° of motion and a negative moment arm above this height, while Liu et al. (34) found a small, positive elevation moment arm at 0° that increased at 15° and remained constant until maximal elevation was reached. Force analysis during external rotation identified the infraspinatus together with the teres minor as the most important external rotators (37;38).

Dynamic shoulder stability

Stability of the glenohumeral joint is critical because of its few static restraints. Static stabilizers, including cartilaginous, capsular and ligamentous structures, contribute primarily at the end-range of joint motion. Dynamic stability is therefore necessary during the mid-range of motion and this can be provided by muscle contraction. Due to its line of action close to the rotational centre of the glenohumeral joint, the rotator cuff is in an ideal position to act as a dynamic stabilizer. Simultaneous activation of all four rotator cuff muscles results in a centrally and inferiorly directed force vector and active compression of the humeral head into the glenoid cavity (concavity compression) (39). By counteracting the shearing forces from glenohumeral muscles, which have lines of pull that are oblique to the plane of the glenoid, the rotator cuff maintains the net force vector across the glenoid and resists translation of the humeral head. This means that the glenoid can be used as a fulcrum during glenohumeral joint elevation.

EMG has provided important insight into the stabilizing function of the rotator cuff. During isokinetic internal and external rotation, EMG registration showed activation of the whole rotator cuff prior to the initiation of the actual movement and prior to the onset of activity in prime movers such as the deltoid and the pectoralis major. This presetting of the rotator cuff prior to movement results in pretension of the glenohumeral joint and confirms the role of the rotator cuff as a dynamic stabilizer (40). Furthermore, EMG has demonstrated coactivation of both the agonist and antagonist part of the rotator cuff during active rotation in the glenohumeral joint. This indicates that the antagonist has a stabilizing function and supports the hypothesis that the rotator cuff acts as a force couple around the glenohumeral joint (40). A force couple can be defined as a pair of forces which are opposite in direction and which act around a joint as centralizers during rotation. Two key force couples are described around the glenohumeral joint: 1) the coronal force couple, in which the rotator cuff counteracts the upwardly directed shearing component of the deltoid during elevation, and 2) the transverse force couple, which provides stability during rotation by the counter activity of the lower parts of the subscapularis on one side and of the infraspinatus and the teres minor on the other (41).

In addition to its important role in mid-range stability, the rotator cuff also contributes to end-range stability. In the position of anterior shoulder instability (abduction, external rotation, horizontal abduction), the infraspinatus and the teres minor increase compression

forces by pulling the humeral head backwards and tensioning the anterior capsular ligaments (29;42). Simulated decrease in infraspinatus muscle activity in a cadaveric model with the shoulder in apprehension was found to significantly decrease stabilizing compressive glenohumeral joint forces (43).

Although they act primarily as dynamic stabilizers, the rotator cuff muscles also contribute as static stabilizers of the shoulder. A weak stabilising effect on the glenohumeral joint results from passive muscle tension (the bulk effect). More important is the barrier effect of the contracted muscles with the contracted subscapularis muscle acting as a barrier against anterior dislocation of the humeral head and the infraspinatus and teres minor acting as barriers to posterior translation (44-46).

5.3 Tears of the rotator cuff

Prevalence and pathogenesis

Tears of the rotator cuff are common. Using sonography, Yamamoto et al. (47) found a prevalence of full-thickness tears of 20.7% in the general population with and without shoulder problems (mean age 57.9 years). In a literature review of cadaver studies, including 2553 shoulders from samples with a mean age of 70.1 years, prevalences of 11.8% and 18.5% were found for full-thickness and partial-thickness tears respectively (48). Sonographic and MRI studies have shown a significant association between advancing age and increasing frequency of rotator cuff tears, and that some tears are asymptomatic (49-52).

Full-thickness tears are rarely found in individuals under the age of 40, and tendon aging is believed to be the most important contributing factor in the pathogenesis of rotator cuff tears. Intrinsic and extrinsic mechanisms are thought to be important contributors leading to tendon degeneration. Intrinsic tendon injury may occur in the critical zone proximal to the cuff insertion on the humerus, where repetitive eccentric, concentric and bending loads on tendon fibres during humeral motion, together with relative hypoperfusion, can lead to degeneration and ultimately failure of the tendon. Extrinsic injury may occur as a consequence of tendon compression against an abnormal coracoacromial arch during shoulder motion. Contributing factors include curved and hooked acromial shapes, acromial spurring, acromioclavicular osteophytes, tendon and bursal swelling, altered

glenohumeral kinematics and postural changes like scapula protraction, all of which lead to a narrowing of the functional subacromial space (53-55).

Classification

As tear characteristics vary widely and influence the prognosis and choice of treatment, classification is of importance. Properties of a rotator cuff tear that should be recorded for classification are its symptomatic status, whether the tear is full-thickness or partial-thickness and whether it is acute (traumatic), chronic (atraumatic) or a combination of both (acute on chronic). Further a classification has to be based on imaging findings for tear size in two planes, tear localisation, the trophic quality of the muscles and of the torn tendon, and on the state of the long head of the biceps tendon.

Tear size is measured in the anterior-posterior and medial-lateral plane and is usually classified as small (< 1 cm), medium (1-3 cm), large (3-5 cm) or massive (> 5 cm) (56). Retraction of the tendon in the medial-lateral plane can be classified according to Patte (57). Tear localisation is given in terms of the tendons involved, by differentiating between superior tears (affecting the supraspinatus tendon only), superoposterior tears (affecting the supraspinatus and infraspinatus tendons) and superoanterior tears (affecting the supraspinatus, the rotator interval, the subscapularis and sometimes the long head of the biceps) (57;58). Classification of the atrophy of the supraspinatus muscle is performed on MRI according to Thomazeau et al. by calculating the occupational ratio of the scapular fossa (58) or by using the tangent sign as described by Zanetti et al. (59). Fatty degeneration of the rotator cuff muscles is evaluated according to the CT-based classification of Goutallier et al. (60). The transferability of this classification to MRI has been demonstrated by Fuchs et al. (61).

Clinical aspects

Clinical findings from a rotator cuff tear vary considerably from shoulder to shoulder. Some shoulders with a cuff tear remain asymptomatic, while others show severe pain and loss of strength and function. The reason why some tears are, and may remain, asymptomatic is not yet understood. The two main complaints by patients with a symptomatic rotator cuff tear are shoulder pain and weakness. Findings at clinical examination vary depending on tear size and which parts of the rotator cuff are affected. Tears of the supraspinatus tendon typically result in a painful arc (62), loss of active

shoulder abduction and flexion, weakness on resisted isometric contraction in abduction and positive impingement signs (63;64). In addition, superoposterior tears show a loss of active range of motion and weakness in external rotation, and a positive lag sign (65). Tears of the subscapularis result in a reduced active range of motion and weakness in internal rotation, together with a positive lift-off, belly-press and lag sign (66). In many tears a shoulder shrug and loss of the physiological humeroscapular rhythm may be observed during active abduction and flexion. In long-standing rotator cuff tears, wasting of the affected muscle bellies may be seen.

As most of these clinical findings show high specificity together with low sensitivity or vice versa, the clinical diagnosis of a rotator cuff tear has to be based on a combination of specific physical findings. Combined findings of a weakness in abduction and external rotation together with a positive impingement sign have been found to be closely associated with the presence of a full- or partial-thickness tear. If only two of the findings were present and the patient was aged 60 or older, the predictive value for the combination was still significant (67). A close association with the presence of a rotator cuff tear was also demonstrated for the combined findings of night pain, a positive impingement sign and weakness in external rotation (68). Thus in cases presenting these specific findings the diagnosis of a rotator cuff tear can be made with high probability on the basis of patient history and physical examination. In the other cases, however, differentiation from other shoulder conditions is not possible without supplementary examination by diagnostic imaging tests. Visualization of a tear is particularly important in patients who are candidates for surgery, when definition of specific tear characteristics is indispensable for planning the operative approach.

5.4 Diagnostic imaging of the rotator cuff

Imaging methods used for the assessment of rotator cuff-related pathologies are plain radiography, single or double contrast arthrography, sonography, MRI, magnetic resonance (MR) arthrography and CT arthrography.

Plain radiography

Despite its ineffectiveness in detecting soft tissue lesions, conventional radiography should be routinely used as a first-step examination in the evaluation of suspected pathology of the

rotator cuff. Examination should be performed in three planes, including (1) a true anteroposterior view in the plane of the scapula with the arm along the body and in internal and external rotation, (2) a 30° degree caudal tilt view and (3) a scapular outlet view. Findings of interest are secondary signs of chronic cuff disease such as sclerosis of the undersurface of the acromion, traction spurs in the coracoacromial ligament, changes at the cuff insertion to the humerus and calcifications in the tendons of the rotator cuff. Large rotator cuff tears may lead to cranial dislocation of the humeral head on the glenoid and to narrowing of the acromiohumeral interval. Long-standing massive rotator cuff tears can result in cuff tear arthropathy with concave remodelling of the acromial undersurface and the formation of an acromiohumeral neoarticulation. Further, the shape of the acromion (flat, curved, hooked) (54) and the condition of the acromioclavicular joint should be determined, as they may influence therapeutic decisions.

Arthrography

Arthrography was the main method for diagnosing rotator cuff tears until the advent of sonography and MRI of the shoulder in the 1990s. Compared with these newer techniques, arthrography has the disadvantage of radiation, of being invasive and of not permitting the diagnosis of intratendinous or bursal-sided partial-thickness tears. Determination of tear size and location is not possible with single-contrast arthrography. Thus today there are few indications for conventional arthrography of the shoulder as an isolated investigation, but single-contrast arthrography is used as a procedure to prepare the patient for MR arthrography.

Sonography

Performed in real-time with a high-frequency linear array transducer (9-13 MHz), sonography permits direct visualization of the soft parts of the shoulder, including the rotator cuff and the long head of the biceps muscle. The method is highly effective in diagnosing rotator cuff tears and biceps tendon pathologies (69-75) and should be used as the initial imaging test when the primary question is one of rotator cuff or biceps tendon abnormalities. Sonography provides rapid diagnosis, is widely available, non-invasive and non-radiating, allows routine dynamic and bilateral examination and immediate clinical correlation, is inexpensive on a per-examination basis and has no known side effects. Routine sonographic shoulder examination should be performed according to a standardized examination protocol, including five views (anterior transverse and

longitudinal, lateral transverse and longitudinal, posterior transverse) together with dynamic examination. Standardized diagnostic criteria for rotator cuff tears and biceps pathology have been defined (76;77). In operation correlation studies, sensitivities and specificities of 90% and more were found for the correct diagnosis of a full-thickness tear by sonography (69-75). Measurement of tear size and description of tear localization have been performed successfully (68;78). Sonography has proved to be less effective in detecting partial-thickness tears, with reported specificities and sensitivities ranging from 13 to 93% and from 20 to 94% respectively (79-82). The disadvantages of the method are its low diagnostic value for concomitant shoulder abnormalities (labral and capsular tears, articular damage), its hands-on aspect, which makes the full diagnostic impact of the study only accessible to the executing sonographer, and the lack of a qualitative sonographic grading system for muscle atrophy.

MRI

MRI is the imaging modality that provides the most complete information about the shoulder, but it is rarely indicated as a first-line examination for patients with routine rotator cuff problems. MRI is indicated as a second-line examination in patients in whom the diagnosis is still in doubt after primary clinical, radiographic and sonographic evaluation, and in patients who are candidates for tendon repair and for whom additional information about muscular atrophy, fatty degeneration, biceps outlet pathology or concomitant intraarticular abnormalities is needed. MRI of the shoulder is performed according to standardized protocols that usually include three imaging planes (oblique sagittal, oblique coronal and axial). It has shown high diagnostic validity for the detection of full-thickness tears of the rotator cuff, with a sensitivity and specificity comparable to those of sonography (83;84), and for the description of tear characteristics like tear size and localization (58;78;85). Success in detecting partial-thickness tears has been shown to be lower than for full-thickness tears (80;81;84). MRI is useful in revealing and classifying atrophy and fatty degeneration, which can develop in the rotator cuff muscles as a consequence of a tendon tear and which are important prognostic factors for tendon repair (58;86;87). MRI is contraindicated for patients with a pacemaker, intracranial magnetic aneurismal clips, certain neurostimulator and cochlear implants and intraocular metallic foreign bodies, and may be difficult to perform in patients with claustrophobia if an open MRI machine is not available.

If necessary, the accuracy of MRI for the depiction of rotator cuff lesions can be enhanced by direct or indirect MR arthrography, especially in cases with suspected articular-sided partial-thickness tears, small full-thickness tears, tears of the rotator interval or lesions of the biceps outlet. Indirect MR arthrography is performed by injecting contrast intravenously and has the advantage of avoiding joint injection. In direct MR arthrography, contrast is injected intraarticularly under fluoroscopic guidance, leading to distension of the joint capsule and better visualization of subtle lesions of the rotator cuff. Both methods have the disadvantage of possible allergic reactions. In addition, direct MR arthrography may be complicated by joint infection and post-injection pain.

CT

CT is mainly used for the diagnosis of bony lesions of the shoulder. However, CT arthrography has regained its popularity in some orthopaedic communities as a valuable and accurate diagnostic method for the rotator cuff and the biceps tendon. It may be an alternative for patients for whom MRI is contraindicated and for those with claustrophobia if sonography is not available.

5.5 Treatment methods for rotator cuff tears

As patients with rotator cuff tears present with a wide spectrum of symptoms, tear characteristics and physical activity requirements, treatment regimes have to be tailored individually. Both conservative and surgical interventions exist. Conservative treatment has the advantage of less treatment-related morbidity and interferes less with the patient's activities of daily living, but should only be preferred if the short- and long-term results are comparable to those achieved by surgical repair. Conservative treatment is usually based on a physiotherapeutic rehabilitation regime, often in combination with one or more of the following: local or systemic glucocorticosteroid medication, non-steroidal anti-inflammatory medication, acupuncture, electrotherapy and therapeutic ultrasound. Operative treatment has been performed by anatomical tendon repair using open, mini-open or arthroscopic techniques. In patients with irreparable defects, palliative surgery such as subacromial decompression, tendon debridement, biceps tenotomy or tenodesis, synovectomy, partial repair or tendon transfers may be effective. In cases of cuff arthropathy, prosthetic replacement may be indicated. In recent years adjuvant biologic

treatment strategies have been developed to improve biologic healing at the tendon-to-bone junction.

Whether conservative or operative treatment should be selected for an individual rotator cuff tear has to be determined on a case-to-case basis. Primary operative treatment by tendon repair is usually indicated for younger, physically active patients with an acute full-thickness tear leading to significant functional deficits. Conservative treatment may be tried initially and for a period of at least 3 months for patients over the age of 65 with an atraumatic tear, functional weakness resulting from pain, and lower shoulder demands than their younger counterparts. However, many cases cannot be classified into any of these groups and a generally accepted treatment algorithm has not yet been established for these patients.

Conservative treatment

Physiotherapeutic exercise therapy is usually the cornerstone of the conservative management of patients with rotator cuff tears. Exercise programmes should be individually tailored according to the functional deficits detected at patient examination. Restoration of full pain-free ROM, muscle balance, muscle synchrony and scapulothoracic and glenohumeral muscular control and stability are important goals of the rehabilitation. Supplementary measures like steroid or non-steroid anti-inflammatory medication and physical modalities may be adequate initially to achieve pain control, but there is little evidence of protracted benefit from these methods alone (88-90).

A number of different physiotherapeutic treatment regimes have been tried in case studies. In studies with a short-term follow-up of less than one year and with the majority of tears limited to the supraspinatus tendon, improvement from baseline in terms of the Constant score ranged from 13 to 30 points (91-93).

In studies with medium-term follow-ups (1-4 years) of acute and chronic tears of various sizes, the percentages of excellent or good results ranged from 59% to 82% (94-97).

However, separate analysis of patients with moderate and large tear sizes in one of these studies showed an excellent or good result in only 25%.

One long-term study over 7.6 years, with a majority of traumatic rotator cuff tears, found no or only slight shoulder discomfort in 74% of patients at follow-up, but weakness was found on muscle testing in 94% (98). Another long-term study of atraumatic tears over 7

years found a 23-point improvement on the Constant scale, and a satisfaction rate of 63% (99). Factors that were found to be positively correlated with successful conservative treatment were well-preserved shoulder motion and strength at baseline (94;96). Predictive factors for unsuccessful conservative treatment were pre-treatment clinical symptoms for more than one year, tear size exceeding 1 cm, sleep loss due to shoulder pain and an insurance claim (95;100).

Taken together, these study results appear to support an initial trial of conservative treatment in cases where primary tendon repair is not clearly indicated. However, the value of these studies is limited, as most are retrospective, present pre-selected patient groups, lack independent observers and control groups, and exclude from analysis patients who had been converted to surgical therapy after failed conservative treatment. Further, initially repairable rotator cuff tears that are treated conservatively may develop irreversible changes in the muscle-tendon unit such as muscle atrophy, fatty degeneration, tendon retraction and tissue thinning. Such changes make surgical tendon repair at a later time more difficult, if not impossible, and may compromise the outcome for the patient (86;87).

Operative treatment

In patients considered for operative treatment, the reparability of the tear has to be determined. Factors that have been shown to be positively related to a structurally and clinically successful repair are a patient age of less than 65 years (101), a short duration of symptoms, an acromiohumeral distance of more than 7 mm on anterior-posterior radiographs (102;103), and the absence of tobacco abuse (104), of steroid medication (105) and of comorbidities such as diabetes (106). MRI-derived factors indicating reparability are tendon retraction not exceeding stage 2 according to Patte (57), muscle atrophy not exceeding grade 2 according to Thomazeau et al. (107) and fatty dystrophy of the muscles not exceeding grade 1 according to Goutallier et al. (86;87).

Functional cuff repair requires restoration of normal cuff anatomy by use of tendon-to-tendon and tendon-to-bone techniques and tension-free fixation to the humerus by mobilizing retracted and shortened rotator cuff tendons. In cases of pathology of the long head of the biceps tendon or its outlet, treatment by biceps tenodesis or tenotomy may be indicated. Acromioplasty may be considered in patients with chronic tears, but two recent studies have shown similar short-term results of tendon repair with and without

decompression (108;109). A postoperative rehabilitation regime including gentle progression from passive motion to active unloaded motion to strengthening exercises over 3 to 6 months is essential.

Tendon repair was found to have good results for pain relief and restoration of shoulder function in a number of case studies. After open repair, good or excellent results were achieved by Rokito et al. for large and massive chronic rotator cuff tears in 76% of patients after a mean of 5.5 years (110). In a long-term study over 13.4 years Cofield et al. (111) found excellent and good results in 80% of patients, and Galatz et al. (112) demonstrated constancy of the results achieved by tendon repair over 10 years. In a meta-analysis of the results of a number of studies, Cofield (113) found good or excellent results after open tendon repair in 85%. Because it is potentially less traumatic to shoulder-covering tissues, many shoulder surgeons today prefer mini-open or all-arthroscopic tendon repair. For both procedures short and mid-term outcomes have been shown to be comparable to those of open surgery. Satisfaction rates ranging from 86% to 96% (114-116) after mini-open repair and from 91% to 95% after arthroscopic repair (117-119) have been reported. In two recent meta-analyses of studies comparing mini-open with arthroscopic rotator cuff repair, no differences could be demonstrated in final outcome or complication rates (120;121). However, most of the existing studies are retrospective and randomized controlled studies are lacking. The impact of the surgical technique on the results of full-thickness tear repair still has to be analysed by adequately designed studies.

Tendon repair aims to re-establish normal cuff anatomy without tear recurrence. However, assessment of tendon integrity after tendon repair has shown variable results. In a study by Harryman et al., sonographic follow-up of 105 tendon repairs 5 years after open surgery (122) showed a recurrent full-thickness defect in 20% of patients for tears affecting the supraspinatus tendon alone, in 43% for tears affecting the supraspinatus and infraspinatus tendons and in 68% for three tendon tears. Intact rotator cuffs at follow-up showed better function and ROM than rotator cuffs with recurrences, and the size of the recurrent defect was negatively correlated to the functional outcome. However, patient satisfaction was generally high independent of cuff integrity. Similar results have been reported for mini-open repair (116), and for arthroscopic repair (117-119).

To summarize, in the absence of any prospective randomized clinical trials, only limited evidence is available for treatment selection for full-thickness tears of the rotator cuff. Better studies are needed to determine optimal surgical treatment techniques and sound indications for operative and conservative treatment.

6. Aims of the research

Paper I

To investigate the early learning curve of an orthopaedic surgeon with diagnostic sonography of the shoulder.

Paper II

To investigate sonography as an isolated diagnostic tool for the painful shoulder unbiased by clinical examination findings and patient history.

Paper III

To compare treatment benefits from tendon repair and physiotherapy in the treatment of rotator cuff tears up to 3 cm in diameter.

Paper IV

To investigate the prevalence and characteristics of asymptomatic full-thickness tears of the rotator cuff in the general population by sonography.

Paper V

To compare findings on magnetic resonance imaging from symptomatic and asymptomatic full-thickness tears of the rotator cuff.

7. Methods:

7.1 Imaging methods

Sonography (Papers I, II, III, IV, V)

Real time sonography in studies I and II was performed with a Siemens Sonoline Sienna scanner equipped with a 5.5-9.4 MHz linear-array transducer and in studies III to V with a Siemens Sonoline Antares scanner equipped with an 8.5-11.5 MHz linear-array transducer. A standardized examination protocol was followed. Five standard views were obtained with the patient sitting on a swivel stool and the examiner standing behind. Lateral views were taken with the arm placed in adduction and internal rotation (on the patient's back). For other views the arm was placed in adduction and neutral rotation (on the patient's thigh). Supplementary dynamic examination was performed during active or passive external rotation (the subscapularis) and abduction (the supraspinatus), and by compressing the tendon with the transducer. Two plane examinations were performed for the subscapularis, supraspinatus and infraspinatus and the long head of the biceps muscle.

Criteria for a full-thickness tear consisted of (1) nonvisualization of the rotator cuff, (2) hypoechoic or anechoic discontinuity of the rotator cuff or (3) contour concavity of the superior border of the rotator cuff in two planes. For the diagnosis of a partial-thickness tear, focal heterogeneous hypoechogenicity or an incomplete hypoechoic cleft had to be present. Secondary sonographic signs like a double cortex sign, irregularities of the bony surface of the greater tuberosity and effusion both in the subdeltoid bursa and the biceps tendon sheath supported the diagnosis of a tendon tear, but were not sufficient for the diagnosis on their own (76;77;79). A rupture of the long head of the biceps muscle was diagnosed if the tendon could not be identified in the intertubercular sulcus or elsewhere anterior to the humerus. A dislocation was diagnosed if the tendon was depicted anterior or medial to the lesser tuberosity (84).

Measurement of maximum tear size in the supraspinatus and infraspinatus was performed on lateral transverse and longitudinal views along a straight line visualizing the distance between the margins of the tear (lateral transverse view) or between the greater tuberosity and the lateral margin of the tear (lateral longitudinal view) (123). In large tears, where a single line would have intersected the humeral head, measuring was performed along

several lines following the contour of the humeral head (78). Measuring in the longitudinal plane was not possible in cases where the tendon had retracted under the acromion.

Location of the tears was determined on anterior (subscapularis) and lateral (supra- and infraspinatus) transverse views. Tears with a posterior extension of no more than 15 mm measured from the intraarticular portion of the biceps tendon were registered as supraspinatus tears and those extending for more than 15 mm as tears involving both the supraspinatus and the infraspinatus. Tears localized anterior to the biceps tendon were recorded as tears of the subscapularis (124).

Magnetic resonance imaging (Papers III, IV, V)

MRI of the shoulder in studies III to V was performed on a 1.5 T scanner. A dedicated shoulder array coil was used. The arm was placed along the side of the body with the thumb pointing upwards. Five sequences, all with 3.5-4 mm slice thickness, 17.5-18.0 FOV and one NEX, were obtained: (1) oblique sagittal T1-weighted spin echo (TR/TE = 513/13 ms, matrix 192 x 256), (2) oblique sagittal T2-weighted TSE (TR/TE = 2930/74 ms, matrix 218 x 256), (3) oblique coronal and (4) axial proton density-weighted TSE with fat saturation (TR/TE = 2800/40 ms, matrix 230 x 256), and (5) oblique coronal dual echo TSE (TR/TE = 2500/13 – 81, matrix 205 x 256). MRI data were stored on a picture archiving and communication system for further analysis.

A full-thickness tear of the rotator cuff was diagnosed on MRI (1) in the presence of a complete discontinuity or gap in the tendon, or (2) if increased signal intensity (isointense compared to fluid), extending from the articular to the bursal surface of the tendon, was found on T2-weighted images (83;84;125). Tear size in two planes was measured along a straight line between the margins of the tear (oblique sagittal plane) and between the margin of the tear and the lateral edge of the humeral articular surface (oblique coronal plane). In large tears, the measurement lines followed the contour of the humeral head (78). Tear location (tendon involved) was determined in the oblique sagittal plane according to the classification of Thomazeau et al. (58). A tear of the long head of the biceps muscle was diagnosed if the tendon could not be visualized within the intertubercular sulcus or any other location in the joint (126).

Atrophy of the supraspinatus muscle was assessed by calculating the occupational ratio of the fossa and by the tangent sign (59;107). The occupational ratio was measured on the

oblique sagittal T1-weighted series on the image showing the Y-shaped view of the scapula. The contours of the supraspinatus muscle and the supraspinatus fossa were traced, and the CSAs were determined. Calculation of the ratio was performed by dividing the CSA of the supraspinatus by the CSA of the fossa. According to Thomazeau et al., ratios above 0.6 indicate a normal muscle volume, ratios between 0.4 and 0.6 indicate moderate atrophy and ratios less than 0.4 indicate severe atrophy of the supraspinatus muscle. On the same image, the tangent line was drawn between the top of the coracoid and the top of the spine of the scapula. A positive tangent sign (indicating severe atrophy) was registered if the supraspinatus muscle belly and the tangent line did not intersect.

Fatty degeneration of the supraspinatus, infraspinatus and subscapularis muscles was classified according to Goutallier et al. and Fuchs et al. (60;61). As in the quantitative assessments, the Y-shaped view of the scapula was used for analysis. Muscles showing no fat (grade 0) or only some fatty streaks (grade 1) were considered to be normal, muscles with more than some fatty streaks but still more muscle than fat (grade 2), with equal amounts of muscle and fat (grade 3) or with less muscle than fat (grade 4) were considered to be severely degenerated.

7.2 Therapeutic methods

Tendon repair (Paper III)

A mini-open or open approach was used for tendon repair, with the patient in the beach-chair position and under a combination of interscalene block regional anaesthesia and total intravenous anaesthesia. Surgery started with a diagnostic arthroscopy through a standard posterior portal and the glenohumeral joint was thoroughly inspected for associated intra-articular pathology.

An anterior/superior approach was used for tear exposure. The fibres of the deltoid were split for a distance of 3 to 4 cm, followed by detachment of the anterior part of the deltoid and release of the coracoacromial ligament from the acromion. An anterior/inferior acromioplasty was performed as described by Neer (53). When present, osteophytes were removed from the undersurface of the acromioclavicular joint. After partial bursectomy and limited debridement of tendon margins, the rotator cuff was mobilized with the arm at the side until full coverage of the footprint without undue tension was achieved. In almost all

cases this was possible after blunt dissection on the bursal and articular surface of the tendons. In some cases, however, a stepwise release of the coracohumeral ligament, the rotator interval and the superior half of the capsule from the labrum had to be performed. The footprint was prepared to bleeding bone, and the tendon repaired by a combination of tendon-to-tendon and tendon-to-bone techniques. Tendon-to-bone repair was performed with a modified Mason-Allen technique, with one limb of the suture passed through drill holes in the greater tuberosity and tied laterally, over bone, to the other limb. Two to four sets of size 2 nonabsorbable braided sutures were used, depending on the size of the tear.

The detached part of the deltoid was repaired through bone tunnels to the acromion. Supplemental tenodesis of the long head of the biceps tendon to the intertubercular sulcus with anchors was performed when arthroscopy had shown degeneration or a partial tear of this tendon. Mini-open tendon repair differed from open repair in that the incision was shorter and acromioplasty was performed arthroscopically.

Physiotherapy (Paper III)

A rehabilitation programme describing treatment goals and methods was established prior to the study, together with a photographic essay demonstrating the therapeutic exercises. Physiotherapy was given in a non-standardized manner on the basis of this programme. Selection of exercises, number of repetitions and duration of treatment were individually tailored according to examination findings and treatment progression. Treatment sessions of 40 minutes were given on average twice weekly for 12 weeks and at increasing intervals during the subsequent 6 to 12 weeks. Particular attention was directed towards correcting the upper quarter posture and restoring of scapulothoracic and glenohumeral muscular control and stability. Exercises were supplemented by educative measures to give the patient a better understanding of shoulder function and treatment principles.

Correction of upper quarter posture

Increased elevation of the shoulder girdle was addressed by manual therapy, stretching exercises and massage of tight and overactive cervicoscapular muscles. In patients presenting with increased scapular protraction, manual techniques were used to reduce tension and increase flexibility in overactive scapula protractors, together with strengthening exercises for weakened interscapular muscles. Active and passive exercises

were given to increase the flexibility of the thoracic spine and to counteract increased thoracic kyphosis.

Scapulothoracic muscular control and stability

The principle of establishing proximal stability as a basis for distal function was followed. Exercises to achieve and maintain the ideal postural position of the scapula prior to movement (scapula setting) were given. Therapeutic measures included (1) educative measures to increase the patient's awareness of the appropriate starting position of the scapula, (2) manual techniques to increase the flexibility of muscles counteracting free scapular motion, (3) exercises to achieve and maintain ideal scapula orientation without use of substitution strategies and (4) facilitation techniques to improve proprioception. Once appropriate scapula positioning was achieved, dynamic control of the scapulothoracic joint was addressed. Exercises with the humerus in more challenging positions (overhead) were introduced, and training was administered in positions in which scapulothoracic control was still present, but close to the position where control was lost.

Glenohumeral muscular control and stability

Initially, exercises for local control of the glenohumeral joint were given. Centring of the humeral head in the glenoid fossa was trained by isometric exercises and exercises against eccentric and concentric resistance for shoulder rotators. Inelastic and shortened rotator muscles were addressed manually. Closed kinetic chain exercises were introduced to improve concavity compression of the humeral head into the glenoid. Once local glenohumeral control was achieved, training of strength and endurance of shoulder rotators and depressors was started. Exercises with increasing loads were given progressing from neutral to more challenging positions. During all exercises scapular stability had to be maintained. Additional exercises were given to meet specific demands made by work, sport and leisure activities.

Educational measures

The educational measures consisted of verbal and written information together with demonstrations on anatomic models to explain the treatment process and the reasons for the treatment programme. Standing in front of a mirror, patients learned to discern individual elements of poor posture and motion and to recognize changes occurring as a result of

therapy. Home exercises were given to increase the patient's awareness of correct use of the shoulder during everyday shoulder activities (127-129).

7.3 Outcome measures

Constant score (Paper III)

The Constant score (130) is a widely accepted joint-specific outcome instrument for the shoulder. Its interobserver reliability was established in the original study and a more complete assessment of its reliability in patients with shoulder pathology was later performed by Conboy et al. (131). The system uses a combination of subjective and objective components to assess shoulder function. The maximum score of 100 points consists of 35 points based on subjective assessments of pain and activities of daily living and 65 points based on examiner-derived measurements of shoulder strength and ROM.

ASES score (Papers III, IV, V)

The self-report section of the ASES score (132) consists of two equally weighted parts for pain and shoulder function, each contributing 50 points to a maximum score of 100. Pain measurement is performed on a 10 cm VAS scale divided into 1 cm increments. Shoulder function is measured by classifying 10 activities of daily living on a four-point ordinal scale. The validity, reliability and responsiveness of the system for the follow-up of dysfunction of the shoulder have been demonstrated (133).

SF-36 health survey (Paper III)

In contrast to shoulder-specific outcome scores, the SF-36 is a generic measurement unit designed to measure health-related quality of life. This self-administered survey consists of eight scales concerned with physical function, physical role, bodily pain, general health perception, vitality, social function, emotional role and mental health. Each scale has a range of 0-100 points, with 100 indicating the best possible health condition. A summary score for physical and one for mental health is calculated from the results of the scales. The validity of the parameters as measures of physical and mental health constructs has been documented (134). Sensitivity and responsiveness have been demonstrated for measurement of the relative impact of shoulder pathologies and of the benefit of shoulder treatment (135-139).

7.4 Statistical methods

All statistical analyses were performed using SPSS version 16.0 (Papers I to III) and 17.0 (Papers IV and V) (SPSS Inc., Chicago, IL, USA). P values of less than 0.05 were considered statistically significant.

Papers I and II

The ability of a diagnostic test (sonography) to diagnose full-thickness tears of the rotator cuff was compared with a gold standard (arthroscopy or open surgery). The main results were given in terms of the sensitivity, specificity and positive and negative predictive values of the diagnostic test. Sensitivity is the proportion of positives correctly identified by a test. Specificity is the proportion of negatives correctly identified by a test. Sensitivity and specificity have the advantage that they are not affected by the prevalence of the disease in the study population and can therefore be compared between studies (assuming that the gold standard almost always reflects the true disease status of the subject). Positive and negative predictive values are the proportions of patients with positive or negative test results who are correctly diagnosed. Predictive values are more useful for the clinician as they express the probability that a given test result will reflect the correct diagnosis. As they depend strongly on the prevalence of the disease in the study population, they cannot be universally applied.

Paper III

Paper III reported a randomized controlled single-blinded study where the results of conservative treatment and tendon repair for rotator cuff tears were compared between groups. Analysis was performed according to an intention-to-treat principle by using the last-observation-carried-forward technique for the missing non-operative follow-up values from patients crossing over from physiotherapy to surgery. Outcome was measured on continuous scoring scales and repeated measurements were taken at baseline and after 6 and 12 months. To handle possible dependencies between the repeated measurements, a linear mixed model was used for analysis. The time of follow-up, the treatment group and an interaction term between the two were introduced into the model as explanatory covariates. As follow-up was after 6 and 12 months for all study subjects, time was included as a categorical covariate. Assumptions for a mixed model analysis were found to be fulfilled, with normally distributed residuals without systematic trends as shown on histograms and scatterplots. An unstructured covariance matrix was used for analysis.

Other types of matrix were tested but resulted in an inferior goodness of fit according to Akaike's Information Criterion.

Paper IV

Tear prevalence was calculated by dividing the number of subjects presenting an asymptomatic rotator cuff tear by the total number of study subjects, and was given in percent. To assess the association between tear prevalence and age group, a chi-square test for trend was used. The effect of tear/no-tear on shoulder strength was assessed by one-way ANCOVA with age and gender as covariates.

Paper V

The association between a binary outcome variable (rotator cuff tear with or without symptoms) and a number of categorical, two-levelled exposure variables (MRI-derived values for tear size and location, condition of the biceps tendon, muscle atrophy and fatty degeneration) was tested by logistic regression. Analysis was performed as a single factor analysis. In all analyses we controlled for subject age as a confounder by including it in the regression model. This was done because subject age differed between study groups (older mean age in the asymptomatic group), and at the same time was positively correlated to exposure groups (tear size, muscle quality) and negatively correlated to the outcome variable (symptoms of a rotator cuff tear). Fitting our regression model without adjusting for subject age would have masked the association between exposure groups and outcome variable and would have led to confounding bias. Prior to final analysis, interaction between independent factors and variables of interest (age, gender) was analysed, but was not found to be present.

8. Summary of papers

Paper I

Background: According to the literature, sonography has the disadvantage of a long learning curve (70;76;140;141). Studies performed by inexperienced examiners, however, have rarely been reported. The aim of the study was to document the results achieved by an orthopaedic surgeon at an early stage of the learning curve using this method.

Patients and Methods: After a 2-day training course consisting of theoretical and practical lessons in sonography of the shoulder, one orthopaedic surgeon examined 350 consecutive shoulder patients clinically and sonographically. The patients were referred by general practitioners for chronic shoulder pain, and the results of previous radiographs (53 cases) and MRI examinations (39 cases) were available to the examiner. Sonographic findings of interest were full-thickness and partial-thickness tears of the rotator cuff and tears or dislocations of the long head of the biceps muscle. Indications for operative treatment were found for 79 patients, who formed the study group. Surgery was performed by experienced orthopaedic surgeons other than the sonologist, who were aware of the findings from sonography. The surgical findings were then compared with the sonographic findings.

Results: Twenty of 26 surgically proven full-thickness tears of the rotator cuff were detected by sonography. In 45 of 46 cases with an intact rotator cuff on operation, sonography had been negative. Six of seven partial-thickness tears were overlooked. For sonographic detection of full-thickness tears, sensitivity was 77%, specificity 98%, positive predictive value 95% and negative predictive value 90%. For the long head of the biceps muscle, all eight cases with a surgically proved tendon rupture or dislocation were detected by sonography, but differentiation between the two conditions was not possible in two cases.

Conclusion: Our results support the usefulness of sonography as a diagnostic method for full-thickness tears of the rotator cuff and for pathology of the long head of the biceps muscle, even when the sonographer is in an early learning phase.

Paper II

Background: Rotator cuff tears can be diagnosed clinically in patients with typical symptoms (67;68;142;143). Lack of blinding of the sonographer to physical examination findings may have biased the results of earlier studies of the diagnostic accuracy of

sonography for rotator cuff tears. The aim of this study was to assess the value of sonography as an isolated diagnostic test for the detection and quantification of rotator cuff tears.

Patients and Methods: One orthopaedic surgeon performed sonography as the first-line examination on 350 patients referred by their general practitioner for chronic shoulder pain. The examiner was blinded to the patient's history, physical examination findings and results of previous imaging examinations. Sonographic findings of interest were full- and partial-thickness tears of the rotator cuff, maximum tear size and location of the tear. Indications for surgical treatment were found for 58 shoulders. Thirty-four patients were treated with arthroscopic acromioplasty by a single orthopaedic surgeon who was blinded to the sonographic findings. In 18 patients open repair of a full-thickness rotator cuff tear was performed. In these cases the rotator cuff was evaluated by the the assistant surgeon, who was blinded to the sonographic findings. The surgical findings were compared with the sonographic findings.

Results: All 24 surgically proved full-thickness tears of the rotator cuff had been diagnosed correctly by sonography. In 19 of 20 cases with an intact rotator cuff, preoperative sonography was negative. Thirteen of 14 partial-thickness tears were overlooked. Sensitivity for the detection of full-thickness tears was 100%, specificity 97%, positive predictive value 96% and negative predictive value 100%. Location of the tear in relation to the rotator cuff tendons was described correctly in 21 of 25 cases. For tear size measurement in the anterior-posterior and medial-lateral planes, the 95% range of agreement was -2.6 ± 9.8 mm, and -3.4 mm \pm 9.9 mm respectively.

Conclusion: Sonography of the shoulder performed without access to clinical information showed high diagnostic accuracy for full-thickness tears of the rotator cuff but not for partial-thickness tears. The results for tear size measurement and determination of tear location were close to the surgical findings in most cases.

Paper III

Background: Tendon repair and physiotherapy are accepted treatment options for rotator cuff tears, but have never been compared in randomized controlled studies. The aim of this study was to investigate differences in treatment benefits between the two methods by comparing outcome measures of open or mini-open tendon repair with those of a defined physiotherapeutic treatment regime.

Patients and Methods: The study was designed as a randomized controlled study with examinations at baseline and follow-ups after 6 and 12 months. One hundred and three patients with a symptomatic full-thickness tear of the rotator cuff not exceeding 3 cm were randomly allocated to physiotherapy or tendon repair. Outcome measures included the Constant score, the self-report section of the ASES score, the SF-36 Health Survey and measurements of pain, strength and pain-free mobility of the shoulder and patient satisfaction. The outcome assessor was blinded to the patient's treatment allocation. Patients from the physiotherapy group who complained of lack of improvement after at least 15 treatment sessions were re-examined and, if inadequate improvement was confirmed clinically and by the scores, secondary surgical treatment was offered. In these cases the last scoring result prior to secondary surgery was carried forward to the analyses. After secondary surgery these patients were followed as a separate group (secondary surgery group) with outcome measurements performed after 6 and 12 months. In the surgical group, the integrity of the repaired tendon was assessed on MRI after 12 months.

Results: Demographic data and study scores were comparable between groups at inclusion. Nine of 51 patients (18%) in the physiotherapy group did not show improvement after a mean of 24 (range 15 to 34) training sessions and were converted to secondary surgery. One patient, who had been allocated to surgical treatment, withdrew from the study before treatment was started.

Within-group analysis showed significant rises in scores from baseline to 12 months in both groups. Between-group comparison showed significantly better results for the surgery group on several scales. On the Constant scale, a 13.0-point ($p = 0.002$) larger increase was found for the surgery group after 12 months. On the ASES scale the corresponding difference between groups was 16.1 points ($p < 0.0005$). Patient satisfaction after 12 months as measured on a VAS scale was better after surgery (9.0 cm) than after physiotherapy (7.2 cm, $p < 0.0005$).

In the secondary surgery group the increase on the Constant scale was 33.9 points compared with 41.9 points in the primary surgery group. Using the results of secondary surgery instead of the last observation carried forward technique for the nine crossover patients in the main analysis would have reduced the between-group difference on the Constant scale to 7.7 points ($p = 0.04$).

Control of the integrity of the repaired tendon in the primary surgery group showed an intact rotator cuff in 38 cases (76%), a partial-thickness tear in 6 cases (12%), a full-

thickness tear in 4 cases (8%) and an inconclusive result in 2 cases. In the secondary surgery group 8 of 9 tendons were diagnosed as intact.

Conclusion: Our analysis of the results of physiotherapy and tendon repair in the treatment of small and medium-sized rotator cuff tears after 12 months showed greater benefits after tendon repair on several scoring scales. On the other hand, 42 of 51 conservatively treated patients accepted the results achieved by physiotherapy as their final treatment results, and nine patients with no effect from physiotherapy were effectively treated by secondary surgery.

Paper IV

Background: Asymptomatic rotator cuff tears have been detected in earlier studies with varying prevalence (6.1 to 33.9%) (49-51;144;145). The aim of this study was to determine the prevalence and characteristics of asymptomatic full-thickness tears by sonographically screening a large group of subjects with no shoulder problems.

Patients and Methods: Clinical and sonographic shoulder examination was performed on 420 subjects with at least one asymptomatic shoulder in the age groups 50 to 59, 60 to 69 and 70 to 79 years. Criteria for an asymptomatic shoulder were absence of acute and earlier pain and subjective dysfunction, and a score of 90 points or more on the ASES scale. Sonography was performed by an experienced examiner and a full-thickness tear of the rotator cuff was the positive finding of interest. Tear size, tear location, the condition of the long head of the biceps muscle, and the amount of effusion in the subacromial-subdeltoid bursa and the biceps tendon sheath as assessed by sonography were registered. To control for false positive findings, additional MRI examination was performed on subjects with a full-thickness tear on sonography. To control for false-negative findings MRI was performed on subjects with a sonographic finding of a partial-thickness tear or severe tendon degeneration. Tear prevalence was calculated per subject, not per shoulder.

Results: A full-thickness tear was found in 32 of 420 subjects (prevalence 7.6%). Association between prevalence and increasing age was highly significant ($p < 0.0005$). Agreement between findings from sonography and MRI was good. Analysis of tear characteristics by sonography showed a tear size of ≤ 3 cm in 30 of 32 subjects (94%) and a tear location limited to the supraspinatus in 25 of 32 subjects (78%).

Conclusion: Our finding of a significant association between age and tear prevalence is in accordance with results from other studies. The overall prevalence of asymptomatic tears of 7.6% in our study group, however, was lower than in most of the earlier reports.

Paper V

Background: It is not understood why some rotator cuff tears are asymptomatic while others cause shoulder pain and dysfunction. Differences in tear anatomy may be suspected. The aim of this study was to compare MRI findings in two groups of subjects with rotator cuff tears with and without symptoms.

Patients and Methods: Findings from standardized MRI examinations from 50 asymptomatic and 50 symptomatic shoulders were compared. The asymptomatic group consisted of subjects with at least one shoulder with no history of acute or earlier pain or dysfunction, 90 points or more on the self-report section of the ASES score and the finding of a full-thickness rotator cuff tear on both sonography and MRI. Asymptomatic subjects differed with respect to the contralateral shoulder, which was painful in 22 cases and pain-free in 28 cases (asymptomatic subgroups).

The symptomatic group consisted of shoulders referred to our outpatient clinics for atraumatic shoulder pain with clinical, sonographic and MRI findings consistent with a full-thickness rotator cuff tear.

MRI examinations from asymptomatic and symptomatic shoulders were randomly mixed and independently evaluated by two experienced musculoskeletal radiologists. Tears were classified as small (≤ 3 cm) or large (> 3 cm) and as superior-anterior or superior-posterior. The long head of the biceps muscle was classified as intact or torn. The supraspinatus muscle volume was classified according to Thomazeau et al. and Zanetti et al. as normal/moderately atrophied or severely atrophied. Fatty degeneration of the rotator cuff muscles was classified according to Goutallier et al. and Fuchs et al. as low or severe. Tear characteristics were compared between the two main groups. Additional analyses were performed separately for the two asymptomatic subgroups.

Results: MRI-determined tear characteristics that were found to be associated with symptomatic rotator cuff tears were (1) a tear size > 3 cm in the medial-lateral plan ($p = 0.007$), (2) a positive tangent sign ($p = 0.04$) and (3) a high degree of fatty degeneration in the supraspinatus ($p = 0.004$) or the infraspinatus muscle ($p = 0.009$). Comparison of the symptomatic group with each of the two asymptomatic subgroups separately showed larger ORs for all MRI derived factors for the comparison with the subgroup of asymptomatic subjects with a painfree contralateral shoulder.

Conclusion: Significant differences between symptomatic and asymptomatic rotator cuff tears were found for several MRI-determined tear characteristics. As differences were

larger for the subgroup of bilateral asymptomatic subjects, the condition of the contralateral shoulder has to be taken into consideration in studies of asymptomatic rotator cuff tears.

9. General discussion

9.1 Diagnosis of rotator cuff tears (Papers I and II)

Patients

In Papers I and II the effectiveness of sonography in diagnosing rotator cuff tears in painful shoulders was assessed. In studies of the effectiveness of diagnostic tests, adequate patient selection is crucial and the eligibility criteria must be clearly defined. Multiple sources of bias exist and have to be borne in mind when evaluating the findings from this type of study. Study results are only valid for patients comparable to those included, and cannot be transferred to other groups of patients.

Our two diagnostic studies were conducted in an orthopaedic shoulder unit on patients referred by general practitioners for chronic shoulder pain and dysfunction. The patients were included prospectively and consecutively. The criteria for referral were not standardized and were often unclear. Most of the patients were referred because they were not responding to treatment measures given in primary care, which means that they may represent a selection of more severe and more chronic “problem patients” (selection bias). The pathology may be more discernible on imaging tests in more severe cases, which means that the agreement between the index and reference tests may be inflated.

Furthermore, the reference test (diagnostic arthroscopy, open surgery) was part of an invasive therapeutic procedure and consequently only performed on the subgroup of patients with surgical indications. Among those who had undergone sonography initially (350 patients in both studies), such indications were found for 79 (Paper I) and 58 (Paper II) patients respectively. Again, this may have resulted in study groups consisting of more serious cases (partial verification bias).

However, bias during patient selection cannot always be excluded. Analysis of other studies in the field shows that selection and partial verification bias could have played a role in most of them. This may explain the high prevalence (range 35-70%) of full-thickness tears of the rotator cuff in the majority of published materials (70;72;75;84;123;146;147). In our studies selection bias was accepted as our aim was to present results for the use of diagnostic ultrasound in a specialist setting and not in primary

care. Partial verification bias could not be excluded as it would have been unethical to perform a surgical procedure on subjects without indication, and there is no alternative non-invasive gold standard. Consequently the validity of our results is limited to the group of secondary care patients with surgical indications.

Methods

The examiner

In methodological studies of diagnostic ultrasound, details of the examiner interpreting the test must be provided as they may influence the study results. The results may vary according to whether the examination was performed by a radiologist, an orthopaedist or a rheumatologist, and may also depend on the examiner's level of experience of the method. Most of the fundamental studies in the field have been written by very experienced radiologists, who have stated that sonography of the shoulder has a long learning curve and depends heavily on examiner experience (70;76;140;141). However, scientific proof of this statement is weak (148-150). In our two studies the examiner had little (Paper I) and medium (Paper II) experience, and thus our findings reflect performance in the lower part of the learning curve.

Sonography

Technical details of the intervention are important information as they may influence the study results. The examination techniques and diagnostic criteria used in Papers I and II were largely based on the work of Middleton et al., Bouffard et al., and Teefey et al., which are considered to represent the state of the art in sonography of the shoulder (72;76;77). We had access to a linear array transducer with frequencies ranging from 5.5 to 9.4 MHz during both our studies. This is in contrast to more recent studies, where transducers of 10 MHz and more have been used (147;150). Transducers with higher frequencies give better image resolution and will potentially lead to increased diagnostic reliability.

Methodological biases

In Paper I, the sonographer was not blinded to the patient's history, physical examination findings and the results of previous radiographic and MRI examinations, nor were the surgeons blinded to clinical and imaging reports prior to surgery. The interpretation of sonographic results may therefore have been influenced by the results of examinations performed prior to sonography, and the interpretation of the reference test may have been

influenced by the results of examinations performed prior to surgery. An examiner who is aware of the result of one test may spend more (or less) time searching for pathology in a later test if he knows that it has already been (or not been) shown by the first test (verification bias). This could have influenced our study results. However, using a test as one of a group of diagnostic modalities reflects daily clinical practice. In this study we did not want to analyse sonography as an isolated technique but as part of a diagnostic algorithm for rotator cuff tears and biceps tendon pathology.

In Paper II we tried to exclude verification bias. It has been shown that rotator cuff tears can be diagnosed clinically in cases presenting typical examination findings (65;67;68;142;143). Knowledge of clinical information may therefore have influenced the interpretation of sonographic findings in earlier studies. This hypothesis is supported by the findings of Iannotti et al. (149) who reported that more accurate results were obtained by a sonographer who was aware of the patient's clinical examination findings than by a blinded examiner. Consequently, in Paper II the sonographer was blinded to previous examination findings and the surgeon to the findings from sonography.

The reference test

Diagnostic arthroscopy is widely accepted as the gold standard of reference for imaging studies of the rotator cuff and the long head of the biceps muscle. However, its accuracy in determining the true disease status of these structures depends on examiner experience. Small full-thickness tears may be overlooked and grading of partial thickness tears can be difficult. Information about the experience of the examiner performing arthroscopy as the reference test is therefore important. In Paper I arthroscopy and in some cases open surgery were performed by different, experienced surgeons from our orthopaedic department. This may have lead to inter-observer differences in the diagnosis of rotator cuff tears and biceps tendon pathology, but it reflects the daily clinical situation, where diagnostic criteria for these conditions may vary between arthroscopists. In Paper II inter-observer variation was excluded as all the dagnostic procedures during arthroscopy were performed by a single, experienced, orthopaedic surgeon.

Results

Paper I

In Paper I we present the sensitivity and specificity of sonography for the diagnosis of full-thickness rotator cuff tears when used by an orthopaedic surgeon with little experience of the method. Although it is a widespread assumption that successful shoulder sonography requires long examiner experience, our results were not very different from those achieved by experienced sonographers. There are several possible explanations for this early success of an orthopaedic surgeon. Performing history-taking, physical patient examination and sonography together makes it possible for the orthopaedist to focus the sonographic examination on his clinical findings. Furthermore, being confronted with his own sonographic findings during the subsequent operation enables the surgeon to correct his sonographic interpretation by directly comparing it with his surgical findings. This type of feed-back from surgery may enhance the learning process.

Paper II

A review of the existing literature on shoulder sonography shows that many results may have been influenced by verification bias. In almost all studies the sonographers were aware of the patient's history and the physical examination findings (69-75), and in some studies the surgeon was not blinded to the sonographic findings (149). Theoretically, verification bias should inflate the diagnostic accuracy of sonography in relation to the reference test. However, our finding of a sensitivity and specificity of over 90% in a blinded setting is in good accordance with findings from unblinded studies, which indicates that verification bias may have only a minor influence on the results of these studies.

Partial-thickness rotator cuff tears

In both papers we attempted to diagnose partial-thickness tears as a separate entity. In contrast to our results for full-thickness tears, however, the sonographic sensitivity and specificity for these tears were low. This is in accordance with findings from other publications where lower sensitivity and specificity of sonography for small full-thickness tears and partial-thickness tears have been found (74;80-82;151). The very low accuracy found in our studies could be due to limited examiner experience (Paper I), blinding to clinical information and/or the high proportion of superficial partial-thickness tears (grade 1 according to Ellman) (Paper II) (152). Finally, the use of technical equipment with a

maximum transducer frequency of only 9.4 MHz in both studies may also have contributed to our results.

9.2 Treatment of rotator cuff tears (Paper III)

Tendon repair and physiotherapy are frequently used to treat full-thickness rotator cuff tears. However, currently there is no accepted standard for treatment selection. Based on tear characteristics and patient expectations, indication for one of the two treatments may be obvious in some cases but unclear in others. Existing scientific evidence for treatment selection is weak, and therapeutic decisions often depend on the patient's preference or are the result of a period of failed conservative treatment. Most previous studies have been designed as retrospective (94-96;98) or prospective case series, (100;117-119;153-157) which means that although they have shown that both treatment methods are effective, they have serious limitations, mainly due to selection bias and differential loss to follow-up. Their results should be used to develop hypotheses rather than to guide practice. Comparison of the two treatment modalities should be performed in randomised controlled studies. If adequately designed, those studies will provide results that are least likely to be affected by bias. To our knowledge, Paper III represents the first attempt to present a study of this kind for the comparison of treatment effects from tendon repair and from physiotherapy for small- and medium-sized full-thickness tears of the rotator cuff (88-90). However, randomized controlled studies are methodologically challenging and the validity of their results depends on appropriate study design.

Patients

Lack of external validity is a frequent criticism of randomized controlled studies. External validity reflects the generalizability of the study results and depends on the pathway to recruitment (patient referral, investigation and diagnostics), the eligibility criteria and the methodological criteria related to interventions and outcome measures. Although results from randomized controlled studies cannot be expected to apply to all patients and settings, trials should be presented in a way that makes it possible for the reader to assess their relevance.

In our study, all 281 patients with a rotator cuff tear who were assessed for eligibility had been referred by general practitioners, which means that they represented the subgroup of

patients with symptoms that had not responded to primary health care treatment. Of these, only 103 (37%) met the eligibility criteria of our study. In consequence the applicability of our findings is limited to a Scandinavian secondary health care setting and to the proportion of patients fulfilling the inclusion and exclusion criteria in our study protocol.

The purpose of randomization is to create patient groups that are balanced for prognostic variables and that differ only with respect to the intervention. However, between-group differences at baseline may arise by chance and may influence study results. In our study, patient characteristics at time of enrolment showed good comparability between study groups. For our two shoulder-specific scores, only small baseline differences were found. To examine the impact of these differences on our study results, analyses were performed both adjusted and unadjusted for baseline differences. Both analyses resulted in the same conclusions, thus supporting the validity of our results.

Methods

Interventions

To allow generalizability, study interventions have to reflect normal clinical practice and should be performed by clinicians with a level of training and experience that is comparable to those of most other clinicians in the field. Surgical treatment in our study was performed by open or mini-open tendon repair together with acromioplasty, and consequently our results may differ from those obtained by the use of other current techniques like arthroscopic repair or repair without acromioplasty. However, as long as there have not been reported significant differences between the results of these treatment methods (108;109;117-119;153-157), our surgical intervention may be considered to be a gold standard. Furthermore, as all surgical treatment was performed by one of three experienced but not extremely specialized orthopaedists, our surgical results should be comparable to those from routine clinical practice.

In our study physiotherapy was provided as outpatient treatment by one of four physiotherapists at our hospital. Treatment was given according to a rehabilitation programme developed prior to the study in a non-standardized manner. Selection of exercises, number of repetitions and duration of treatment were individually tailored according to examination findings and treatment progression. This is in accordance with modern state-of-the-art treatment strategies for shoulder patients. However, as

physiotherapy regimes may differ substantially between physiotherapists and institutions, the generalizability of our results from physiotherapy is limited to comparable treatment protocols.

Outcome measures

To support the validity of a study, outcome measures should be appropriate to the research question, clinically relevant, tested for validity, reliability and responsiveness, and reflect the patient's priorities. Established scales in general use should be preferred in order to facilitate comparability with similar studies. An appropriate time horizon for times and duration of follow-up has to be defined.

To allow for a broad evaluation of treatment effects, we employed a number of different outcome measures at follow-up, including two shoulder-specific scales (Constant score, ASES score), and a generic quality of life instrument (SF-36). Shoulder specific scores had to be selected among a large number of existing questionnaires, all with different strengths and weaknesses. To our knowledge none of them has been adopted as a standard for the follow-up of patients with a rotator cuff tear by the orthopaedic community.

Our selection of the Constant score as the primary outcome measure was based on its widespread use in earlier studies and its combination of subjective (pain, activities of daily living) and objective (ROM, shoulder strength) measurement components, which were considered to be appropriate to the research question. However, the score has been criticized for the fact that the evaluation of its validity and reliability is incomplete, and that its minimal clinically important change has never been defined (130;131). However, the validity of our results is supported by the fact that the findings from our second shoulder-specific instrument, the self-report section of the ASES score, were very close to those from the Constant score. The validity, reliability and responsiveness of the ASES score with regard to the follow-up of dysfunction of the shoulder have been demonstrated, (133) and good correlations have been shown between the measurement results of ASES and those of the Constant score in shoulder patients (158).

To provide a more comprehensive assessment of treatment effects, the shoulder-specific scores were supplemented by a generic health questionnaire (SF-36) at follow-up. Generic outcome scales have the advantage of measuring the relative impact of shoulder pathology

on general health status and quality of life, but the disadvantage is that small but important changes may be overlooked. However, the results can be used to evaluate the impact of various medical and surgical interventions in a wide range of diseases.

Sample size

An essential step in the planning of a randomized controlled study is estimating the necessary sample size. The following values must be determined prior to study start: a clinically relevant primary outcome measure, the minimum difference considered to be clinically relevant, the expected variance of the data and the risk levels for type I and type II errors (risk of a false positive or a false negative conclusion). In Paper III the Constant score was selected as the primary outcome measure, and risk levels for type I and type II errors were set at 5% and 15% respectively. Standard deviation for change of score was estimated to be 20 Constant points, based on measurement findings from previous patients at our hospital. This value was in fact very close to the values found in our study population after 6 (SD 20.7) and 12 months (SD 21.7). The value on the Constant scale that reflects the minimum difference considered to be clinically relevant, however, has never been determined in studies of the psychometric properties of the score. We therefore based our estimation of the value on clinical judgement and the existing literature (159-161). The value of 12 points on the Constant scale that was chosen for calculating the sample size is therefore a subject for discussion.

Blinding

As knowledge of a patient's assignment to a group may influence the process of outcome assessment, studies should be designed with a high degree of blinding of all study contributors. Patients, health care providers, outcome assessors and those who analyse study data may all be influenced by knowledge of the treatment. In surgical studies, however, maximum blinding is often not possible. Comparison of operative and non-operative treatment in Paper III allowed only for blinding of the outcome assessor. The patients were informed prior to every follow-up examination that treatment status had to be concealed from the outcome assessor and that the examination had to be performed with the shoulder covered by a T-shirt.

Data analysis

To preserve similarities in determinants of outcome between groups in randomized clinical trials, data analysis should be performed according to the intention-to-treat principle. This means that all study patients are included in the final analysis according to the treatment group to which they were originally allocated. However, strict application of the intention-to-treat principle is sometimes difficult because patient cross over from one study treatment to the other and because of missing data. In Paper III, nine of 51 patients (18%) with unsatisfactory results from physiotherapy wanted to change treatment group, and obliging them to continue with ineffective treatment sessions would have been unethical. These patients were treated by secondary surgery and for this group the set of non-operative follow-up data is incomplete. In a strict intention-to-treat analysis the results of secondary surgery would have to be used for outcome analysis. However, such an analysis would no longer represent a comparison between operative and non-operative treatment because it would mean that surgical results were being used for some of the patients originally allocated to physiotherapy. Further, in our study replacing missing non-operative data from patients with no effect from physiotherapy by the far better results from secondary surgery would have inflated the outcome from the physiotherapy group.

In Paper III we therefore conducted a modified intention-to-treat analysis, where missing non-operative data from crossover patients were treated according to a last-observation-carried-forward principle. This means that the last result from non-operative treatment prior to secondary surgery was carried forward for further analysis. This result was assumed to represent our best estimate for the final result from physiotherapy. The analysis takes no account of the possibility of a change in score as a result of continued non-operative treatment. As proposed in the literature, a supplementary secondary analysis according to a strict intention-to-treat principle was performed and the results are given in the discussion part of Paper III for comparison (162-166).

Results

The main result of the study in Paper III is a 13-point-larger increase on the Constant scale from baseline to one-year follow-up after tendon repair of full-thickness tears up to 3 cm in diameter as compared with non-operative treatment. Comparing this result with results from other studies in the field is difficult because of important methodological differences between studies. Most of the earlier studies are case series or non-randomized trials (167),

where patients could have been selected on the basis of the investigator's preconception of tear characteristics that are favourable for successful non-operative or operative treatment.

These studies are also susceptible to bias through differential loss to follow-up. In many of them, patients who experienced no effect from the trial treatment and who had crossed over to alternative treatment regimes during follow-up were excluded from the analysis (94;99;100), which could have led to an overestimation of treatment effects.

Another problem affecting between-study comparisons is the use of different scoring systems. Comparisons may be possible between shoulder scoring instruments for which significant outcome correlations have been demonstrated (135;136;158), but for many shoulder scores no such analyses have ever been performed.

These limitations should be borne in mind when between-study comparisons are presented. Both Cofield (113) and Ruotolo et al. (168) have reviewed the literature and compared outcomes from studies of operative (169-174) and non-operative treatment (94;95;98;100;175). In both reviews, the successful outcome after non-operative treatment was reported to be 50% as compared with 85% after operative treatment.

Statistically significant findings from randomized studies must be assessed for clinical relevance. Our between-group difference of 13 Constant points was both statistically significant and higher than our preselected cut-off value for clinical relevance. The clinical importance of our result is further supported by the ASES score and the measurement of patient satisfaction. For the ASES score, the minimum clinically important difference and the minimum detectable change have been defined as 6.4 and 9.7 points respectively (133), and are thus exceeded by our finding of a 16.1-point between-group difference after one year. Finally, a difference of 1.8 cm on the 10 cm VAS scale for patient satisfaction at one year is an indication of the relevance of our findings to clinical practice.

The time horizon for follow-up can influence the validity of study results. Ideally, patients should be followed up until a final result that is constant over time is achieved, and obviously a follow-up time of one year does not meet this requirement. Deterioration is to be expected, especially in the non-operative group and in patients with unsuccessful tendon repair (94;97). According to the findings of Yamaguchi et al. (176), an unrepaired rotator

cuff may be at risk for progression of tear size and deterioration of muscle and tendon quality, resulting in the recurrence of symptoms. Patients' non-compliance with measures aimed at maintaining the results of physiotherapy may also lead to symptom recurrence. Therefore the results presented in Paper III must be regarded as provisional and further outcome analyses are necessary.

It is important to compare the results of secondary surgery with those of primary surgery in our study. Large differences would represent an ethical dilemma, as non-responders to physiotherapy would be at risk of a very poor treatment result. In Paper III, operations on patients in the secondary surgery group were performed after an average delay of 5 months, and the result on the Constant scale was 7.5 points poorer than for the primary surgery group. We consider this difference to be small, but the validity of the result is limited by the low sample size.

Finally, the consequences of our findings for clinical practice should be discussed. The tear characteristics, symptoms, and activity requirements of patients diagnosed with a tear of the rotator cuff vary widely, and treatment cannot be standardized. Some patients will prefer non-operative treatment because it has less treatment-related morbidity. Avoidance of a long period of postoperative rehabilitation together with the possibility of secondary surgery in the event of insufficient treatment effect may make non-operative treatment attractive to these patients. In our study the low rate of crossover (9/51) and the good effects of secondary surgery are likely to encourage this attitude. However, on the basis of the results from Paper III, patients should be informed that one-year results of surgery are on average superior to those of physiotherapy. In our study between-group differences have been quantified for the first time according to different shoulder scoring scales and in terms of subscores for pain, range of motion, strength and patient satisfaction. This should improve the basis for therapeutic decisions. However, evidence of the medium- and long-term effects of the two treatment measures is still weak.

9.3 Asymptomatic rotator cuff tears (Papers IV and V)

Rotator cuff tears are often associated with shoulder pain and dysfunction. Asymptomatic tears, however, have been revealed in cadaver studies and in sonographic and MRI screening studies of the general population. Reported prevalences vary between studies,

and information about the factors causing symptoms is sparse. Papers IV and V were designed to assess the prevalence of asymptomatic rotator cuff tears in a Norwegian population group and to explore associations between MRI-determined predictor variables and symptoms from a rotator cuff tear. Both studies are based on observational research. Even when such studies are well designed, the results are often influenced by bias and confounding (177;178). This may explain some of the variations in the results from earlier, comparable studies. However, observational study design is an appropriate choice for assessing many health-related events, including those relating to our research questions. Potential sources of bias and confounding should be analysed and reported so that the reliability of the study results can be evaluated.

Patients

Paper IV

The prevalences reported in the majority of previous studies are higher than our finding of a 7.6% prevalence of asymptomatic rotator cuff tears. Several factors related to study populations and individual study subjects may have contributed to these differences. Firstly, prevalences may differ between study populations because of racial differences and differences in work- and leisure-time-related demands on the shoulder. Our study was performed on subjects taken from the urban Norwegian population, most of whom had not been exposed to heavy demands on the shoulder, and the validity of our results is limited to comparable settings.

Secondly, the validity of study results depends on the inclusion of only true asymptomatic shoulders into the study sample. Whether a shoulder is and has been asymptomatic, however, has to be based on the subject's self-evaluation. Even if self-report of shoulder function is supplemented by more objective measures like pain-free ROM and shoulder strength, patient selection may be affected by recall bias. Study subjects may forget or neglect earlier periods of shoulder pain and dysfunction, and previously symptomatic rotator cuff tears may consequently be included.

Thirdly, the shoulder is a paired organ and the condition of the contralateral shoulder may be of interest. In study IV, contrary to many earlier studies (49;50;145), we also included 120 subjects who presented with only one asymptomatic shoulder. Exclusion of these subjects from analysis would have resulted in selection bias, as they represent an important

part of the general population and may have a tear in their true asymptomatic study shoulder. Not including these subjects in the analysis would have restricted the generalizability of our findings to persons with bilateral asymptomatic shoulders only. On the other hand, self-evaluation of the study shoulder in these cases may be biased by pain on the other side. These subjects may compare their two shoulders and tend to overlook minor symptoms in the study shoulder as they experience it as having fewer problems than the reference shoulder. Again, this could lead to the inclusion of symptomatic shoulders in the sample.

Paper V

In Paper V, cases (symptomatic rotator cuff tears) and controls (asymptomatic rotator cuff tears) were compared retrospectively for certain predictive factors for symptoms of a rotator cuff tear diagnosed on MRI. The creation of valid case and control groups is challenging in this type of observational study. Ideally, the cases should be a random sample of all subjects with a symptomatic rotator cuff tear. All our cases, however, were referred by general practitioners for secondary care treatment, which means that they represent a selection of patients who were unresponsive to primary health care treatment. Thus they could represent cases with larger tear sizes or higher degrees of muscle atrophy and degeneration (selection bias).

Methods

Paper IV

Paper IV presents a cross-sectional study. It was designed to avoid methodological weaknesses that could have influenced the results of previous studies. Sonography was performed by an examiner with documented experience of more than 2 000 sonographic examinations of painful shoulders and who had published results showing a diagnostic sensitivity of 97% and a diagnostic specificity of 100% for the sonographic detection of full-thickness rotator cuff tears. The sonographic equipment was of high quality, including a transducer frequency ranging from 7 to 12 MHz and use of tissue harmonic imaging. Control of sonographic findings by MRI was performed in a large number of subjects to assess the validity of the sonographic results. Finally, a sample size exceeding that of earlier studies was chosen, and balance in the three age groups was achieved by proportionate stratification.

Paper V

This paper presents a case-control study. A power analysis showed that a sample size of 50 cases and controls was needed. Thirty controls were found during the prevalence study (Paper IV) and the group of controls had to be enlarged by adding subjects referred to our outpatient clinics for unilateral shoulder problems in whom bilateral examination showed an asymptomatic contralateral rotator cuff tear. Thus the controls consisted of two subgroups who differed with regard to the condition of the contralateral shoulder. As all presented with a true asymptomatic index shoulder, it was considered acceptable to include them in the control group, and subgroup analysis was initially not planned. However, the results showed larger differences in prognostic values between bilateral asymptomatic controls and cases than between unilateral asymptomatic controls and cases. As existing knowledge about the characteristics of asymptomatic rotator cuff tears is partly based on results from studies that include subjects with unilateral asymptomatic shoulders only, this is important information (176;179). Given the insufficient sample sizes in our two asymptomatic subgroups, the finding must be regarded as a secondary result only, and requires further exploration.

The predictor variables in Paper V were selected on the basis of existing knowledge about their potential influence on symptoms from rotator cuff tears (176;179-182). We hypothesized positive associations between a larger tear size, an anterior tear location, the presence of a biceps tendon tear, and severe atrophy or fatty degeneration on one side, and symptoms from the rotator cuff tear on the other. Predictor variables were graded on the basis of MRI findings, which can be influenced by measurement error and misclassification. For most of the potential prognostic factors used in our study, however, earlier research has shown high reliability of findings from MRI compared to a reference standard. For tear size measurement on MRI, Bryant et al. (85) and Kluger et al. (78) found good interobserver agreement and good correlation to intraoperative measurement. For measurement of rotator cuff muscle volume, Tingart et al. (183) found intraobserver and interobserver variability of less than 4% for a three-dimensional reconstruction of rotator cuff muscle volume based on tracing of muscle contours on MRI. For grading of fatty muscle degeneration on MRI, Fuchs et al. (61) found good to excellent interobserver reproducibility, while Oh et al. (184) reported good to moderate intraobserver and interobserver reliability with the best results coming from experienced radiologists.

Results

Paper IV

Our finding of an age-related increase in the prevalence of rotator cuff tears in the general population with no shoulder problems is in good agreement with findings from earlier reports (49;50). Prevalences for defined age groups, however, vary widely between earlier studies and the true prevalence of asymptomatic tears in the general population is still unclear. Prevalences have been reported from cadaver studies (185-189) and from radiological studies using MRI (49;190-193) or sonography (47;50-52;144;145). Cadaver studies have the advantage of high diagnostic validity but are unable to provide clinical details. This means that the study sample may include symptomatic shoulders, which in turn could result in an exaggeration of the underlying true prevalence. The prevalence may be further increased by the older mean age of the cadaver samples compared with the general population. The prevalence reported by the majority of cadaver studies ranges from 5% to 20% (185-189). Reports of higher values (up to 40%) are generally based on small samples (less than 100 shoulders), high mean ages (> 75 years) or both (194-196).

Selection of true asymptomatic samples and adequate age groups is possible in radiological studies, and lower prevalences than in cadaver studies should be expected here. On the other hand, results from imaging studies may be affected by diagnostic error. Prevalences ranging from 6% to 34% have been reported in MRI- and sonography-based studies (47;49-52;145). Prevalences higher than those from cadaver studies are difficult to explain. Our finding of a prevalence of 7.6% for a sample with a mean age of 64.8 years fits well with the theory that in vivo studies show a slightly lower prevalence than cadaver studies. Together with the result reported by Schibany et al. (51) (prevalence 6.1%, mean age 67 years) our finding is the lowest prevalence reported for comparable age groups in radiologic studies. The good agreement in our study between the sonographic findings and findings from supplementary MRI supports the validity of the results. Differences between our findings and findings from other studies may be explained by methodological differences such as examination technique, technical equipment, examiner experience and diagnostic criteria, but may also reflect true prevalence differences between different population groups.

Paper V

Little information is available about morphologic differences between asymptomatic and symptomatic rotator cuff tears and about the natural history of asymptomatic tears. This means that we lack information relevant to clinical practice, as therapeutic action should be directed against the symptomatic aspects of a rotator cuff tear. In earlier studies, symptoms from rotator cuff tears have been found to be associated with larger tear sizes (179) and proximal humeral migration during active arm elevation (197). In these studies, comparison of tear groups with and without symptoms was based on radiography or ultrasound, which means that muscle atrophy and degeneration could not be assessed and classified. In our study shoulders were examined by MRI in order to obtain results that could be analysed in this way. We found positive associations with symptoms from rotator cuff tears for larger tear sizes and for more serious degrees of muscle atrophy and fatty degeneration, the latter representing new knowledge. Causal relationships between these tear characteristics and tear symptoms could not be established on the basis of our study, but our findings fit well with earlier study results. In a cross-sectional study of patients with a symptomatic rotator cuff tear in one shoulder and an asymptomatic tear in the other, Yamaguchi et al. found larger tear sizes on the symptomatic side (179). In a longitudinal study (176), the same authors followed asymptomatic rotator cuff tears sonographically and clinically over five years and found development of symptoms in 51% (23/45) and progression of tear size in 39% (9/23) of cases. Of those who developed symptoms, 50% (7/14) showed tear size progression compared with 22% (2/9) in the group who did not. Consequently, if tear size is positively correlated to symptoms and increases over time, initially asymptomatic rotator cuff tears might be at risk for development of symptoms. The negative correlation between tear size and prognosis for a tendon repair (198) should have consequences for follow-up, and unrepaired tears with no symptoms, including those after successful conservative treatment, should be followed up clinically and by imaging so that appropriate therapeutic action can be taken in time.

Paper V presents an early explorative study of a field about which there is currently little information. The aim was to generate explanatory hypotheses for the symptomatic status of rotator cuff tears. MRI-determined factors significantly associated with tear symptoms were found, but wide confidence intervals reflect the uncertainty related to our findings. Further exploration of these factors in different study samples, preferably with a longitudinal study design, is needed.

10. Contributions to existing knowledge

Paper I

In several fundamental studies on diagnostic sonography of the shoulder it has been stated that sonography is a difficult technique with a long learning curve. Our study, however, showed that a relatively inexperienced orthopedic surgeon achieved high accuracy in the diagnosis of full-thickness rotator cuff tears and biceps tendon pathology.

Paper II

Earlier studies on the accuracy of diagnostic shoulder sonography have been criticized for the potential influence of verification bias on study results (199). We tried to avoid such bias by blinding the sonographer to clinical findings and the surgeon to sonographic findings, and found a sensitivity and specificity for sonographic diagnosis of full-thickness rotator cuff tears comparable to those from unblinded designs.

Paper III

Non-operative treatment by physiotherapy and operative treatment by tendon repair are central to the treatment of full-thickness rotator cuff tears. Up to now the effectiveness of these treatment methods has been assessed in case studies only, which has made it difficult to assess whether either of these treatments is superior to the other. To our knowledge, Paper III presents the first published study with a randomized controlled design that compares the results of the two treatment methods. At one-year follow-up we found a greater increase in study-scores after operative treatment.

Paper IV

In vivo examinations of asymptomatic shoulders have been performed by MRI and sonography to assess the prevalence of asymptomatic rotator cuff tears in the general population. In contrast to the results from earlier studies, we found a low prevalence of asymptomatic tears of only 7.6%, in the age group 50-79 years. This may indicate a lower occurrence of these tears than has previously been assumed, at least in some population groups.

Paper V

The reason why some rotator cuff tears are asymptomatic while others cause symptoms is still unknown, but differences in MRI-determined tear characteristics are a possible explanation. Our finding of a difference in tear size between symptomatic and asymptomatic rotator cuff tears confirms those of earlier studies. However, the finding of between-group differences in the degree of fatty degeneration and muscle atrophy in our study has not previously been reported.

11. Future research

Diagnostic studies

The majority of studies assessing the diagnostic accuracy of sonography for the detection of rotator cuff tears have been performed on groups of secondary care patients for whom surgical treatment was indicated. Future studies should include the large group of shoulder patients who are treated in primary health care or who are successfully treated by non-operative methods. These patients may represent a low-prevalence group for rotator cuff tears, and the diagnostic accuracy of sonography for such samples has still to be demonstrated. As it would be unethical to perform surgery on these patients, a less invasive reference test (MR arthrography?) will have to be used. The cost-effectiveness of sonography as compared with alternative methods like MRI should also be addressed.

Therapeutic studies

Few high-quality trials have yet been conducted comparing frequently used treatment methods for rotator cuff tears. Our randomized study comparing tendon repair with physiotherapy should be followed-up by similar studies on different population groups and by multi-centre studies. Given the short-term follow-up of only one year our results cannot be used as a basis for firm therapeutic conclusions. Medium- and long-term follow-ups are necessary and are currently being conducted.

Asymptomatic rotator cuff tears

Differences in characteristics between symptomatic and asymptomatic rotator cuff tears have been detected in several studies, but no causal relationship between these characteristics and symptoms from a tear has been established. Longitudinal studies are needed to investigate this question. As asymptomatic rotator cuff tears can be followed up without being influenced by therapeutic measures, longitudinal studies would provide insight into the natural course of the condition. Longitudinal follow-up would show whether these tears remain asymptomatic over time and whether changes in tear characteristics result in development of symptoms. A three-year clinical, sonographic and MRI follow-up of our asymptomatic tear group is currently being conducted.

12. References

- (1) Codman EA. The shoulder. The rupture of the supraspinatus tendon and other lesions in and about the subacromial bursa. 1934;
<http://www.shoulderdoc.co.uk/article.asp?section=609>
- (2) Clark JM, Harryman DT. Tendons, ligaments, and capsule of the rotator cuff. Gross and microscopic anatomy. *J Bone Joint Surg Am* 1992;74:713-25.
- (3) Dugas JR, Campbell DA, Warren RF, Robie BH, Millett PJ. Anatomy and dimensions of rotator cuff insertions. *J Shoulder Elbow Surg* 2002;11:498-503.
- (4) Curtis AS, Burbank KM, Tierney JJ, Scheller AD, Curran AR. The insertional footprint of the rotator cuff: An anatomic study. *Arthroscopy* 2006;22:603-9.
- (5) Ide J, Tokiyoshi A, Hirose J, Mizuta H. An anatomic study of the subscapularis insertion to the humerus: The subscapularis footprint. *Arthroscopy* 2008;24:749-53.
- (6) Kolts I. A note on the anatomy of the supraspinatus muscle. *Arch Orthop Trauma Surg* 1992;111:247-9.
- (7) Mochizuki T, Sugaya H, Uomizu M, Maeda K, Matsuki K, Sekiya I, Muneta T, Akita K. Humeral insertion of the supraspinatus and infraspinatus. New anatomical findings regarding the footprint of the rotator cuff. *J Bone Joint Surg Am* 2008;90:962-9.
- (8) Ruotolo C, Fow JE, Nottage WM. The supraspinatus footprint: An anatomic study of the supraspinatus insertion. *Arthroscopy* 2004;20:246-9.
- (9) Habermeyer P, Magosch P, Pritsch M, Scheibel MT, Lichtenberg S. Anterosuperior impingement of the shoulder as a result of pulley lesions: A prospective arthroscopic study. *J Shoulder Elbow Surg* 2004;13:5-12.
- (10) Nobuhara K, Ikeda H. Rotator interval lesion. *Clin Orthop Rel Res* 1987;223:44-50.
- (11) Harryman DT, Sidles JA, Harris SL, Matsen FA. The role of the rotator interval capsule in passive motion and stability of the shoulder. *J Bone Joint Surg Am* 1992;74:53-66.
- (12) Cooper DE, O'Brien SJ, Warren RF. Supporting layers of the glenohumeral joint. *Clin Orthop Rel Res* 1993;289:144-55.

- (13) Walch G, Nove-Josserand L, Levigne C, Renaud E. Tears of the supraspinatus tendon associated with “hidden” lesions of the rotator interval. *J Shoulder Elbow Surg* 1994;3:353-60.
- (14) Werner A, Mueller T, Boehm D, Gohlke F. The stabilizing sling for the long head of the biceps tendon in the rotator cuff interval: A histoanatomic study. *Am J Sports Med* 2000;28:28-31.
- (15) Bigoni BJ, Chung CB. MR imaging of the rotator cuff interval. *Radiol Clin North Am* 2006;44:525-36.
- (16) DePalma AF. The classic: Surgical anatomy of the rotator cuff and the natural history of degenerative periarthritis. *Clin Orthop Rel Res* 2008;466:543-51.
- (17) Prescher A. Anatomical basics, variations, and degenerative changes of the shoulder joint and shoulder girdle. *Eur J Rad* 2000;35:88-102.
- (18) Rothman RH, Parke WW. The vascular anatomy of the rotator cuff. *Clin Orthop* 1965;41:176-86.
- (19) Determe D, Rongières M, Kany J, Glasson JM, Bellumore Y, Mansat M et al. Anatomic study of the tendinous rotator cuff of the shoulder. *Surg Radiol Anat* 1996;18:195-200.
- (20) Ling SC, Chen CF, Wan RX. A study on the vascular supply of the supraspinatus tendon. *Surg Radiol Anat* 1990;12:161-5.
- (21) Rudzki JR, Adler RS, Warren RF, Kadrmas WR, Verma N, Pearle AD et al. Contrast-enhanced ultrasound characterization of the vascularity of the rotator cuff tendon: Age- and activity-related changes in the intact asymptomatic rotator cuff. *J Shoulder Elbow Surg* 2008;17:96S-100S.
- (22) Rathburn JB, Macnab I. The microvascular pattern of the rotator cuff. *J Bone Joint Surg Br* 1970;52:540-53.
- (23) Levy O, Relwani J, Zaman T, Even T, Venkateswaran B, Copeland S. Measurement of blood flow in the rotator cuff using laser Doppler flowmetry. *J Bone Joint Surg Br* 2008;90:893-8.
- (24) Burkhart SS, Esch JC, Jolson RS. The rotator crescent and rotator cable: An anatomic description of the shoulder’s “Suspension Bridge”. *Arthroscopy* 1993;6:11-6.
- (25) Seibold CJ, Mallisee TA, Erickson SJ, Boynton MD, Raasch WG, Timins ME. *Radiographics* 1999;19:685-705.
- (26) Lewis JS. Rotator cuff tendinopathy. *Br J Sports Med* 2009;43:236-41.

- (27) Benjamin M, Evans EJ, Copp L. The history of tendon attachments to bone in man. *J Anat* 1986;149:89-100.
- (28) Veeger HE, Van der Helm FC. Shoulder function: The perfect compromise between mobility and stability. *J Biomech* 2007;40:2119-29.
- (29) Lee SB, Kim KJ, O'Driscoll SW, Morrey BF, An KN. Dynamic glenohumeral stability provided by the rotator cuff muscles in the mid-range and end-range of motion. *J Bone Joint Surg Am* 2000;82:849-57.
- (30) Keating JF, Waterworth P, Shawn-Dunn, Crossan J. The relative strengths of the rotator cuff muscles. *J Bone Joint Surg Br* 1993;75:137-140.
- (31) Kuhlman JR, Iannotti JP, Kelly MJ, Riegler FX, Gevaert ML, Ergin TM. Isokinetic and isometric measurement of strength of external rotation and abduction of the shoulder. *J Bone Joint Surg Am* 1992;74:1320-33.
- (32) Otis JC, Peterson MG, Warren RF, Santner TJ. Changes in the moment arms of the rotator cuff and deltoid muscles with abduction and rotation. *J Bone Joint Surg Am* 1994;76:667-776.
- (33) Kuechle DK, Newman SR, Itoi Eiji, Morrey BF, An KN. Shoulder muscle moment arms during horizontal flexion and elevation. *J Shoulder Elbow Surg* 1997;6:429-39.
- (34) Liu J, Hughes RE, Schmutz WP, Niebur G, Nan-An K. Roles of deltoid and rotator cuff muscles in shoulder elevation. *Clin Biomech* 1997;12:32-38.
- (35) Kronberg M, Németh G, Broström LA. Muscle activity and coordination in the normal shoulder. An electromyographic study. *Clin Orthop Rel Res* 1990;257:76-85.
- (36) Townsend H, Jobe FW, Pink M, Perry J. Electromyographic analysis of the glenohumeral muscles during a baseball rehabilitation program. *Am J Sports Med* 1991;19:264-72.
- (37) Hughes RE, An KN. Force analysis of rotator cuff muscles. *Clin Orth Rel Res* 1996;330:75-83.
- (38) Halder A, Zobitz ME, Schultz F, An KN. Mechanical properties of the posterior rotator cuff. *Clin Biomech*, 2000;15:456-62.
- (39) Lippitt SB, Vanderhooft JE, Harris SL, Sidles JA, Harryman DT, Matsen FA. Glenohumeral stability from concavity-compression: A quantitative analysis. *J Shoulder Elbow Surg* 1993;2:27-35.

- (40) David G, Magarey ME, Jones MA, Dvir Z, Türker KS, Sharpe M. EMG and strength correlates of selected shoulder muscles during rotations of the glenohumeral joint. *Clin Biomech* 2000;15:95-102.
- (41) Inman VT, Saunders JB, Abbott LC. Observations on the function of the shoulder joint. *J Bone Joint Surg Am* 1944;26:1-30.
- (42) Cain PR, Mutschler TA, Fu FH, Lee SK. Anterior stability of the glenohumeral joint. A dynamic model. *Am J Sports Med* 1987;15:144-8.
- (43) Labriola JE, Lee TQ, Debski RE, McMahon PJ. Stability and instability of the glenohumeral joint: The role of shoulder muscles. *J Shoulder Elbow Surg* 2005;14:32S-8S.
- (44) Symeonides PP. The significance of the subscapularis muscle in the pathogenesis of recurrent anterior dislocation of the shoulder. *J Bone Joint Surg Br* 1972;54:476-83.
- (45) Kumar VP, Balasubramaniam. The role of atmospheric pressure in stabilising the shoulder. *J Bone Joint Surg Br* 1985;67:719-21.
- (46) Ovesen J, Nielsen S. Anterior and posterior shoulder instability. *Acta Orthop Scand* 1986;57:324-7.
- (47) Yamamoto A, Takagishi K, Osawa T, Yanagawa T, Nakajima D, Shitara H, et al. Prevalence and risk factors of a rotator cuff tear in the general population. *J Shoulder Elbow Surg* 2010;19:116-20.
- (48) Reilly P, Dead man and radiologists don't lie. *Ann R Coll Surg Engl* 2006;88:116-21.
- (49) Sher JS, Uribe JW, Posada A, Murphy BJ, Zlatkin MB. Abnormal findings on magnetic resonance images of asymptomatic shoulders. *J Bone Joint Surg Am* 1995;77:10-5.
- (50) Tempelhof S, Rupp S, Seil R. Age-related prevalence of rotator cuff tears in asymptomatic shoulders. *J Shoulder Elbow Surg* 1999;8:296-9.
- (51) Schibany N, Zehetgruber H, Kainberger F, Wurnig C, Ba-Ssalamah A, Herneth AM et al. Rotator cuff tears in asymptomatic individuals: a clinical and ultrasonographic screening study. *Eur J Radiol* 2004;51:263-8.
- (52) Kim HM, Teefey SA, Zelig A, Galatz LM, Keener JD, Yamaguchi K. Shoulder strength in asymptomatic individuals with intact compared with torn rotator cuffs. *J Bone Joint Surg Am* 2009;91:289-96.

- (53) Neer CS II. Anterior acromioplasty for the chronic impingement syndrome in the shoulder. A preliminary report. *J Bone Joint Surg* 1972;54:41-50.
- (54) Bigliani LU, Ticker JB, Flatow EL, Soslowky LJ, Mow VC. The relationship of acromial architecture to rotator cuff disease. *Clin Sports Med* 1991;10:823-8.
- (55) Kibler WB. The role of the scapula in athletic shoulder function. *Am J Sports Med* 1998;26:325-37.
- (56) Bateman JE. The diagnosis and treatment of ruptures of the rotator cuff. *Surg Clin N Am* 1963;43:1523-30.
- (57) Patte D. Classification of rotator cuff lesions. *Clin Orthop Rel Res* 1990;254:81-6.
- (58) Thomazeau H, Boukobza E, Morcet N, Chaperon J, Langlais F. Prediction of rotator cuff repair results by magnetic resonance imaging. *Clin Orthop* 1997;344:275-83.
- (59) Zanetti M, Gerber C, Hodler J. Quantitative assessment of the muscles of the rotator cuff with magnetic resonance imaging. *Invest Radiol* 1998;33:163-70.
- (60) Goutallier D, Postel JM, Bernageau J, Lavau L, Voisin MC. Fatty muscle degeneration in cuff ruptures. Pre- and postoperative evaluation by CT scan. *Clin Orthop* 1994;304:78-83.
- (61) Fuchs B, Weishaupt D, Zanetti M, Hodler J, Gerber C. Fatty degeneration of the muscles of the rotator cuff: Assessment by computed tomography versus magnetic resonance imaging. *J Shoulder Elbow Surg* 1999;8:599-605.
- (62) Kessel L, Watson M. The painful arc syndrome. *J Bone Joint Surg Br* 1957;59:166-72.
- (63) Hawkins RJ, Kennedy JC. Impingement syndrome in athletes. *Am J Sports Med* 1980;3:151-8.
- (64) Neer CS II. Impingement lesions. *Clin Orthop Rel Res* 1983;173:70-7.
- (65) Hertel R, Ballmer FT, Lambert SM, Gerber C. Lag signs in the diagnosis of rotator cuff rupture. *J Shoulder Elbow Surg* 1996;5:307-13.
- (66) Deutsch A, Altchek DW, Veltri DM, Potter HG, Warren RF. Traumatic tears of the subscapularis tendon, *Am J Sports Med* 1997;25:13-22.
- (67) Murell GA, Walton JR. Diagnosis of rotator cuff tears. *Lancet* 2001;357:769-70.
- (68) Litaker D, Piro M, El Bilbeisi H, Brems J. Returning to the bedside: using the history and physical examination to identify rotator cuff tears. *J Am Geriatr Soc* 2000;48:1633-7.

- (69) Farin PU, Kaukanen E, Jaroma H, Vaatainen U, Miettinen H, Soimakallio S. Site and size of rotator cuff tear. Findings at ultrasound, double-contrast arthrography, and computed tomography arthrography with surgical correlation. *Invest Radiol* 1996;31:387-94.
- (70) Sonnabend DH, Hughes JS, Giuffre BM, Farrell R. The clinical role of shoulder ultrasound. *Aust NZ J Surg* 1997;67:630-3.
- (71) Read JW, Perko M. Shoulder ultrasound: diagnostic accuracy for impingement syndrome, rotator cuff tear, and biceps tendon pathology. *J Shoulder Elbow Surg* 1998;7:264-71.
- (72) Teefey SA, Hasan SA, Middleton WD, Patel M, Wright RW, Yamaguchi K. Ultrasonography of the rotator cuff. *J Bone Joint Surg Am* 2000;82:498-504.
- (73) Roberts CS, Walker JA, Seligson D. Diagnostic capabilities of shoulder ultrasonography in the detection of complete and partial rotator cuff tears. *Am J Orthop* 2001;30:159-62.
- (74) Ferrari FS, Governi S, Burresi F, Vigni F, Stefani P. Supraspinatus tendon tears: comparison of US and MR arthrography with surgical correlation. *Eur Radiol* 2002;12:1211-7.
- (75) Ziegler DW. The use of in-office, orthopaedist-performed ultrasound of the shoulder to evaluate and manage rotator cuff disorders. *J Shoulder Elbow Surg* 2004;13:291-7.
- (76) Middleton WD, Teefey SA, Yamaguchi K. Sonography of the shoulder. *Semin Musculoskelet Radiol* 1998;2:211-21.
- (77) Bouffard JA, Lee S-M, Dhanju J. Ultrasonography of the Shoulder. *Semin Ultrasound* 2000;21:164-91.
- (78) Kluger R, Mayrhofer R, Kröner A, Pabinger C, Partan G, Hruba W et al. Sonographic versus magnetic resonance arthrographic evaluation of full-thickness rotator cuff tears in millimeters. *J Shoulder Elbow Surg* 2003;12:110-6.
- (79) van Holsbeeck MT, Kolowich PA, Eyster WR, Craig JG, Shirazi KK, Habra GK et al. US depiction of partial-thickness tear of the rotator cuff. *Radiology* 1995;197:443-6.
- (80) Kenn W, Hufnagel P, Müller T, Gohlke F, Böhm D, Kellner M et al. Arthrography, ultrasound and MR imaging in the evaluation of the rotator cuff: a prospective study [in German]. *Fortschr Röntgenstr* 2000;172:260-6.

- (81) Martin-Hervàs C, Romero J, Navas-Acién A, Reboiras JJ, Munuera L. Ultrasonographic and magnetic resonance images of rotator cuff lesions compared with arthroscopy or open surgery findings. *J Shoulder Elbow Surg* 2001;10:410-5.
- (82) Wu HP, Dubinsky TJ, Richardson ML. Association of shoulder sonographic findings with subsequent surgical treatment for rotator cuff injury. *J Ultrasound Med* 2003;22:155-61.
- (83) Iannotti JP, Zlatkin MB, Esterhai JL, Kressel HY, Dalinka MK, Spindler KP. Magnetic resonance imaging of the shoulder. Sensitivity, specificity, and predictive value. *J Bone Joint Surg Am* 1991;73:17-29.
- (84) Teefey SA, Rubin DA, Middleton WD, Hildebolt CF, Leibold RA, Yamaguchi K. Detection and quantification of rotator cuff tears. Comparison of ultrasonographic, magnetic resonance imaging, and arthroscopic findings in seventy-one consecutive cases. *J Bone Joint Surg Am* 2004;86:708-11.
- (85) Bryant L, Shnier R, Bryant C, Murrell GA. A comparison of clinical estimation, ultrasonography, magnetic resonance imaging and arthroscopy in determining the size of rotator cuff tears. *J Shoulder Elbow Surg* 2002;11:219-24.
- (86) Gerber C, Fuchs B, Hodler J. The results of repair of massive tears of the rotator cuff. *J Bone Joint Surg Am* 2000;82:505-15.
- (87) Goutallier D, Postel JM, Gleyze P, Leguilloux P, Van Driessche S. Influence of cuff muscle fatty degeneration on anatomic and functional outcome after simple suture of full-thickness tears. *J Shoulder Elbow Surg* 2003;12:550-4.
- (88) Ejnisman B, Andreoli CV, Soares BGO, Fallopa F, Peccin MS. Interventions for tears of the rotator cuff in adults. *The Cochrane Database of Systematic Reviews* 2004;1:pCD002758.
- (89) Grant HJ, Arthur A, Pichora DR. Evaluation of interventions for rotator cuff pathology: a systematic review. *J Hand Ther* 2004;17:274-99.
- (90) Coghlan JA, Buchbinder R, Green S, Johnston RV, Bell SN. Surgery for rotator cuff disease. *Cochrane database of systematic reviews* 2008;23(1):CD005619
- (91) Heers G, Anders S, Werther M, Lerch K, Hedtmann A. Effektivität der Physiotherapie in Eigenregie bei Rotatorenmanschettendefekten. *Sportverl Sportschad* 2005;19:22-7.

- (92) Koubâa S, Ben Salah FZ, Lebib S, Miri I, Ghorbel S. Conservative management of full-thickness rotator cuff tears. A prospective study of 24 patients. *Ann Readapt Med Phys* 2006;49:62-7.
- (93) Baydar M, Akalin E, Ozlem E, Gulbahar S, Bircan C. The efficacy of conservative treatment in patients with full-thickness rotator cuff tears. *Rheumatol Int* 2009;29:623-8.
- (94) Itoi E, Tabata S. Conservative treatment of rotator cuff tears. *Clin Orthop Rel Res* 1992;275:165-73.
- (95) Bartolozzi A, Andreychik D, Ahmad S. Determinants of outcome in the treatment of rotator cuff disease. *Clin Orth Rel Res* 1994;308:90-97.
- (96) Wirth MA, Basamania C, Rockwood CA. Nonoperative management of full-thickness tears of the rotator cuff. *Orthop Clin N Am* 1997;28:59-67.
- (97) Goldberg BA, Nowinski RJ, Matsen FA. Outcome of nonoperative management of full-thickness rotator cuff tears. *Clin Orthop Rel Res* 2001;382:99-107.
- (98) Bokor DJ, Hawkins RJ, Huckell GH, Angelo RL, Schickendantz MS. Results of nonoperative management of full-thickness tears of the rotator cuff. *Clin Orthop Rel Res* 1993;294:103-10.
- (99) Ghroubi S, Chaari M, Elleuch H, Guermazi M, Baklouti S. Functional and quality of life outcome of none operated rotator cuff tears. *Ann Readapt Med Phys* 2008;51:714-21.
- (100) Hawkins RH, Dunlop R. Nonoperative treatment of rotator cuff tears. *Clin Orthop Rel Res* 1995;321:178-88.
- (101) Liem D, Lichtenberg S, Magosch P, Habermeyer P. Magnetic resonance imaging of arthroscopic supraspinatus tendon repair. *J Bone Joint Surg Am* 2007;89:1770-6.
- (102) Ellman H, Hanker G, Bayer M. Repair of the rotator cuff. End-result study of factors influencing reconstruction. *J Bone Joint Surg Am* 1986;68:1136-44.
- (103) Saupé N, Pfirrmann CW, Schmid MR, Jost B, Werner CM, Zanetti M. Association between rotator cuff abnormalities and reduced acromiohumeral distance. *Am J Roentgenol* 2006;198:376-82.
- (104) Mallon WJ, Misamore GW, Snead DS, Denton P. The impact of preoperative smoking habits on the results of rotator cuff repair. *J Shoulder Elbow Surg* 2004;13:129-32.

- (105) Watson M. Major ruptures of the rotator cuff: The results of surgical repair in 89 patients. *J Bone Joint Surg Br* 1985;67:618-24.
- (106) Chen AL, Shapiro JA, Ahn AK, Zuckerman JD, Cuomo F. Rotator cuff repair in patients with type I diabetes mellitus. *J Shoulder Elbow Surg* 2003;12:416-21.
- (107) Thomazeau H, Rolland Y, Lucas C, Duval JM, Langlais F. Atrophy of the supraspinatus belly. Assessment by MRI in 55 patients with rotator cuff pathology. *Acta Orthop Scand* 1996;67:264-8.
- (108) Gartsman GM, O'Connor DP. Arthroscopic rotator cuff repair with and without arthroscopic subacromial decompression: A prospective, randomized study of one-year outcomes. *J Shoulder Elbow Surg*, 2004;13:424-6.
- (109) Milano G, Grasso A, Salvatore M, Zarelli D, Deriu L, Fabbriani C. Arthroscopic rotator cuff repair with and without subacromial decompression: A prospective randomized study. *Arthroscopy*, 2007;23:81-8.
- (110) Rokito AS, Cuomo F, Gallagher MA, Zuckerman JD. Long term functional outcome of repair of large and massive chronic tears of the rotator cuff. *J Bone Joint Surg Am* 1999;81:991-7.
- (111) Cofield RH, Parvizi J, Hoffmeyer PJ, Lanzer WL, Ilstrup DM, Rowland CM. Surgical repair of chronic rotator cuff tears. A prospective long-term study. *J Bone Joint Surg Am* 2001;83:71-7.
- (112) Galatz LM, Griggs S, Cameron BD, Iannotti JP. Prospective longitudinal analysis of postoperative shoulder function: a ten-year follow-up study of full-thickness rotator cuff tears. *J Bone Joint Surg Am* 2001;83:1052-6.
- (113) Cofield RH. Rotator cuff disease of the shoulder. *J Bone Joint Surg Am* 1985;67:974-9.
- (114) Hersch JC, Sgaglione NA. Arthroscopically assisted mini-open rotator cuff repairs. Functional outcome at 2- to 7-year follow-up. *Am J Sports Med* 2000;28:301-11.
- (115) Baysal D, Balyk R, Otto D, Luciak-Corea C, Beaupre L. Functional outcome and health-related quality of life after surgical repair of full-thickness rotator cuff tear using a mini-open technique. *Am J Sports Med* 2005;33:1346-55.
- (116) Hanusch BC, Goodchild L, Finn P, Rangan A. Large and massive tears of the rotator cuff: functional outcome and integrity of the repair after a mini-open procedure. *J Bone Joint Surg Br* 2009;91:201-5.

- (117) Boileau P, Brassart N, Watkinson DJ, Carles M, Hatzidakis AM. Arthroscopic repair of full-thickness tears of the supraspinatus: does the tendon really heal? *J Bone Joint Surg Am* 2005;87:1229-40.
- (118) Huijsmans PE, Pritchard MP, Berghs BM, van Rooyen KS, Wallace AL. Arthroscopic rotator cuff repair with double-row fixation. *J Bone Joint Surg Am* 2007;89:1248-57.
- (119) Levy O, Venkateswaran B, Even T, Ravenscroft M, Copeland S. Mid-term clinical and sonographic outcome of arthroscopic repair of the rotator cuff. *J Bone Joint Surg Br* 2008;90:1341-7.
- (120) Nho SJ, Shindle MK, Sherman SL, Freedman KB, Lyman S, MacGillivray JD. Systematic review of arthroscopic repair and mini-open rotator cuff repair. *J Bone Joint Surg Am* 2007;89(S3):127-36.
- (121) Morse K, Davis AD, Afra R, Kaye EK, Schepsis A, Vloshin I. Arthroscopic versus mini-open rotator cuff repair. *Am J Sports Med* 2008;36:1824-8.
- (122) Harryman DT, Mack LA, Wang KY, Jackins SE, Richardson ML, Matsen FA. Repairs of the rotator cuff. Correlation of functional results with integrity of the cuff. *J Bone Joint Surg Am* 1991;73:982-9.
- (123) Wiener SN, Seitz WH. Sonography of the shoulder in patients with tears of the rotator cuff: Accuracy and value for selecting surgical options. *Am J Roentgenol* 1993;160:103-7.
- (124) Zehetgruber H, Lang T, Wurnig C. Distinction between supraspinatus, infraspinatus and subscapularis tendon tears with ultrasound in 332 surgically confirmed cases. *Ultrasound Med Biol* 2002;28:711-7.
- (125) Radke S, Kenn W, Gohlke F. MRT der Schulter. *Orthopäde* 2001;30:484-91.
- (126) Zanetti M, Weishaupt D, Gerber C, Hodler J. Tendinopathy and rupture of the tendon of the long head of the biceps brachii muscle: Evaluation with MR Arthrography. *Am J Roentgenol* 1998;170:1557-61.
- (127) Mottram SL. Dynamic stability of the scapula. *Man Ther* 1997;2:123-31.
- (128) Hess SA. Functional stability of the glenohumeral joint. *Man Ther* 2000;5:63-71.
- (129) Magarey ME, Jones MA. Dynamic evaluation and early management of altered motor control around the shoulder complex. *Man Ther* 2003;8:195-206.

- (130) Constant CR, Murley AHG. A clinical method of functional assessment of the shoulder. *Clin Orthop Relat Res* 1987;214:160-4.
- (131) Conboy VB, Morris RW, Kiss J, Carr AJ. An evaluation of the Constant-Murley shoulder assessment. *J Bone Joint Surg Br* 1996;78:229-32.
- (132) Richards RR, An KN, Bigliani LU, Friedman RJ, Gartsman GM. A standardized method for the assessment of shoulder function. *J Shoulder Elbow Surg* 1994;3:347-52.
- (133) Michener LA, McClure PW, Sennett BJ. American shoulder and elbow surgeons standardized shoulder assessment form, patient self-report section: Reliability, validity, and responsiveness. *J Shoulder Elbow Surg* 2002;11:587-94.
- (134) McHorney CA, Ware JE, Raczek AE. The MOS 36-item short-form health survey (SF-36): II. Psychometric and clinical tests of validity in measuring physical and mental health constructs. *Medical Care* 1993;31:247-63.
- (135) Beaton DE, Richards RR. Measuring function of the shoulder. A cross-sectional comparison of five questionnaires. *J Bone Joint Surg Am* 1996;78:882-90.
- (136) Beaton DE, Richards RR. Assessing the reliability and responsiveness of 5 shoulder questionnaires. *J Shoulder Elbow Surg* 1998;7:565-72.
- (137) Gartsman GM, Brinker MR, Khan M, Karahan M. Self-assessment of general health status in patients with five common shoulder conditions. *J Shoulder Elbow Surg* 1998;7:228-37.
- (138) Duckworth DG, Smith KL, Campbell B, Matsen FA. Self-assessment questionnaires document substantial variability in the clinical expression of rotator cuff tears. *J Shoulder Elbow Surg* 1999;8:330-3.
- (139) McKee MD, Yoo DJ. The effect of surgery for rotator cuff disease on general health status. *J Bone Joint Surg Am* 2000;82:970-9.
- (140) Swen WAA, Jacobs JWG, Algra PR, Manoliu RA, Rijkmans J, Willems WJ et al. Sonography and magnetic resonance imaging equivalent for the assessment of full-thickness rotator cuff tears. *Arthritis Rheum* 1999; 42:2231-8.
- (141) Backhaus M, Burmester GR, Gerber T, Grassi W, Machold KP, Swen WA et al. Guidelines for musculoskeletal ultrasound in rheumatology. *Ann Rheum Dis* 2001;60:641-9.

- (142) Lyons AR, Tomlinson JE. Clinical diagnosis of tears of the rotator cuff. *J Bone Joint Surg Br* 1992;74:414-5.
- (143) Wolf EM, Agrawal V. Transdeltoid palpation (the rent test) in the diagnosis of rotator cuff tears. *J Shoulder Elbow Surg* 2001;10:470-3.
- (144) Milgrom C, Schaffler M, Gilbert S, van Holsbeck M. Rotator-cuff changes in asymptomatic adults. *J Bone Joint Surg Br* 1995;77:296-8.
- (145) Worland RL, Lee D, Orozco CG, SozaRex F, Keenan J. Correlation of age, acromial morphology, and rotator cuff tear pathology diagnosed by ultrasound in asymptomatic patients. *J South Orthop Assoc* 2003;12:23-6.
- (146) Hodler J, Fretz CJ, Terrier F, Gerber C. Rotator cuff tears: Correlation of sonographic and surgical findings. *Radiology* 1988;169:791-4.
- (147) Al-Shawi A, Badge R, Bunker T. The detection of full thickness rotator cuff tears using ultrasound. *J Bone Joint Surg Br* 2008;90:889-92.
- (148) Roberts CS, Galloway KP, Honaker JT, Hulse G, Seligson D. Sonography for the office screening of suspected rotator cuff tears: early experience of the orthopaedic surgeon. *Am J Orthop* 1998;7:503-6.
- (149) Iannotti JP, Ciccone J, Buss DD, Visotsky JL, Mascha E, Cotman K et al. Accuracy of office-based ultrasonography of the shoulder for the diagnosis of rotator cuff tears. *J Bone Joint Surg Am* 2005;87:1305-11.
- (150) Le Coroller T, Cohen M, Aswad R, Pauly V, Champsaur P. Sonography of the painful shoulder: role of the operator's experience. *Skeletal Radiol* 2008;37:979-86.
- (151) Bachmann GF, Melzer C, Heinrichs CM, Mohring B, Rominger MB. Diagnosis of rotator cuff lesions: comparison of US and MRI on 38 joint specimens. *Eur Radiol* 1997;7:192-7.
- (152) Ellman H. Diagnosis and treatment of incomplete rotator cuff tears. *Clin Orthop Relat Res* 1990;254:64-74.
- (153) Gazielly DF, Gleyze P, Montagnon C. Functional and anatomical results after rotator cuff repair. *Clin Orthop Relat Res* 1994;304:43-53.
- (154) Gartsman GM, Khan M, Hammerman SM. Arthroscopic repair of full-thickness tears of the rotator cuff. *J Bone Joint Surg Am* 1998;80:832-40.

- (155) Klepps S, Bishop J, Lin J, Cahlon O, Strauss A. Prospective evaluation of the effect of rotator cuff integrity on the outcome of open rotator cuff repairs. *Am J Sports Med* 2004;32:1716-22.
- (156) Fuchs B, Gilbert MK, Hodler J, Gerber C. Clinical and structural results of open repair of an isolated one-tendon tear of the rotator cuff. *J Bone Joint Surg Am* 2006;88:309-16.
- (157) Lafosse L, Brozka R, Toussaint B, Gobezie R. The outcome and structural integrity of arthroscopic rotator cuff repair with use of the double-row suture anchor technique. *J Bone Joint Surg Am* 2007;89:1533-41.
- (158) Skutek M, Zeichen J, Fremerey RW, Bosch O. Outcomeanalyse nach offener Rekonstruktion von Rotatorenmanschettenrupturen. Eine vergleichende Beurteilung neuer Bewertungsverfahren. *Unfallchirurg* 2001;104:480-7.
- (159) Hodgson SA, Mawson SJ, Stanley D. Rehabilitation after two-part fractures of the neck of the humerus. *J Bone Joint Surg Br* 2003;85:419-22.
- (160) Haahr JP, Østergaard S, Dalsgaard J, Norup K, Frost P. Exercises versus arthroscopic decompression in patients with subacromial impingement: a randomised, controlled study in 90 cases with a one year follow up. *Ann Rheum Dis* 2005;64:760-4.
- (161) Lefevre-Colau MM, Babinet A, Fayad F, Fermanian J, Anract P. Immediate mobilization compared with conventional immobilization for the impacted nonoperatively treated proximal humeral fracture. A randomised controlled trial. *J Bone Joint Surg Am* 2007;89:2582-90.
- (162) Hollis S, Campbell F. What is meant by intention-to-treat analysis. Survey of published randomised controlled trials. *BMJ* 1999;319:670-4.
- (163) Altmann DG, Schulz KF, Moher D, Egger M, Davidoff F, Elbourne D et al. The revised Consort statement for reporting randomized trials: explanation and elaboration. *An Int Med* 2001;134:663-94.
- (164) Herman A, Botser IB, Tenenbaum S, Chechik A. Intention to treat analysis and accounting for missing data in orthopaedic randomised controlled studies. *J Bone Joint Surg Am* 2009;91:2137-43.
- (165) Bhandari M, Joansson A. *Clinical research for Surgeons*. 2009, Thieme, Stuttgart, New York, 1. Edition.

- (166) Rothwell PM. Factors that can affect the external validity of randomised controlled trials. *PLoS Clin Trials* 1(1): e9. DOI:10.1371/journal.pctr.0010009.
- (167) Yamada N, Hamada K, Nakajima T, Kobayashi K, Fukuda H. Comparison of conservative and operative treatments of massive rotator cuff tears. *J Exp Clin Med* 2000;25:151-63.
- (168) Ruotolo C, Nottage WM. Surgical and nonsurgical management of rotator cuff tears. *Arthroscopy* 2002;18:527-31.
- (169) Baker CL, Liu SH. Comparison of open and arthroscopic assisted rotator cuff repairs. *Am J Sports Med* 1995;23:99-104.
- (170) Blevins FT, Warren RF, Cavo C, Altchek DW, Dines D, Palletta G et al. Arthroscopic assisted rotator cuff repair: Results using a mini-open deltoid splitting approach. *Arthroscopy* 1996;12:50-9.
- (171) Levy HJ, Uribe JW, Delaney LG. Arthroscopic assisted rotator cuff repair: Preliminary results. *Arthroscopy* 1990;6:55-60.
- (172) Paulos LE, Kody MH. Arthroscopically enhanced "miniapproach" to rotator cuff repair. *Am J Sports Med* 1994;22:19-25.
- (173) Posada A, Uribe JW, Hechtman KS, Tjin-A-Tsoi EW, Zvijac JE. Mini-deltoid splitting rotator cuff repair: Do results deteriorate with time? *Arthroscopy* 2000;16:137-41.
- (174) Tauro JC. Arthroscopic rotator cuff repair: Analysis of technique and results at 2 and 3 year follow-up. *Arthroscopy* 1998;14:45-51.
- (175) Takagishi N. Conservative treatment of the ruptures of the rotator cuff. *J Japanese Orthop Assn* 1978;52:781-87.
- (176) Yamaguchi K, Tetro AM, Blam O, Evanoff BA, Teefey SA, Middleton WD. Natural history of asymptomatic rotator cuff tears: A longitudinal analysis of asymptomatic tears detected sonographically. *J Shoulder Elbow Surg* 2001;10:199-203.
- (177) Vandembroucke JP, von Elm E, Altman DG, Gøtzsche PC, Mulrow CD, Pocock SJ et al. Strengthening the reporting of observational studies in epidemiology (STROBE): Explanation and elaboration. *Ann Intern Med* 2007;147:163-94.
- (178) Callas PW. Searching the biomedical literature: Research study designs and critical appraisal. *Clin Lab Sci* 2008;21:42-8.
- (179) Yamaguchi K, Ditsios K, Middleton WD, Hildebolt CF, Galatz LM, Teefey SA. The demographic and morphological features of rotator cuff disease. A

- comparison of asymptomatic and symptomatic shoulders. *J Bone Joint Surg Am* 2006;88:1699-704.
- (180) Burkhart SS. Arthroscopic debridement and decompression for selected rotator cuff tears. *Orthop Clin* 1993;24:111-23.
- (181) Thompson WO, Debski RE, Boardman III ND, Taskiran E, Warner JJ, Fu FH et al. A biomechanical analysis of rotator cuff deficiency in a cadaveric model. *Am J Sports Med* 1996;24:286-92.
- (182) Kedgley AE, Mackenzie GA, Ferreira LM, Johnson JA, Faber KJ. In vitro kinematics of the shoulder following rotator cuff injury. *Clin Biomech* 2007;22:1068-73.
- (183) Tingart MJ, Apreleva M, Lehtinen JT, Capell B, Palmer WE, Warner JJP. Magnetic resonance imaging in quantitative analysis of rotator cuff muscle volume. *Clin Orthop Rel Res* 2003;415:104-10.
- (184) Oh JH, Kim SH, Choi JA, Kim Y, Oh CH. Reliability of the grading system for fatty degeneration of rotator cuff muscles. *Clin Orthop Rel Res* 2009;4:epub ahead of print.
- (185) Keyes EL. Anatomical observations on senile changes in the shoulder. *J Bone Joint Surg Am* 1935;17:953-60.
- (186) Skinner HA. Anatomical considerations relative to rupture of the supraspinatus tendon. *J Bone Joint Surg Am* 1937;19:137-51.
- (187) Cotton RE, Rideout DF. Tears of the humeral rotator cuff. *J Bone Joint Surg Br* 1964;46:314-28.
- (188) Ozaki J, Fujimoto S, Nakagawa Y, Masuhara K, Tamai S. Tears of the rotator cuff of the shoulder associated with pathological changes of the acromion. A study in cadavera. *J Bone Joint Surg Am* 1988;70:1224-30.
- (189) Lehman C, Cuomo F, Kummer FJ, Zuckerman JD. The prevalence of full thickness rotator cuff tears in a large cadaveric population. *Bull Hosp Joint Dis* 1995;54:30-1.
- (190) Chandnani V, Ho C, Gerharter J, Neumann C, Kursunoglu-Brahme S, Sartoris DJ et al. MR findings in asymptomatic shoulders: a blind analysis using symptomatic shoulders as controls. *Clin Imaging* 1992;16:25-30.

- (191) Neumann CH, Holt RG, Steinbach LS, Jahnke AH, Petersen SA. MR imaging of the shoulder: Appearance of the supraspinatus tendon in asymptomatic volunteers. *Am J Roentgenol* 1992;158:1281-7.
- (192) Miniaci A, Dowdy PA, Willits KR, Vellet AD. Magnetic resonance imaging evaluation of the rotator cuff tendons in the asymptomatic shoulder. *Am J Sports Med* 1995;23:142-5.
- (193) Needell SD, Zlatkin MB, Sher JS, Murphy BJ, Uribe JW. MR imaging of the rotator cuff: Peritendinous and bone abnormalities in an asymptomatic population. *Am J Roentgenol* 1996;166:863-7.
- (194) Itoi E, Hsu HC, Carmichael SW, Morrey BF, An KN. Morphology of the torn rotator cuff. *J Anat* 1995;186:429-34.
- (195) Sakurai G, Ozaki J, Tomita Y, Kondo T, Tamai S. Incomplete tears of the subscapularis tendon associated with tears of the supraspinatus tendon: cadaveric and clinical studies. *J Shoulder Elbow Surg* 1998;7:510-5.
- (196) Jiang Y, Zhao J, van Holsbeek MT, Flynn MJ, Ouyang X, Genant HK. Trabecular microstructure and surface changes in the greater tuberosity in rotator cuff tears. *Skeletal Radiol* 2002;31:522-8.
- (197) Keener JD, Wei AS, Kim HM, Steger-May K, Yamaguchi K. Proximal humeral migration in shoulders with symptomatic and asymptomatic rotator cuff tears. *J Bone Joint Surg Am* 2009;91:1405-13.
- (198) Oh JH, Kim SH, Ji HM, Jo KH, Bin SW, Gong HS. Prognostic factors affecting anatomic outcome of rotator cuff repair and correlation with functional outcome. *Arthroscopy* 2009;25:30-9.
- (199) Dinnes J, Loveman E, McIntyre L, Waugh N. The effectiveness of diagnostic tests for the assessment of shoulder pain due to soft tissue disorders: a systematic review. *Health Technol Assess* 2003;7:piii, 1-166.

13. Papers

MRI of symptomatic and asymptomatic full-thickness rotator cuff tears

A comparison of findings in 100 subjects

Stefan Moosmayer¹, Rana Tariq², Morten G Stiris³, and Hans-Jørgen Smith^{4,5}

¹Department of Orthopaedic Surgery, Martina Hansen's Hospital, Baerum; ²Unilab Diagnostics, Oslo; ³Department of Radiology, Oslo University Hospital, Aker, Oslo; ⁴Department of Radiology, Oslo University Hospital, Rikshospitalet, Oslo; ⁵Faculty Division Rikshospitalet, University of Oslo, Norway
Correspondence: st.moos@online.no
Submitted 09-10-08. Accepted 10-01-08

Background and purpose Why some full-thickness rotator cuff tears are symptomatic and others are asymptomatic is not understood. By comparing MRI findings in symptomatic and asymptomatic tears, we wanted to identify any tear characteristics that differed between groups.

Patients and methods 50 subjects with asymptomatic and 50 subjects with symptomatic full-thickness tears were examined by MRI. Tear characteristics including tear size, tear location, the condition of the long head of the biceps, atrophy, and fatty degeneration of the muscles were compared between groups.

Results Single factor logistic regression analysis showed that there were statistically significant associations between symptoms and tear size exceeding 3 cm in the medial-lateral plane, positive tangent sign, and fatty degeneration exceeding grade 1 of the supraspinatus and infraspinatus muscles.

Interpretation We found associations between the symptomatic status of a rotator cuff tear and MRI-derived tear characteristics. The causal relationships are unclear.

2006). Based on clinical judgement, we selected MRI-derivable factors with potential importance for tear symptomatics. MRI is widely accepted as a diagnostic tool in imaging of the shoulder. It has shown high diagnostic validity for the detection of full-thickness rotator cuff tears (Ianotti et al. 1991, Teefey et al. 2004) and for the description of tear characteristics such as tear size and location (Bryant et al. 2002, Kluger et al. 2003), muscle atrophy, fatty degeneration (Thomazeau et al. 1996, Zanetti et al. 1998a, Fuchs et al. 1999), and involvement of the biceps tendon (Zanetti et al. 1998b). Our hypothesis was that morphological tear characteristics would differ between patients with symptomatic and asymptomatic tears, and that these differences would be detectable by MRI. Such information might lead to a better understanding of factors that are important in the development of symptoms in full-thickness tears of the rotator cuff.

Patients and methods

Asymptomatic full-thickness tears of the rotator cuff have been detected in sonographic (Tempelhof et al. 1999, Worland et al. 2003, Schibany et al. 2004, Moosmayer et al. 2009) and MRI screening studies (Sher et al. 1995) of individuals with no shoulder problems, and in cadaver studies (Cotton and Rideout 1964, Ozaki et al. 1988). Reported prevalences vary from 6% to 34%, and increase with age. Why these tears are asymptomatic while others cause shoulder pain and dysfunction is not understood. Differences in tear anatomy and shoulder kinematics may be suspected, but have not been detected to date. Few comparative studies have been performed, and on small patient groups only (Yamaguchi et al. 2000, Hirano et al.

Our study protocol was approved by our regional health ethics board (no. 288-05082) and informed consent was obtained from study subjects before examination. From September 2005 through January 2008, 50 shoulders with asymptomatic and 50 shoulders with symptomatic full-thickness tears of the rotator cuff were included. Criteria for inclusion into the asymptomatic group consisted of a history involving no earlier or acute shoulder pain, normal shoulder function, normal physical examination findings, a result of at least 90 points in the self-report section of the American Shoulder and Elbow Surgeons form (ASES) (Richards et al. 1994), and a full-thickness rotator cuff tear demonstrated at both sonography and MRI. The choice of a cut-off point of 90 on the ASES

scale was based on age-related baseline values from studies of individuals with no history of shoulder problems (Sallay and Reed 2003, Thomas et al. 2003). In subjects presenting with bilateral asymptomatic tears, only one shoulder was included in the study.

Thirty individuals who fulfilled our inclusion criteria regarding at least one shoulder were found during a study of the prevalence of asymptomatic rotator cuff tears (Moosmayer et al. 2009). In this study, clinical and sonographic screening supplemented with MRI was performed on asymptomatic subjects who had been treated earlier at our hospital for minor orthopedic conditions unrelated to the shoulder. The remaining 20 asymptomatic tears were found among present outpatients referred to our hospital for a history of earlier or acute unilateral shoulder pain, and where bilateral clinical, sonographic, and MR examination showed an asymptomatic rotator cuff tear in the pain-free contralateral shoulder.

Consequently, subjects in the asymptomatic tear group differed with respect to the condition of the contralateral shoulder, and comparison between the asymptomatic and the symptomatic tear groups was supplemented by comparing each of the two asymptomatic subgroups (with or without pain contralaterally) to the symptomatic tear group.

Criteria of inclusion into the symptomatic tear group consisted of a history of atraumatic shoulder pain, physical examination findings typical of a rotator cuff tear, and a full-thickness tear as detected by sonography and MRI. In patients with bilateral rotator cuff tears, only one of the shoulders was used for study analysis. Patients with other local or systemic diseases affecting shoulder function were excluded. 50 patients who were referred to our outpatient clinic and who fulfilled our criteria were included consecutively.

Both clinical examination and sonography at baseline in both groups were performed by one examiner (SM). Details of the sonographic examination have been reported (Moosmayer et al. 2007). Range of motion (ROM) measurement for abduction, flexion, and external rotation was performed with a goniometer. Strength was assessed in kg with a handheld spring balance in 90° shoulder abduction and flexion. The “break test method” was used, in which the subject resisted the examiner’s downward directed force until the examiner overcame the subject’s isometric contraction. The average of 2 consecutive measurements was used for data analysis. The ASES score was completed by all subjects.

All MR examinations were performed on a 1.5 T scanner (Siemens Medical Systems, Erlangen, Germany). A dedicated shoulder array coil was used. The arm was placed at the side of the body with the thumb pointing upwards. The following 5 sequences, all with a slice thickness of 3.5–4 mm, a 17.5- to 18.0-cm field of view (FOV), and one number of excitations (NEX) were obtained: (1) oblique sagittal T1-weighted spin echo (TR/TE = 513/13 ms, matrix 192 × 256), (2) oblique sagittal T2-weighted turbo spin echo (TSE) (TR/TE = 2930/74 ms, matrix 218 × 256), (3) oblique coronal and (4) axial proton

density-weighted TSE with fat saturation (TR/TE = 2800/40 ms, matrix 230 × 256), and (5) oblique coronal dual echo TSE (TR/TE = 2,500/13 – 81, matrix 205 × 256). A full-thickness tear was diagnosed in case of a discontinuity or a gap in the tendon or increased signal intensity (isointense compared to fluid) on T2-weighted images, extending from the articular to the bursal surface of the tendon (Ianotti et al. 1991).

MRI data were stored on a picture-archiving and communication system (PACS) workstation and the provider’s image analysis software was used for review of images. Studies from asymptomatic and symptomatic rotator cuff tears were randomly mixed and independently evaluated by 2 experienced musculoskeletal radiologists (RT and MGS). The radiologists were blinded regarding previous clinical and radiological findings. **Differing results were discussed between the radiologists in order to reach a consensus.**

Selection of MRI-derivable variables for further analysis was performed on the basis of clinical judgement and existing knowledge about their potential influence on symptoms from rotator cuff tears (Burkhart 1993, Thompson et al. 1996, Yamaguchi et al. 2001 and 2006, Kedgley et al. 2007). We hypothesized that there was a positive correlation between tear size, superior-anterior tear location, a biceps tendon tear, severe atrophy or fatty degeneration, and symptoms from a rotator cuff tear.

Maximum tear size on MRI was measured in oblique-sagittal and oblique-coronal planes. Tears were classified as being small/medium (up to 3 cm) or large/massive (exceeding 3 cm). Measurement was performed along a straight line, visualizing the distance between the margins of the tear (oblique sagittal plane) or between the margin of the tear and the lateral edge of the humeral articular surface (oblique coronal plane) (Teefey et al. 2004). Transition areas with markedly increased signal intensity compared to normal cuff tissue were included in the tear size.

The location of the tear (with tendon involved) was determined in the oblique sagittal plane as being superior-anterior (affecting the supraspinatus together with the rotator interval and/or the subscapularis) or superior-posterior (affecting the supraspinatus with or without extension into the infraspinatus).

The long head of the biceps muscle was classified as being intact or torn. A tear was diagnosed if the tendon could not be identified within the intertubercular sulcus or at any other place in the joint (Zanetti et al. 1998b).

Atrophy of the supraspinatus muscle was assessed by calculating the occupational ratio of the fossa (Thomazeau et al. 1996) and from the tangent sign (Zanetti et al. 1998a). Analyses were performed on the most lateral image of the oblique sagittal T1-weighted series, on which the scapular spine was in contact with the scapular body (Y-shaped view). Cross-sectional areas (CSAs; in cm²) of the supraspinatus muscle and of the supraspinatus fossa were determined by tracing the contour of each region, using the manufacturer’s image analysis

Table 1. Demographic data at inclusion

	Symptomatic tears	Asymptomatic tears	p-value
No. of study subjects	50	50	
Age, years ^a	64 (10)	69 (7.9)	0.004
Sex (M/F) ^b	32/18	31/19	1.0
Affected side (R/L) ^b	36/14	31/19	0.4
Tear on dominant/non-dominant side ^b	35/15	30/20	0.4
Contralateral shoulder (AS/S) ^b	32/18	28/22	0.3
Shoulder demanding activities in work, sports, leisure time (Y/N) ^b	34/16	28/22	0.3

^a Values are mean (SD).
^b Values are given as no. of patients.
AS: asymptomatic; S: symptomatic.

Table 2. Clinical findings at inclusion

	Symptomatic tears	Asymptomatic tears	p-value
No. of study subjects	50	50	
ASES score, points ^a	47 (14)	97 (3.3)	< 0.001
Pain free abduction, degrees ^a	82 (36)	176 (11)	< 0.001
Pain free flexion, degrees ^a	105 (43)	177 (5.5)	< 0.001
Pain-free external rotation, degrees ^a	56 (17)	68 (11)	< 0.001
Strength in abduction, kg ^a	4.0 (2.5)	6.6 (2.7)	< 0.001
Strength in flexion, kg ^a	4.6 (3.0)	6.6 (2.7)	0.001
Pain, VAS ^a	5.8 (1.6)	0.2 (0.4)	< 0.001

^aValues are mean (SD).

software. The occupational ratio was calculated by dividing the CSA of the supraspinatus muscle by the CSA of the fossa. Tears were classified into groups with ratios below 0.4 (grade 3, indicating severe atrophy) or ratios of 0.4 and more (grade 1 or 2, indicating no or moderate atrophy).

For analysis of the tangent sign, an additional straight line was drawn from the top of the coracoid process to the top of the spine of the scapula. The tangent sign was determined as being positive (indicating severe atrophy) if the superior border of the muscle was below the tangent line, and as being negative if the muscle belly and tangent line intersected.

Assessment of fatty degeneration of the muscles was performed on the same MRI slice as the quantitative assessments, according to the classification of Goutaillier et al. (1994). Originally, this classification was described for CT scanning, but has been shown to be reproducible on MRI (Fuchs et al. 1999). Fatty degeneration of each of the muscle bellies of the supraspinatus, infraspinatus, and subscapularis was classified as low (grade 0 = no fat, or 1 = some fatty streaks) or as severe (grades 2–4). To differentiate localized fatty degeneration of the rotator cuff from generalized, constitutional muscular degeneration, the teres major muscle was used as a reference. This muscle was chosen because it could be evaluated on our reference slice for the rotator cuff muscles and it differs from the rotator cuff by its function and innervation.

Statistics

Sample size calculation was performed for an expected low proportion of 0.15 in the asymptomatic group for tear characteristics that we assumed to be associated with symptoms. We wanted to be able to detect a 4-fold higher odds of being symptomatic (OR = 4) for subjects presenting the tear characteristics on MRI. To achieve a significance level of 0.05 and a power of 0.8, a sample size of 43 subjects in each group would be necessary.

Demographic and clinical data at inclusion were compared between groups by t-tests or Mann-Whitney U tests for

continuous parameters and chi-squared tests for categorical parameters. The age of the subject at inclusion was considered to be a confounder, and all logistic regression analyses were performed while adjusting for age. Associations between MRI-derived variables (independent factors) and tear group (dependent factor) were tested by logistic regression. Single-factor analyses were performed between the main groups, and odds ratios, 95% CI, and p-values are given. Subsequently, single-factor analyses were performed separately between the 2 asymptomatic subgroups and the symptomatic tear group.

Results

For demographic data, with the exception of mean subject age, no statistically significant baseline differences were found. Difference in mean age was 5 years (95% CI: 1.8–9.0), the higher mean age being in the asymptomatic group (Table 1). As a consequence of our selection criteria for the 2 groups, there was a statistically significant difference in clinical data between the symptomatic subjects and the asymptomatic subjects (Table 2).

Of the subjects with an asymptomatic tear in the index shoulder, 22 had a painful contralateral shoulder and constituted the first asymptomatic subgroup (subgroup 1) whereas 28 subjects had no pain contralaterally and they formed the second asymptomatic subgroup (subgroup 2).

Primary study result (Table 3)

In single-factor, age-adjusted logistic regression analysis, findings that were significantly associated with symptoms from rotator cuff tears were (1) tear size exceeding 3 cm in the medial-lateral plane (OR = 4, meaning that subjects with rotator cuff tears exceeding 3 cm in the medial-lateral plane had 4-times higher odds of having symptoms than subjects with smaller tears), (2) positive tangent sign (OR = 3), and (3) severe degree (grade 2–4) of fatty degeneration in the supra-

Table 3. Distributions of independent variables between symptomatic and asymptomatic tear groups with results from single-factor, age adjusted logistic regression analysis. An OR of > 1 indicates a positive association between the potential predictor and symptoms

Independent variable	Dependent variable		OR ^a (95% CI)	p-value
	Asymptomatic	Symptomatic		
Tear size, med.-lat.	≤ 3 cm	29	4 (1.5–10)	0.007
	> 3 cm	21		
Tear size, ant.-post.	≤ 3 cm	40	2 (0.5–4.2)	0.5
	> 3 cm	10		
Tear location	Superior-posterior	34	2 (0.7–4.2)	0.3
	Superior-anterior	16		
Biceps tendon	No tear	41	1 (0.4–3.5)	0.7
	Tear	9		
Muscle atrophy ^b	Grade 1 or 2	31	2 (0.9–5.5)	0.09
	Grade 3	19		
Muscle atrophy (tangent sign)	Negative	36	3 (1.1–9.0)	0.04
	Positive	14		
Fatty atrophy SSP ^c	Grade 0–1	31	5 (1.6–13)	0.004
	Grade 2–4	19		
Fatty atrophy ISP ^c	Grade 0–1	35	5 (1.5–14)	0.009
	Grade 2–4	15		
Fatty atrophy SSC ^c	Grade 0–1	41	2 (0.6–7.3)	0.2
	Grade 2–4	9		

^a age-adjusted odds ratios.

^b grading according to Thomazeau et al. (1996).

^c grading according to Goutallier et al. (1994).

CI: confidence interval;

SSP: supraspinatus muscle;

ISP: infraspinatus muscle;

SSC: subscapularis muscle.

spinatus (OR = 5) or infraspinatus (OR = 5) muscles.

In all subjects with fatty degeneration of grade 2–4 of the supraspinatus or infraspinatus muscles, the teres major muscle (our reference muscle) appeared normal on MRI (grade 0–1), indicating a localized degeneration of the affected rotator cuff muscles only.

Secondary study result (Table 4)

We found larger ORs for all MRI-derived factors for the comparison between asymptomatic tear subgroup 2 and the symptomatic tear group. This indicates that asymptomatic tears which are accompanied by a pain-free contralateral shoulder differ more from symptomatic tears than asymptomatic tears which are accompanied by a painful contralateral shoulder.

Table 4. Results from single-factor, age-adjusted logistic regression analysis from the comparison between asymptomatic tear subgroups 1 and 2 and the symptomatic tear group. An OR of > 1 indicates a positive association between the potential predictor and symptoms. Values are OR^c (95% confidence interval) and p-value

	Asymptomatic subgroup 1 ^a (n = 22) vs. Symptomatic tear group (n = 50)	Asymptomatic subgroup 2 ^b (n = 28) vs. Symptomatic tear group (n = 50)
Tear size, med.-lat.	3 (1.0–12)	5 (1.5–19)
≤ 3 cm vs. > 3 cm	0.05	0.008
Tear size, ant.-post.	1 (0.4–5.0)	2 (0.5–5.8)
≤ 3 cm vs. > 3 cm	0.6	0.5
Tear location, sup.-ant. vs. sup.-post.	1 (0.4–3.9)	2 (0.7–7.7)
Biceps tendon tear, tear vs. no tear	0.7	0.2
Muscle atrophy ^d	1 (0.4–3.3)	5 (1.4–17)
≤ vs. > grade 2	0.8	0.01
Muscle atrophy pos. vs. neg. tangent sign	1 (0.4–4.5)	13 (2.3–74)
Fatty atrophy SSP ^e	2 (0.6–5.9)	24 (3.9–143)
≤ vs. > grade 1	0.3	0.001
Fatty atrophy ISP ^e	4 (0.9–15)	5 (1.3–23)
≤ vs. > grade 1	0.08	0.02
Fatty atrophy SSC ^e	2 (0.4–12)	3 (0.6–12)
≤ vs. > grade 1	0.4	0.2

^a asymptomatic tear in the index shoulder, pain in the contralateral shoulder.

^b asymptomatic tear in the index shoulder, no pain in the contralateral shoulder.

^c age-adjusted odds ratio.

^d grading according to Thomazeau et al. (1996).

^e grading according to Goutallier et al. (1994).

SSP: supraspinatus muscle;

ISP: infraspinatus muscle;

SSC: subscapularis muscle.

Discussion

In contrast to earlier publications, we found associations between the symptoms of a rotator cuff tear and the characteristics of the tear. This may be explained by differences in study populations, study protocols, and examination techniques. Yamaguchi et al. (2000) used scapular plane radiographs to compare humeral kinematics during active arm elevation between normal volunteers, patients with symptomatic rotator cuff tears, and subjects with asymptomatic tears. They found increased superior translation of the humeral head on the glenoid in both tear groups compared to the no-tear group, but there were no statistically significant differences between the symptomatic tear group and the asymptomatic tear group. This may have been a consequence of having a sample size of only 10 subjects in each group.

Hirano et al. (2006) used indirect MR arthrography to compare tear size and the amount of subacromial-subdeltoid

bursal fluid in 15 asymptomatic and 23 symptomatic rotator cuff tears. The findings were similar in the two groups, but the majority of the study population had partial-thickness tears and analysis of muscle atrophy and degeneration was not part of the study protocol.

In our study, we selected tear characteristics as demonstrated on MRI for analysis. On the basis of existing knowledge, we considered these characteristics to be potential predictors of the symptomatic status of rotator cuff tears. Tear size was included according to the findings of Yamaguchi et al. (2001) who, in a longitudinal study, followed asymptomatic tears sonographically and clinically over 5 years. Symptoms developed in 23 of 45 cases and there was progression of tear size in 9 of 23 cases. Of those who became symptomatic, 7 of 14 showed tear size progression, compared to 2 of 9 in the group that remained asymptomatic. In a recent cross-sectional study, Yamaguchi et al. (2006) examined tear sizes by sonography in 82 patients with a symptomatic rotator cuff tear in one shoulder and an asymptomatic tear in the other. He found larger tear sizes in the symptomatic shoulders, with a mean difference between groups of 5.4 mm. Our finding of a positive association between tear size in the medial-lateral plane and symptoms of a rotator cuff tear is therefore in good agreement with the findings of Yamaguchi et al. (2001, 2006).

We selected atrophy and fatty degeneration of the rotator cuff muscles as potential predictors of pain from a rotator cuff tear, on the basis of the idea of an anatomically deficient but functionally sound rotator cuff, as described by Burkhart (1993). According to a suspension bridge model, tears located within the area defined by the rotator cable (crescent area) might be less at risk of development of serious muscle dystrophy as force transfer from the muscles to the greater tuberosity will be possible through the cable. Consequently, tears of the supraspinatus and parts of the infraspinatus that are bypassed by an intact cable will have a lower risk of development of muscle atrophy and fatty degeneration. These muscles will still contribute as humeral depressors, and thus prevent impingement and pain. Our findings of lower frequencies of serious supra- and infraspinatus muscle atrophy and fatty degeneration in the asymptomatic tear group support this hypothesis.

The pathological long head of the biceps muscle has been proposed as a source of pain in patients with a rotator cuff tear (Szabó et al. 2008). We classified the biceps tendon only into torn or not torn, and based on this classification we found no differences between the groups. Pain from the biceps tendon is usually related to conditions such as tendonitis, delamination, subluxation, or dislocation, but these conditions were not registered in our study.

Both in the symptomatic tear group and the asymptomatic tear group, only one shoulder per subject was included. In subjects where both shoulders fulfilled our criteria for inclusion, the shoulder that (by chance) was examined first was included in the study. This was done to perform statistical analyses on the basis of independent observations.

We identified subject age as a confounder and all regression analyses were performed while controlling for age. This had to be done because subject age was associated with independent factors (older subjects had larger tear sizes, higher degrees of atrophy, and fatty degeneration) and with the dependent factor, and, at the same time, differed at baseline between groups (with higher mean age in the asymptomatic group). Not controlling for age would have led to confounding bias, and would have masked the positive associations found in this study.

Even though all tears included in the asymptomatic group represented true asymptomatic tears according to our inclusion criteria, and should thus reflect typical characteristics of the condition, they differed with respect to the status of the contralateral shoulder. One might argue that by comparing their two shoulders, subjects with pain contralaterally might tend to overlook minor symptoms in their index shoulder, as they experience this shoulder as being much better than the reference shoulder. This argument may be supported by our findings from subgroup analyses. Greater differences, as expressed by ORs, were found for MRI-derived tear characteristics between the symptomatic tear group and the subgroup with an asymptomatic tear in the index shoulder together with a pain-free contralateral shoulder. This is important, as existing evidence in the field is partly based on results from studies exclusively involving subjects with pain in the contralateral shoulder (Yamaguchi et al. 2001, 2006).

Despite the associations we found between MRI-derived tear characteristics and tear symptoms, the clinical value of these findings is limited. The cross-sectional design of our study does not permit establishment of any causal relationships between independent and dependent variables. On the other hand, our findings fit well with existing knowledge about the negative effect of increasing tear size and decreasing muscle quality on physiological shoulder kinematics (Thompson et al. 1996, Kedgley et al. 2007). Our results should mainly be used as a basis for future research. The question of whether the positive associations found in our study reflect a causal relationship should be investigated in longitudinal studies.

SM designed the study, carried out clinical and sonographic patient examination, analyzed the data, interpreted the results, and wrote the article. RT and MGS worked together on study design, analyzed and interpreted the MRI data from all study patients, and performed a critical revision of the manuscript. HJS supervised the study, collaborated on study design and on the analysis and interpretation of data, and was a co-writer of the manuscript.

We thank biostatistician Ingar Holme of the Preventive Medicine Clinic, Oslo University Hospital, Ullevål, for help with the statistical analysis. This study was supported by a grant from the Southeastern Norwegian Regional Health Authorities.

No competing interests declared.

- Bryant L, Shnier R, Bryant C, Murrell G A. A comparison of clinical estimation, ultrasonography, magnetic resonance imaging and arthroscopy in determining the size of rotator cuff tears. *J Shoulder Elbow Surg* 2002; 11: 219-24.
- Burkhart S S. Arthroscopic debridement and decompression for selected rotator cuff tears. *Orthop Clin* 1993; 24: 111-23.
- Cotton R E, Rideout D F. Tears of the humeral rotator cuff. *J Bone Joint Surg (Br)* 1964; 46: 314-28.
- Fuchs B, Weishaupt D, Zanetti M, Hodler J, Gerber C. Fatty degeneration of the muscles of the rotator cuff: Assessment by computed tomography versus magnetic resonance imaging. *J Shoulder Elbow Surg* 1999; 8: 599-605.
- Goutallier D, Postel J M, Bernageau J, Lavau L, Voisin M C. Fatty muscle degeneration in cuffruptures. Pre- and postoperative evaluation by CT scan. *Clin Orthop* 1994; (304): 78-83.
- Hirano Y, Sashi R, Izumi J, Itoi E, Watarai J. Comparison of the findings on indirect MR arthrography in patients with rotator cuff tears with and without symptoms. *Radiat Med* 2006; 24: 23-7.
- Ianotti J P, Zlatkin M B, Esterhai J L, Kressel H Y, Dalinka M K, Spindler K P. Magnetic resonance imaging of the shoulder. Sensitivity, specificity, and predictive value. *J Bone Joint Surg (Am)* 1991; 73: 17-29.
- Kedgley A E, Mackenzie G A, Ferreira L M, Johnson J A, Faber K J. In vitro kinematics of the shoulder following rotator cuff injury. *Clin Biomech* 2007; 22: 1068-73.
- Kluger R, Mayrhofer R, Kröner A, Pabinger C, Pärtan G, Hruby W, Engel A. Sonographic versus magnetic resonance arthrographic evaluation of full-thickness rotator cuff tears in millimeters. *J Shoulder Elbow Surg* 2003; 12: 110-6.
- Moosmayer S, Heir S, Smith H J. Sonography of the rotator cuff in painful shoulders performed without knowledge of clinical information: Results from 58 sonographic examinations with surgical correlation. *J Clin Ultrasound* 2007; 35: 20-6.
- Moosmayer S, Smith H J, Tariq R, Larmo A. Prevalence and characteristics of asymptomatic tears of the rotator cuff. An ultrasonographic and clinical study. *J Bone Joint Surg (Br)* 2009; 91: 196-200.
- Ozaki J, Fujimoto S, Nakagawa Y, Masuhara K, Tamai S. Tears of the rotator cuff of the shoulder associated with pathological changes of the acromion. A study in cadavera. *J Bone Joint Surg (Am)* 1988; 70: 1224-30.
- Richards R R, Kai-Nan A, Bigliani L U, Friedman R J, Gartsman G M, Gristina A G, Iannotti J P, Mow V C, Sidles J A, Zuckerman J D. A standardized method for the assessment of shoulder function. *J Shoulder Elbow Surg* 1994; 3: 347-52.
- Sallay P I, Reed L. The measurement of normative American shoulder and elbow surgeons scores. *J Shoulder Elbow Surg* 2003; 12: 622-7.
- Schibany N, Zehetgruber H, Kainberger F, Wurnig C, Ba-Ssalamah A, Herenth A M, Lang T, Gruber D, Breitenscher M J. **Rotator cuff tears in asymptomatic individuals: a clinical and ultrasonographic screening study.** *Eur J Radiol* 2004; 51: 263-8.
- Sher J S, Uribe J W, Posada A, Murphy B J, Zlatkin M B. Abnormal findings on magnetic resonance images of asymptomatic shoulders. *J Bone Joint Surg (Am)* 1995; 77: 10-5.
- Szabó I, Boileau P, Walch G. The proximal biceps as a pain generator and results of tenotomy. *Sports Med Arthrosc Rev* 2008; 16: 180-6.
- Teefey S A, Rubin D A, Middleton W D, Hildebolt C F, Leibold R A, Yamaguchi K. Detection and quantification of rotator cuff tears. Comparison of ultrasonographic, magnetic resonance imaging, and arthroscopic findings in seventy-one consecutive cases. *J Bone Joint Surg (Am)* 2004; 86: 708-11.
- Tempelhof S, Rupp S, Seil R. Age-related prevalence of rotator cuff tears in asymptomatic shoulders. *J Shoulder Elbow Surg* 1999; 8: 296-9.
- Thomas M, Dieball O, Busse M. Normalwerte der Schulterkraft in Abhängigkeit von Alter und Geschlecht – Vergleich zum Constant-, UCLA-, ASES-Score und SF-36 Fragebogen. *Z Orthop* 2003; 141: 160-70.
- Thomazeau H, Rolland Y, Lucas C, Duval J M, Langlais F. Atrophy of the supraspinatus belly. Assessment by MRI in 55 patients with rotator cuff pathology. *Acta Orthop Scand* 1996; 67: 264-8.
- Thompson W O, Debski R E, Boardman III N D, Taskiran E, Warner J J, Fu F H, Woo S L. A biomechanical analysis of rotator cuff deficiency in a cadaveric model. *Am J Sports Med* 1996; 24: 286-92.
- Worland R L, Lee D, Orozco C G, SozaRex F, Keenan J. Correlation of age, acromial morphology, and rotator cuff tear pathology diagnosed by ultrasound in asymptomatic patients. *J South Orthop Assoc* 2003; 12: 23-6.
- Yamaguchi K, Sher J S, Andersen W K, Garretson R, Uribe J W, Hechtman K, Neviasser R J. Glenohumeral motion in patients with rotator cuff tears: A comparison of asymptomatic and symptomatic shoulders. *J Shoulder Elbow Surg* 2000; 9: 6-11.
- Yamaguchi K, Tetro A M, Blam O, Evanoff B A, Teefey S A, Middleton W D. Natural history of asymptomatic rotator cuff tears: A longitudinal analysis of asymptomatic tears detected sonographically. *J Shoulder Elbow Surg* 2001; 10: 199-203.
- Yamaguchi K, Ditsios K, Middleton W D, Hildebolt C F, Galatz L M, Teefey S A. The demographic and morphological features of rotator cuff disease. A comparison of asymptomatic and symptomatic shoulders. *J Bone Joint Surg (Am)* 2006; 88: 1699-704.
- Zanetti M, Gerber C, Hodler J. Quantitative assessment of the muscles of the rotator cuff with magnetic resonance imaging. *Invest Radiol* 1998a; 33: 163-70.
- Zanetti M, Weishaupt D, Gerber C, Hodler J. Tendinopathy and rupture of the tendon of the long head of the biceps brachii muscle: Evaluation with MR arthrography. *AJR* 1998b; 170: 1557-61.

List of errata:

Page 8: Paper V: "MRI of symptomatic and asymptomatic full-thickness rotator cuff tears: comparison of findings. Acta Orthop 2010;81(3):x-x, accepted" *was corrected to:* "MRI of symptomatic and asymptomatic full-thickness rotator cuff tears: A comparison of findings. Acta Orthop 2010;81:361-6.

Page 10, line 1/2: "...varying from 16 mm to 20 mm. (3-5)." *The full stop after 20 mm was omitted.*

Page 11, line 11: "...innervated by the axillary nerve (C4 - C6)" *A full stop was added after (C4 - C6).*

Page 52, line 5: "...outcome analyses are necessary". *was corrected to* "...outcome analyses are necessary".

Page 52, line 14: "...and activity requirements of ptiens diagnosed with a tear of the rotator cuff..." *was corrected to* "...and activity requirements of patients diagnosed with a tear of the rotator cuff..."

Page 73, reference number 162: "...BMJ199;319:670-4" *A full stop was added after 670-4.*

Page 73, reference number 164: "Amir H. et al. Intention to treat analysis..." *was corrected to* "Herman A, Botser IB, Tenenbaum S, Chechik A. Intention to treat analysis..."

