

**Complications and clinical outcomes after surgery for
symptomatic subaxial cervical degenerative disease**

Bjarne Lied M.D.

Dissertation for the degree of philosophiae doctor (Ph.D.)

University of Oslo, Norway

2012



© **Bjarne Lied, 2012**

*Series of dissertations submitted to the
Faculty of Medicine, University of Oslo
No. 1432*

ISBN 978-82-8264-202-6

All rights reserved. No part of this publication may be reproduced or transmitted, in any form or by any means, without permission.

Cover: Inger Sandved Anfinsen.
Printed in Norway: AIT Oslo AS.

Produced in co-operation with Akademika publishing.
The thesis is produced by Akademika publishing merely in connection with the thesis defence. Kindly direct all inquiries regarding the thesis to the copyright holder or the unit which grants the doctorate.

Andrea, Ingrid, Victoria, Maria og Inger-Mari

Contents

1. Acknowledgements	3
2. Selected Abbreviations	4
3. List of papers (publications).....	5
4. Background	5
4.1 Anatomy and physiology of the cervical spine	6
4.2 Pathophysiology of cervical degenerative disease (CDD)	8
4.3 Asymptomatic CDD	15
4.4 Symptomatic CDD	17
4.4.1 Cervical radiculopathy	17
4.4.2 Cervical spondylotic myelopathy	19
4.5 Treatment of CDD	20
4.5.1 Conservative Treatment	20
4.5.1.1 Cervical radiculopathy	20
4.5.1.2 Cervical spondylotic myelopathy (CSM)	21
4.5.2 Surgical Treatment	21
4.5.2.1 Candidates for surgery	21
4.5.2.2 Operative techniques.....	21
4.5.2.3 Surgical mortality and morbidity.....	26
4.5.2.4 Feasibility of surgery for CDD in an outpatient setting.....	29
5. Aims of the present study (thesis)	29
6. Materials and Methods	30
7. Summary of papers I – IV	33
8. Discussion	37
8.1 Internal and external validity of the studies.....	38
8.2 Complications after ACDF and cervical laminectomy for CDD	39
8.3 Clinical outcome after ACDF for CDD	40
8.4 ACDF in an outpatient setting.....	41
9. Conclusions	42
10. Future perspectives	43
11. Reference List	44

1. Acknowledgements

Even when I embarked on my career in surgery many years ago, first in general surgery at Kongsberg Hospital, encouraged by Dr. Hans Christian Blom, and later on as I finished my orthopaedic surgery education at Buskerud's hospital in Drammen, degeneration of the spine was always my main interest.

At that time, I was familiar only with the degenerated lumbar spine. This all changed when I began my neurosurgery training at Rikshospitalet in Oslo. I was introduced to the operating microscope for the first time and I was trained and supervised by senior neurosurgeon, Dr. Jan Wiberg, who taught me how to treat degeneration of the cervical spine. Later, with the enthusiastic support of my main mentor and friend, Professor Eirik Helseth, I began a prospective preoperative and postoperative register for this large group of patients.

My dear colleagues, Drs. Jarle Sundseth, Jon Berg-Johnsen, Charlotte Marie Halvorsen, Marianne Efskind Harr, Vidar Stenset and Kåre Ekseth have helped me greatly during this work. The statistical analyses and discussion sessions of this thesis would not have been the same without the excellent support of my colleague Dr. Pål Rønning. This study would not have been possible without the help and advice that I received from Hanne Veбенstad, who was always there to help me when I struggled with the database. Last, but not least, I wish to thank the Department of Neurosurgery at Oslo University Hospital and the Oslofjord Clinic for their support and treatment of our patients. We are tremendously grateful to all the patients who participated in the studies.

I wish to thank my lovely parents, Gjertrud and Målfinn, who have always supported me; I am very appreciative for everything they have done for me and for the way that they raised me. A huge thanks to my family, especially to my wife, Inger-Mari, and to my children, Maria, Victoria, Ingrid, and Andrea, for their constant support and understanding of my many late arrivals at home.

2. Selected Abbreviations

AICG:	Autologous iliac crest graft
ACDF:	Anterior cervical discectomy and fusion
ACD:	Anterior cervical discectomy
CDD:	Cervical disc degeneration
CSM:	Cervical spondylotic myelopathy
CSF:	Cerebrospinal fluid
CT:	Computed tomography
NASSQ:	North American Spine Score Questionnaire
MR:	Magnetic resonance
MRI:	Magnetic resonance imaging
PEEK:	Polyetheretherketone
VAS:	Visual analogue scale

3. List of papers (publications)

1. Lied B, Sundseth J, Helseth E. Immediate (0-6 h), early (6-72 h) and late (>72 h) complications after anterior cervical discectomy with fusion for cervical disc degeneration: discharge six hours after operation is feasible. *Acta Neurochir (Wien)* 2008;150:111-118.
2. Lied B, Roenning PA, Sundseth J, Helseth E. Anterior cervical discectomy with fusion in patients with cervical disc degeneration: A prospective outcome study of 258 patients (181 fused with autologous bone graft and 77 fused with a PEEK cage). *BMC Surg* 2010 Mar 21;10:10.
3. Halvorsen CM, Lied B, Harr ME, Roenning PA, Sundseth J, Kolstad F, Helseth E. Surgical mortality and complications leading to reoperation in 318 consecutive posterior decompressions for cervical spondylotic myelopathy. *Acta Neurol Scand* 2011;123:358-365.
4. Lied B, Rønning PA, Halvorsen CM, Ekseth K, Helseth E. Outpatient anterior cervical discectomy and fusion (ACDF) for cervical disc disease; a prospective consecutive series of 96 patients. *Acta Neurol Scand* 2012 May 10. [Epub ahead of print].

4. Background

This thesis is based on four studies recounting the complications and clinical outcome following surgery for symptomatic degenerative disease of the subaxial part of the cervical spine.

4.1 Anatomy and physiology of the cervical spine

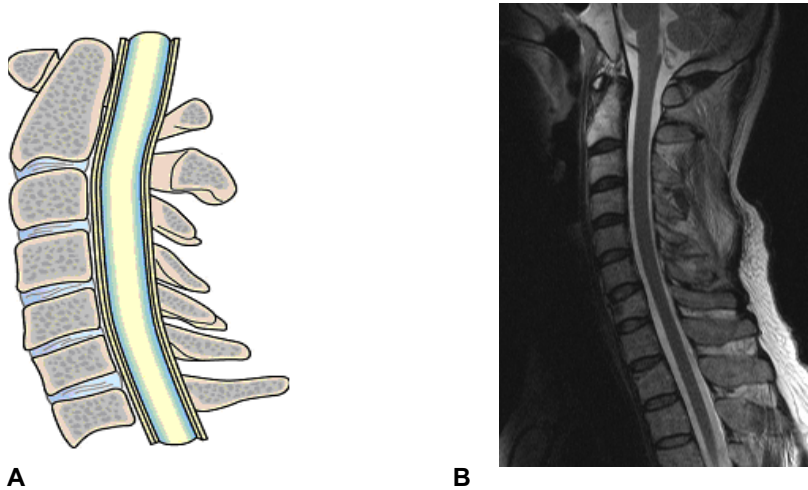


Figure 1: Drawing (A) and T2-weighted MR image (B) of the cervical spine (sagittal view).

The cervical spine comprises seven vertebrae: the atlas (C1), axis (C2), and five subaxial vertebrae (C3-C7), which contribute to the physiological cervical lordosis.

Between each subaxial vertebra are five joints that permit and restrict mobility of the subaxial spinal column; a large joint between the vertebral bodies, two small synovial joints on each side of the intervertebral disc (uncovertebral joints), and two synovial joints between the articular processes (facet joints). The intervertebral disc is positioned within the joint between the vertebral bodies. The disc comprises a vertebral endplate, nucleus pulposus, and annulus fibrosus, and is thicker anteriorly, which contributes to the normal cervical lordosis. The vertebrae are held together by ligaments and muscles, which give both strength and flexibility to the spinal column.

Knowledge of the important neighbouring structures to the spine, such as the major cervical blood vessels, larynx/trachea, oesophagus, and lower cranial nerves, is mandatory for spine surgery (Figure 2).

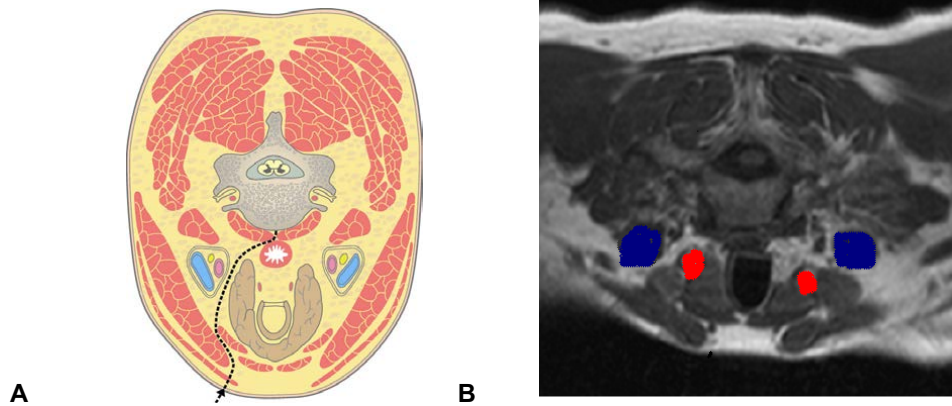


Figure 2: Drawing (A) and T1-weighted MR image (B) of the neck showing the vertebrae, spinal cord, trachea, oesophagus, muscles and major vessels. The common carotid artery is in red and the internal jugular vein in blue (axial view).

The cervical spinal canal contains the spinal cord and eight pairs of cervical nerve roots. The spinal nerves exit the spinal canal through the intervertebral foramen located between the pedicles of the vertebrae (Figure 3).

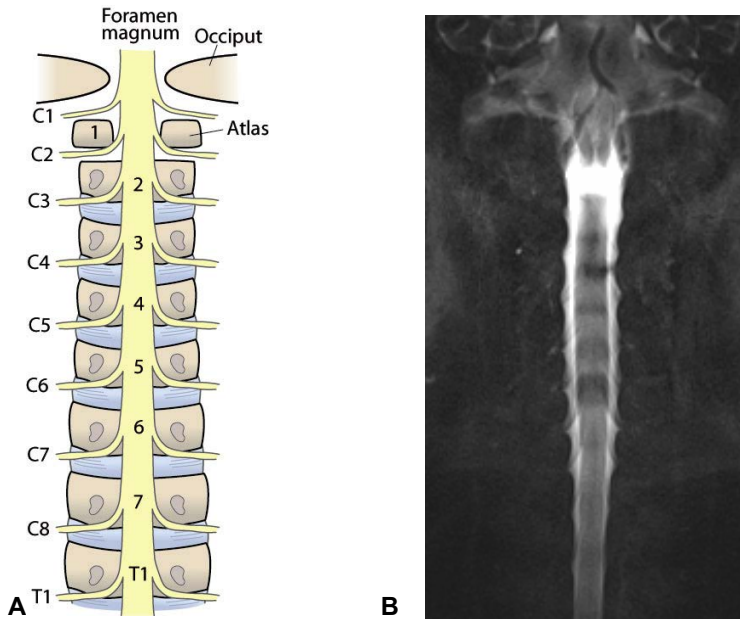


Figure 3: Drawing (A) and T2-weighted MR myelogram (B) of the spine showing the cervical spinal column, spinal cord and spinal nerves (coronal view).

4.2 Pathophysiology of cervical degenerative disease (CDD)

The exact relationship between natural ageing, degenerative processes, and actual disease is far from clear. Cervical spondylosis is a term used to describe the degenerative ageing process that encompasses a sequence of changes in the intervertebral disc, vertebral bodies, joints, and/or ligaments of the cervical spine (1).

The pathophysiological processes involved in cervical spondylosis can lead to dysfunction of the intervertebral joints, root canal stenosis, and cervical canal stenosis (Figures 4 and 5).

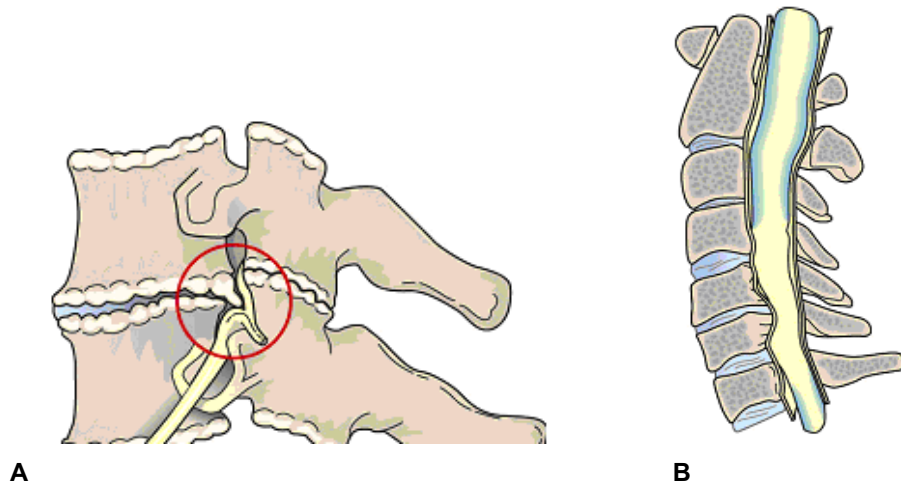


Figure 4: Drawing of cervical spondylosis with foraminal stenosis (A) and spinal canal stenosis (B) (sagittal view).

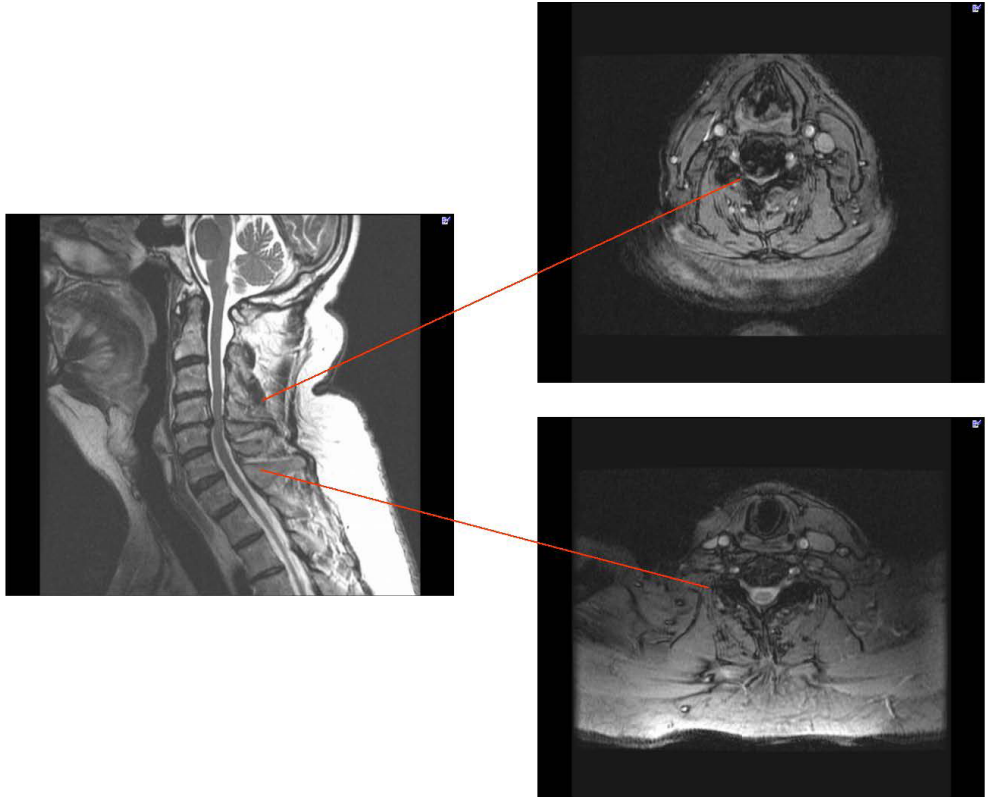
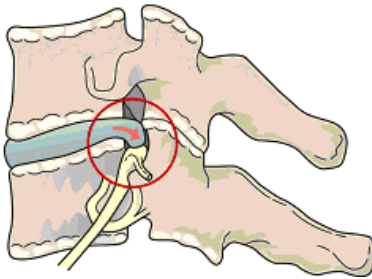


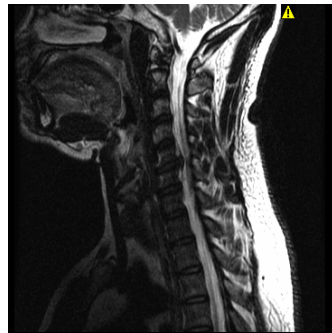
Figure 5: Cervical MR image of a 74-year old man with spondylotic foraminal stenosis and spinal canal stenosis at level C4/C5 (sagittal and axial T2-weighted MRI).

The intervertebral disc is an avascular tissue element containing cells within an extensive extracellular matrix. A variety of inflammatory mediators have been implicated in the degeneration of the intervertebral disc (2). Although the annulus fibrosus is predominantly collagenous, the matrix of the central nucleus pulposus is rich in proteoglycans. Proteoglycans have a strong attraction for water molecules and the amount of proteoglycans decreases with ageing, a process that is believed to be critical to intervertebral disc degeneration. This leads to loss of elasticity,

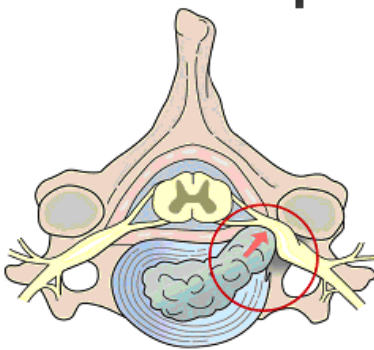
reduction of height, and increase in weight bearing for the annulus fibrosus, which can lead to bulging of the disc into the spinal canal/root canal (Figure 6). The increased load borne by the uncovertebral joints may in turn lead to accelerated osteophyte formation (3). The osteophytes may project into the intervertebral root canals and into the spinal canal (Figures 4 and 5). Additionally, disc degeneration accompanied by height reduction increases the axial load on the facet joints, which can induce degeneration of these joints (4;5). Degeneration of the facet joints includes ligament hypertrophy and osteophyte formation causing narrowing of the root canals and spinal canal.



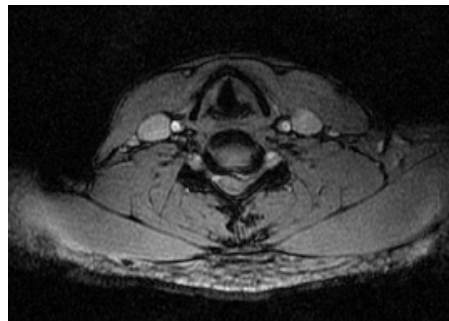
A



B



C



D

Figure 6: Foraminal stenosis secondary to a herniated cervical disc. Sagittal drawing (A), sagittal T2-weighted MR image (B), axial drawing (C), and axial T2-weighted MR (D).

Root canal stenosis may cause nerve entrapment and resultant sensory deficit(s), motor weakness, and/or radicular pain; spinal canal stenosis may cause myelopathy (1).

Each intervertebral foramen houses its exiting cervical nerves. The largest cervical spine foramen is at the C2/C3 level, and the smallest foramen is at the C6/C7 level. The size of each cervical foramen depends upon its position in the cervical spine. The intervertebral foraminae enlarge with flexion and become smaller with extension. In rotation, the ipsilateral side becomes smaller, and the contralateral side enlarges. Extreme changes of the foramina occur with coupled movements (i.e., flexion-rotation and extension-rotation-lateral flexion). This explains the pain aggravation caused by Spurling's test in patients with root canal stenosis (Figure 7). A 20%-30% reduction of the foraminal area was found with a 1 mm narrowing of the intervertebral disc spaces, a 30%-40% reduction of the foraminal area was found with a 2 mm narrowing of the intervertebral disc space, and a 35%-45% reduction of the foraminal area was found with a 3 mm narrowing of the intervertebral disc space (6).

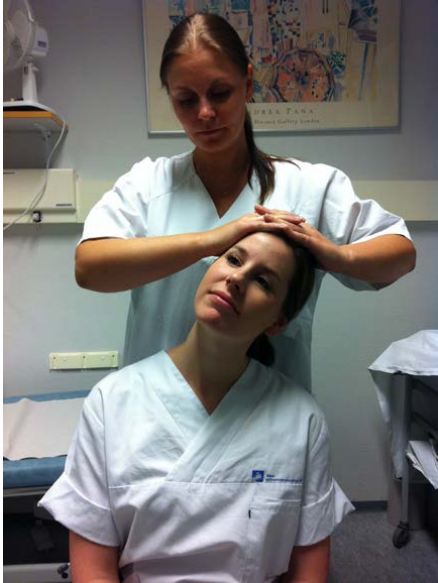

Figure 7: Spurling's test.

Mechanical pressure caused by a herniated disc or by osteophytic formation is the most obvious and probably the most important cause of radicular pain. This may change the intraradicular circulation and cause oedema. In 1989, Olmarker from Gothenburg showed that the formation of oedema in spinal nerves was more pronounced after the rapid than after the slow onset of compression (7). In 1993, Kobayashi et al. showed that the blood-nerve barrier of the nerve root can be disrupted and intraradicular oedema produced by compression of the nerve root in dogs (8). This fits well with surgical observations of inflammation appearing as oedema and hyperaemia of the root. Histological examination of cadaveric intervertebral exit foraminae in which herniated discs were present demonstrated congestion and thrombosis with basement membrane thickening and endothelial fibrosis (9).

Other studies have shown that long-lasting compression can lead to intraneural fibrosis (10;11). Pain can be caused both by an inflammatory process and by perineural fibrosis, although which is more important has yet to be determined.

The spinal canal houses the spinal cord along with cerebrospinal fluid (CSF) and dura. In a cadaver study of 469 adult skeletal specimens, Lee et al. found an average anterior-posterior canal diameter of 14.1 ± 1.6 mm, with a significantly larger diameter in males than in females (12). They also found a strong correlation between age >60 years and significantly smaller spinal canal diameter. The normal sagittal diameter should exceed 13 mm, and a congenitally narrow canal is an important risk factor for the development of cervical spinal stenosis and cervical spondylotic myelopathy (CSM) (13;14). Measurement of the sagittal diameter and calculation of the transverse area are used to grade cervical spinal canal stenosis (13-15).

Both neural and vascular processes are causally involved in the neurological symptoms in CSM (5;16;17). The local arterial supplies to the spinal cord may be compressed by the degenerative changes occurring with cervical spondylosis (5;17-20).

Histological analysis of the spinal cord in patients with CSM characteristically shows that the central grey matter and the medial portions of the myelinated long tracts are affected most severely. Wallerian degeneration of the posterior columns and posterolateral tracts occurs cephalad to the site of compression. Anterior horn cell dropout occurs at the site of compression, and the corticospinal tracts undergo degeneration, with loss of myelin staining caudal to the site of compression (21-23).

Burrows studied the sagittal diameter of the spinal canal in cervical spondylosis radiographically and noted three distinct types of degenerative encroachment in the cervical spinal canal. The first type involved obliteration of the neuroforamen by osteophytic overgrowth at the posterolateral margin of the vertebral body. The second type involved encroachment on the neural canal by an osteophytic spur or

"bar" across the back of the degenerated disc, producing an impression on the spinal cord by direct compression. The third encroachment was caused by degeneration, hypertrophy, and buckling of the ligament flavum. Burrows concluded that the initial size of the canal was a key factor underlying the subsequent development of CSM (21;24).

Ogino et al. found that the severity of pathological changes in the spinal cord correlate well with the extent of spinal cord compression, measured by the anteroposterior compression ratio. The posterolateral white matter fibres, including the lateral corticospinal tracts, were most susceptible to minor degrees of compression. By contrast, anterior horn cell loss and localized infarction of the grey matter are associated with more severe degrees of compression. Extensive infarction of the grey matter occurs with an anteroposterior compression ratio of <20% (25).

4.3 Asymptomatic CDD

Normal ageing of the spine is associated with disc degeneration, ligament hypertrophy, joint degeneration, and hypertrophy of osseous structures. Investigation of healthy, asymptomatic volunteers has shown that degenerative disease of the cervical spine occurs frequently, even in the absence of clinical symptoms (26;27). In many patients, there is a poor correlation between radiological findings and clinical symptoms. Some patients have advanced degenerative changes in the spine without symptoms, whereas others have severe symptoms and discrete radiological findings. The discrepancy between radiological findings and clinical symptoms is especially pronounced in the cervical region.

In an MR study of the cervical spine, Boden et al. found that 19% of asymptomatic volunteers had abnormal findings in the scan; 14% were younger and 28% were older than 40 years (26).

Lehto et al. used MRI to examine 89 asymptomatic volunteers and found abnormalities in 63% of those older than 40 years (27). He concluded that abnormal MRI findings and age correlate strongly.

Matsumoto et al. examined 497 asymptomatic volunteers without any previous history of cervical trauma and concluded similarly that the frequency of each degenerative MRI finding increased linearly with age (28).

Teresi et al. studied asymptomatic individuals referred for MRI examination of the larynx without symptoms attributable to the cervical spine. They found spinal cord impingement in 16% of those younger than and in 26% of those older than 64 years. Interestingly, they could not find any obliteration of the intraforaminal fat, and the percentage of cord reduction never exceeded 16% and was on average about 7% (29).

In a prospective study with a 10-year follow-up, Okada et al. looked at MRI changes in the cervical spine in healthy volunteers. They found progression of degenerative findings in 81.1% of the volunteers. A decrease in signal intensity of the disc was observed in 59.6% of the patients, increased anterior compression of the dura and spinal cord in 61.4%, progression of posterior disc protrusion in 70%, disc space narrowing in 26.9%, and progression of foraminal stenosis in 9%. Neck pain, shoulder stiffness, and upper extremity numbness were identified in 9.9%, 30%, and 4% of the subjects, respectively, and one or more clinical symptoms developed in 34% of the volunteers during the 10 year follow up period (30).

The question of when MRI abnormalities translate into symptomatic disease is difficult to answer. Interpretation of MRI scans can be challenging and there are large variations in interobserver and intraobserver interpretation. A study of observer variability in the analysis of CT and MR images between six radiologists published in the American Journal of Neuroradiology in 2003, concluded that interobserver agreement between the radiologists, about the level, degree, and cause of stenosis on CT myelograms was low (31).

Most people with degenerative changes of the cervical spine remain asymptomatic. Symptomatic patients are generally older than 40 years. Younger patients tend to have herniated cervical discs, and older patients tend to have spinal canal stenosis or foraminal stenosis.

4.4 Symptomatic CDD

In this presentation symptomatic CDD is limited to cervical radiculopathy and CSM. Neck pain and headache are not discussed in detail.

4.4.1 Cervical radiculopathy

(Synonyms: cervicobrachialgia, degenerative cervical foraminal stenosis with radiculopathy).

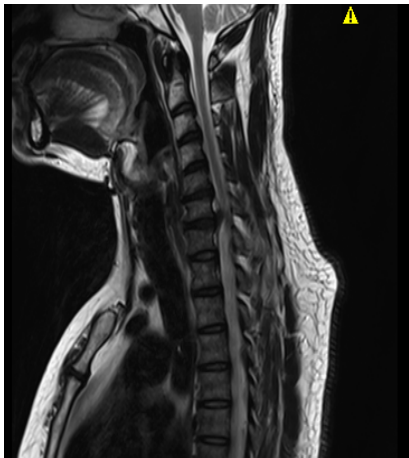The most common causes of radiculopathy are foraminal stenosis caused by osteophyte formation, disc protrusion and/or herniation of the disc.

Valleix first described brachialgia as a syndrome in 1841 (32). Later, Barre and Lieou recognized headache as a component of the neck pain syndrome in *Revue Neurologie* in 1926 (33).

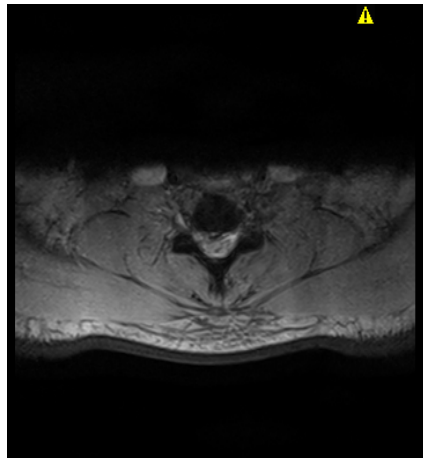
Acute symptoms occur in most cases without any history of trauma. Pain radiating from the neck to the corresponding dermatome of the affected spinal nerve is the dominating symptom followed by sensory loss in the same dermatome and muscular deficit in the corresponding myotome. Clinical evaluation comprises a detailed history and thorough physical examination, which includes testing of muscular strength, sensation, and reflexes, and Spurling's test (34-36).

Table 1. Cervical disc syndromes. (Modified from Handbook of Neurosurgery by Mark S. Greenberg, Thieme, 2006).

Disc	Nerve root	Pain, paresthesia, hypoesthesia	Reflex deficit	Motor deficit
C4/C5	C5	Shoulder	Biceps	Shoulder abduction and elbow flexion
C5/C6	C6	Upper arm, radial forearm, thumb	Biceps and brachioradialis	Elbow flexion
C6/C7	C7	Upper arm and forearm, fingers 2 and 3	Triceps	Elbow extension, wrist extension, finger extension.
C7/Th1	C8	Medial upper arm and forearm, fingers 4 and 5	Finger jerk	Finger flexion, finger abduction, and adduction



A



B

Figure 8: Cervical MR (sagittal T2 (A), Axial T2 (B)) of a patient with a herniated cervical disc at C6/C7 with right-sided C7 radiculopathy.

4.4.2 CSM

(Synonyms: cervical canal stenosis with myelopathy)

Central canal stenosis secondary to CDD with compression of the spinal cord can cause CSM. The disorder was originally described by Stookey in 1928 and was attributed to compression of the cord by cartilaginous nodules of degenerated disc material (21;37). CSM is the most common cause of spinal cord dysfunction in the elderly in the Western world (38).

CSM most often presents with neck pain, numb and clumsy hands, gait disturbances, sphincter dysfunction and/or impotence (39;40). Muscular weakness is usually a late symptom or sign. CSM develops in only a fraction of patients with spondylosis and may be stable for many years or may show rapid progression (41). The presence of cervical spondylosis alone is not enough to develop myelopathy. Normally, there is ample tolerance of the spinal cord to encroachment caused by spondylosis, and myelopathy is more likely to occur in patients with a developmentally narrow spinal canal. Arnold demonstrated that a sagittal diameter of ≤ 12 mm is a critical factor in the development of CSM (42).

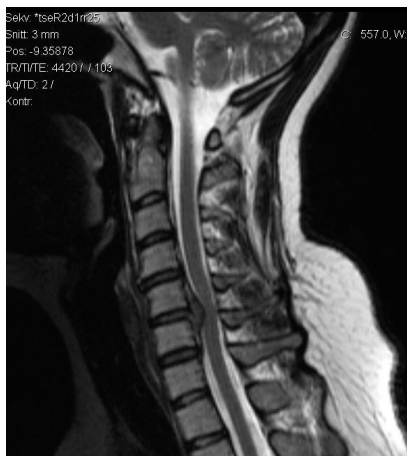Movement of the cervical spine may significantly influence the extent of mechanical compression of the spinal cord. As reviewed by White and Panjabi, several investigators have observed that the functional diameter of the cervical spinal canal may be reduced to a critical level or less upon flexion and extension (43).

4.5 Treatment of CDD

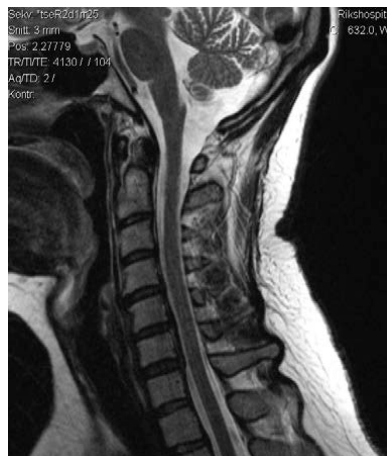4.5.1 Conservative treatment

4.5.1.1 Cervical radiculopathy

Conservative treatment is the first line of treatment because most patients improve without surgery. Some authors recommend surgical treatment after 6-8 weeks of conservative treatment (44-46). Because of the lack of evidence indicating the best conservative treatment option, there is disagreement about the mode and duration of treatment for symptomatic herniated disc(s) and/or narrowing of the intervertebral foramina(e) (47). Spontaneous remission of a herniated cervical disc is well known and is illustrated in Figure 9. Conservative treatment is beyond the scope of this thesis, and is therefore not discussed further.



A



B

Figure 9: MR of a 39-year-old woman who had intense C6 radiculopathy without muscular weakness or myelopathy in March 2006. She was treated conservatively, and in August 2006, she had no symptoms or signs of C6 radiculopathy. T2-weighted sagittal MR image of this woman in March 2006 (A) and August 2006 (B).

4.5.1.2 CSM

As mentioned above, cervical radiculopathy usually resolves without surgical intervention. By contrast, the long-term prognosis in untreated patients with CSM is elusive. Some patients experience a progressive decline, whereas others experience long periods of disease stability with intermittent exacerbations. Patients with mild myelopathy may be treated conservatively or surgically (47). Conservative treatment is beyond the scope of this thesis, and therefore not discussed further.

4.5.2 Surgical treatment

4.5.2.1 Candidates for surgery

Long lasting disability, pain, sensory disturbances, and/or paresis caused by compression of a cervical root are accepted indications for surgery. Even though there is no consensus about the timing of surgery, most surgeons generally agree that patients with clinical signs and/or symptoms of cervical disc degeneration (CDD) and coinciding MRI findings should be examined and considered for surgical treatment if they have failed to improve after 8 weeks of conservative treatment (45;46).

Patients with severe myelopathy should be treated with surgical decompression. Adequate decompression may arrest the progression of CSM, although this is not always the case. Patients must be informed before surgery that the best they can expect is cessation of the disease and symptom progression but that they may also experience further disease and symptom progression

4.5.2.2 Operative techniques

Surgery as an option for the treatment of radicular symptoms and myelopathy was first developed in the 1950s. The earliest surgeries on the cervical spine were performed via posterior approaches. Because of the potential for greater discomfort and longer hospital stay because of cutting of the paraspinosus muscles, and

awareness of postlaminectomy deformity, the anterior approach has become the method of choice for cervical pathologies. In the past four decades anterior cervical approaches have been developed and expanded from the simple anterior discectomy technique in the 1950, to multilevel corpectomy with anterior instrumentation, with or without dynamic plating constructs. The decision whether to use an anterior or posterior approach in both the treatment of radiculopathy and myelopathy, has been debated for many years.

Some of the different techniques are described in detail in the following section.

Anterior cervical discectomy and fusion /ACDF)

Dr. Exum Walker of Atlanta, Georgia, introduced the technique of anterior discography by inserting the needle into the anterior surface of the disc between the carotid sheath and trachea. Later, this approach was tested on cadavers and found to be easy, safe, and fast. Anterior fusion of the cervical spine has been performed since 1952; the first surgery was on a patient who had an extensive lytic lesion involving the fourth and fifth vertebrae. The ease of the approach and the attainment of stability in this individual sparked the application of the approach to other lesions in the cervical spine (48). The technique was refined further and popularized by Cloward and Smith and Robinson (49-52).

The Cloward operation

The Cloward technique is not used in our series, and therefore is not described further (49,52).

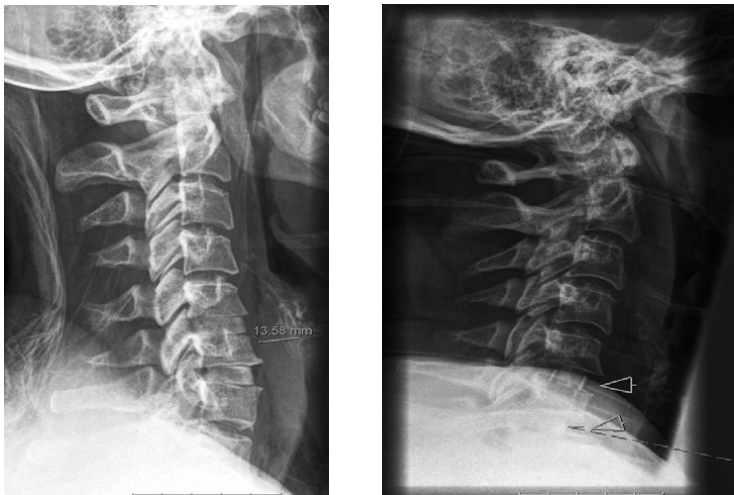The Smith-Robinson procedure

This procedure is performed from the right or left side of the column. It was first described with a left-sided incision to reduce the risk of damage to the recurrent laryngeal nerve. More recently, surgeons use both the left- and right-sided incision according to preference. Unlike the Cloward procedure, the disc material is removed with a curette, and the dura and nerve root are visualized (51;52). Thereafter, a tricortical bone graft is placed in the disc space. When one level is fused, the Smith

and Robinson do not recommend postoperative external immobilization, but if pain recurs postoperatively, they recommend a removable head-neck-shoulder splint made of plaster of Paris or a well-fitted neck brace for 1-3 months. When multiple levels are fused, immobilization of the neck for 3-6 months is the routine procedure (52).

In Norway, an anterior left- or right-sided approach has been the standard for treating CDD since Drs. Styri and Mangnæs, with the assistance of Dr. Cloward, performed the first procedure at Ullevål Hospital in the 1970s. Following implementation of the procedure, supplemental anterior plating has been used on a few occasions, whereas a stiff CAMP brace is used for all operations.

During the past 10 years, the polyetheretherketone (PEEK) cage has replaced the autologous bone graft in most cases. The routine use of external immobilization after ACDF was abandoned in 2005.



A

B

Figure 10: Cervical x-ray (side view) after the Smith-Robinson procedure with an autologous bone graft (A) and with a PEEK cage (B).

Cervical prosthesis

The cervical intervertebral disc can absorb load and allows movement between two vertebral discs. In 1964, Reitz et al. published the first report on the implantation of a cervical metal disc prosthesis (53). Since then, a wide range of designs and material has been introduced to try to provide the same unique properties of the cervical intervertebral disc (54-60). This procedure is beyond the scope of this thesis and is therefore not discussed further.

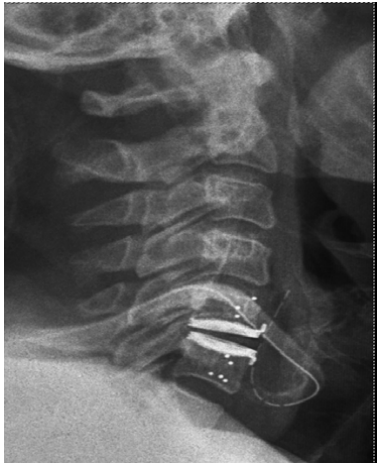

Figure 11: Cervical x-ray (side view) after insertion of the Bryan cervical disc prosthesis (with tantalum balls for RSA analysis)

Cervical laminectomy

Cervical laminectomy is used to treat spinal stenosis from the posterior approach. In this procedure, the laminae are cut to relieve pressure on the spinal cord and to provide more space for the spinal cord and nerve roots. The goal of cervical laminectomy is to prevent further damage to the spinal cord and to allow for as much recovery of function as possible. The procedure is performed under narcosis with the patient in the prone position and with the head fixed in a Mayfield clamp. Following the injection of a local anaesthetic, a midline incision is performed and sharp

dissection down to the laminae is made. The desired levels for decompression are identified and the laminectomy is performed using a high-speed drill or rongeurs. The thickened ligamentum flavum is removed, and the dura, and in some cases the spinal nerves, are decompressed.

We do not routinely perform posterior fixation, but we always use postoperative wound drains for 24 h. The patient is mobilized with a soft neck brace on postoperative day 1, and the brace is worn for 3 weeks.

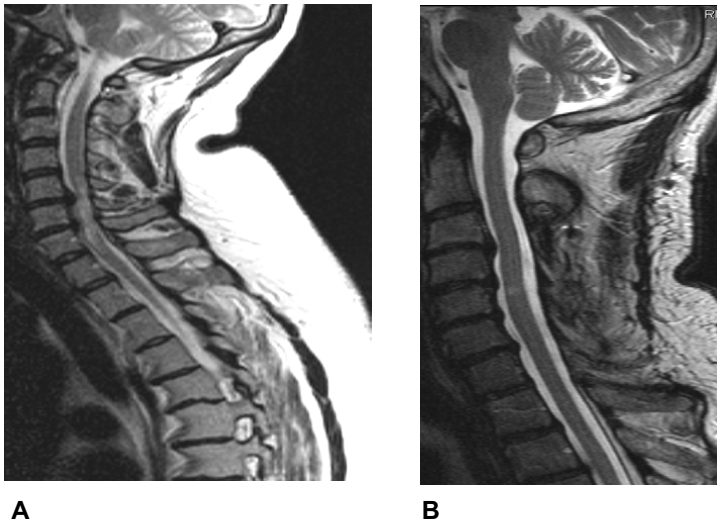


Figure 12: Cervical MR (T2, sagittal view) of a patient with cervical spinal stenosis before (A) and after cervical laminectomy (B).

Cervical laminoplasty

Cervical laminoplasty is used to treat spinal stenosis without removing the lamina. Different techniques are used. The procedure is beyond the scope of this thesis and is therefore not discussed in detail.

4.5.2.3 Surgical mortality and morbidity

All surgical procedures carry the inherent risk of complications. Early identification and prompt management of these potential complications are imperative for achieving good outcome in these patients. All surgeons should be aware of his/her complication rate, and thorough knowledge of previously reported complications is mandatory (44;61;62). The risks associated with cervical spinal surgery depend upon the approach: anterior or posterior.

Anterior approach

The anterior right- or left-sided approach to remove the intervertebral disc is a well-proven and safe route. The choice of the right- or left-sided approach is made according to the surgeon's preference. Some studies have suggested a greater risk of injury of the recurrent laryngeal nerve using a right-sided approach compared with a left-sided approach (63-65), although others found no difference between these approaches (66). In our series, all patients were operated on from the right side.

After the skin incision, the surgeon must either make a transverse incision of, or split, the platysma, as recommended by Cloward (49). The next step is to dissect medial to the vessels, taking care not to injure the carotid artery and the common jugular vein. Vascular injury of the great vessels seems to be rare, but postoperative haematoma is reported in 1.3 - 5.6% of cases (44;67-69).

Dysphagia is defined as a subjective increase in the time or effort required to move food from the mouth to the stomach and is a common complaint after ACDF. There is a broad range of signs and symptoms; painful swallowing, difficulty swallowing, coughing or choking with swallowing, or frequent throat clearing are reported frequently (44;70;71).

The exact explanation for this dysphagia is not clear. Prevertebral soft tissue swelling after ACDF as a cause of dysphagia is debated (72;73).

Oesophageal injury seems to be very rare and is reported in 0.3-4% of cases in the literature (44;72-76). Other complications such as Horner syndrome, injury of the vertebral artery, secondary dislocation of the graft, infections, spinal cord injury, spinal root injury, and CSF leakage are seen rarely (Table 2). To my knowledge, surgery at the wrong level is not described in the literature other than in our own publication (77).

In 2010, Nasser et al. published a systematic evidence-based review of the literature, titled "Complications in spine surgery", and concluded that retrospective reviews significantly underestimate the overall incidence of complications in spine surgery. Nasser et al. highlighted a lack of standardized reporting of these complications (61).

Yadla and co-workers recently published a prospective study on early complications in spine surgery, including trauma surgery, and reported high complication rates (78). Their interpretation was that many studies contain lower complication rates because of incomplete records and recall bias, and these results seem reasonable.

Table 2. Complications of cervical surgery.

Type of complication	ACDF		Cervical laminectomy	
Surgical mortality (death within 30 days)	0-0.2%	(44;67;68;79)	0-1%	(80-86)
Postoperative haematoma (neck)	0.2-5.6%	(44;67;68;79)	0.08-0.5%	(80;87;88)
Postoperative infection (neck)	0.1-0.9%	(44;89)	3.7-18%	(80;90;91)
Neurological deterioration	0.1-3.3%	(44;67;92)	5-30%	(80;82-84;87;93;94)
CSF leak	0.2-0.5%	(44;67)	2%	(95)
Dysphagia	9.6-17.8%	(44;70;71;96)	NA	
Lesion of oesophagus	0-3.4%	(72-75;97-100)	NA	
Vocal cord paralysis	3.1-11%	(44;101)	NA	
Lesion of major artery (vertebral artery)	0.3-0.5%	(102-104)	NA	
Anterior graft dislocation	0.4-2%	(79;105)	NA	
Operation at the wrong level			NA	
Increasing kyphosis after surgery	60%	(106)	17-20%	(107;108)
Thromboembolism	0.068%	(109)		
Pneumonia	4%	(78)		
Donor site morbidity (autologous crista graft)	2-4.7%	(110;111)	NA	
Haematoma (crista)	2.3%	(110)	NA	
Infection (crista)	0.6%	(110)	NA	

NA-Not applicable

4.5.2.4 Feasibility of surgery for CDD in an outpatient setting

In a time of limited health care resources, efficient and cost-effective treatments are needed. Outpatient surgery, when safe and feasible, is a more cost-effective option than inpatient surgery. Because of the short operation time and moderate postoperative pain, ACDF may be well suited for outpatient surgery (112-115).

However, potential life threatening complications of ACDF, such as postoperative haematoma, may limit the safety of this procedure in an outpatient setting (44).

Outpatient surgery is performed routinely for lumbar disc disease and is performed safely and efficiently for various types of general surgery, and orthopaedic and gynaecological procedures.

5. Aims of the present study (thesis)

1. To study mortality and morbidity following ACDF for CDD.
2. To study mortality, morbidity, and clinical outcome following posterior decompression for CSM.
3. To study clinical outcome of ACDF, with respect to both patient selection and choice of surgical procedure: fusion with an autologous iliac crest graft (AICG) versus fusion with an artificial cage made of polyetheretherketone (PEEK).
4. To study the safety, efficacy, and feasibility of performing ACDF in an outpatient setting.

6. Materials and methods

Paper I

This was a prospective study at Oslo University Hospital, Rikshospitalet, during the period January 2003 through January 2005. The complications that occurred in 390 consecutive patients who underwent ACDF for CDD were recorded.

The inclusion criteria included patients with persistent severe radicular pain that did not respond to conservative measures, cervical radiculopathy with progressive paresis, and myelopathy caused by disc disease. The exclusion criteria included cervical injury within the previous 4 weeks or the presence of a cervical tumour or ongoing cervical infection. The diagnosis was based on the history, neurological examination, and cervical MRI results. In the few cases where MRI was contraindicated, cervical CT myelography was used.

For all patients who underwent ACDF, we used an anterior approach to the cervical spine with a right-sided skin incision, as described originally by Robinson and Smith (51). The patients were observed in a postanaesthesia care unit for 4-6 h following surgery before their transfer to the neurosurgical ward. All patients were mobilized within 24 h after surgery and provided with a stiff collar. The vast majority were discharged from our hospital to the referring neurology department within 48-72 h after surgery. Surgery related complications were recorded prospectively.

Paper II

The patients included in this paper were a subset of the patients described in Paper I. The aim of this study was to evaluate the clinical outcomes after ACDF.

The prospective registration of clinical parameters included those parameters registered before surgery including age, sex, symptom duration before surgery (months), previous surgery for CDD, previous neck trauma, working status, radicular pain, neck pain, headache, myelopathy (yes/no), and paresis. Each of the three pain categories was scored using a visual analogue scale (VAS), where 0 indicated no pain and 10 represented extreme pain. The parameters registered during surgery included: number of levels fused, level fused, and fusion type (AICG or PEEK cage). The following parameters were registered at the 6-month follow-up visit to our outpatient clinic: radicular pain, neck pain, headache, myelopathy, paresis, working status, and patient satisfaction with the surgical treatment. Patient satisfaction was measured using a VAS, where a score of 0 indicated that the patient was not at all satisfied with the result of ACDF and a score of 10 indicated that the patient was very satisfied with the surgical outcome. We defined a VAS score ≥ 8 as a success, and a score ≤ 5 as a failure.

Paper III

All adults (>18 years of age) treated surgically with posterior decompression (cervical laminectomy or cervical laminoplasty) for cervical myelopathy secondary to cervical spinal canal stenosis at the Oslo University Hospitals, Rikshospitalet and Ullevål, between 2003 and 2008 were included in this retrospective study. Patients were identified by reviewing operative protocols from this time. The patient charts were reviewed systematically. Neurological function preoperatively, in the immediate postoperative period, and at the most recent outpatient examination was ascertained from the detailed neurological examination results recorded in the chart. Reoperation for postoperative haematoma and postoperative infection were recorded; if these complications resulted in sequela(e), these were also registered.

Surgery included a standard laminectomy or a standard open-door cervical laminoplasty, as first described by Hirabayashi. Postoperatively, all patients were observed in a postanesthesia care unit for 3-6 h and were then transferred either to a phase II step-down unit for overnight observation or directly to the neurosurgical

floor. Most patients were mobilized with a soft neck brace as soon as possible following surgery, either on the day of surgery or on postoperative day 1.

Paper IV

This was a prospective single centre study of patients who underwent single- or two-level ACDF for CDD as outpatients during the years 2008 to 2010. The study was performed at the Oslofjord Clinic (www.oslofjordklinikken.no), a private neurosurgical clinic, located in a suburb just outside of Oslo. The government covers all surgical costs performed at Oslo University Hospital, whereas private health insurance and/or the patients themselves pay for outpatient ACDF surgery at the Oslofjord Clinic.

The indications for ACDF surgery included persistent, severe radicular pain lasting for more than 3 months that failed to respond to conservative treatment, cervical radiculopathy with progressive paresis, selected cases of myelopathy secondary to cervical spinal canal stenosis, and selected cases where neck pain and headache were the chief complaints. MRI- documented CDD with compression of cervical nerve roots and/or spinal cord that correlated with the clinical symptoms and signs was required.

The exclusion criteria included cervical trauma within the past 4 weeks, cervical spine neoplasia, ongoing cervical infection, or medical co-morbidity anticipated to require more >6h of postoperative observation.

For all patients who underwent ACDF, we used an anterior approach to the cervical spine with a right-sided skin incision, as described originally by Robinson and Smith (51). All ACDF procedures were scheduled for morning surgery to allow for sufficient postoperative observation and discharge before 9 p.m. on the day of surgery.

Surgery was performed by two experienced board-certified neurosurgeons. The patients were observed in a recovery unit for 3 - 12 h following surgery. Two hours after surgery, the patients were mobilized and allowed to walk about the recovery unit. Patients were discharged if the following postoperative checklist was

satisfactory: adequate pain control, adequate wound haemostasis, stable neurological status, and the ability to drink, void and ambulate.

In order to study patient selection for outpatient ACDF versus ACDF done in an inpatient setting, the patient characteristics from the present study were compared to patient characteristics from our previous study; a study of complications in an inpatient setting within the same health region.

7. Summary of papers I – IV

Paper I

Lied B, Sundseth J, Helseth E. Immediate (0-6 h), early (6-72 h) and late (>72 h) complications after anterior cervical discectomy with fusion for cervical disc degeneration; discharge six hours after operation is feasible. **Acta Neurochir 2008;150:111-118.**

Objectives. The introduction of minimally invasive techniques and total intravenous anaesthesia has led to reports of the performance of anterior cervical discectomy and fusion as an outpatient. The safety of this approach requires information about the complications presenting within this period. The aim of this study was to assess the rates and types of immediate (0-6 h), early (6-72 h), and late (>72 h) complications after anterior cervical discectomy with fusion.

Methods. We prospectively studied complications after anterior cervical discectomy with fusion in patients with degenerative cervical disc disease. There were 390 consecutive operations: 278 fused with autologous iliac crest bone graft and 112 with a PEEK (Polyetheretherketone) graft.

Results. No patient died. Thirty-seven patients (9%) experienced one or more complications that could be related to the operation. These presented in the

immediate, early and late periods in 17, one and 19 patients, respectively. Thus, 18/37 complications were detected before discharge from the neurosurgical department 72h after operation and of these 17 (4.2%) were detected within the first 6 h after surgery. Each of the five potentially life-threatening neck haematomas was detected within 6 h (immediate).

Conclusions. After anterior cervical discectomy and fusion, a 6 h postoperative observation period followed by discharge from the neurosurgical unit is likely to be as safe as observation as an inpatient for a longer period.

Paper II

Lied B, Roenning PA, Sundseth J, Helseth E. Anterior cervical discectomy with fusion in patients with cervical disc degeneration: a prospective outcome study of 258 patients (181 fused with autologous bone graft and 77 fused with a PEEK cage).

BMC Surgery 2010;10,10.

Background. Anterior cervical discectomy with fusion (ACDF) is challenging with respect to both patient selection and choice of surgical procedure. The aim of this study was to evaluate the clinical outcome of ACDF, with respect to both patient selection and choice of surgical procedure: fusion with an autologous iliac crest graft (AICG) versus fusion with an artificial cage made of polyetheretherketone (PEEK).

Methods. This was a non-randomized prospective single centre outcome study of 258 patients who underwent ACDF for CDD. Fusion was attained with either tricortical AICG or PEEK cages without additional anterior plating, with treatment selected at the surgeon's discretion. Radicular pain, neck pain, headache, and patient satisfaction with the treatment were scored using a visual analogue scale (VAS).

Results. The median age was 47.5 (28.3–82.8) years, and 44% of patients were female. Fifty nine percent had single-level ACDF, 40% had two level ACDF, and 1% had three-level ACDF. Of the patients, 181 were fused with AICG and 77 with a PEEK cage. After surgery, the patients showed a significant reduction in radicular pain (Δ VAS = 3.05), neck pain (Δ VAS = 2.30), and headache (Δ VAS = 0.55). Six

months after surgery, 48% of patients had returned to work: however 24% were still receiving worker's compensation.

Using univariate and multivariate analyses we found that high preoperative pain intensity was significantly associated with a decrease in pain intensity after surgery, for all three pain categories. There were no significant correlations between pain relief and the following patient characteristics: fusion method (AICG or PEEK cage), sex, age, number of levels fused, disc level fused, previous neck surgery (except for neck pain), previous neck trauma, or preoperative symptom duration. Two hundred of the 256 (78%) patients evaluated the surgical result as successful. Only 27/256 (11%) classified the surgical result as a failure. Patient satisfaction was significantly associated with pain relief after surgery.

Conclusions. ACDF is an effective treatment for radicular pain in selected patients with CDD after 6 months follow up. Because of similar clinical outcomes and lack of donor site morbidity when using PEEK, we now prefer fusion with a PEEK cage to AICG. Lengthy symptom duration was not a negative prognostic marker in our patient population. The number of patients who returned to work 6 months after surgery was lower than expected.

Paper III

Halvorsen CM, Lied B, Harr ME, Roenning PA, Sundseth J, Kolstad F, Helseth E. Surgical mortality and complications leading to reoperation in 318 consecutive posterior decompressions for cervical spondylotic myelopathy. *Acta Neurol Scand* 2011;123:358-365.

Objective. To determine surgical mortality, incidence of surgery-related neurological deterioration and incidence of postoperative infection or haematoma requiring reoperation in a consecutive series of 318 patients surgically treated with laminectomy or laminoplasty for cervical spondylotic myelopathy.

Methods. This is a retrospective study of 318 consecutive patients treated with laminectomy or laminoplasty for cervical spondylotic myelopathy at Oslo University Hospital in the time period 2003-2008. The defined neurosurgical catchment area for

Oslo University Hospital is the southeast region of Norway with 2.7 million inhabitants. The patient charts were systematically reviewed, focusing primarily on operative notes, postoperative (po) complications such as po deterioration of neurological function, po haematoma and po infection and neurological function at most recent follow-up.

Results. The mean age was 64 years (range 29-90 years). Laminectomy was done in 310/318 (97.5%) and laminoplasty in 8/318 (2.5%) of the patients. The incidence of laminectomy/laminoplasty for CSM was 2.0/100,000 inhabitants per year. The surgical mortality was 0%, and 37 (11.6%) patients had a deterioration of neurological function in the immediate postoperative period. Four (1.3%) patients were reoperated due to po haematoma. We found a statistically significant association between po haematoma and previous posterior neck surgery and American Association of Anaesthetists score. Five (1.6%) patients were reoperated due to postoperative infection. Univariate logistic regression analysis showed a statistically significant association between po infection and the number of levels decompressed.

Conclusions. The incidence of laminectomy/laminoplasty for CSM is 2.0/100,000 inhabitants per year. Surgical mortality, postoperative haematoma and postoperative infection are rare complications of laminectomy/laminoplasty for CSM. Neurological deterioration is not an uncommon complication after posterior decompression for CSM.

Paper IV

Lied B, Roenning PA, Halvorsen CM, Ekseth K, Helseth E.

Outpatient anterior cervical discectomy and fusion (ACDF) for cervical disc disease; a prospective consecutive series of 96 patients. *Acta Neur Scand* 2012 May 10.

[Epub ahead of print].

Objectives: To evaluate surgical complications and clinical outcome in a consecutive series of 96 patients undergoing anterior cervical discectomy and fusion (ACDF) for cervical disc degeneration (CDD) in an outpatient setting.

Methods: Pre-, per- and postoperative data on patients undergoing single- or two-level outpatient ACDF at the private Oslofjord Clinic were prospectively collected.

Results: This study includes 96 consecutive patients with a mean age of 49.1 years. 36/96 had a two-level ACDF. Mean postoperative observation time before discharge was 350 minutes, and 95/96 were successfully discharged either to their home or to a hotel on the day of surgery. The surgical mortality was 0%, while the surgical morbidity rate was 5.2%. Two (2.1%) patients developed postoperative hematoma, 2 (2.1%) patients experienced postoperative dysphagia and 1 (1%) experienced deterioration of neurological function. Radicular pain, neck pain, and headache decreased significantly after surgery. 91% of patients were satisfied with the surgery, according to the NASSQ.

Conclusion: ACDF in carefully selected patients with CDD appears to be safe in the outpatient setting, provided a sufficient postoperative observation period. The clinical outcome and patient satisfaction of outpatients is comparable to that of inpatients.

8. Discussion

The fundamental conclusions that can be drawn from this thesis are:

1. Discharge from the neurosurgical unit following a 6 h postoperative observation period for CDD patients treated with ACDF is likely to be as safe as observation for longer periods.
2. ACDF is a successful treatment for radicular pain in selected patients. Because of the similar clinical outcome and lack of donor site morbidity when using PEEK, fusion with PEEK cage is now preferable to AICG.
3. Surgical mortality, postoperative haematoma, and postoperative infection are rare complications of laminectomy/laminoplasty for CSM, whereas neurological deterioration is not an uncommon complication after posterior decompression for CSM.
4. ACDF in carefully selected patients with CDD is just as safe in the outpatient setting as in the inpatient setting, provided there is a sufficient postoperative observation period.

8.1 Internal and external validity of the studies

Internal validity is defined as the validity of causal inferences in scientific studies. The various threats to internal validity such as confounding factors, selection bias, and information bias are discussed here. A confounding factor is an extraneous factor that correlates with both the dependent and independent variables. For example, in a study examining the correlation between alcohol drinking and lung cancer, smoking would be a confounding factor; if alcohol consumers were also more likely to be cigarette smokers, the results might erroneously show that alcohol drinking increases the risk of developing lung cancer.

Selection bias refers to self-selection of individuals to participate as subjects in an experimental study or to selection of patients by researchers to support a particular hypothesis. An example of this would be a study of the cardiovascular benefits of exercise in hypertensive patients that included only patients with no other co-morbidities.

Information bias refers to bias arising in a study due to misclassification of the level of exposure to the agent or factor being assessed and/or misclassification of the disease or other outcome itself. For example, information bias can arise when a person conducting the study interviews the study subjects.

External validity refers to the capacity to generalize the findings to the general population.

Papers I-III

Papers I-III of this thesis describe a general population who were treated at the same hospital and who had equal access to health care. The internal and external validity are deemed to be acceptable.

Paper IV

Paper IV describes a selected population; the patients in the study either had access to private insurance or paid for the surgery for themselves. In addition, only the most experienced attending neurosurgeons perform surgery in the outpatient setting. These factors imply that this study included some inherent selection bias. Therefore, the external validity of this study is low, except for in units where only the most experienced neurosurgeons perform outpatient surgery.

8.2 Complications after ACDF and cervical laminectomy for CDD

In our studies, the surgical mortality rate was 0% for patients treated with ACDF for CDD and for patients treated with laminectomy or laminoplasty for CSM. Other studies reported surgical mortality rates of 0-0.2% following ACDF and 0-1% following laminectomy (43-53).

Postoperative haematoma is a potentially life-threatening complication of ACDF and laminectomy (77). Vascular complications are most commonly recognized intraoperatively or in the immediate postoperative period. Following ACDF, we found a haematoma rate of 1.2%, which compares with the 0.2-2.4% rates found in other studies (43-46). The published series that we reviewed reported impressively low postoperative haematoma rates following laminectomy of 0.08 -0.5%, which are lower than our rate of 1.3% (47,54,55).

In our study, postoperative infection occurred in 0.2% of patients following ACDF; others have reported rates of 0.1-0.9% (45,56). In our laminectomy study, 1.6% of patients were afflicted with postoperative infection as compared with 3.7% in the study by Wimmer et al., which included both anterior and posterior procedures (22). The lower rate of infection in this series compared with other series could be explained by the routine prophylactic use of antibiotics in our patients. We found that the more levels decompressed, the greater the risk of postoperative infection.

Neurological deterioration was experienced in 1.2% of patients in our ACDF series, compared with other studies that reported neurological deterioration in 0.1-3.3% of

cases (43,45,59). Neurological deterioration was experienced by 11.6% of patients in the immediate postlaminectomy period. Previous studies show that 50-80 % of patients improve after surgery for CSM compared with 5-30 % whose neurological function deteriorates immediately following surgery or show subsequent deterioration thereafter (47,49-51,54,60,61).

In the ACDF study, we did not encounter any lesions of a major artery or the oesophagus, although we detected two instances of CSF leak. One patient was diagnosed peroperatively, and a duraplasty was performed; the other patient was diagnosed and reoperated on postoperative day 2. Neither patient had any sequela(e). Postoperative dysphagia and vocal change can be difficult to diagnose and classify. We found 0.3% of patients with permanent vocal cord paralysis. Dysphagia is a common complaint in the immediate postoperative period. It is a subjective symptom and can therefore be difficult to classify. Some consider dysphagia to be inevitable and is therefore not strictly a complication of ACDF (67). In a prospective study, Bazaz et al. report dysphagia in 50% of patients 1 month following ACDF surgery, whereas only 4.9% had persistent dysphagia at 6 months (70). In our study, 2.1% of patients reported dysphagia at 6 months after surgery. In a study by Yue et al., persistent ACDF related dysphagia was found in 35% of the patients 7 years after surgery (116).

Unfortunately, the common public perception is that neck surgery is dangerous. However, when ACDF is performed by an experienced neurosurgeon according to the clinical indications, the complication rate is low. We believe that ACDF is both safe and effective in relieving debilitating pain.

8.3 Clinical outcomes after ACDF for CDD

The effectiveness of ACDF in relieving radicular pain secondary to CDD is well documented both in long- and short-term follow up studies (117-122). In our studies, there was a significant reduction in radicular pain and neck pain at 6 months

postoperatively; 78.5% of the patients with radicular pain improved two or more points on the VAS scale, and 85.4% of the patients with neck pain improved two or more points on the VAS scale. The benefits of ACDF in relieving neck pain and/or headache caused by CDD, in the absence of radicular pain, are elusive. Future studies are needed to determine whether neck pain and/or headache justify ACDF.

By introducing the PEEK graft we eliminated the risk of donor site morbidity and reduced the operating time, yet we produced similar clinical results.

8.4 ACDF in the outpatient setting

In a time of limited health care resources, efficient and cost-effective treatments are needed. When safe and feasible, outpatient surgery is more cost effective than inpatient surgery (113). Outpatient surgery is performed routinely for lumbar disc disease and is performed safely and efficiently for various types of general surgery, and orthopaedic and gynaecologic procedures.

Because of short operation time and moderate postoperative pain, ACDF may be well suited for outpatient surgery (112-115).

However, potential complications of ACDF, such as postoperative haematoma, may limit the safe application of this procedure in the outpatient setting. In 2008, we published an analysis of the complications encountered in a consecutive series of 390 ACDFs performed on inpatients (Paper I). Based on this study, we suggested that ACDF could be performed safely as an outpatient procedure provided there is a sufficient postoperative observation period of 6 h.

The feasibility and safety of ACDF were evaluated in a prospective study of outpatient ACDFs performed at the private Oslofjord Clinic (Paper IV). Outpatient ACDF was found to be both feasible and safe. The complication rate in our

outpatient study was 5.2%; the complications encountered included postoperative haematoma, neurological deterioration, and dysphagia (Paper IV).

In our previous inpatient ACDF study from 2008, we found a complication rate of 9% (Paper I). The slightly higher complication rate found in the inpatient setting most likely relates to the larger proportion of patients with medical co-morbidities and probably does not reflect an inherent increased risk in inpatient versus outpatient surgery. Other groups have published results from which they concluded that ACDF performed in the outpatient setting is just as safe as ACDF performed in the inpatient setting (112-115;123). However, clinics performing outpatient ACDF should be affiliated with a hospital that has a neurosurgical unit in cases where an uncommon event causing serious complications requires prolonged hospitalization.

Clinical outcomes and patient satisfaction following outpatient ACDF are similar to those following inpatient ACDF (121). This has also been reported by Silvers et al. and Liu et al (113;123).

9. Conclusions

All potential, life-threatening complications of ACDF to treat CDD in our large inpatient series were detected within 6 h after surgery. This finding suggests that discharge from the neurosurgical unit following a 6 h postoperative observation period is likely to be as safe as observation for longer periods.

ACDF is a successful treatment for radicular pain in selected patients. Because of the similar clinical outcome and lack of donor site morbidity with the use of PEEK, fusion with a PEEK cage is now preferable to AICG. Lengthy symptom duration was not a negative prognostic marker in our patient population. The number of patients returning to work 6 months postoperatively was lower than initially expected.

The incidence of laminectomy/laminoplasty for CSM is 2.0/100,000 inhabitants per year.

Surgical mortality, postoperative haematoma and postoperative infection are rare complications of laminectomy/laminoplasty for CSM. Neurological deterioration is not an uncommon complication after posterior decompression for CSM.

ACDF in carefully selected patients with CDD is just as safe in the outpatient setting as in the inpatient setting, provided there is a sufficient postoperative observation period. The clinical outcome and satisfaction of outpatients are similar to those of inpatients. Outpatient surgery is more cost effective than inpatient surgery and should be considered an option in this time of limited health care resources.

10. Future perspectives

The incidence of degenerative disease of the spine increases with age, and the rapidly growing older population poses a challenge to the field of neurosurgery, which already has limited health care resources and long wait-lists for elective surgery. The alternative of outpatient surgery should be explored to clear wait-lists and to accommodate the inevitable rise in the number of surgeries for this disease expected in future.

The aetiology of degenerative disease of the spine is multifactorial, and examining each of the known risk factors should help identify measures to limit or prevent the development of degenerative spinal disease. Known risk factors for developing degenerative disc disease include osteoporosis and cigarette smoking. Osteoporosis can be prevented through diet and lifestyle, and education about these measures could in turn reduce the risk of degenerative disc disease. Health intervention programmes that focus on smoking cessation in patients with degenerative disease of the spine should be instituted. The importance of preventive

medicine cannot be underestimated; the prevention of disease is more cost effective than the treatment of disease.

11. Reference list

Reference List

- (1) ABBED KM, COUMANS JV. Cervical radiculopathy: pathophysiology, presentation, and clinical evaluation. *Neurosurgery* 2007; 60:S28-S34.
- (2) ROUGHLEY PJ. Biology of intervertebral disc aging and degeneration: involvement of the extracellular matrix. *Spine (Phila Pa 1976)* 2004; 29:2691-2699.
- (3) BLUMENKRANTZ N, SYLVEST J, ASBOE-HANSEN G. Local low-collagen content may allow herniation of intervertebral disc: biochemical studies. *Biochem Med* 1977; 18:283-290.
- (4) FERGUSON RJ, CAPLAN LR. Cervical spondylitic myelopathy. *Neurol Clin* 1985; 3:373-382.
- (5) SHEDID D, BENZEL EC. Cervical spondylosis anatomy: pathophysiology and biomechanics. *Neurosurgery* 2007; 60:S7-13.
- (6) LU J, EBRAHEIM NA, HUNTOON M, HAMAN SP. Cervical intervertebral disc space narrowing and size of intervertebral foramina. *Clin Orthop Relat Res* 2000;259-264.
- (7) OLMARKER K, RYDEVIK B, HOLM S. Edema formation in spinal nerve roots induced by experimental, graded compression. An experimental study on the pig cauda equina with special reference to differences in effects between rapid and slow onset of compression. *Spine (Phila Pa 1976)* 1989; 14:569-573.
- (8) KOBAYASHI S, YOSHIZAWA H, HACHIYA Y, UKAI T, MORITA T. Vasogenic edema induced by compression injury to the spinal nerve root. Distribution of intravenously injected protein tracers and gadolinium-enhanced magnetic resonance imaging. *Spine (Phila Pa 1976)* 1993; 18:1410-1424.
- (9) COOPER RG, FREEMONT AJ, HOYLAND JA et al. Herniated intervertebral disc-associated periradicular fibrosis and vascular abnormalities occur without inflammatory cell infiltration. *Spine (Phila Pa 1976)* 1995; 20:591-598.
- (10) LUNDBORG G. Structure and function of the intraneural microvessels as related to trauma, edema formation, and nerve function. *J Bone Joint Surg Am* 1975; 57:938-948.

- (11) RYDEVIK B, BROWN MD, LUNDBORG G. Pathoanatomy and pathophysiology of nerve root compression. *Spine (Phila Pa 1976)* 1984; 9:7-15.
- (12) LEE MJ, CASSINELLI EH, RIEW KD. Prevalence of cervical spine stenosis. Anatomic study in cadavers. *J Bone Joint Surg Am* 2007; 89:376-380.
- (13) EDWARDS WC, LAROCCA H. The developmental segmental sagittal diameter of the cervical spinal canal in patients with cervical spondylosis. *Spine (Phila Pa 1976)* 1983; 8:20-27.
- (14) GORE DR. Roentgenographic findings in the cervical spine in asymptomatic persons: a ten-year follow-up. *Spine (Phila Pa 1976)* 2001; 26:2463-2466.
- (15) MORISHITA Y, NAITO M, HYMANSON H, MIYAZAKI M, WU G, WANG JC. The relationship between the cervical spinal canal diameter and the pathological changes in the cervical spine. *Eur Spine J* 2009; 18:877-883.
- (16) ARNASSON O, CARLSSON CA, PELLETTIERI L. Surgical and conservative treatment of cervical spondylotic radiculopathy and myelopathy. *Acta Neurochir (Wien)* 1987; 84:48-53.
- (17) WHITE AA, III, PANJABI MM. Biomechanical considerations in the surgical management of cervical spondylotic myelopathy. *Spine (Phila Pa 1976)* 1988; 13:856-860.
- (18) FAGER CA. Results of adequate posterior decompression in the relief of spondylotic cervical myelopathy. *J Neurosurg* 1973; 38:684-692.
- (19) GORTER K. Influence of laminectomy on the course of cervical myelopathy. *Acta Neurochir (Wien)* 1976; 33:265-281.
- (20) HARROP JS, HANNA A, SILVA MT, SHARAN A. Neurological manifestations of cervical spondylosis: an overview of signs, symptoms, and pathophysiology. *Neurosurgery* 2007; 60:S14-S20.
- (21) FEHLINGS MG, SKAF G. A review of the pathophysiology of cervical spondylotic myelopathy with insights for potential novel mechanisms drawn from traumatic spinal cord injury. *Spine (Phila Pa 1976)* 1998; 23:2730-2737.
- (22) MAIR WG, DRUCKMAN R. The pathology of spinal cord lesions and their relation to the clinical features in protrusion of cervical intervertebral discs; a report of four cases. *Brain* 1953; 76:70-91.
- (23) BUNGE RP, PUCKETT WR, BECERRA JL, MARCILLO A, QUENCER RM. Observations on the pathology of human spinal cord injury. A review and classification of 22 new cases with details from a case of chronic cord compression with extensive focal demyelination. *Adv Neurol* 1993; 59:75-89.

- (24) BURROWS EH. The sagittal diameter of the spinal canal in cervical spondylosis. *Clin Radiol* 1963; 14:77-86.
- (25) OGINO H, TADA K, OKADA K et al. Canal diameter, anteroposterior compression ratio, and spondylotic myelopathy of the cervical spine. *Spine (Phila Pa 1976)* 1983; 8:1-15.
- (26) BODEN SD, MCCOWIN PR, DAVIS DO, DINA TS, MARK AS, WIESEL S. Abnormal magnetic-resonance scans of the cervical spine in asymptomatic subjects. A prospective investigation. *J Bone Joint Surg Am* 1990; 72:1178-1184.
- (27) LEHTO IJ, TERTTI MO, KOMU ME, PAAJANEN HE, TUOMINEN J, KORMANO MJ. Age-related MRI changes at 0.1 T in cervical discs in asymptomatic subjects. *Neuroradiology* 1994; 36:49-53.
- (28) MATSUMOTO M, FUJIMURA Y, SUZUKI N et al. MRI of cervical intervertebral discs in asymptomatic subjects. *J Bone Joint Surg Br* 1998; 80:19-24.
- (29) TERESI LM, LUFKIN RB, REICHER MA et al. Asymptomatic degenerative disk disease and spondylosis of the cervical spine: MR imaging. *Radiology* 1987; 164:83-88.
- (30) OKADA E, MATSUMOTO M, ICHIHARA D et al. Aging of the cervical spine in healthy volunteers: a 10-year longitudinal magnetic resonance imaging study. *Spine (Phila Pa 1976)* 2009; 34:706-712.
- (31) STAFIRA JS, SONNAD JR, YUH WT et al. Qualitative assessment of cervical spinal stenosis: observer variability on CT and MR images. *AJNR Am J Neuroradiol* 2003; 24:766-769.
- (32) VALLEIX FRANCOIS LOUIS ISIDORE. *Traite des Nevralgies ou affections douloureuses des nerfs. Brachialgia* 1841.
- (33) BARRE J.A. Sur un syndrome sympathique cervical posterieur et sa cause frequente larthrite cervicae. *Rev Neurol* 1926; 33.
- (34) TONG HC, HAIG AJ, YAMAKAWA K. The Spurling test and cervical radiculopathy. *Spine (Phila Pa 1976)* 2002; 27:156-159.
- (35) TRUUMES E, HERKOWITZ HN. Cervical spondylotic myelopathy and radiculopathy. *Instr Course Lect* 2000; 49:339-360.
- (36) VIIKARI-JUNTURA E, PORRAS M, LAASONEN EM. Validity of clinical tests in the diagnosis of root compression in cervical disc disease. *Spine (Phila Pa 1976)* 1989; 14:253-257.
- (37) STOOKEY B. Compression of the spinal cord due to ventral extradural cervical chondromas. *Archs Neurol Psychiat, Chicago* 1928; 20:275-291.

- (38) YOUNG WF. Cervical spondylotic myelopathy: a common cause of spinal cord dysfunction in older persons. *Am Fam Physician* 2000; 62:1064-70, 1073.
- (39) NURICK S. The pathogenesis of the spinal cord disorder associated with cervical spondylosis. *Brain* 1972; 95:87-100.
- (40) NURICK S. The natural history and the results of surgical treatment of the spinal cord disorder associated with cervical spondylosis. *Brain* 1972; 95:101-108.
- (41) CRANDALL PH, BATZDORF U. Cervical spondylotic myelopathy. *J Neurosurg* 1966; 25:57-66.
- (42) ARNOLD JG, JR. The clinical manifestations of spondylochondrosis (spondylosis) of the cervical spine. *Ann Surg* 1955; 141:872-889.
- (43) WHITE AA, III, PANJABI MM. Biomechanical considerations in the surgical management of cervical spondylotic myelopathy. *Spine (Phila Pa 1976)* 1988; 13:856-860.
- (44) FOUNTAS KN, KAPSALAKI EZ, NIKOLAKAKOS LG et al. Anterior cervical discectomy and fusion associated complications. *Spine (Phila Pa 1976)* 2007; 32:2310-2317.
- (45) ALDRICH F. Posterolateral microdisectomy for cervical monoradiculopathy caused by posterolateral soft cervical disc sequestration. *J Neurosurg* 1990; 72:370-377.
- (46) LUNS福德 LD, BISSONETTE DJ, JANNETTA PJ, SHEPTAK PE, ZORUB DS. Anterior surgery for cervical disc disease. Part 1: Treatment of lateral cervical disc herniation in 253 cases. *J Neurosurg* 1980; 53:1-11.
- (47) NIKOLAIDIS I, FOUYAS IP, SANDERCOCK PA, STATHAM PF. Surgery for cervical radiculopathy or myelopathy. *Cochrane Database Syst Rev* 2010;CD001466.
- (48) BAILEY RW, BADGLEY CE. Stabilization of the cervical spine by anterior fusion. *J Bone Joint Surg Am* 1960; 42-A:565-594.
- (49) CLOWARD RB. The anterior approach for removal of ruptured cervical discs. *J Neurosurg* 1958; 15:602-616.
- (50) CLOWARD RB. Lesions of the intervertebral discs and their treatment by interbody fusion methods. *Clin Orthop* 1963; 2:51-77.
- (51) ROBINSON RA, SMITH GW. Anterolateral cervical disc removal and interbody fusion for cervical disc syndrome. *Bull Johns Hopkins Hospital* 1955; 96:223-224.
- (52) SMITH GW, ROBINSON RA. The treatment of certain cervical-spine disorders by anterior removal of the intervertebral disc and interbody fusion. *J Bone Joint Surg Am* 1958; 40-A:607-624.

- (53) REITZ H, JOUBERT MJ. Intractable headache and cervicobrachialgia treated by complete replacement of cervical intervertebral discs with a metal prosthesis. *S Afr Med J* 1964; 38:881-884.
- (54) SASSO RC, SMUCKER JD, HACKER RJ, HELLER JG. Artificial disc versus fusion: a prospective, randomized study with 2-year follow-up on 99 patients. *Spine* 2007; 32:2933-2940.
- (55) SEKHON LH. Cervical arthroplasty in the management of spondylotic myelopathy: 18-month results. *Neurosurg Focus* 2004; 17:E8.
- (56) RIEW KD, BUCHOWSKI JM, SASSO R, ZDEBLICK T, METCALF NH, ANDERSON PA. Cervical disc arthroplasty compared with arthrodesis for the treatment of myelopathy. *J Bone Joint Surg Am* 2008; 90:2354-2364.
- (57) STEINMETZ MP, PATEL R, TRAYNELIS V, RESNICK DK, ANDERSON PA. Cervical disc arthroplasty compared with fusion in a workers' compensation population. *Neurosurgery* 2008; 63:741-747.
- (58) BRYAN VE, JR. Cervical motion segment replacement. *Eur Spine J* 2002; 11 Suppl 2:S92-S97.
- (59) SASSO RC, SMUCKER JD, HACKER RJ, HELLER JG. Clinical outcomes of BRYAN cervical disc arthroplasty: a prospective, randomized, controlled, multicenter trial with 24-month follow-up. *J Spinal Disord Tech* 2007; 20:481-491.
- (60) MURREY D, JANSSEN M, DELAMARTER R et al. Results of the prospective, randomized, controlled multicenter Food and Drug Administration investigational device exemption study of the ProDisc-C total disc replacement versus anterior discectomy and fusion for the treatment of 1-level symptomatic cervical disc disease. *Spine J* 2008.
- (61) NASSER R, YADLA S, MALTENFORT MG et al. Complications in spine surgery. *J Neurosurg Spine* 2010; 13:144-157.
- (62) CAMPBELL PG, YADLA S, MALONE J et al. Early complications related to approach in cervical spine surgery: single-center prospective study. *World Neurosurg* 2010; 74:363-368.
- (63) MORPETH JF, WILLIAMS MF. Vocal fold paralysis after anterior cervical discectomy and fusion. *Laryngoscope* 2000; 110:43-46.
- (64) NETTERVILLE JL, KORIWCHAK MJ, WINKLE M, COUREY MS, OSSOFF RH. Vocal fold paralysis following the anterior approach to the cervical spine. *Ann Otol Rhinol Laryngol* 1996; 105:85-91.

- (65) WEISBERG NK, SPENGLER DM, NETTERVILLE JL. Stretch-induced nerve injury as a cause of paralysis secondary to the anterior cervical approach. *Otolaryngol Head Neck Surg* 1997; 116:317-326.
- (66) KILBURG C, SULLIVAN HG, MATHIASON MA. Effect of approach side during anterior cervical discectomy and fusion on the incidence of recurrent laryngeal nerve injury. *J Neurosurg Spine* 2006; 4:273-277.
- (67) BERTALANFFY H, EGGERT HR. Complications of anterior cervical discectomy without fusion in 450 consecutive patients. *Acta Neurochir (Wien)* 1989; 99:41-50.
- (68) ESPERSEN JO, BUHL M, ERIKSEN EF et al. Treatment of cervical disc disease using Cloward's technique. I. General results, effect of different operative methods and complications in 1,106 patients. *Acta Neurochir (Wien)* 1984; 70:97-114.
- (69) YU NH, JAHNG TA, KIM CH, CHUNG CK. Life-threatening late hemorrhage due to superior thyroid artery dissection after anterior cervical discectomy and fusion. *Spine (Phila Pa 1976)* 2010; 35:E739-E742.
- (70) BAZAZ R, LEE MJ, YOO JU. Incidence of dysphagia after anterior cervical spine surgery: a prospective study. *Spine* 2002; 27:2453-2458.
- (71) LEE MJ, BAZAZ R, FUREY CG, YOO J. Risk factors for dysphagia after anterior cervical spine surgery: a two-year prospective cohort study. *Spine J* 2007; 7:141-147.
- (72) GRAHAM JJ. Complications of cervical spine surgery. A five-year report on a survey of the membership of the Cervical Spine Research Society by the Morbidity and Mortality Committee. *Spine* 1989; 14:1046-1050.
- (73) NEWHOUSE KE, LINDSEY RW, CLARK CR, LIEPONIS J, MURPHY MJ. Esophageal perforation following anterior cervical spine surgery. *Spine (Phila Pa 1976)* 1989; 14:1051-1053.
- (74) ORLANDO ER, CAROLI E, FERRANTE L. Management of the cervical esophagus and hypopharynx perforations complicating anterior cervical spine surgery. *Spine (Phila Pa 1976)* 2003; 28:E290-E295.
- (75) RUETH N, SHAW D, GROTH S et al. Management of cervical esophageal injury after spinal surgery. *Ann Thorac Surg* 2010; 90:1128-1133.
- (76) WANG JC, MCDONOUGH PW, ENDOW KK, DELAMARTER RB. Increased fusion rates with cervical plating for two-level anterior cervical discectomy and fusion. *Spine* 2000; 25:41-45.
- (77) LIED B, SUNDSETH J, HELSETH E. Immediate (0-6 h), early (6-72 h) and late (>72 h) complications after anterior cervical discectomy with fusion for cervical disc degeneration; discharge six hours after operation is feasible. *Acta Neurochir (Wien)* 2008; 150:111-118.

- (78) YADLA S, MALONE J, CAMPBELL PG et al. Incidence of early complications in cervical spine surgery and relation to preoperative diagnosis: a single-center prospective study. *J Spinal Disord Tech* 2011; 24:50-54.
- (79) TEW JM, JR., MAYFIELD FH. Complications of surgery of the anterior cervical spine. *Clin Neurosurg* 1976; 23:424-434.
- (80) WANG MY, SHAH S, GREEN BA. Clinical outcomes following cervical laminoplasty for 204 patients with cervical spondylotic myelopathy. *Surg Neurol* 2004; 62:487-492.
- (81) CARETTE S, FEHLINGS MG. Clinical practice. Cervical radiculopathy. *N Engl J Med* 2005; 353:392-399.
- (82) KUMAR VG, REA GL, MERVIS LJ, MCGREGOR JM. Cervical spondylotic myelopathy: functional and radiographic long-term outcome after laminectomy and posterior fusion. *Neurosurgery* 1999; 44:771-777.
- (83) EBERSOLD MJ, PARE MC, QUAST LM. Surgical treatment for cervical spondylitic myelopathy. *J Neurosurg* 1995; 82:745-751.
- (84) HASEGAWA K, HOMMA T, CHIBA Y, HIRANO T, WATANABE K, YAMAZAKI A. Effects of surgical treatment for cervical spondylotic myelopathy in patients > or = 70 years of age: a retrospective comparative study. *J Spinal Disord Tech* 2002; 15:458-460.
- (85) GREINER-PERTH R, ELSAGHIR H, BOHM H, EL-MESHTAWY M. The incidence of C5-C6 radiculopathy as a complication of extensive cervical decompression: own results and review of literature. *Neurosurg Rev* 2005; 28:137-142.
- (86) CHILES BW, III, LEONARD MA, CHOUDHRI HF, COOPER PR. Cervical spondylotic myelopathy: patterns of neurological deficit and recovery after anterior cervical decompression. *Neurosurgery* 1999; 44:762-769.
- (87) SCAVARDA D, PERUZZI P, BAZIN A et al. [Postoperative spinal extradural hematomas. 14 cases]. *Neurochirurgie* 1997; 43:220-227.
- (88) YI S, YOON DH, KIM KN, KIM SH, SHIN HC. Postoperative spinal epidural hematoma: risk factor and clinical outcome. *Yonsei Med J* 2006; 47:326-332.
- (89) MURREY D, JANSSEN M, DELAMARTER R et al. Results of the prospective, randomized, controlled multicenter Food and Drug Administration investigational device exemption study of the ProDisc-C total disc replacement versus anterior discectomy and fusion for the treatment of 1-level symptomatic cervical disc disease. *Spine J* 2009; 9:275-286.

- (90) WIMMER C, GLUCH H, FRANZREB M, OGON M. Predisposing factors for infection in spine surgery: a survey of 850 spinal procedures. *J Spinal Disord* 1998; 11:124-128.
- (91) CASHA S, ENGELBRECHT HA, DUPLESSIS SJ, HURLBERT RJ. Suspended laminoplasty for wide posterior cervical decompression and intradural access: results, advantages, and complications. *J Neurosurg Spine* 2004; 1:80-86.
- (92) IKENAGA M, SHIKATA J, TANAKA C. Radiculopathy of C-5 after anterior decompression for cervical myelopathy. *J Neurosurg Spine* 2005; 3:210-217.
- (93) LUNS福德 LD, BISSONETTE DJ, ZORUB DS. Anterior surgery for cervical disc disease. Part 2: Treatment of cervical spondylotic myelopathy in 32 cases. *J Neurosurg* 1980; 53:12-19.
- (94) CHEUNG WY, ARVINTE D, WONG YW, LUK KD, CHEUNG KM. Neurological recovery after surgical decompression in patients with cervical spondylotic myelopathy - a prospective study. *Int Orthop* 2008; 32:273-278.
- (95) TEPLICK JG, PEYSTER RG, TEPLICK SK, GOODMAN LR, HASKIN ME. CT Identification of postlaminectomy pseudomeningocele. *AJR Am J Roentgenol* 1983; 140:1203-1206.
- (96) LEE MJ, BAZAZ R, FUREY CG, YOO J. Influence of anterior cervical plate design on Dysphagia: a 2-year prospective longitudinal follow-up study. *J Spinal Disord Tech* 2005; 18:406-409.
- (97) GAUDINEZ RF, ENGLISH GM, GEBHARD JS, BRUGMAN JL, DONALDSON DH, BROWN CW. Esophageal perforations after anterior cervical surgery. *J Spinal Disord* 2000; 13:77-84.
- (98) WANG SB, WANG SL, MA QJ, LIU DD, ZHANG JF, ZHANG XL. [Diagnosis and treatment of esophageal fistula in anterior cervical spine surgery]. *Zhonghua Wai Ke Za Zhi* 2004; 42:1319-1321.
- (99) ROMANO PS, CAMPA DR, RAINWATER JA. Elective cervical discectomy in California: postoperative in-hospital complications and their risk factors. *Spine (Phila Pa 1976)* 1997; 22:2677-2692.
- (100) VROUENRAETS BC, BEEN HD, BROUWER-MLADIN R, BRUNO M, VAN LANSCHOT JJ. Esophageal perforation associated with cervical spine surgery: report of two cases and review of the literature. *Dig Surg* 2004; 21:246-249.
- (101) JUNG A, SCHRAMM J, LEHNERDT K, HERBERHOLD C. Recurrent laryngeal nerve palsy during anterior cervical spine surgery: a prospective study. *J Neurosurg Spine* 2005; 2:123-127.

- (102) BURKE JP, GERSZTEN PC, WELCH WC. Iatrogenic vertebral artery injury during anterior cervical spine surgery. *Spine J* 2005; 5:508-514.
- (103) GOLFINOS JG, DICKMAN CA, ZABRAMSKI JM, SONNTAG VK, SPETZLER RF. Repair of vertebral artery injury during anterior cervical decompression. *Spine (Phila Pa 1976)* 1994; 19:2552-2556.
- (104) SMITH MD, EMERY SE, DUDLEY A, MURRAY KJ, LEVENTHAL M. Vertebral artery injury during anterior decompression of the cervical spine. A retrospective review of ten patients. *J Bone Joint Surg Br* 1993; 75:410-415.
- (105) RILEY LH, III, VACCARO AR, DETTORI JR, HASHIMOTO R. Postoperative dysphagia in anterior cervical spine surgery. *Spine (Phila Pa 1976)* 2010; 35:S76-S85.
- (106) SAVOLAINEN S, RINNE J, HERNESNIEMI J. A prospective randomized study of anterior single-level cervical disc operations with long-term follow-up: surgical fusion is unnecessary. *Neurosurgery* 1998; 43:51-55.
- (107) KAPTAIN GJ, SIMMONS NE, REPLOGLE RE, POBERESKIN L. Incidence and outcome of kyphotic deformity following laminectomy for cervical spondylotic myelopathy. *J Neurosurg* 2000; 93:199-204.
- (108) MIYAZAKI K, KIRITA Y. Extensive simultaneous multisegment laminectomy for myelopathy due to the ossification of the posterior longitudinal ligament in the cervical region. *Spine (Phila Pa 1976)* 1986; 11:531-542.
- (109) SMITH JS, FU KM, POLLY DW, JR. et al. Complication rates of three common spine procedures and rates of thromboembolism following spine surgery based on 108,419 procedures: a report from the Scoliosis Research Society Morbidity and Mortality Committee. *Spine (Phila Pa 1976)* 2010; 35:2140-2149.
- (110) CAUTHEN JC, KINARD RE, VOGLER JB et al. Outcome analysis of noninstrumented anterior cervical discectomy and interbody fusion in 348 patients. *Spine (Phila Pa 1976)* 1998; 23:188-192.
- (111) WRIGHT IP, EISENSTEIN SM. Anterior cervical discectomy and fusion without instrumentation. *Spine (Phila Pa 1976)* 2007; 32:772-774.
- (112) ERICKSON M, FITES BS, THIEKEN MT, MCGEE AW. Outpatient anterior cervical discectomy and fusion. *Am J Orthop* 2007; 36:429-432.
- (113) SILVERS HR, LEWIS PJ, SUDDABY LS, ASCH HL, CLABEAUX DE, BLUMENSON LE. Day surgery for cervical microdiscectomy: is it safe and effective? *J Spinal Disord* 1996; 9:287-293.

- (114) STIEBER JR, BROWN K, DONALD GD, COHEN JD. Anterior cervical decompression and fusion with plate fixation as an outpatient procedure. *Spine J* 2005; 5:503-507.
- (115) PURZNER T, PURZNER J, MASSICOTTE EM, BERNSTEIN M. Outpatient brain tumor surgery and spinal decompression: a prospective study of 1003 patients. *Neurosurgery* 2011.
- (116) YUE WM, BRODNER W, HIGHLAND TR. Persistent swallowing and voice problems after anterior cervical discectomy and fusion with allograft and plating: a 5- to 11-year follow-up study. *Eur Spine J* 2005; 14:677-682.
- (117) GOLDBERG EJ, SINGH K, VAN U, GARRETSON R, AN HS. Comparing outcomes of anterior cervical discectomy and fusion in workman's versus non-workman's compensation population. *Spine J* 2002; 2:408-414.
- (118) GORE DR, SEPIC SB. Anterior discectomy and fusion for painful cervical disc disease. A report of 50 patients with an average follow-up of 21 years. *Spine* 1998; 23:2047-2051.
- (119) HACKER RJ, CAUTHEN JC, GILBERT TJ, GRIFFITH SL. A prospective randomized multicenter clinical evaluation of an anterior cervical fusion cage. *Spine* 2000; 25:2646-2654.
- (120) JAGANNATHAN J, SHAFFREY CI, OSKOUIAN RJ et al. Radiographic and clinical outcomes following single-level anterior cervical discectomy and allograft fusion without plate placement or cervical collar. *J Neurosurg Spine* 2008; 8:420-428.
- (121) LIED B, ROENNING PA, SUNDSETH J, HELSETH E. Anterior cervical discectomy with fusion in patients with cervical disc degeneration: a prospective outcome study of 258 patients (181 fused with autologous bone graft and 77 fused with a PEEK cage). *BMC Surg* 2010; 10:10.
- (122) PEOLSSON A. Investigation of clinically important benefit of anterior cervical decompression and fusion. *Eur Spine J* 2007; 16:507-514.
- (123) LIU JT, BRINER RP, FRIEDMAN JA. Comparison of inpatient vs. outpatient anterior cervical discectomy and fusion: a retrospective case series. *BMC Surg* 2009; 9:3.

RESEARCH ARTICLE

Open Access

Anterior cervical discectomy with fusion in patients with cervical disc degeneration: a prospective outcome study of 258 patients (181 fused with autologous bone graft and 77 fused with a PEEK cage)

Bjarne Lied^{1,2,3*}, Paal Andre Roenning², Jarle Sundseth¹, Eirik Helseth^{1,2,3}

Abstract

Background: Anterior cervical discectomy with fusion (ACDF) is challenging with respect to both patient selection and choice of surgical procedure. The aim of this study was to evaluate the clinical outcome of ACDF, with respect to both patient selection and choice of surgical procedure: fusion with an autologous iliac crest graft (AICG) versus fusion with an artificial cage made of polyetheretherketone (PEEK).

Methods: This was a non-randomized prospective single-center outcome study of 258 patients who underwent ACDF for cervical disc degeneration (CDD). Fusion was attained with either tricortical AICG or PEEK cages without additional anterior plating, with treatment selected at surgeon's discretion. Radicular pain, neck-pain, headache and patient satisfaction with the treatment were scored using the visual analogue scale (VAS).

Results: The median age was 47.5 (28.3-82.8) years, and 44% of patients were female. 59% had single-level ACDF, 40% had two level ACDF and 1% had three-level ACDF. Of the patients, 181 were fused with AICG and 77 with a PEEK-cage. After surgery, the patients showed a significant reduction in radicular pain (Δ VAS = 3.05), neck pain (Δ VAS = 2.30) and headache (Δ VAS = 0.55). Six months after surgery, 48% of patients had returned to work; however 24% were still receiving workers' compensation.

Using univariate and multivariate analyses we found that high preoperative pain intensity was significantly associated with a decrease in pain intensity after surgery, for all three pain categories. There were no significant correlations between pain relief and the following patient characteristics: fusion method (AICG or PEEK-cage), sex, age, number of levels fused, disc level fused, previous neck surgery (except for neck pain), previous neck trauma, or pre-operative symptom duration. Two hundred out of the 256 (78%) patients evaluated the surgical result as successful. Only 27/256 (11%) classified the surgical result as a failure. Patient satisfaction was significantly associated with pain relief after surgery.

Conclusions: ACDF is an effective treatment for radicular pain in selected patients with CDD after six months follow up.

Because of similar clinical outcomes and lack of donor site morbidity when using PEEK, we now prefer fusion with PEEK cage to AICG.

Lengthy symptom duration was not a negative prognostic marker in our patient population.

The number of patients who returned to work 6 months after surgery was lower than expected.

* Correspondence: bjarnelied@ulleval.no

¹Department of Neurosurgery-Rikshospitalet, Oslo University Hospital, N-0027 Oslo, Norway

Background

The vast majority of patients with symptomatic cervical disc degeneration (CDD) respond well to conservative treatment [1]. For nonresponders, surgical treatment using ACDF is an option for selected patients [2]. In the USA, the annual incidence of surgery for CDD is 50-60 per 100 000 inhabitants [3]. Selection of adequate candidates for ACDF surgery is a continuous challenge. According to the literature, the following are potential positive predictive preoperative markers: intense radicular pain, low disability, young age, soft disc disease in one segmental level, male sex, non-smoker status, presence of a correlation between radiological and clinical findings, good hand strength, good active range of motion in the neck, and no spinal litigations [4,5]. In surgery for lumbar disc degeneration, symptom duration > 6 months is regarded as a negative prognostic factor [6]. This is also reported to be true for ACDF surgery [7]. This is intriguing, as many patients referred to ACDF surgery have symptom duration > 6 months. Is surgery in these patients worthwhile or futile?

The gold standard for ACDF has been fusion with an AICG [8-10]. This is a relatively safe procedure with few complications [11-13]. However, this surgical procedure has been hampered by iliac crest donor site morbidity. This has led to a growing interest in artificial cages made of various materials, including tantalum blocks, titanium, carbonfiber and polyetheretherketone (PEEK), to replace the AICG [12,14-18]. In our hospital since 2004 we have gradually shifted from AICG to PEEK. We found no increase in complications after shifting to fusion with a PEEK cage [11].

We prospectively registered all ACDF patients followed in our department from 2003-2005 and used this information to address the following questions.

1. What improvement in clinical outcomes can be expected after ACDF for CDD with regard to radicular pain, neck pain, headache, and return to work?

2. Did the gradual shift from fusion with AICG to fusion with PEEK cage, in our department during the study period, influence outcomes?

3. Do symptom duration or other preoperative clinical variables correlate with outcome after ACDF for CDD in our series?

Methods

This was a prospective single-center study of patients who underwent single-, two-, or three-level ACDF for CDD. The study was performed at the Oslo University Hospital-Rikshospitalet in Oslo from 2003 to 2005. All surgeons were asked to participate in a prospective registration of clinical parameters. During this period, 390 patients (total group) were eligible for inclusion and we obtained complete preoperative and follow-up data

for 258 patients (66.1%) (study group). Only the 258 patients with complete data sets were included in the analysis.

Inclusion criteria (1 + 2)

The inclusion criteria were

1. One or more of the following symptoms and signs of CDD:

- a. Persistent severe radicular pain not responding to conservative management for three months.
- b. Cervical radiculopathy with progressive paresis.
- c. Selected cases with myelopathy secondary to cervical spinal canal stenosis that can be adequately decompressed with ACDF.
- d. Selected cases with mainly neck pain and headache and less radicular pain.

2. MRI- documented CDD with compression of cervical nerve roots or spinal cord, which most likely explain the clinical symptoms and signs.

Exclusion criteria

The exclusion criteria were

1. Cervical trauma within the past four weeks.
2. Cervical neoplasia.
3. Ongoing cervical infection.

Diagnostic work-up

The diagnostic work-up included

1. Clinical and neurological examination.
2. Cervical MRI (cervical CT-myelography was used in one case where MRI was contraindicated due to a permanent pacemaker).

ACDF

In all patients, we used an anterior approach to the cervical spine with a right-sided skin incision, as originally described by Robinson and Smith [9]. A self-retractor was mounted after verification of the levels of interest using fluoroscopy, (Shadow -line, V. Mueller Neuro/Spine Product, Cardinal Health, San Carlos, CA).

In most patients, an operating microscope was used and the disc was removed with a high-speed drill (Midas Rex, Medtronic, Memphis, TN). Removal of the posterior longitudinal ligament and the final decompression of the nerve roots were performed using small rongeurs. Bilateral nerve root decompression was always performed, even in patients with unilateral symptoms. After the procedure, distraction was applied using the Shadow-line Distraction System (V. Mueller Neuro/Spine Product, Cardinal Health). Fusion was attained with either tricortical AICG or PEEK cages (Cervios, Stratec Medical, Oberdorf, Switzerland), at the discretion of the surgeon. After

removal of the Shadow-line distracters, the screw holes were plugged with bone wax (Ethicon, Johnson & Johnson, Somerville, NJ) to prevent postoperative bleeding. Wound drainage was not routinely used. A single dose of cephalothin (30 mg/kg), which was used as infection prophylaxis, was administered 15-30 min before the skin incision [19-21].

Iliac crest auto graft

The tricortical AICG was harvested from the right iliac crest. Care was taken to preserve the anterior 2 cm of the iliac crest and the lateral cutaneous femoral nerve. The bone grafts were harvested using an oscillating saw and a graft cutter, and the bone bed was waxed with bone wax (Ethicon, Johnson & Johnson, USA). Wound drainage was not routinely used, and the surrounding soft tissue was infiltrated with 20 ml of bupivacaine after wound closure.

Postoperative care

The patients were observed in a recovery unit for the first 4-6 h after surgery, and were then transferred to the regular neurosurgical ward. All patients were mobilized with a stiff collar within 24 h after surgery. Almost all patients were discharged from our hospital to the referring neurological department 48-72 h after surgery. All patients were encouraged repeatedly to participate in normal activities 6-14 weeks after surgery. A final clinical examination was performed 6 months after surgery in our outpatient clinic.

Prospective registration of clinical parameters

The parameters registered the day before surgery included age, sex, symptom duration before surgery (months), previous surgery for CDD, previous neck trauma, working status, radicular pain, neck pain, headache, myelopathy (yes/no), and paresis (muscular strength graded according to the Royal Medical Research Council of Great Britain, where 5 is normal strength and 0 is total paralysis in the affected muscle group)[22]. Each of the three pain categories was scored using a VAS, where 0 indicated no pain and 10 represented extreme pain[23].

As the clinical impact of changes in VAS scores less than ± 2 is unclear, we estimated the number of patients that had changes in VAS scores of more than ± 2 for the three pain categories [24,25]. The parameters registered during surgery included: number of levels fused (single-level, two-level, or three-level fusion), level fused (C3/C4, C4/C5, C5/C6, C6/7 or C7/Th1) and fusion type (AICG or PEEKcage). The following parameters were registered at the 6-month follow-up visit in our outpatient clinic: radicular pain, neck pain, headache, myelopathy (a diagnosis of myelopathy required

neurological signs of upper motor neuron affection as Babinsky sign, hyperreflexia or increased muscular tone), paresis, working status and patient satisfaction with the surgical treatment. Patient satisfaction was measured using a VAS scale, where a score of 0 indicated that the patient was not at all satisfied with the result of ACDF and a score of 10 indicated that the patient was very satisfied with the surgical outcomes [26,27]. We defined a VAS score ≥ 8 as a success, while a score ≤ 5 was regarded as a failure.

Surgery-related complications

We have previously published our complications in 390 consecutive ACDF operations, which included 278 patients fused with AICG and 112 patients fused with a PEEK graft [11].

Database and statistical analyses

For linear regression analysis, we first performed a univariate analysis, followed by multivariate modeling introducing all the variables, in an exploratory fashion. The linearity assumption of the linear regression was checked using a plot of the fitted regression line compared with a locally weighted nonparametric scatterplot of the outcome variable against the predictor. Homoscedasticity was checked by graphing residuals versus predicted and observed values. Finally, normality of residuals was checked using boxplots, histograms, and quantile plots of residuals. Ordinal variables were also checked for linearity using a nested likelihood ratio test.

Some of our variables displayed heteroscedasticity, therefore, we repeated the analyses using both the Huber-White sandwich estimator of variance relaxing the homoscedasticity assumption and bootstrapped regressions with 1.000 repetitions. The results of these analyses were in agreement with the findings of our traditional regression results, which allowed us to take a relaxed stance toward the heteroscedastic findings in some of our models. Standard paired t-tests, chi-squared, and z-tests for proportions were also used. Significance was set at $\alpha < 0.05$. The Stata v10.1 (Stata Corp, Austin, TX) software was used in all analyses.

Ethics

The Data Protection Officials of the Rikshospitalet approved the study. All patients gave signed informed consent for entry of the data into the database and for the subsequent prospective study.

Results

Baseline clinical characteristics

Of the 390 patients eligible for inclusion in this study (total group), we obtained complete preoperative- and follow-up data for 258 patients (66.1%) (study group).

Table 1 Patient characteristics.

ACDF	Study group N = 258	Total group N = 390	p-value
Females - no of patients (%)	114 (44)	178 (46)	0.72 ^{prop}
Median age (range) - (years)	47.5 (28.3-82.8)	47.7 (26.9- 82.8)	0.73
Levels per procedure - no of patients (%)			
One level	152 (59)	240 (61)	0.50
Two levels	104 (40)	148 (38)	0.55
Three levels	2 (1)	2 (1)	0.68
0.75 ^{x2}			
Level - no of patients (%)			
C3/C4	7 (3)	7 (2)	0.43
C4/C5	38 (15)	56 (14)	0.90
C5/C6	182 (71)	266 (68)	0.53
C6/C7	137 (53)	207 (53)	0.99
C7/Th1	2 (1)	6 (2)	0.39
0.85 ^{x2}			
Method of fusion - no of patients (%)			
Autologous bone graft	181 (70)	278 (71)	0.76
PEEK* cage	77 (30)	112 (29)	0.76
0.76 ^{x2}			
Symptoms - no of patients (%)			
Radiculopathy	206 (80)	309 (79)	0.85
Radiculopathy and myelopathy	36 (14)	50 (13)	0.86
Myelopathy	9 (3)	18 (5)	0.48
No radiculopathy or myelopathy	7 (3)	13 (3)	0.66
Previous ACDF - no of patients (%)			
	11 (4)	18 (5)	0.83
Previous neck trauma - no of patients (%)			
	23 (9)	26 (7)	0.29

*Polyetheretherketone

The patient characteristics for both groups are included in Table 1. No significant differences were found between the groups with respect to baseline clinical characteristics. Only the 258 patients with complete data sets were included in the analyses.

Pain relief after surgery

We found a significant reduction in radicular pain, neck pain, and headache after surgery in the study group (Table 2). The reduction was most pronounced for

radicular pain and neck pain. Using univariate and multivariate analyses we found that high preoperative pain intensity was significantly associated with a decrease in pain intensity after surgery, for all three pain categories. There were no significant correlations between pain relief and the following patients characteristics: sex, age, number of levels fused, disc level fused, fusion method (AICG versus PEEK-cage), previous neck surgery (except for neck pain), previous neck trauma, or preoperative symptom duration (Table 3). As the clinical impact of

Table 2 Intensity of pain measured using the VAS scale before surgery (preop) and 6 months after surgery (postop).

Paired samples	N	Mean	Paired differences			Sig. (two-tailed)
			Mean	95% Confidence interval		
			Mean	Lower	Upper	
Preop radicular pain	258	7.47				
			3.05	2.65	3.45	0.000
Postop radicular pain	258	4.42				
Preop neck pain	255	6.45				
			2.30	1.90	2.71	0.000
Postop neck pain	255	4.15				
Preop headache	254	3.63				
			0.55	0.22	0.89	0.001
Postop headache	254	3.08				

(Paired sample t-test).

Table 3 Univariate and multivariate Cox regression model of potential predictors of outcome.

	Delta radicular pain		Delta neck pain		Delta headache	
	Univariate	Multivariate	Univariate	Multivariate	Univariate	Multivariate
Sex	0.25 [-0.56, 1.05]	0.031 [-0.73, 0.79]	0.40 [-0.41, 1.22]	0.18 [-0.49, 0.85]	0.34 [-0.34, 1.01]	0.15 [-0.45, 0.74]
Age	-0.035 [-0.08, 0.01]	0 .	0.0095 [-0.03, 0.05]	0 .	-0.000059 [-0.04, 0.04]	0 .
Type of fusion	0.0077 [-0.87, 0.88]	0.21 [-0.61, 1.04]	0.096 [-0.78, 0.98]	-0.069 [-0.79, 0.66]	-0.21 [-0.94, 0.52]	-0.040 [-0.69, 0.61]
No of levels	0.40 [-0.38, 1.19]	0.35 [-0.49, 1.18]	0.23 [-0.56, 1.02]	0.14 [-0.60, 0.87]	0.32 [-0.34, 0.98]	0.37 [-0.28, 1.03]
Level	0.088 [-0.46, 0.64]	0.055 [-0.53, 0.64]	0.35 [-0.20, 0.91]	0.068 [-0.45, 0.58]	0.019 [-0.44, 0.48]	-0.18 [-0.64, 0.28]
Previous symptom duration	-0.0019 [-0.01, 0.01]	-0.0016 [-0.01, 0.01]	0.0028 [-0.00, 0.01]	-0.00088 [-0.01, 0.01]	0.0018 [-0.00, 0.01]	-0.0014 [-0.01, 0.00]
Previous neck surgery	-0.62 [-2.59, 1.36]	-0.50 [-2.37, 1.36]	-1.75 [-3.73, 0.23]	-1.82* [-3.45, -0.18]	-1.31 [-3.03, 0.41]	-1.02 [-2.54, 0.51]
Previous neck trauma	0.24 [-1.17, 1.64]	-0.098 [-1.42, 1.23]	-0.58 [-1.99, 0.83]	-0.37 [-1.53, 0.79]	0.011 [-1.16, 1.18]	-0.53 [-1.56, 0.51]
Preop radicular pain	0.60*** [0.44, 0.76]	0.63*** [0.45, 0.81]	0.31*** [0.13, 0.48]	-0.030 [-0.19, 0.13]	0.065 [-0.08, 0.21]	-0.021 [-0.16, 0.12]
Preop neck pain	0.14 [-0.00, 0.28]	-0.075 [-0.23, 0.08]	0.66*** [0.54, 0.78]	0.75*** [0.62, 0.89]	0.16** [0.04, 0.28]	-0.035 [-0.16, 0.09]
Preop headache	0.078 [-0.07, 0.22]	0.041 [-0.11, 0.19]	0.087 [-0.06, 0.23]	-0.22** [-0.35, -0.09]	0.52*** [0.41, 0.62]	0.54*** [0.42, 0.66]
Observations	256		255		252	
Adjusted R^2	0.150		0.350		0.261	

95% confidence intervals are shown in brackets

$p < 0.05$, ** $p < 0.01$, *** $p < 0.00$

Outcome variables are the paired differences between preoperative and postoperative pain VAS scores (delta radicular pain, delta neck pain and delta headache).

changes in VAS scores less than ± 2 is unclear, we estimated the number of patients that had changes in VAS scores of more than ± 2 for the three pain categories (Table 4). Radicular pain improved ≥ 2 VAS points in 64% of the patients, while 6% of patients experienced a worsening of VAS score ≤ -2 . Neck pain improved ≥ 2 VAS points in 55% of the patients, while 10% of patients experienced a worsening of VAS score ≤ -2 . Headache improved ≥ 2 VAS points in 31% of the patients, while 16% of patients experienced a worsening of VAS score ≤ -2 .

Paresis

One hundred and fifty-one of the 249 (61%) patients had normal muscular strength at the time of surgery. At follow-up, 233/249 (94%) patients had normal muscular strength.

Myelopathy

Of the 45 patients with clinical evident myelopathy at the time of surgery, only 16 (35.6%) had persistent myelopathy 6 months after surgery.

Table 4 Number of patients with changes in VAS scores of more than ± 2 for the three pain categories, radicular pain, neck pain and headache, separately.

Pain category	Delta VAS = preoperative - postoperative		
	Worsened (≤ -2 VAS)	Unchanged	Improved (≥ 2 VAS)
Radicular pain	16 (6.2%)	78 (30.2%)	164 (63.6%)
Neck pain	26 (10.1%)	91 (35.3%)	141 (54.7%)
Headache	41 (15.9%)	136 (52.7%)	81 (31.4%)

Working status

At the onset of symptomatic CDD, 80% of patients were employed fulltime, 3% received workers' compensation for CDD, 4% received workers' compensation for reasons other than CDD, 8% received a disability pension, and 5% were students, housewives, retired, or unemployed. At the time of surgery, 66% of patients had received workers' compensation for 1 month or more. The median sick leave before surgery was 5.0 (0-150) months. Six months after surgery, 48% of patients had returned to work: however 24% were still receiving workers' compensation. The percentage of patients receiving a disability pension increased from 8%, before the onset of symptomatic CDD, to 21% 6 months postoperatively. The increase in the number of patients receiving a disability pension was, related to CDD in all cases but one.

Patient satisfaction

At the 6-month postoperative control, all patients were asked to score their satisfaction with the surgical result using a VAS scale. The mean reported VAS score was 8.42, and 200/256 (78%) patients reported a score > 8 (success). Only 27/256 (11%) patients reported a VAS score < 5 , which indicate that the operation did not fulfil their expectations (failure). Patient satisfaction was then correlated to other measures of surgical outcome at 6 months (Table 5). Patient satisfaction was significantly associated with pain relief after surgery.

Discussion

Symptom relief after ACDF

The effectiveness of ACDF in relieving radicular pain secondary to CDD is well documented in both long- and short-term follow-up studies [12,15,28-30]. However, the effectiveness of ACDF in relieving neck pain and headache secondary to CDD remains unclear. In this prospective study of 258 patients, we confirmed the beneficial effect of ACDF on radicular pain. The patients also reported a significant improvement in their neck pain and headache. The reduction in headache, although significant, was only by 0.55 points on the VAS scale, in contrast to the changes observed for radicular and neck pain (VAS score variation of 3.05 and 2.30, respectively). The clinical impact of changes in VAS scores < 2 is

Table 5 Patient satisfaction 6-months after surgery correlated with selected preoperative variables and other measures of surgical outcome at 6 months.

	Patient satisfaction
Sex	-0.19 [-0.85, 0.46]
Age	-0.031 [-0.07, 0.00]
Previous symptom duration	0.00014 [-0.01, 0.01]
Delta radiculopathy	0.33*** [0.24, 0.42]
Delta neck pain	0.22*** [0.12, 0.31]
Delta headache	0.20** [0.08, 0.31]
Observations	

(Linear univariate regression analysis).
 95% confidence intervals are shown in brackets
 * $p < 0.05$, ** $p < 0.01$, *** $p < 0.001$

unclear. An improvement in VAS score ≥ 2 was observed in 64%, 55%, and 31% of patients, for radicular pain, neck pain, and headache, respectively. Almost all patients in our series had radicular pain: therefore, our cohort cannot be used to answer the question concerning the effect of ACDF on neck pain or discogenic headache in patients with mild or no radicular pain. Schofferman et al. published a series of nine patients that allowed them to conclude that ACDF is an effective treatment for discogenic headache [31]. In a recent publication, Laimi et al. reported a low probability of association between headache and CDD [32]. We remain reluctant to offer ACDF to patients with dominating neck pain or headache who have little or no radicular pain.

Working status

The percentage of patients that returned to work within 6 months of surgery was lower than expected [28]. The

most likely explanations for this result are symptom persistence, passive approach with respect to motivating the patient to return to work, and that surgery in some patients was regarded as the last necessary step for the collection of a permanent disability pension. More effort is required to assist the return of patients to the workplace as early as possible. Bhandari et al. reported that 28% of their patient cohort had not returned to work one year after cervical discectomy [33]. These authors found that long preoperative sick leave and persistent postoperative neck pain were associated with not returning to work after surgery. Age and disability claims also influenced the rates of return to work. Steinmetz et al. have studied return to work in a cohort of patients who had workers compensation as their primary insurance. They found 42% return to work 6 months after ACDF and 55% return to work 6 months after cervical disc arthroplasty [34].

Patient satisfaction

Two hundred out of the 256 (78%) patients evaluated the surgical result as successful. Only 27/256 (11%) patients classified the surgical result as a failure. A 78% success rate after surgery for CDD must be regarded as acceptable. Patient satisfaction is often evaluated using the Odom Criteria [35]. This said, the VAS scale is an accepted tool to evaluate patient satisfaction [26].

Prognostic factors

In our series, we found a significant correlation between high preoperative pain intensity and decrease in pain intensity after surgery, for all three pain categories. We found no significant correlation between symptom reduction after ACDF and sex, age, number of levels fused, disc level fused, fusion method (AICG or PEEK), previous neck surgery (except for neck pain), previous neck trauma or preoperative symptom duration. The most likely explanation for the lack of identification of prognostic factors is that we selected the best candidates for surgery based on previous knowledge [4,5]. However we were surprised by the fact that symptom duration failed to influence the final surgery outcome, as many of our patients had a rather long preoperative symptom duration. This finding is in contrast with earlier reports on symptomatic CDD and herniated lumbar disc with sciatica [6,7]. An unfavorable postoperative outcome was reported in cases where symptom duration exceeded 6 months in patients treated for herniated lumbar disc and sciatica [6]. Our data suggest that a lengthy duration of symptoms does not influence outcomes.

Fusion with PEEK cage versus AICG

Anterior cervical decompression and fusion with autologous bone graft has been the standard treatment for

CDD for more than 50 years [9]. In recent years, many surgeons have replaced autologous bone grafting with an artificial cage and they report equivalent clinical outcomes after this shift in surgical procedure [12,14-17]. Our study confirmed the results of these previous studies. We found no significant differences between the type of fusion in relation to reduction of radicular pain, neck pain, or headache. We have reported the presence of similar complication rates for patients fused with a PEEK cage or with AICG, with the exception of the absence of donor site morbidity in patients fused with a PEEK cage [11]. The absence of donor site morbidity, the shorter operation time, and the equivalent clinical results associated with the use of PEEK cages lead us to prefer this type of fusion to AICG.

Optimal surgical procedure for CDD

There is no clear consensus regarding the optimal surgical procedure for CDD [2,36-38]. Which procedure provides the best clinical outcomes: anterior cervical discectomy alone (ACD), ACDF, discectomy with intervertebral fusion and instrumentation (ACDFI), or cervical arthroplasty? A recent prospective randomized study comparing ACD, ACDF and ACDFI in patients with CDD showed no significant differences in clinical outcomes at the 2 year follow up [37]. However, patients operated with ACD had a higher rate of segmental kyphosis than patients operated with ACDF or ACDFI. Some authors report lesser graft dislocations and graft collapse and higher fusion rates after ACDFI compared with ACDF [13,39,39-42]. On the other hand, the complication rate after ACDFI is somewhat higher compared with ACDF [12,13,41]. ACD, ACDF and ACDFI reduce segmental motion and cause heightened stress on the discs below and above the fusion, which in turn may induce adjacent-level degeneration [43-46]. The main arguments in favor of cervical arthroplasty are the preservation of segmental motion and a lower risk of adjacent-level disc degeneration. The results of randomized, controlled clinical trials comparing cervical disc arthroplasty with ACDF are now emerging [45,47-54]. The follow-up times in the arthroplasty studies are relatively short, however there is a tendency for slightly improved outcomes after cervical prosthesis compared with ACDF. Our routine procedure has so far been ACDF, (both single-level and two-level ACDF). Based on the current literature, we see no reason to change this strategy at this time, although we accept that ACD, ACDFI, and prosthesis probably provide similar clinical outcomes. If the long-term clinical outcome of cervical arthroplasty is demonstrated to be superior to ACDF, we will change our treatment strategy.

Limitations of the study

- The patients were not randomized to fusion with either AICG or PEEK-cage. The type of fusion was in each case decided by the surgeon. This may cause a bias in the material.
- Ideally the outcome after ACDF for CDD should have been compared with an equivalent group managed with conservative measures.
- The follow-up evaluation was done by the surgeons and not an independent investigator, this may have influenced the final result.

Conclusions

- ACDF is an effective treatment for radicular pain in selected patients with CDD (patients evaluated 6 months after surgery).
- Because of similar clinical outcome and lack of donor site morbidity when using PEEK, we now prefer fusion with PEEK-cage to AICG.
- Lengthy symptom duration was not a negative prognostic marker in our patient population.
- The number of patients who returned to work 6 months after surgery was lower than expected.

Author details

¹Department of Neurosurgery-Rikshospitalet, Oslo University Hospital, N-0027 Oslo, Norway. ²Department of Neurosurgery-Ullevål, Oslo University Hospital, N-0407 Oslo, Norway. ³Faculty of Medicine, University of Oslo, Oslo, Norway.

Authors' contributions

BL; llib@ullevål.no; Data collection, statistics, data analysis, discussion and writing. PAR; mpl@uus.no; Statistics, discussion and writing. JS; jarle.sundseth@rikshospitalet.no; Data collection and discussion. EH; heej@uus.no; Data collection, statistics, data analysis, discussion and writing. All authors have read and approved the final manuscript.

Competing interests

The authors did not receive financial support in conjunction with the generation of this article. The authors have no personal or institutional financial interest in drugs, materials, or devices described in this article.

Received: 20 May 2009 Accepted: 21 March 2010

Published: 21 March 2010

References

1. Radhakrishnan K, Litchy WJ, O'Fallon WM, Kurland LT: **Epidemiology of cervical radiculopathy. A population-based study from Rochester, Minnesota, 1976 through 1990.** *Brain* 1994, **117**(Pt 2):325-335.
2. Jacobs WC, Anderson PG, Limbeek J, Willems PC, Pavlov P: **Single or double-level anterior interbody fusion techniques for cervical degenerative disc disease.** *Cochrane Database Syst Rev* 2004, CD004958.
3. Patil PG, Turner DA, Pietrobon R: **National trends in surgical procedures for degenerative cervical spine disease: 1990-2000.** *Neurosurgery* 2005, **57**:753-758.
4. Peolsson A, Peolsson M: **Predictive factors for long-term outcome of anterior cervical decompression and fusion: a multivariate data analysis.** *Eur Spine J* 2008, **17**:406-414.
5. Anderson PA, Subach BR, Riew KD: **Predictors of outcome after anterior cervical discectomy and fusion: a multivariate analysis.** *Spine* 2009, **34**:161-166.
6. Nygaard OP, Romner B, Trumphy JH: **Duration of symptoms as a predictor of outcome after lumbar disc surgery.** *Acta Neurochir (Wien)* 1994, **128**:53-56.
7. Bertalanffy H, Eggert HR: **Clinical long-term results of anterior discectomy without fusion for treatment of cervical radiculopathy and myelopathy. A follow-up of 164 cases.** *Acta Neurochir (Wien)* 1988, **90**:127-135.
8. Cloward RB: **The anterior approach for removal of ruptured cervical discs.** *J Neurosurg* 1958, **15**:602-616.
9. Robinson RA, Smith GW: **Anterolateral cervical disc removal and interbody fusion for cervical disc syndrome.** *Bull Johns Hopkins Hospital* 1955, **96**:223-224.
10. Sonntag VK, Han PP, Vishteh AG: **Anterior cervical discectomy.** *Neurosurgery* 2001, **49**:909-912.
11. Lied B, Sundseth J, Helsest E: **Immediate (0-6 h), early (6-72 h) and late (>72 h) complications after anterior cervical discectomy with fusion for cervical disc degeneration; discharge six hours after operation is feasible.** *Acta Neurochir (Wien)* 2008, **150**:111-118.
12. Hacker RJ, Cauthen JC, Gilbert TJ, Griffith SL: **A prospective randomized multicenter clinical evaluation of an anterior cervical fusion cage.** *Spine* 2000, **25**:2646-2654.
13. Fountas KN, Kapsalaki EZ, Nikolakakos LG, Smisson HF, Johnston KW, Grigorian AA, et al: **Anterior cervical discectomy and fusion associated complications.** *Spine* 2007, **32**:2310-2317.
14. Cho DY, Liao WR, Lee WY, Liu JT, Chiu CL, Sheu PC: **Preliminary experience using a polyetheretherketone (PEEK) cage in the treatment of cervical disc disease.** *Neurosurgery* 2002, **51**:1343-1349.
15. Peolsson A: **Investigation of clinically important benefit of anterior cervical decompression and fusion.** *Eur Spine J* 2007, **16**:507-514.
16. Moreland DB, Asch HL, Clabeaux DE, Castiglia GJ, Czajka GA, Lewis PJ, et al: **Anterior cervical discectomy and fusion with implantable titanium cage: initial impressions, patient outcomes and comparison to fusion with allograft.** *Spine J* 2004, **4**:184-191.
17. Thome C, Krauss JK, Zevgaridis D: **A prospective clinical comparison of rectangular titanium cages and iliac crest autografts in anterior cervical discectomy and fusion.** *Neurosurg Rev* 2004, **27**:34-41.
18. Fernandez-Fairen M, Sala P, Dufuo M Jr, Ballester J, Murcia A, Merzthal L: **Anterior cervical fusion with tantalum implant: a prospective randomized controlled study.** *Spine (Phila Pa 1976)* 2008, **33**:465-472.
19. Garcia S, Lozano ML, Gatell JM, Soriano E, Ramon R, Sanmiguel JG: **Prophylaxis against infection. Single-dose cefonicid compared with multiple-dose cefamandole.** *J Bone Joint Surg Am* 1991, **73**:1044-1048.
20. Hill C, Flamant R, Mazas F, Evrard J: **Prophylactic cefazolin versus placebo in total hip replacement. Report of a multicentre double-blind randomised trial.** *Lancet* 1981, **1**:795-796.
21. Rubinstein E, Findler G, Amit P, Shaked I: **Perioperative prophylactic cephalosporin in spinal surgery. A double-blind placebo-controlled trial.** *J Bone Joint Surg Br* 1994, **76**:99-102.
22. Her Majesty's Stationary Office London: **Medical Research Council. Aida to examination of the peripheral nervous system. Memorandum no 45** 1981.
23. Huskisson EC: **Measurement of pain.** *J Rheumatol* 1982, **9**:768-769.
24. DeLoach LJ, Higgins MS, Caplan AB, Stiff JL: **The visual analog scale in the immediate postoperative period: intrasubject variability and correlation with a numeric scale.** *Anesth Analg* 1998, **86**:102-106.
25. Pool JJ, Ostelo RW, Hoving JL, Bouter LM, de Vet HC: **Minimal clinically important change of the Neck Disability Index and the Numerical Rating Scale for patients with neck pain.** *Spine (Phila Pa 1976)* 2007, **32**:3047-3051.
26. Brokelman RB, van Loon CJ, Rijnberg WJ: **Patient versus surgeon satisfaction after total hip arthroplasty.** *J Bone Joint Surg Br* 2003, **85**:495-498.
27. Dolan P, Sutton M: **Mapping visual analogue scale health state valuations onto standard gamble and time trade-off values.** *Soc Sci Med* 1997, **44**:1519-1530.
28. Goldberg EJ, Singh K, Van U, Garretson R, An HS: **Comparing outcomes of anterior cervical discectomy and fusion in workman's versus non-workman's compensation population.** *Spine J* 2002, **2**:408-414.
29. Gore DR, Sepic SB: **Anterior discectomy and fusion for painful cervical disc disease. A report of 50 patients with an average follow-up of 21 years.** *Spine* 1998, **23**:2047-2051.

30. Jagannathan J, Shaffrey CI, Oskouian RJ, Dumont AS, Herrold C, Sansur CA, *et al*: Radiographic and clinical outcomes following single-level anterior cervical discectomy and allograft fusion without plate placement or cervical collar. *J Neurosurg Spine* 2008, **8**:420-428.
31. Schofferman J, Garges K, Goldthwaite N, Koestler M, Libby E: Upper cervical anterior discectomy and fusion improves discogenic cervical headaches. *Spine* 2002, **27**:2240-2244.
32. Laimi K, Erkintalo M, Metsahonkala L, Vahlberg T, Mikkelsen M, Sonninen P, *et al*: Adolescent disc degeneration—no headache association. *Cephalalgia* 2007, **27**:14-21.
33. Bhandari M, Louw D, Reddy K: Predictors of return to work after anterior cervical discectomy. *J Spinal Disord* 1999, **12**:94-98.
34. Steinmetz MP, Patel R, Traynelis V, Resnick DK, Anderson PA: Cervical disc arthroplasty compared with fusion in a workers' compensation population. *Neurosurgery* 2008, **63**:741-747.
35. Odom GL, Finney W, Woodhall B: Cervical disk lesions. *J Am Med Assoc* 1958, **166**:23-28.
36. Samartzis D, Shen FH, Matthews DK, Yoon ST, Goldberg EJ, An HS: Comparison of allograft to autograft in multilevel anterior cervical discectomy and fusion with rigid plate fixation. *Spine J* 2003, **3**:451-459.
37. Xie JC, Hurlbert RJ: Discectomy versus discectomy with fusion versus discectomy with fusion and instrumentation: a prospective randomized study. *Neurosurgery* 2007, **61**:107-116.
38. Samartzis D, Shen FH, Lyon C, Phillips M, Goldberg EJ, An HS: Does rigid instrumentation increase the fusion rate in one-level anterior cervical discectomy and fusion? *Spine J* 2004, **4**:636-643.
39. Fraser JF, Hartl R: Anterior approaches to fusion of the cervical spine: a metaanalysis of fusion rates. *J Neurosurg Spine* 2007, **6**:298-303.
40. Wang JC, McDonough PW, Endow KK, Delamarter RB: Increased fusion rates with cervical plating for two-level anterior cervical discectomy and fusion. *Spine* 2000, **25**:41-45.
41. Cho DY, Lee WY, Sheu PC: Treatment of multilevel cervical fusion with cages. *Surg Neurol* 2004, **62**:378-85, discussion.
42. Zoega B, Karrholm J, Lind B: Plate fixation adds stability to two-level anterior fusion in the cervical spine: a randomized study using radiostereometry. *Eur Spine J* 1998, **7**:302-307.
43. Hillibrand AS, Carlson GD, Palumbo MA, Jones PK, Bohlman HH: Radiculopathy and myelopathy at segments adjacent to the site of a previous anterior cervical arthrodesis. *J Bone Joint Surg Am* 1999, **81**:519-528.
44. Ishihara H, Kanamori M, Kawaguchi Y, Nakamura H, Kimura T: Adjacent segment disease after anterior cervical interbody fusion. *Spine J* 2004, **4**:624-628.
45. Nabhan A, Steudel WJ, Nabhan A, Pape D, Ishak B: Segmental kinematics and adjacent level degeneration following disc replacement versus fusion: RCT with three years of follow-up. *J Long Term Eff Med Implants* 2007, **17**:229-236.
46. Seo M, Choi D: Adjacent segment disease after fusion for cervical spondylosis; myth or reality? *Br J Neurosurg* 2008, **22**:195-199.
47. Heller JG, Sasso RC, Papadopoulos SM, Anderson PA, Fessler RG, Hacker RJ, *et al*: Comparison of BRYAN cervical disc arthroplasty with anterior cervical decompression and fusion: clinical and radiographic results of a randomized, controlled, clinical trial. *Spine* 2009, **34**:101-107.
48. Kim SW, Limson MA, Kim SB, Arbatin JJ, Chang KY, Park MS, *et al*: Comparison of radiographic changes after ACDF versus Bryan disc arthroplasty in single and bi-level cases. *Eur Spine J* 2009, **18**:218-231.
49. Mummaneni PV, Burkus JK, Haid RW, Traynelis VC, Zdeblick TA: Clinical and radiographic analysis of cervical disc arthroplasty compared with allograft fusion: a randomized controlled clinical trial. *J Neurosurg Spine* 2007, **6**:198-209.
50. Nabhan A, Ahlhelm F, Pitzen T, Steudel WJ, Jung J, Shariat K, *et al*: Disc replacement using Pro-Disc C versus fusion: a prospective randomised and controlled radiographic and clinical study. *Eur Spine J* 2007, **16**:423-430.
51. Sasso RC, Smucker JD, Hacker RJ, Heller JG: Clinical outcomes of BRYAN cervical disc arthroplasty: a prospective, randomized, controlled, multicenter trial with 24-month follow-up. *J Spinal Disord Tech* 2007, **20**:481-491.
52. Sasso RC, Smucker JD, Hacker RJ, Heller JG: Artificial disc versus fusion: a prospective, randomized study with 2-year follow-up on 99 patients. *Spine* 2007, **32**:2933-2940.
53. Sasso RC, Best NM: Cervical kinematics after fusion and bryan disc arthroplasty. *J Spinal Disord Tech* 2008, **21**:19-22.
54. Sasso RC, Best NM, Metcalf NH, Anderson PA: Motion analysis of bryan cervical disc arthroplasty versus anterior discectomy and fusion: results from a prospective, randomized, multicenter, clinical trial. *J Spinal Disord Tech* 2008, **21**:393-399.

Pre-publication history

The pre-publication history for this paper can be accessed here: <http://www.biomedcentral.com/1471-2482/10/10/preview>

doi:10.1186/1471-2482-10-10

Cite this article as: Lied *et al*: Anterior cervical discectomy with fusion in patients with cervical disc degeneration: a prospective outcome study of 258 patients (181 fused with autologous bone graft and 77 fused with a PEEK cage). *BMC Surgery* 2010 **10**:10.

Submit your next manuscript to BioMed Central and take full advantage of:

- Convenient online submission
- Thorough peer review
- No space constraints or color figure charges
- Immediate publication on acceptance
- Inclusion in PubMed, CAS, Scopus and Google Scholar
- Research which is freely available for redistribution

Submit your manuscript at
www.biomedcentral.com/submit



