



<http://dx.doi.org/10.1016/j.jemermed.2013.03.029>

Ultrasound in Emergency Medicine

ANIMAL LABORATORY TRAINING IMPROVES LUNG ULTRASOUND PROFICIENCY AND SPEED

Nils Petter Oveland, MD,*† Hans Morten Lossius, MD, PHD,*‡ Rasmus Aagaard, MD,§|| Jim Connolly, MD,¶
 Erik Sloth, MD, PHD, DMSC,§# and Lars Knudsen, MD, PHD#

*Department of Research and Development, Norwegian Air Ambulance Foundation, Droebak, Norway, †Department of Anesthesiology and Intensive Care, Stavanger University Hospital, Stavanger, Norway, ‡Department of Surgical Sciences, University of Bergen, Bergen, Norway, §Faculty of Health Sciences, Institute of Clinical Medicine, Aarhus University, Aarhus, Denmark, ||Department of Anesthesiology, Regional Hospital of Randers, Randers, Denmark, ¶Emergency Department, Royal Victoria Infirmary, Newcastle upon Tyne, UK, and #Department of Anesthesiology and Intensive Care, Aarhus University Hospital, Aarhus, Denmark

Reprint Address: Nils Petter Oveland, MD, Department of Research and Development, Norwegian Air Ambulance Foundation, P.O. Box 94, 1441 Droebak, Norway

Abstract—Background: Although lung ultrasound (US) is accurate in diagnosing pneumothorax (PTX), the training requirements and methods necessary to perform US examinations must be defined. **Objective:** Our aim was to test whether animal laboratory training (ALT) improves the diagnostic competency and speed of PTX detection with US. **Methods:** Twenty medical students without lung US experience attended a 1-day course. Didactic, practical, and experimental lectures covered the basics of US physics, US machines, and lung US, followed by hands-on training to demonstrate the signs of normal lung sliding and PTX. Each student's diagnostic skill level was tested with three subsequent examinations (at day 1, day 2, and 6-month follow-up) using experimentally induced PTX in porcine models. The outcome measures were sensitivity and specificity for US detection of PTX, self-reported diagnostic confidence, and scan time. **Results:** The students improved their skills between the initial two examinations: sensitivity increased from 81.7% (range 69.1%–90.1%) to 100.0% (range 94.3%–100.0%) and specificity increased from 90.0% (range 82.0%–94.8%) to 98.9% (range 92.3%–100.0%); with no deterioration 6 months later. There was a significant learning curve in choosing the correct answers ($p = 0.018$), a 1-point increase in the self-reported diagnostic confidence (7.8–8.8 on a 10-point scale; $p < 0.05$), and a 1-min reduction in the mean scan time per lung ($p < 0.05$). **Conclusions:** Without previous experience and after

undergoing training in an animal laboratory, medical students improved their diagnostic proficiency and speed for PTX detection with US. Lung US is a basic technique that can be used by novices to accurately diagnose PTX. © 2013 Elsevier Inc.

Keywords—lung ultrasound; animal laboratory training; pneumothorax

INTRODUCTION

Lung ultrasonography (US) is an accurate, rapid, and repeatable bedside diagnostic test for detecting pneumothorax (PTX). A recent meta-analysis indicated that bedside lung US had higher sensitivity and similar specificity compared with supine chest x-ray study (1). In March 2012, the first international evidence-based recommendations suggested that lung US should be used in clinical settings when PTX is in the differential diagnoses (2). There are numerous possible advantages of lung US, including minimizing patient exposure to radiation, delaying or even avoiding transportation to the Radiology Department, and guiding potential life-saving therapies (i.e., pleural drainage or closer patient observation without chest tubes) (3). The potential

RECEIVED: 27 September 2012; FINAL SUBMISSION RECEIVED: 5 March 2013;
 ACCEPTED: 15 March 2013

disadvantage is that US accuracy in diagnosing PTX is highly dependent on operator skill and weak expert consensus is that lung US is a basic technique with a possible learning curve (1,2). Today, there is uncertainty about the optimal methods of lung US training and the number of examinations that are necessary to demonstrate competency (4). Teaching the complexities of lung US is difficult, particularly in time-critical, irreproducible, and unstable trauma-patient situations. Therefore, alternative training methods must be explored and tested. In surgical specialties, animal laboratories have successfully been used to teach surgical procedures under close supervision in a controlled environment, thereby enhancing attending residents' technical skills (5,6). We investigated whether animal laboratory training (ALT) produced similar outcomes for emergency diagnostic procedures. The aim of this study was to test whether medical students, without any prior scanning experience, could improve their diagnostic proficiencies and speeds for US detection of PTX after supervised training in an animal facility.

METHODS

The ALT program was conducted in the vivarium at the Institute of Clinical Medicine, Aarhus University Hospital, Skejby, Denmark. Qualified, experienced animal caretaker personnel monitored animal health during the study period. The experiments complied with the guidelines for animal experimental studies that are issued by the Danish Inspectorate for Animal Experimentation under the Danish Ministry of Justice, which approved the study; the study also adhered to the principles in the Guide for Care and Use of Laboratory Animals (7).

Recruitment of Participants

First-year to graduate-year medical students ($n = 20$) at Aarhus University were recruited for the initial ALT program and two examinations on eight porcine models. Student demographics (i.e., age, sex, and years of medical training) and previous US experience were recorded. Each student signed a consent form with a statement of confidentiality, which was intended to inform them of their rights, obligations, and a promise of secrecy not to collaborate or reveal their own results to their fellow students. At the 6-month follow-up examination, only 11 of the initial 20 participants were able to attend due to conflicting time schedules with lectures at the University. The dropout was random (i.e., not controlled by the project manager) and based on the students' availability. The follow-up examination included only one pig because of a limited time slot of 2 h at the laboratory facility to complete the studies.

Table 1. Learning Objectives for Lung Ultrasound Education

<p>1. Basic US physics Piezoelectric crystals to generate US images The US wave (frequency, length and speed) Wave reflection and absorption Wave frequency vs. depth trade-off US transmission in different tissues/medium Artifacts</p>	<p>3. Normal lung US Basic chest wall and lung anatomy Identification of the pleural line Lung sliding in B-mode Lung sliding in M-mode B-lines (reverberation artifacts) Diaphragm (right and left side)</p>
<p>2. US machines (knobology) Power on/off Changing probes Ergonomics Probe orientation (left/right/up/down/rotation/tilt) Depth Gain Focus Freeze Save Brightness mode (B-mode) Motion mode (M-mode)</p>	<p>4. Pneumothorax No lung sliding in B-mode No lung sliding in M-mode No B-lines (reverberation artifacts) The lung point in B- and M-mode</p>

US = ultrasound.

Competency-based checklist: The students had to demonstrate competency in each step (one to four) before being allowed to continue their training. The terms used are described in detail in Figure 1.

Faculty

The faculty included anesthesiologists ($n = 4$) and an Emergency Physician ($n = 1$). Faculty members contributed with lectures and supervised hands-on training sessions and student examinations.

Animal Model

Eleven Danish female landrace pigs (mean \pm standard deviation body weight 56.1 ± 1.8 kg) were used in this animal study. The porcine PTX model for teaching US diagnostics has been described in detail previously (8). Briefly, the pigs were anesthetized, intubated, and fixated in the supine position on the operating table. A small thoracotomy was performed at the crossing of the fifth to seventh intercostal and at the anterior axillary line; a three-way stopcock catheter (BD Connecta, BD Medical, Franklin Lakes, NJ) was inserted into the pleural space. To obliterate normal lung sliding between the pleural layers, approximately 200 mL of air ($4-5$ mL/kg) was insufflated. The faculty then verified the presence of intrapleural air using US and monitored the PTX between

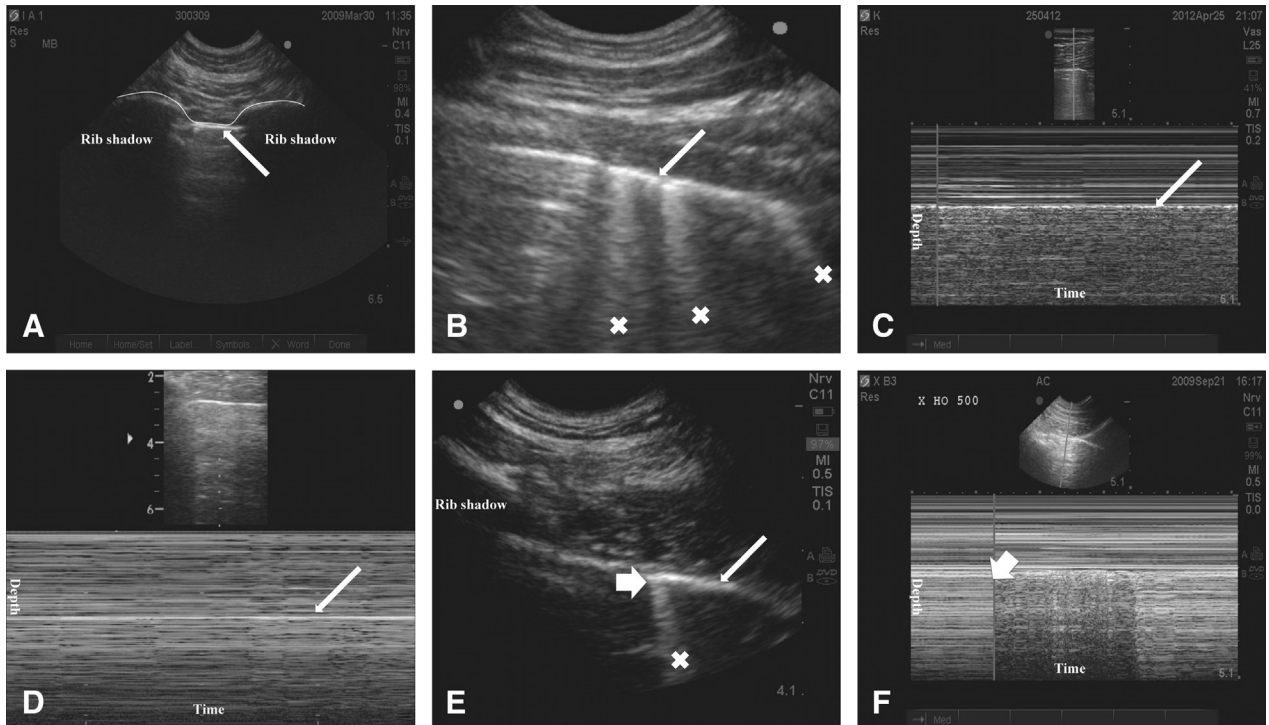


Figure 1. Algorithm to diagnose a pneumothorax (PTX). Throughout the figure, thin arrows point at the pleural line and X marks artifacts extending from the pleural line to the bottom of the screen, called B-lines. Thick arrows indicate the lung points. (A) The bat sign: On a longitudinal scan at the anterior chest, two ribs with the pleural line in-between are identified (this image resembles a bat, as shown by the thin white line). (B) Detection of lung sliding or B-lines: This image is obtained by rotating the probe approximately 90 degrees to align in the intercostal space and then gradually moved toward the lateral-posterior parts of the chest. The aim is to detect the presence or absence of horizontal movements of the pleural layers, called lung sliding (visible only on video clips) or B-lines. Lung sliding or B-lines rule out PTX, and both signs are absent if the pleural layers are separated by air. (C) Seashore sign: Time motion-mode from image B. When lung sliding is present, the image has a granular appearance under the pleural line (resembling sand) and horizontal lines above the pleural line (resembling the horizon). (D) Stratosphere sign: Abolished lung sliding can also be visualized in time motion-mode. Notice here the straight horizontal lines throughout the image in contrast to image (C). (E) Lung point: The boarder between the intrapleural air and the part of the lung still in contact with the interior chest wall is called the lung point (thick arrow). It appears on the screen as two distinct sonographic patterns that interchange synchronous with respiration (visible only on video clips). Identification of the lung point is 100% specific for PTX. (F) Lung point in time motion-mode: The interface between the seashore and stratosphere pattern is the lung point (thick arrow).

examinations. On a few occasions, it was necessary to insufflate 50 mL of air to keep the PTX at its original size. At the opposite side of each animal's chest, a sham operation was performed using an identical catheter placed subcutaneously without entering the pleural cavity. At the conclusion of data collection, each animal was euthanized with an injection of pentobarbital.

Training Program

The 8-h educational program consisted of didactic, practical, and experimental sessions. Phase one (2 h) comprised lectures covering basic US physics, knobology of the US apparatus, and normal lung US signs. In phase two (2 h), the lungs of healthy volunteers were scanned. Phase three (4 h) consisted of scanning experimentally induced PTXs in two porcine models. During this session, the faculty emphasized the difference between normal and pathognomonic lung US signs. The faculty followed

a competency-based procedure using learning objective checklists to ensure that each student demonstrated an acceptable skill level before being allowed to enter the next educational step (Table 1).

Lung US

The students performed all US scans using M-Turbo machines (Sonosite Inc, Bothell, WA) with one of two multifrequency (13-6 MHz or 15-6 MHz) linear array transducers (Sonosite Inc), and they followed a standardized lung scanning technique, which is illustrated in Figure 1.

Examination

The participants were given written multiple-choice questions (n = 34) covering US physics (n = 10), recognition of US pictures (n = 17), and video clips (n = 7). Two

Table 2. Baseline Characteristics of the Medical Students

	Examinations One and Two	6-Month Follow-Up Examination
Age (years), mean \pm SD	23.1 \pm 2.7	22.3 \pm 2.5
Male, n (%)	7/20 (35.0)	4/11 (36.4)
Female, n (%)	13/20 (65.0)	7/11 (63.6)
No. of completed semesters,* mean \pm SD	4.8 \pm 3.2	5.1 \pm 3.2
Previously observed US examinations, n (%)	3/20 (15.0)	NA
Previously performed US examinations, n (%)	3/20 (15.0)	NA
Lung US experience in detecting PTX, n (%)	0/20 (0.0)	NA
Use of lung US since the ALT program, n (%)	NA	1/11 (9.1)

ALT = animal laboratory training; NA = not applicable; PTX = pneumothorax; SD = standard deviation; US = ultrasound.

* Out of 12 possible semesters at the medical school.

scanning examinations followed the ALT program, and the 6-month follow-up examination ended the study.

First examination. PTXs were introduced in three of eight lungs (right side, $n = 2$ and left side, $n = 1$); one pig had two normal lungs, and none had bilateral PTX. Coded envelopes were randomly drawn to determine which side received the PTX (right vs. left). The students were instructed to randomly scan the eight lungs; the random order was determined by choosing a numbered card (one to eight) that corresponded to each lung. The participants did not know whether to expect that each pig would have unilateral or bilateral PTX, or two normal lungs. After each lung scan, the students were asked to diagnose the lung as normal or PTX and to score their confidence level about the diagnosis on a scale from 1 (not sure at all) to 10 (absolutely sure). The scanning time was measured from skin contact (of the probe) to the final diagnosis given by the participant. Faculty members were present at the examination, however, they did not provide instructions.

Faculty feedback and second examination. Before the second examination, the faculty provided 10-min summary lectures to each student, emphasizing the impor-

tance of using the lung US scanning algorithm systematically. In the second examination, PTXs were introduced in four of the eight lungs (right side, $n = 3$ and left side, $n = 1$), and none of the pigs had bilateral PTX; otherwise, this examination was identical to the first examination.

6-Month follow-up examination. At the 6-month follow-up examination, a final survey was given to the medical students to determine the number of lung US scans they had performed clinically since the ALT program. The examination was identical to the previous two examinations, except that one pig was prepared with one normal lung (left side) and one PTX (right side). The students did not receive any training before the final testing.

Data Analysis

Student performance was assessed through theoretical multiple-choice questions and hands-on practical examinations. The confidence level, scan time, and multiple-choice scores were presented as mean \pm standard deviation. The diagnostic skills in detecting PTX using lung US were analyzed using 2×2 frequency tables, and sensitivity, specificity, and 95% confidence intervals were calculated (9). Because not all participants completed the 6-month follow-up examination, a subanalysis was done to visualize possible differences in diagnostic skills in the follow-up group of 11 participants and the nine participants' dropout group. The diagnostic accuracy (i.e., the percentage of all correct answers) after the initial examinations (day 1 and day 2) was therefore calculated for the two groups separately. In addition, a generalized estimating equation analysis with an unstructured correlation structure tested the dependency of the number of correct student answers (PTX yes/no) on the timeline (i.e., first examination, day 1 \rightarrow second examination, day 2 \rightarrow final examination, 6 months) to illustrate the learning curves. Similar timeline assays were performed for the confidence level and scan time, and $p < 0.05$ was regarded as significant. All of the statistical calculations were performed using SPSS V.18.0 (IBM SPSS, Armonk, NY) and VassarStats (<http://vassarstats.net>; Vassar College, Poughkeepsie, NY).

Table 3. Sensitivity and Specificity of Pneumothorax Detection with Ultrasound

Examination	TP	FP	TN	FN	n*	Sensitivity (%)	95% CI	Specificity (%)	95% CI
Day 1	49	10	90	11	160	81.7	69.1–90.1	90.0	82.0–94.8
Day 2	80	1	79	0	160	100.0	94.3–100.0	98.9	92.3–100.0
6 months	11	0	11	0	22	100.0	81.5–100.0	100.0	81.5–100.0

CI = confidence interval; FN = false negative; FP = false positive; TN = true negative; TP = true positive.

* Number of lung ultrasound examinations.

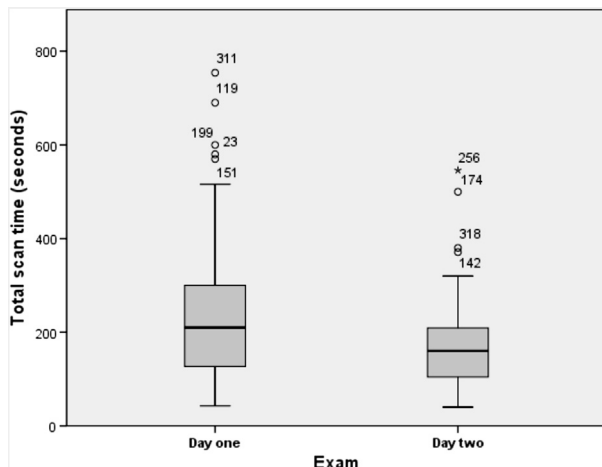


Figure 2. Box plot of the scan time (seconds) per lung on examination days 1 and 2. The box indicates the interquartile range, the horizontal line in the box, the median; and the “whiskers” of the box are outer boundaries called Tukey’s hinges. The points above the boxes are outliers marked by numbers that indicate the corresponding measurement.

RESULTS

Participants

Twenty medical students completed the laboratory training and the two subsequent examinations; depending on availability, 11 of the 20 students attended the 6-month follow-up examination. Table 2 shows the students’ demographics, including their baseline characteristics and previous US training.

Written Test Scores

The mean test scores for the multiple-choice questions were 31.0 ± 2.7 of 34 points (91.1% correct). The scores for the US physics questions, the picture test, and the video-clip test were 8.4 ± 1.4 (of 10), 16.0 ± 1.3 (of 17), and 6.6 ± 0.5 (of 7), respectively.

Sensitivity and Specificity for PTX Detection

In the first examination, 160 US examinations were performed and 139 lungs (86.9%) were correctly diagnosed, resulting in 10 false positives and 11 false negatives. The medical students detected 90 of 100 normal lungs and 49 of the 60 PTXs, for a sensitivity score of 81.7% and a specificity score of 90.0%; the 95% confidence intervals were (69.1–90.1) and (82.0–94.8), respectively. In the second examination, 159 of 160 (99.4%) diagnostic answers were correct, with one false positive. The sensitivity was 100.0% and specificity was 98.9%; the 95% confidence intervals were (94.3–100.0) and (92.3–100.0), re-

spectively. The subanalysis of diagnostic accuracy in the 6-month follow-up group ($n = 11$) and dropout group ($n = 9$) was 94.3% and 91.6%, with 95% confidence intervals of (90.0–98.7) and (85.9–97.4), respectively.

In the 6 months between the laboratory training and the follow-up examination, one student had performed lung US for approximately 1 h on a fellow student (Table 2). The participants that did return for testing interpreted all the 22 US examinations correctly (i.e., 11 normal lungs and 11 PTXs), resulting in 100.0% sensitivity and specificity scores and confidence interval of (81.5–100.0).

The medical students had no deterioration in sensitivity and specificity between the three examinations when the dependency of the correct answers was tested on the timeline (first examination day 1 → second examination day 2 → final examination 6 months), with $p = 0.018$. The diagnostic scores for the three time periods are summarized in Table 3.

Confidence Level

Mean confidence levels (using a 1 to 10 scale) were 7.8 ± 1.9 , 8.8 ± 1.6 , and 9.0 ± 1.3 for the three examinations. The increase in self-reported confidence from the first to the final examination (i.e., 6-month time span) was significant ($p = 0.006$).

Scan Time

Mean scan time per lung was 230 ± 134 s and 168 ± 82 s at the first and second examinations, respectively, and it increased 6 months later to 222 ± 80 s. Examination times decreased significantly between the initial examinations (i.e., a 1-min drop; $p < 0.05$), resulting in scan times of <3 min per lung (illustrated by the box-plot in Figure 2).

DISCUSSION

Our study shows that ALT significantly improved the diagnostic proficiency and speed for PTX detection with US in a group of medical students who had no prior scanning experience of the lungs. Animal laboratories provide a realistic simulation environment in which students are able to repeatedly perform diagnostic procedures on living tissue. This experience is particularly important for lung US because PTX diagnosis relies on dynamic signs that occur at the pleural line simultaneously with respiration (Figure 1). Many emergency US educational programs have focused on the number of examinations required for skill acquisition. In our training, however, we adopted a non-numerical model that focuses on a competency-based checklist evaluation of each student (10,11). This model yielded a written test score of 9 (of

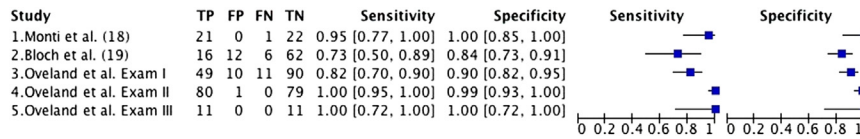


Figure 3. Forest plot comparing the sensitivity and specificity of lung ultrasound detection of pneumothorax in studies using porcine models. FN = false negative; FP = false positive; TN = true negative; TP = true positive.

10) correct answers, improved the students' diagnostic capabilities and technical skills, and increased their diagnostic self-confidence. In addition, we provide the first evidence that students who receive ALT sustain improvement in their diagnostic competency, shown by the lack of deterioration in sensitivity and specificity between the assessments. The reduction in the mean scan time per lung is also suggestive of a learning outcome among the students.

One method for learning lung US is to scan trauma patients, however, other ways might be necessary to obtain an acceptable skill level before use in real clinical settings. Cadavers have been used for training purposes because they are ideal anatomical models, although the realism of the US scans is low, particularly because of the lack of heartbeats and normal respiration. At best, a cadaver model that is randomized for tracheal or esophageal intubation could be used to study the presence or absence of the lung sliding sign (12). The same result can be achieved with a simpler experimental model that uses two intravenous pressure bags submerged in water (13). Brief training modules that use instructional videotapes improve PTX image recognition, however, technical skills are not developed without hands-on training (14,15). Scanning healthy volunteers combined with a theoretical understanding of image interpretation enhances the standard for lung US detection of PTX (16,17). However, anesthetized pigs are vastly different from these other educational models because the participants are diagnosing an actual PTX in a breathing animal. Other studies using experimentally induced PTXs in porcine models have reported deviant results ranging in sensitivity from 73% to 95%, with specificity ranges from 84% to 100%. The participants in these studies received short 10 to 60-min introductory lectures before performing lung US examinations (i.e., 44 and 96 in total) (18,19). In addition, their laboratory training focused on the lung sliding and B-lines, only allowing PTX to be safely ruled out (20,21). In contrast, our 8-h ALT program emphasized the importance of the lung point, a pathognomonic US sign for PTX when found (22). The combination of competency-based checklist evaluations for each student and a much larger number of practice examinations (i.e., 342 in total) could explain the higher sensitivity and specificity for US detection of

PTX that was found in our study. A forest plot compares our results with the other porcine PTX model trials (Figure 3).

The time, venue, and cost required to provide ALT is considerable and, when combined with ethical considerations, alternatives to using animals for medical training should always be sought. In medical simulations, plastic mannequins are used as pathological models to facilitate the training of both diagnostic and treatment algorithms (23–25). These models will always lack certain physical properties of living tissue, including hemorrhage, a beating heart, and breathing lungs. These shortcomings are diminished by the introduction of computer-based simulation, a promising technology that has enormous educational potential for teaching procedures. Still, Medline and Embase literature searches (terms: *pneumothorax* AND *ultrasound* AND [*simulators* OR *mannequins*]) returned no results of studies using computer-operated mannequins for lung US skill training.

Limitations

The porcine anatomy is not identical to that of humans, however, their respiratory and cardiovascular systems are similar (26,27). When validated against computed tomography, our porcine PTX model had the same distribution of intrapleural air that can be expected in supine trauma patients (8). However, we do recognize some limitations. The apex of the chest is cone shaped and unsuitable for US scanning. Therefore, the students were asked to scan the anterior and lateral aspects of each lung and avoid the apex. In addition, only 11 of the original group of 20 medical students could attend the last examination 6 months after the training. This leaves the possibility that the returning participants could have had better diagnostic skills after the initial training and examinations, but the subanalysis only showed a very small difference of 2.7 percentage points (i.e., 94.3% minus 91.6%) in diagnostic accuracy between the two groups (i.e. follow-up and dropout). Still, the 100% diagnostic accuracy found on the 6-month follow-up examination might be lower in a more comprehensive study, where more US examinations are performed on more than one pig.

CONCLUSIONS

This study provides evidence that novices can learn how to diagnose PTX using lung US. Training in an animal facility imparts a high level of long-term diagnostic proficiency and speed for diagnosing PTX. Additional research should reveal the best hands-on educational model for developing US skills, whether this should involve performing a set number of examinations, a competence-based curriculum, or some combination of the two.

Acknowledgments—The authors acknowledge the Faculty of Health Sciences, Institute of Clinical Medicine, Aarhus University, Denmark, for providing the laboratory facilities. The M-Turbo ultrasound machines (Sonosite Inc, Bothell, WA) were provided by Vingmed AS, Hovik, Norway. Geir Egil Eide, Professor at the Western Norway Regional Health Authority, helped with the statistical computation. Christian Alcaraz Frederiksen was part of the faculty and assisted the ultrasound training and examinations. Finally, we thank the medical students from Aarhus University for their eagerness to learn ultrasound and all members of the Norwegian Air Ambulance Foundation for the financial support that made this research possible.

REFERENCES

- Ding W, Shen Y, Yang J, He X, Zhang M. Diagnosis of pneumothorax by radiography and ultrasonography: a meta-analysis. *Chest* 2011;140:859–66.
- Volpicelli G, Elbarbary M, Blaivas M, et al. International evidence-based recommendations for point-of-care lung ultrasound. *Intensive Care Med* 2012;38:577–91.
- Zhang M, Liu ZH, Yang JX, et al. Rapid detection of pneumothorax by ultrasonography in patients with multiple trauma. *Crit Care* 2006;10:R112.
- Wilkerson RG, Stone MB. Sensitivity of bedside ultrasound and supine anteroposterior chest radiographs for the identification of pneumothorax after blunt trauma. *Acad Emerg Med* 2010;17:11–7.
- Custalow CB, Williams-Murphy M. Animal laboratories for procedural education of emergency medicine residents. *J Emerg Med* 2004;26:361–8.
- Custalow CB, Kline JA, Marx JA, Baylor MR. Emergency department resuscitative procedures: animal laboratory training improves procedural competency and speed. *Acad Emerg Med* 2002;9:575–86.
- Committee for the Update of the Guide for the Care and Use of Laboratory Animals; National Research Council. *Guide for the care and use of laboratory animals*. 8th ed. Washington, DC: The National Academies Press; 2010.
- Oveland NP, Sloth E, Andersen G, Lossius HM. A porcine pneumothorax model for teaching ultrasound diagnostics. *Acad Emerg Med* 2012;19:586–92.
- Newcombe RG. Two-sided confidence intervals for the single proportion: comparison of seven methods. *Stat Med* 1998;17:857–72.
- European Federation of Societies for Ultrasound in Medicine and Biology. Minimum training requirements for the practice of medical ultrasound in Europe. *Eur J Ultrasound* 2009;30:90–1.
- American College of Emergency Physicians. Emergency ultrasound guidelines. *Ann Emerg Med* 2009;53:550–70.
- Lyon M, Walton P, Bhalla V, Shiver SA. Ultrasound detection of the sliding lung sign by prehospital critical care providers. *Am J Emerg Med* 2012;30:485–8.
- Lyon M, Shiver SA, Walton P. M-mode ultrasound for the detection of pneumothorax during helicopter transport. *Am J Emerg Med* 2012;30:1577–80.
- Noble VE, Lamhaut L, Capp R, et al. Evaluation of a thoracic ultrasound training module for the detection of pneumothorax and pulmonary edema by prehospital physician care providers. *BMC Med Educ* 2009;9:3.
- Raio CC. Can emergency medical services personnel identify pneumothorax on focused ultrasound examinations? *Crit Ultrasound J* 2009;1:65–8.
- Brooke M, Walton J, Scutt D, Connolly J, Jarman B. Acquisition and interpretation of focused diagnostic ultrasound images by ultrasound-naïve advanced paramedics: trialling a PHUS education programme. *Emerg Med J* 2012;29:322–6.
- Chin EJ, Chan CH, Mortazavi R, et al. A pilot study examining the viability of a prehospital assessment with ultrasound for emergencies (pause) protocol. *J Emerg Med* 2013;44:142–9.
- Monti JD, Younggren B, Blankenship R. Ultrasound detection of pneumothorax with minimally trained sonographers: a preliminary study. *J Spec Oper Med* 2009;9:43–6.
- Bloch AJ, Bloch SA, Secreti L, Prasad NH. A porcine training model for ultrasound diagnosis of pneumothoraces. *J Emerg Med* 2011;41:176–81.
- Lichtenstein DA, Menu Y. A bedside ultrasound sign ruling out pneumothorax in the critically ill. Lung sliding. *Chest* 1995;108:1345–8.
- Lichtenstein D, Meziere G, Biderman P, Gepner A. The comet-tail artifact: an ultrasound sign ruling out pneumothorax. *Intensive Care Med* 1999;25:383–8.
- Lichtenstein D, Meziere G, Biderman P, Gepner A. The “lung point”: an ultrasound sign specific to pneumothorax. *Intensive Care Med* 2000;26:1434–40.
- Cae vimedix ultrasound simulator. Available at: <http://www.Cae.Com/en/healthcare/imaging/Solutions/Vimedix.Echo.Simulator.Asp>. Accessed June 16, 2012.
- Schallware ultrasound simulator. Available at: <http://www.Schallware.De/>. Accessed June 16, 2012.
- Simulab Corporation. eFAST module for SonoMan system. Available at: <http://www.simulab.com/product/ultrasound-trainers/efast-module-sonoman-system>. Accessed June 16, 2012.
- Swindle MM, Smith AC, Hepburn BJ. Swine as models in experimental surgery. *J Invest Surg* 1988;1:65–79.
- Rogers CS, Abraham WM, Brogden KA, et al. The porcine lung as a potential model for cystic fibrosis. *Am J Physiol Lung Cell Mol Physiol* 2008;295:L240–63.

ARTICLE SUMMARY

1. Why is this topic important?

Pneumothorax is common after significant blunt chest trauma and failure to diagnose and treat this condition can cause patient death. Lung ultrasound detects nearly all pneumothoraxes and the training requirements and methods necessary to perform these examinations must be defined.

2. What does this study attempt to show?

We test whether animal laboratory training is associated with sustained improvement in the diagnostic competency and speed of pneumothorax detection with ultrasound.

3. What are the key findings?

Animal laboratory training imparts a high level of long-term diagnostic proficiency for ultrasound detection of pneumothorax. The students' scan time per lung decreased by >1 min after the training.

4. How is patient care impacted?

Adding lung ultrasound to the physicians' armamentarium could improve the diagnostic accuracy for detection of pneumothorax and result in more prompt and correct patient care.