



University of HUDDERSFIELD

University of Huddersfield Repository

Rogers, Melanie and Fawcett, E.

Taking a cervical smear

Original Citation

Rogers, Melanie and Fawcett, E. (2015) Taking a cervical smear. ClinicalSkills.net.

This version is available at <http://eprints.hud.ac.uk/26313/>

The University Repository is a digital collection of the research output of the University, available on Open Access. Copyright and Moral Rights for the items on this site are retained by the individual author and/or other copyright owners. Users may access full items free of charge; copies of full text items generally can be reproduced, displayed or performed and given to third parties in any format or medium for personal research or study, educational or not-for-profit purposes without prior permission or charge, provided:

- The authors, title and full bibliographic details is credited in any copy;
- A hyperlink and/or URL is included for the original metadata page; and
- The content is not changed in any way.

For more information, including our policy and submission procedure, please contact the Repository Team at: E.mailbox@hud.ac.uk.

<http://eprints.hud.ac.uk/>

Taking a cervical smear Page 2

Take the patient's history



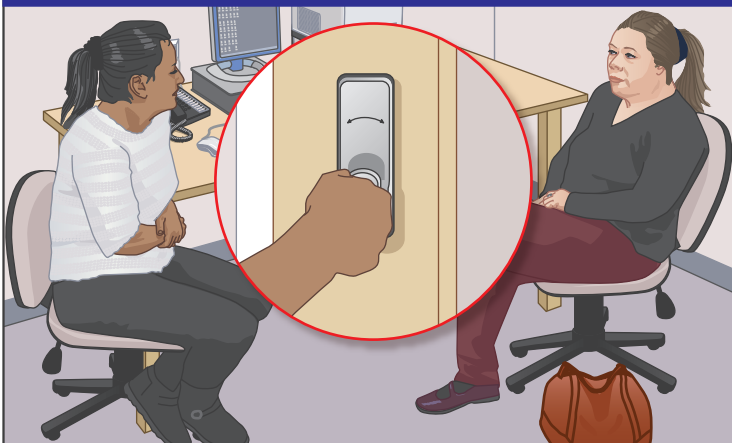Ensure that you put your patient at her ease, as attending for a smear may be an anxious time for women. Introduce yourself and explain the procedure, then take her history. Ask the patient: When was your last period? When was your last cervical screening test? What were the results? Has she ever had any abnormal results? Is she pregnant or trying to conceive? (If she is pregnant, do not perform the smear test.) Is she using any contraceptive? Has she had any unusual discharge? Does she experience any pain during intercourse? Does she have any abnormal bleeding between periods or after/during sexual intercourse?

Offer the patient the opportunity to go to the toilet



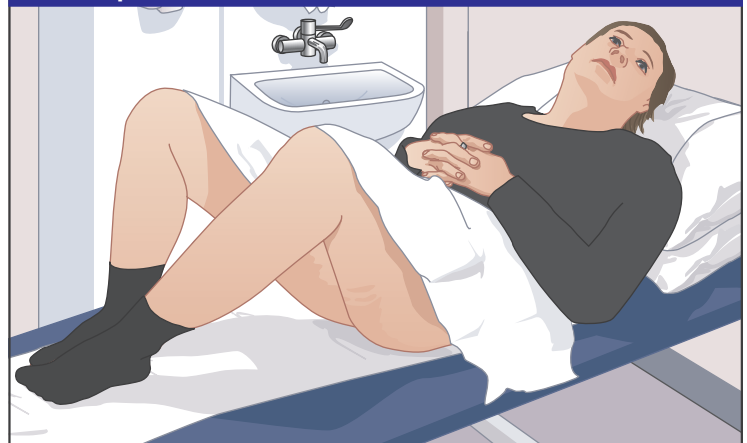If the patient has a full bladder, then taking a cervical sample can be more uncomfortable for her. You should therefore ask her if she would like to go to the toilet.

Offer the patient a chaperone



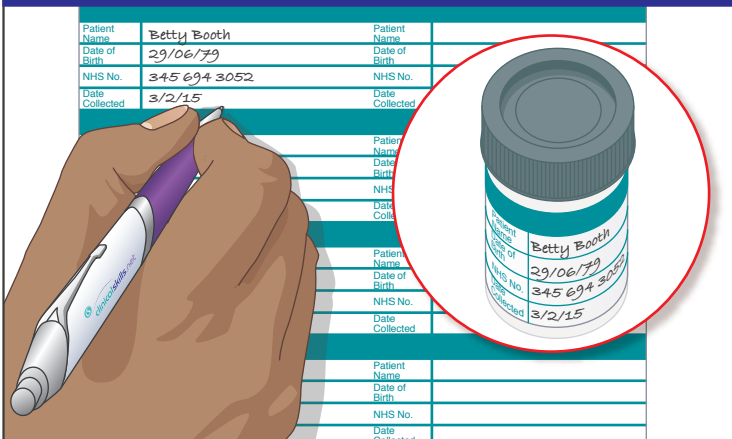
Ask the patient if she would like a chaperone. If she confirms that she is comfortable being alone in the room with you, ask her if she is happy for you to lock the door.

Patient position



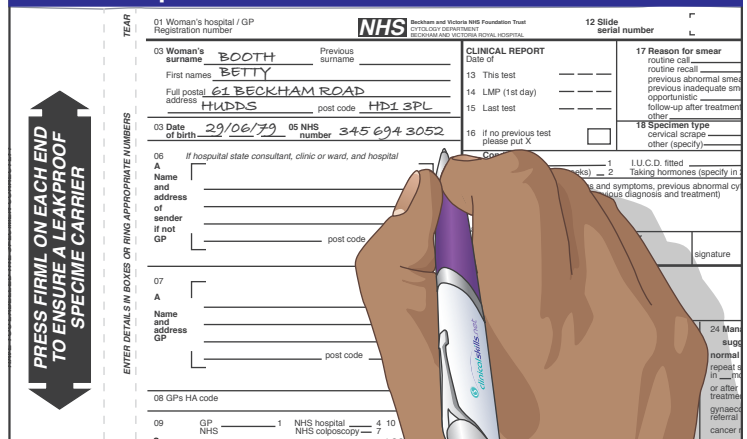
If available, draw the curtain to screen the patient as she undresses. Ask the patient to disrobe from the waist down. Offer the patient a disposable paper towel to protect modesty.

Label the bottle



While the patient is undressing, prepare the labels and equipment. Fill in the label and apply it to the bottle.

Fill in the specimen form

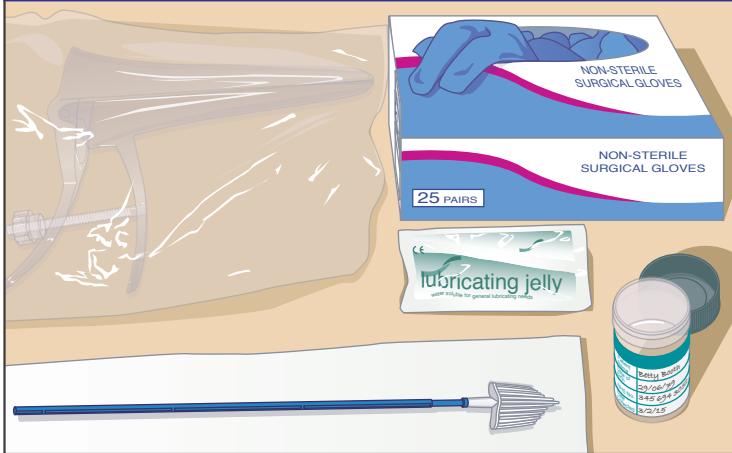

Prepare the appropriate specimen form (you may be able to download it and print it) and fill in the patient's details.

Do not undertake or attempt any procedure unless you are, or have supervision from, a properly trained, experienced and competent person. Always first explain the procedure to the patient and obtain his/her consent, in line with the policies of your employer or educational institution

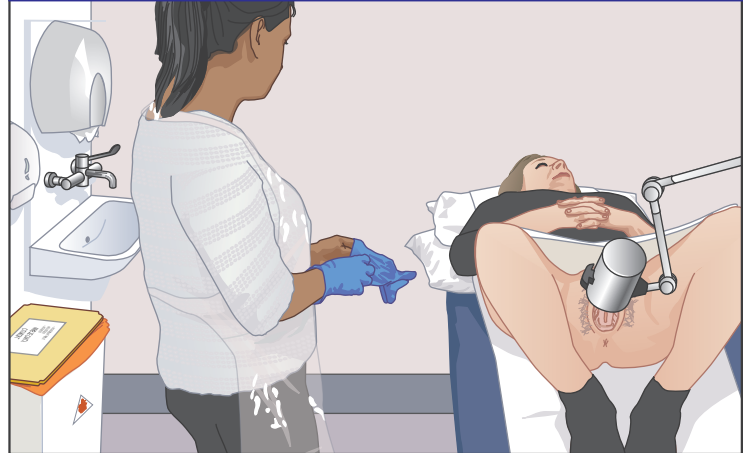
Taking a cervical smear Page 3

Prepare equipment



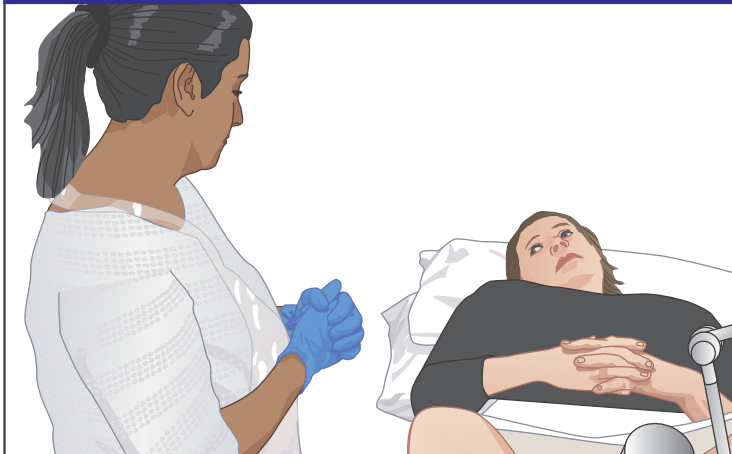Clean a trolley or other surface (such as a tray) according to local policy. Lay out the equipment using a non-touch technique. Unwrap the equipment. Remove the lid from the specimen container, ready to receive the brush head. Lay the brush head on a clean surface such as the inside of the speculum wrapper (once you have unwrapped this) or a paper towel.

Wash your hands



Wash your hands and put on an apron and gloves. Raise the bed to a suitable height.

Reassure the patient



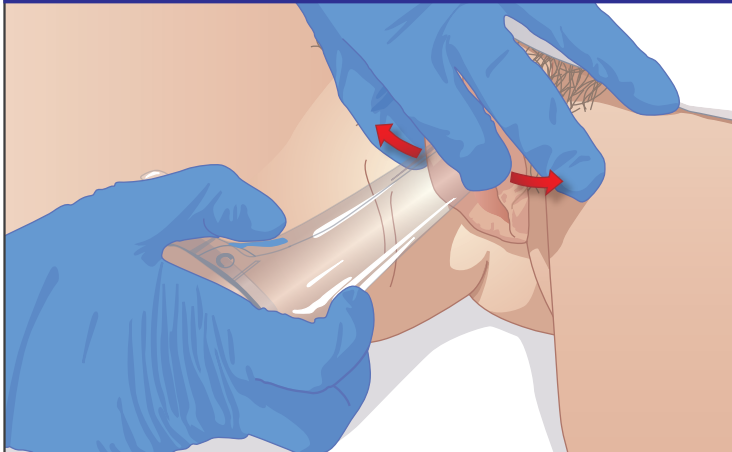Explain to the patient that she is in charge of the procedure and that she can ask you to stop at any time. (If she is in discomfort, you can pause to allow her to relax down onto the speculum, or alternatively, you can stop altogether.)

Preparing the speculum



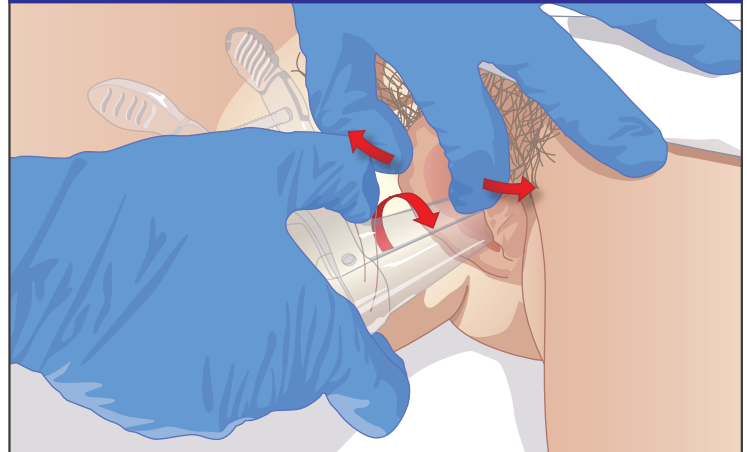
Open the lubricating gel, if using. Warm the speculum if required by holding it under a warm running tap. If using gel, avoid getting this on the tip of the speculum (inset), as this can affect the results. Smooth the gel over the front and back of the speculum.

Introduce the speculum: (a)



Adjust the light source to illuminate the vulva. Separate the labia and insert the speculum sideways into the vagina.

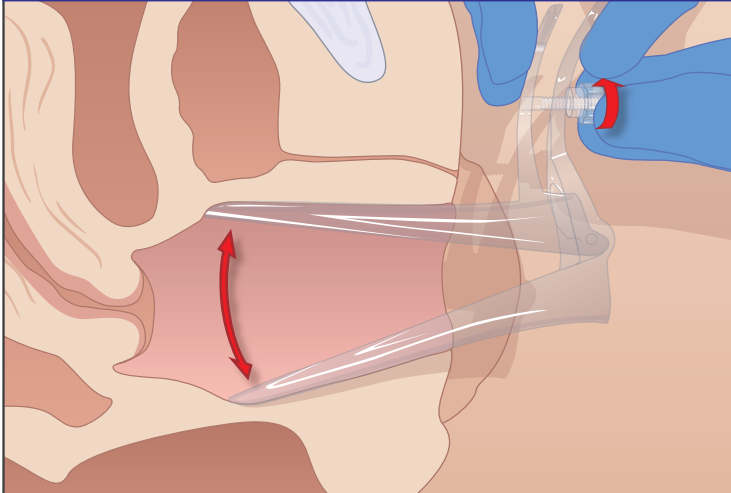
(b)



Aiming for the small of the back, gently push the speculum into the vagina until you meet some resistance, rotating it as you go until the handles are vertical. Avoid touching the clitoris with the handles.

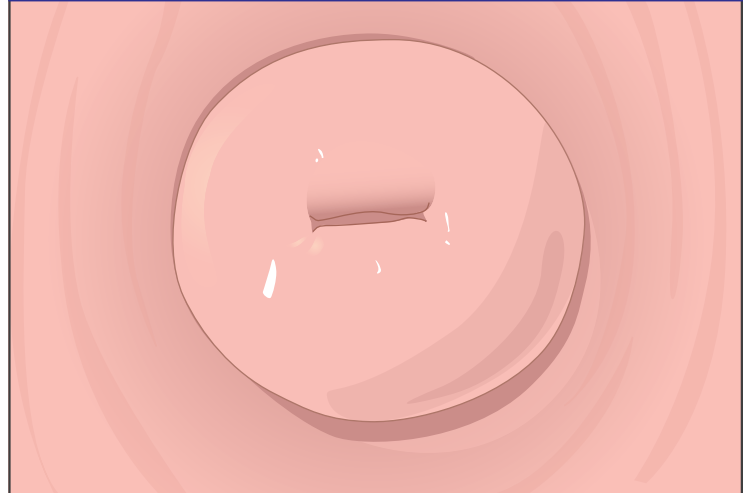Taking a cervical smear Page 4

Open the blades



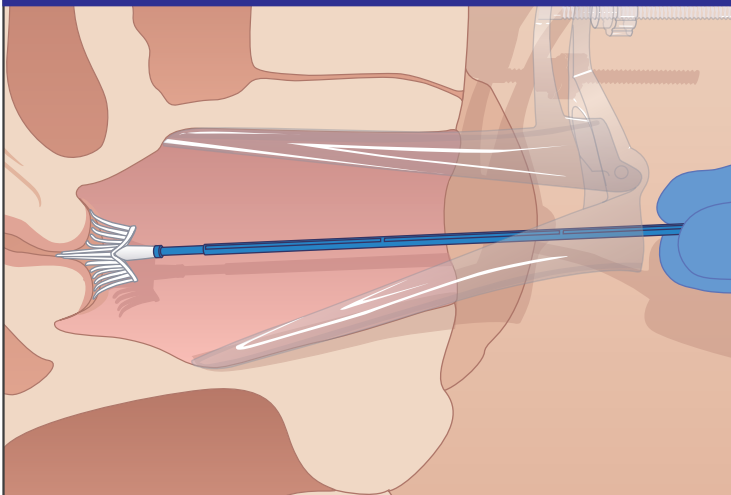
Gently squeeze the handles together to open the blades of the speculum. Turn the screw clockwise to secure the blades into an open position. If you need to leave the room or the patient, first remove the speculum.

Identify the cervix



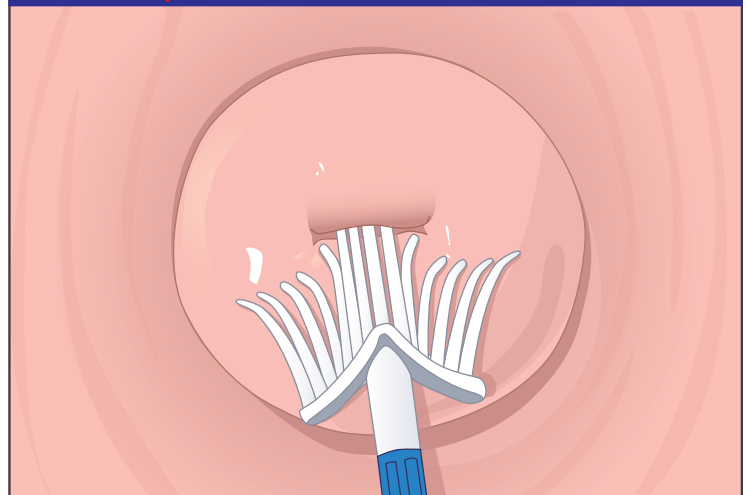Adjust your light source and identify the cervix. Note any abnormalities (see page 6).

Introduce the brush




Insert the brush into the vagina and apply it to the cervix.

Insert the tip of the brush into the cervical os



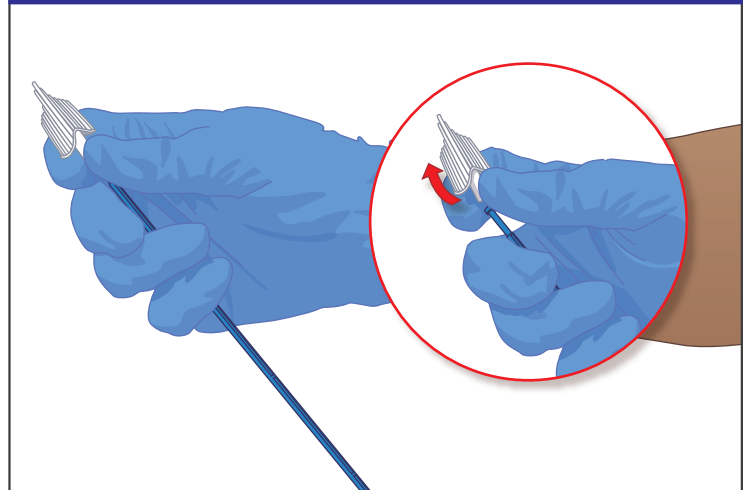
Position the brush so that the tip is in the cervical os and the bristles are splayed out against the cervix but not collapsed.

Rotate the brush five times



Rotate the brush clockwise against the cervix, throughout 360°. Perform five full rotations.

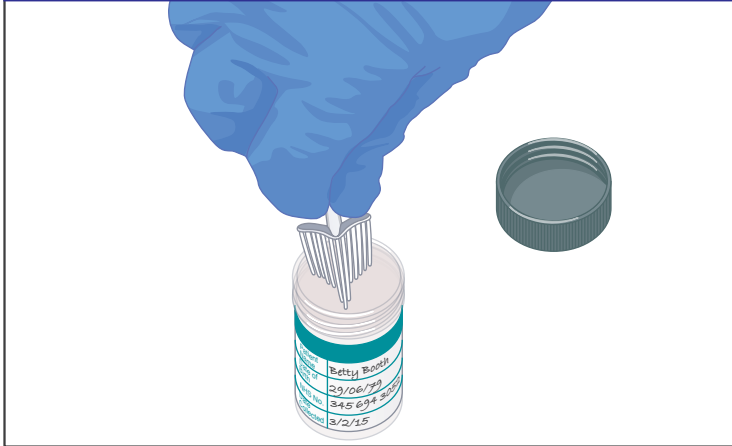Remove the brushhead



Remove the brush from the vagina and, with one hand, remove the brush head from the handle.

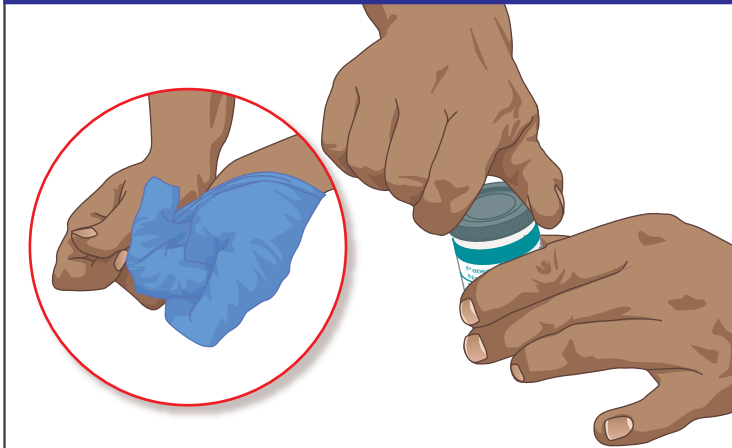
Taking a cervical smear Page 5

Deposit the brush head into the sample bottle



Deposit the brush head into the fluid in the bottle, with the bristles pointing downwards. Do not put the lid on yet.

Put the lid on the specimen container



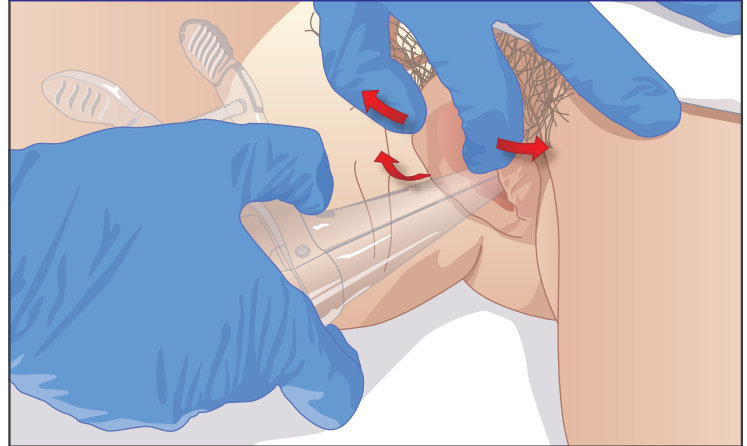
Remove and dispose of gloves and then screw the lid on the bottle. It is important to remove your gloves first, to avoid contaminating the sample in accordance with infection control policies. Agitate the bottle, do not shake it.

Complete the specimen form

01 Woman's hospital / GP Registration number: NHS		12 Slide serial number	
03 Woman's surname: BOOTH First names: BETTY Full postal address: 61 BECKHAM ROAD, HUDDS, post code: HD1 3PL		17 Reason for smear routine call 1 routine recall 2 previous abnormal smear 3 previous inadequate smear 4 opportunistic 5 follow-up after treatment 6 other 7	
03 Date of birth: 29/06/79 05 NHS number: 345 694 3052		18 Specimen type cervical scrape 1 other (specify) 2	
06 If hospital state consultant, clinic or ward, and hospital Name and address of sender if not GP: The Victoria Surgery, Victoria Road, Huddersfield		20 Clinical data (including signs and symptoms, previous abnormal cytology with slide number, previous diagnosis and treatment) Last sm inad? Yes No Cx visualised? Yes No 360° sweep x 5? Yes No	
07 A Name and address of GP: The Victoria Surgery, Victoria Road, Huddersfield		21 CYTOLOGY REPORT 22 Cytological pattern inadequate spec 1 negative 2 borderline ch 3 mild dysk 4 moderate 5 severe 6	
08 GPs HA code		23 Specific infection Trichomonas 1 candida 2 warty virus 3 herpes 4 mild dyskaryosis 5 moderate dyskaryosis 6 severe dyskaryosis 7 severe dyskaryosis/other (specify) 8	
09 Source: community clinic 2 Private 5 LOCAL 2 5		24 Management suggested normal recall 1 repeat smear in months 2 or other treatment 3 gynaecological referral 4 cancer recall 5	

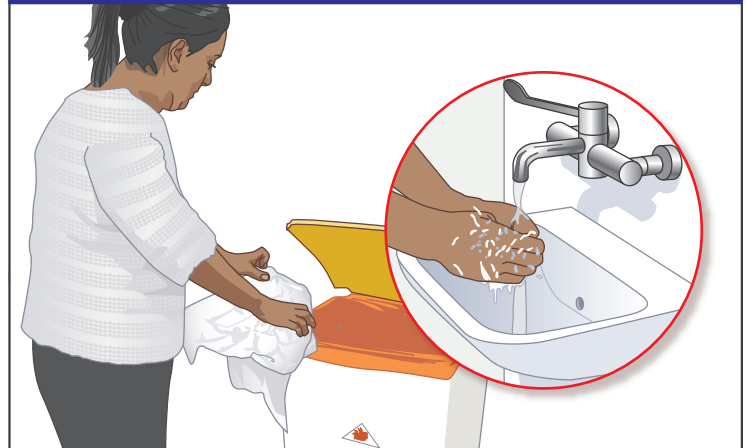Either print off an electronic form or fill in the form stating that you have visualised the cervix and completed five 360° sweeps. It is mandatory to enter the details into your personal audit and any practice audit used (RCN, 2013). The log will be anonymised and will normally include the patient's NHS number or date of birth, the date the sample was obtained, and information on results, presence of transformation zone (TZ) and "Any other comments". If the practitioner's results differ widely from his/her peers or the national average, retraining will take place (RCN, 2015).

Remove the speculum as soon as possible



Gently and slowly remove the speculum from the patient, taking care not to trap the vaginal wall between the blades as you close the speculum.

Dispose of equipment and wash your hands



Lower the bed and assist the patient to stand if necessary. Allow the patient to dress in private. Dispose of equipment and wash your hands. Tell the patient that she will receive the results in the post within 2 to 3 weeks.

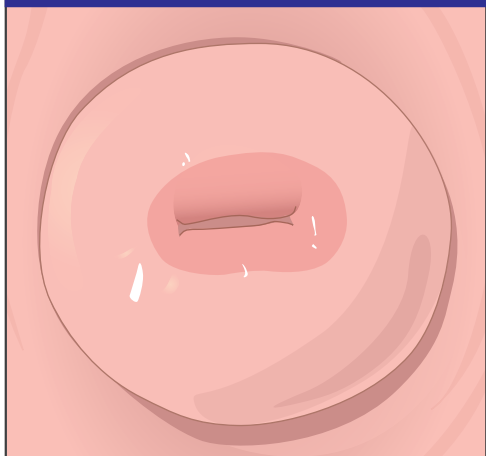(b)

NHS		serial number	
13 This test: 3/2/15		17 Reason for smear: routine recall 1	
14 LMP (1st day): 20/1/15		previous abnormal smear 2	
15 Last test: 21/1/12		previous inadequate smear 3	
16 If no previous test please put X		opportunistic 4	
18 Specimen type: cervical scrape 1		follow-up after treatment 5	
19 NHS number: 345 694 3052		other 6	
20 Clinical data (including signs and symptoms, previous abnormal cytology with slide number, previous diagnosis and treatment)		21 CYTOLOGY REPORT	
22 Cytological pattern: negative 2		23 Specific infection: Trichomonas 1	
24 Management suggested: normal recall 1		24 Management suggested: repeat smear in months 2	

Ensure delivery to the laboratory on the same day if possible, or as soon as possible, to help ensure that women receive their results within 14 days of attending for screening (NHS Improvement, 2009).

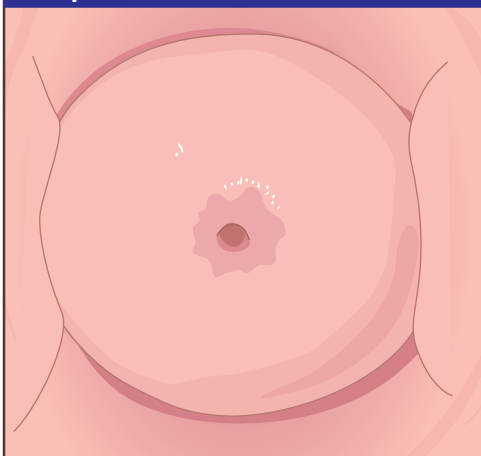Taking a cervical smear Page 6

Normal cervix



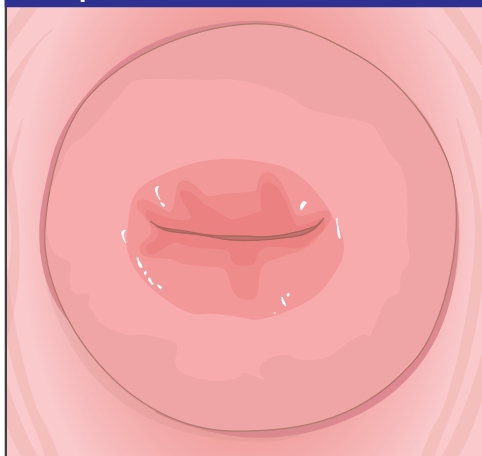
A normal cervix will look pink, smooth and healthy.

Nulliparous os



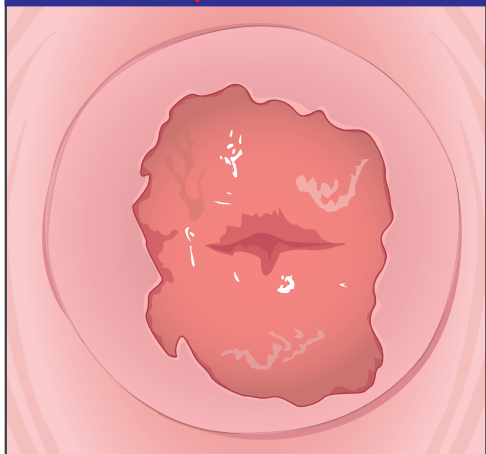
In a nulliparous woman, the os is usually circular.

Multiparous os



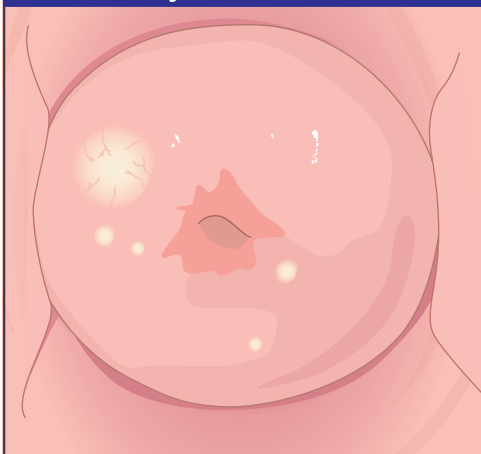In a multiparous woman, the os has the appearance of a horizontal slit.

Cervical ectropion



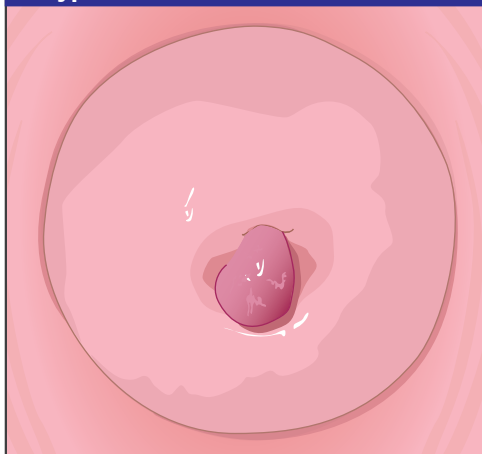The endocervix is inflamed and friable and bleeds easily on contact. There is often mucopurulent discharge which may be green or yellow. **Swabs should be taken to exclude the presence of a sexually transmitted infection (see clinicalskills.net procedure, "Taking cervical swabs").**

Nabothian cysts



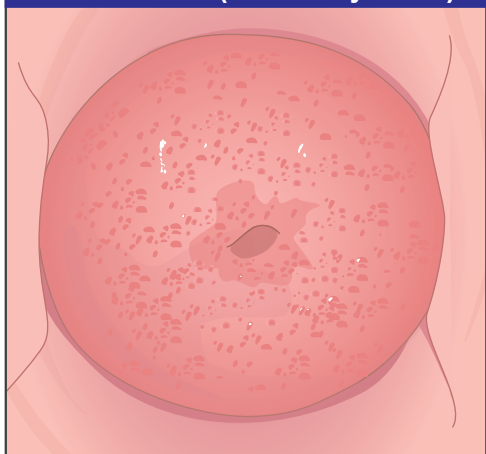
These do not need treating. Nabothian cysts are mucous-filled cysts which are considered normal on an adult cervix. They may look translucent or opaque and can range from 2-10 mm in diameter; they may be individual or multiple.

Polyp



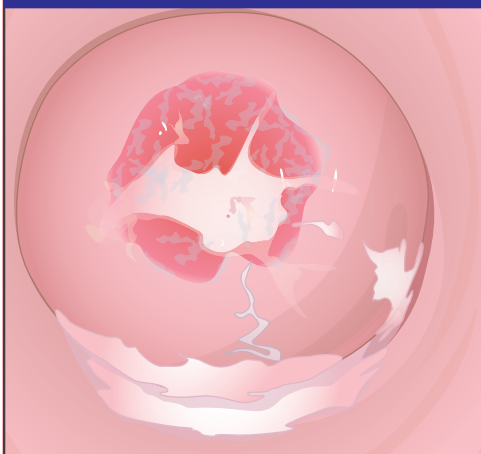
These are mostly benign but should be removed and sent for histology to rule out malignancy. They are often seen in women aged 40-50 years and can look like cherry-red lesions protruding from the os. They can cause abnormal bleeding and can obstruct the os, causing fertility problems.

Trichomoniasis (strawberry cervix)



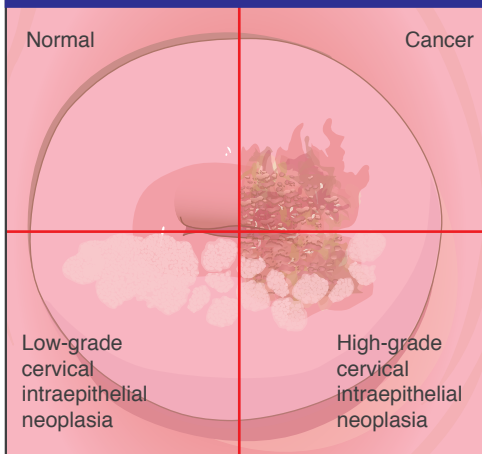
With *Trichomonas* infection, the cervix is erythematous and friable, with microscopic punctate haemorrhages. There is often a mucopurulent discharge. Take swabs for diagnosis and refer for treatment and contact tracing.

Candidiasis



Candidiasis (thrush) is a common presentation. White patches may be seen on the cervix and in the vagina. There is often a thick white curd-like discharge and the patient is likely to complain of itching.

Cellular abnormalities



The smear test detects cellular changes that could lead to abnormalities (intraepithelial neoplasia), which, if untreated, could develop into cancer. Such changes may also sometimes be visible to the naked eye, particularly if advanced.

Do not undertake or attempt any procedure unless you are, or have supervision from, a properly trained, experienced and competent person. Always first explain the procedure to the patient and obtain his/her consent, in line with the policies of your employer or educational institution