



Mullins' syndrome: a new gammopathy-related autoinflammatory syndrome resistant to anakinra.

Longhurst, HJ; Yong, PF; Manson, AL; Cavenagh, JD; Grigoriadou, S; Buckland, MS

© The Author 2012

CC-BY

For additional information about this publication click this link.

<http://qmro.qmul.ac.uk/xmlui/handle/123456789/10691>

Information about this research object was correct at the time of download; we occasionally make corrections to records, please therefore check the published record when citing. For more information contact scholarlycommunications@qmul.ac.uk

Case report

QJM

Mullins' syndrome: a new gammopathy-related autoinflammatory syndrome resistant to anakinra

H.J. LONGHURST¹, P.F.K. YONG¹, A.L. MANSON¹, J.D. CAVENAGH², S. GRIGORIADOU¹
and M.S. BUCKLAND¹

From the ¹Department of Immunology and ²Department of Haemato-Oncology, Barts Health NHS Trust, 2nd Floor, Pathology and Pharmacy Building, The Royal London Hospital, 80 Newark Street, London E1 2ES, UK

Address correspondence to H.J. Longhurst, Department of Immunology, Barts Health NHS Trust, 2nd Floor, Pathology and Pharmacy Building, The Royal London Hospital, 80 Newark Street, London E1 2ES, UK. email: hilary.longhurst@bartshealth.nhs.uk

Case report

A 59-year-old Caucasian male had a 28-year history of episodes of recurrent urticaria, fever, periorbital angio-oedema and conjunctival injection. The episodes would be preceded by prodromal symptoms of nightmares, general malaise/fatigue and anterior chest/upper abdominal pain similar to indigestion. This would then proceed to urticaria, which had been described as atypical, not always being raised or palpable but being intensely itchy (Figure 1), as well as fever, periorbital angio-oedema and sometimes gum or jaw pain. Four to 6 h after onset, symptoms would typically proceed to hypotension resulting in the loss of consciousness on several occasions. Attacks would last 3–4 days, and were followed by fatigue lasting 1–2 weeks.

Investigations showed a monoclonal immunoglobulin G (IgG) kappa paraprotein that has fluctuated between 14 and 20 g/l throughout the course of his illness, although without increasing trend. He was also found to have low levels of kappa free light chains on urine electrophoresis. He had low C4 complement levels and C3 complement levels at the lower end of the normal range during remission, with raised C3d and elevated amounts of the terminal component complex, consistent with ongoing complement activation. Other investigations taken during remission, including C1 inhibitor levels; full blood count; renal and liver function; thyroid function;

erythrocyte sedimentation rate (ESR); and C-reactive protein (CRP), did not show any significant abnormality. Anti-nuclear and anti-neutrophil cytoplasmic antibodies were not detected.

Subsequently, he was admitted for observation during an attack. Investigations done at that time showed a markedly increased CRP of >250 mg/l, leucopenia and thrombocytopenia (with a nadir white cell count of $0.7 \times 10^9/l$, neutrophil count of $0.1 \times 10^9/l$ and platelet count of $28 \times 10^9/l$) and decreased complement C3 and C4 levels. The ESR did not show a concomitant rise with the CRP and was within normal limits. No cryoproteins were isolated. Serial mast cell tryptase levels were not elevated during the attack. This laboratory result picture could have been consistent with active systemic lupus erythematosus or severe sepsis. However, anti-nuclear antibody was negative, urea and electrolytes remained normal, and there was no other clinical evidence of lupus. Multiple blood cultures and viral polymerase chain reaction investigations did not reveal a microbe.

It should be noted that the marked laboratory abnormalities were delayed by a day after onset of severe symptoms, during this and subsequent episodes where corticosteroid treatment was delayed. All laboratory abnormalities returned to baseline following the attack. Figure 2 shows the progression of these investigations during one of his acute attacks. Despite the severe neutropenia, treatment

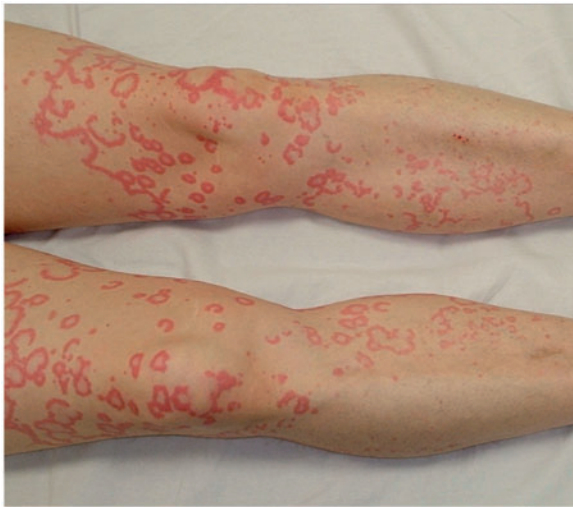

Figure 1. Photograph of rash during attacks.

with granulocyte colony-stimulating factor and broad spectrum antibiotics was unnecessary as the fever and cytopenias spontaneously resolved.

A bone marrow biopsy was normocellular with plasma cells <5%. A skin biopsy of one of the lesions showed mild dermal oedema, consistent with urticaria, but without any specific pathologic features. Radiological imaging did not show evidence of hepatomegaly, splenomegaly and lymphadenopathy on computed tomography scanning. A skeletal survey showed no abnormalities.

To determine if his symptoms were due to a periodic fever syndrome, genetic testing of *FEMV*, *TNFRSF1A*, *NLRP3* and *MVK* (for FMF, TRAPS, CAPS and HIDS, respectively) was undertaken, but no mutations were detected within the exons that have previously been associated with disease causing mutations in these genes.

A diagnosis of monoclonal gammopathy of uncertain significance, rather than myeloma, was made and no further specific treatment for this was indicated. Various therapeutic options to treat and reduce the frequency of his attacks were tried. Antihistamines and tranexamic acid may have helped reduced the urticaria but did not prevent progression of the associated symptoms. Neither C1 inhibitor nor anakinra significantly modified the course of the attacks. Oral prednisolone (30–40 mg daily for 3 days) was found to be helpful in aborting or reducing the severity of attacks when commenced in the prodromal stage. He was subsequently commenced on subcutaneous immunoglobulin replacement therapy because of the evidence of development of immune paresis and the identification of respiratory tract infection as a trigger for attacks.

Discussion

The auto-inflammatory syndromes represent a group of disorders characterized by recurrent fever associated with systemic inflammatory symptoms affecting joints, skin, muscles and eyes (reviewed in Goldbach-Mansky¹). They are thought to be due to dysregulation of the innate immune system, resulting in episodes of spontaneous inflammation. Typically, there is absence of autoimmune reactivity with no detectable auto-antibodies or auto-reactive T cells.

Initially, the auto-inflammatory syndromes were taken to encompass the hereditary recurrent fever syndromes, but with time the umbrella term has expanded to include a broader range of diseases.

The recognized monogenic disorders resulting in an auto-inflammatory syndrome include the hereditary periodic fever syndromes: familial Mediterranean fever (FMF), TNF receptor-associated periodic syndrome (TRAPS), mevalonate kinase deficiency (previously known as hyper-immunoglobulin D syndrome, HIDS), the cryopyrin-associated periodic syndromes (CAPS), Blau syndrome, deficiency of interleukin-1-receptor antagonist and pyogenic arthritis, pyoderma gangrenosum and acne syndrome (PAPA). Other auto-inflammatory diseases of uncertain genetic aetiology include periodic fever, aphthous stomatitis, pharyngitis and adenitis syndrome; Majeed syndrome, associated with chronic recurrent multifocal osteomyelitis, congenital dyserythropoietic anaemia and neutrophilic dermatosis; and Behcet's disease. Acquired auto-inflammatory syndromes such as Schnitzler's syndrome can also occur. Almost all of the auto-inflammatory disorders respond to treatment with interleukin (IL)-1 antagonism, and a number of conditions (including HIDS, Majeed syndrome, TRAPS, PAPA and Blau syndrome) respond to corticosteroid therapy.¹

Schnitzler's syndrome is the occurrence of urticaria and a monoclonal paraprotein (typically IgM). Other associated features include the presence of fever, raised inflammatory markers, hepatomegaly, splenomegaly, lymphadenopathy, bony pain, arthritis/arthralgia and bone abnormalities.^{2–4} It was originally described in 1972 and is relatively rare⁴ with a total of approximately 100 patients described in the literature, mostly in case reports.² Lipsker *et al.*³ proposed a set of diagnostic criteria that included the presence of two major criteria—chronic urticarial rash and a monoclonal IgM paraprotein along with two of any of the following minor criteria: recurrent fever, arthralgia or arthritis, bone pain, lymphadenopathy, hepato- or splenomegaly and an acute phase response (leucocytosis or

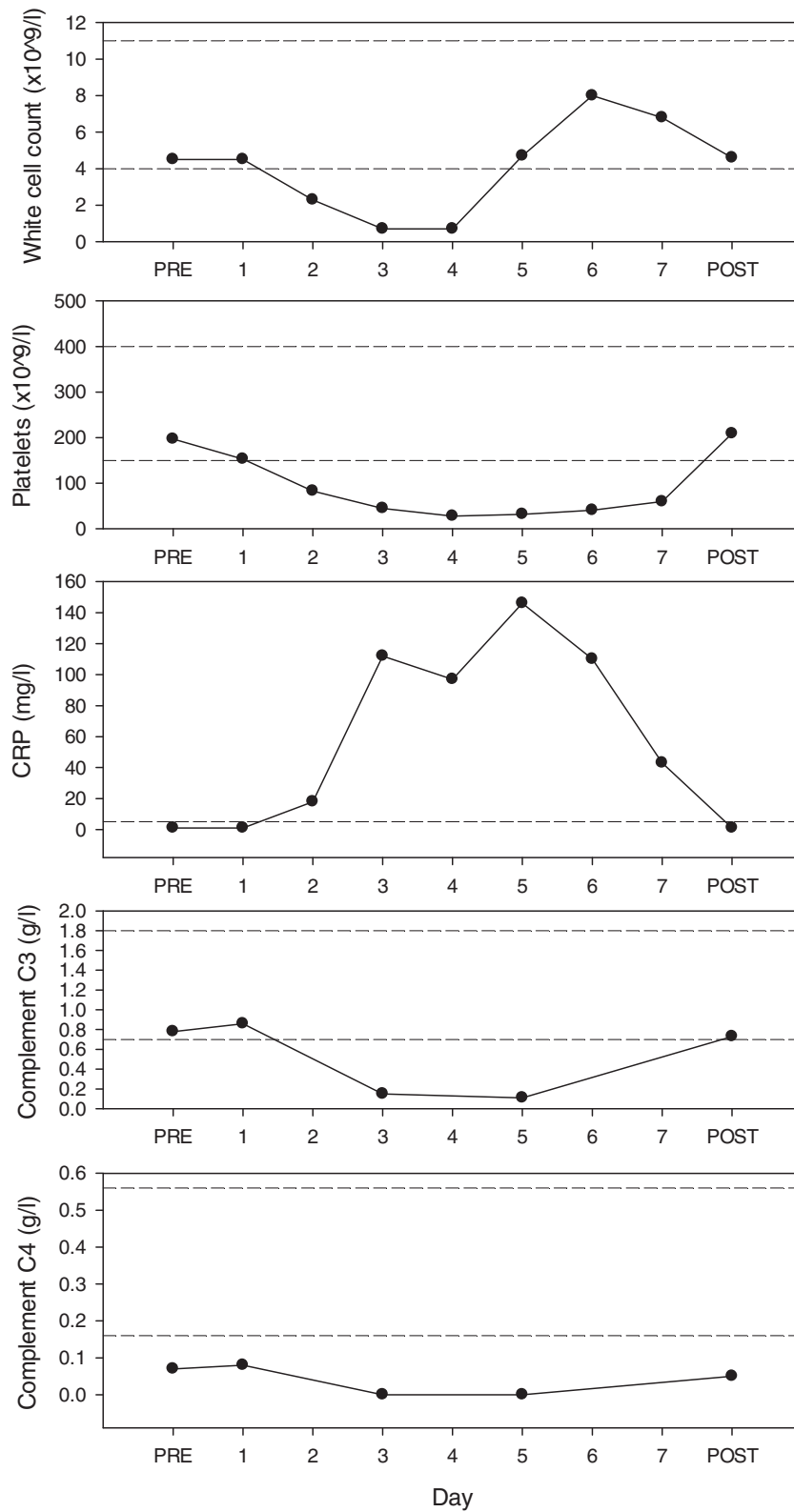


Figure 2. Graph showing serial white cell count, platelets, CRP, complement C3 and complement C4 during, before and after an acute inflammatory attack. The dashed lines represent the reference ranges for the individual parameters.

elevated ESR/CRP). Other causes that can result in a similar symptom complex also need to be excluded. More recently, a Schnitzler syndrome variant has been described with a monoclonal IgG paraprotein (instead of IgM).^{5–7}

Our patient fulfils criteria for a diagnosis of IgG variant Schnitzler's syndrome. However, there are some atypical features to indicate that our patient's syndrome is pathologically distinct, and represents another form of auto-inflammatory disease associated with a monoclonal gammopathy.

Of note, Schnitzler's syndrome is associated with lymphadenopathy (44% of the patients) and hepatosplenomegaly (12% of the patients), as well as a leucocytosis (69% of patients) during attacks.² Our patient had none of those features and conversely had marked neutropenia (as part of pancytopenia), most likely due to immune complex-mediated consumption. In addition, there was marked activation of the complement cascade, with decreased levels of early classical complement components and increased terminal components. Complement activation has been proposed as a possible pathophysiological mechanism for Schnitzler's syndrome; however, complement components have been either normal or elevated in reported cases,² with reduced levels indicating either an alternative diagnosis (e.g. cryoglobulinaemia)⁸ or genetic deficiency,⁹ neither of which our patient had.

Another unusual feature is that in terms of treatment response, our patient had an absent response to anakinra unlike other patients with Schnitzler's syndrome treated with this biological agent.^{2,10} Instead, our patient has responded to treatment with oral steroids. In classical Schnitzler's syndrome, the response to steroids is more variable with only 39% of the patients obtaining complete resolution of symptoms.² The IL-1/IL-1RA pathway is thought to play a major role in the development of Schnitzler's syndrome (as well as many of the other auto-inflammatory syndromes). However, it is likely in our patient that either the IL1 pathway is not playing a significant role or that other mechanisms are more important. A strong possibility in this case is that complement activation due to immune complex deposition might be initiating the inflammatory cascade.

Many inflammatory stimuli (e.g. various bacterial products including lipopolysaccharide) can concurrently trigger IL-1 secretion and complement activation (in addition to many other inflammatory mediators). However, there is limited data investigating the role of complement alone in the activation of IL-1, and this has shown conflicting results. Plasma purified C5a and C3a have been shown to stimulate IL-1 production from mouse macrophages

and human peripheral blood mononuclear cells (PBMC).^{11–13} Conversely, there have been some studies showing no secretion of IL-1 from rabbit mononuclear cells or human PBMCs after stimulation with purified and recombinant complement fractions.^{14,15} A further study using recombinant C5a showed induction of transcription (but not translation) of IL-1 from PBMCs, in contrast to lipopolysaccharide, which resulted in transcription and translation of IL-1.¹⁶ There is data showing that complement, and the membrane attack complex in particular, promotes release of IL-1 α from endothelial cells.¹⁷ Hence, it is unclear whether complement activation alone (in absence of other signals) results in IL-1 release. Although not definitive, the laboratory data suggest that in some circumstances, complement activation does not necessarily result in IL-1 production; consistent with the findings in our patient of complement activation and inflammation but no response to IL-1 antagonism.

Conclusion

We present a case of monoclonal gammopathy-related auto-inflammatory syndrome distinguished from Schnitzler's syndrome by complement activation, neutropenia and an absent response to anakinra. We believe that this patient manifests a new auto-inflammatory syndrome not previously described. Features of the syndrome include:

- monoclonal paraprotein;
- ongoing classical pathway complement consumption;
- intermittent fever, rash and hypotension;
- transient leucopenia and thrombocytopenia, and severe complement depletion following initial symptoms;
- resistance to IL1 antagonists; and
- acute attacks terminated by corticosteroids.

Despite some similarities to Schnitzler's syndrome, the symptoms primarily relate to complement activation rather than IL1 production. In such cases, treatment modalities other than anakinra may need to be considered to dampen down the inflammation.

We propose naming this Mullins' syndrome after the patient described.

Conflict of interest: None declared.

References

1. Goldbach-Mansky R. Immunology in clinic review series; focus on autoinflammatory diseases: update on monogenic autoinflammatory diseases: the role of interleukin (IL)-1 and an emerging role for cytokines beyond IL-1. *Clin Exp Immunol* 2012; **167**:391–404.

2. de Koning HD, Bodar EJ, van der Meer JW, Simon A. Schnitzler syndrome: beyond the case reports: review and follow-up of 94 patients with an emphasis on prognosis and treatment. *Semin Arthritis Rheum* 2007; **37**:137–48.
3. Lipsker D, Veran Y, Grunenberger F, Cribier B, Heid E, Grosshans E. The Schnitzler syndrome. Four new cases and review of the literature. *Medicine* 2001; **80**:37–44.
4. Schnitzler L. Lesions urticariennes chroniques permanentes (erytheme petaloide?) Cas cliniques, No 46B. *J Dermatol Angers* 1972; Abstract 46.
5. Akimoto R, Yoshida M, Matsuda R, Miyasaka K, Itoh M. Schnitzler's syndrome with IgG kappa gammopathy. *J Dermatol* 2002; **29**:735–8.
6. Nashed D, Sunderkotter C, Bonsmann G, Luger T, Goerdts S. Chronic urticaria, arthralgia, raised erythrocyte sedimentation rate and IgG paraproteinaemia: a variant of Schnitzler's syndrome? *Br J Dermatol* 1995; **133**:132–4.
7. Pascual-Lopez M, Hernandez-Nunez A, Sanchez-Perez J, Fernandez-Herrera J, Garcia-Diez A. Schnitzler's syndrome with monoclonal IgG kappa gammopathy: good response to cyclosporin. *J Eur Acad Dermatol Venereol* 2002; **16**:267–70.
8. Baty V, Hoen B, Hudziak H, Aghassian C, Jeandel C, Canton P. Schnitzler's syndrome: two case reports and review of the literature. *Mayo Clin Proc* 1995; **70**:570–2.
9. Rybojad M, Moraillon I, Cordoliani F, Lebbe C, Baccard M, Flageul B, et al. [Schnitzler syndrome with genetic C4 deficiency. 2 cases]. *Ann Dermatol Venereol* 1993; **120**:783–5.
10. de Koning HD, Bodar EJ, Simon A, van der Hilst JC, Netea MG, van der Meer JW. Beneficial response to anakinra and thalidomide in Schnitzler's syndrome. *Ann Rheum Dis* 2006; **65**:542–4.
11. Haeflner-Cavaillon N, Cavaillon JM, Laude M, Kazatchkine MD. C3a(C3adesArg) induces production and release of interleukin 1 by cultured human monocytes. *J Immunol* 1987; **139**:794–9.
12. Okusawa S, Dinarello CA, Yancey KB, Endres S, Lawley TJ, Frank MM, et al. C5a induction of human interleukin 1. Synergistic effect with endotoxin or interferon-gamma. *J Immunol* 1987; **139**:2635–40.
13. Okusawa S, Yancey KB, van der Meer JW, Endres S, Lonnemann G, Hefer K, et al. C5a stimulates secretion of tumor necrosis factor from human mononuclear cells in vitro. Comparison with secretion of interleukin 1 beta and interleukin 1 alpha. *J Exp Med* 1988; **168**:443–8.
14. Arend WP, Massoni RJ, Niemann MA, Giclas PC. Absence of induction of IL-1 production in human monocytes by complement fragments. *J Immunol* 1989; **142**:173–8.
15. Gekowski KM, Atkins E. The search for an endogenous activator. *Yale J Biol Med* 1985; **58**:153–63.
16. Schindler R, Gelfand JA, Dinarello CA. Recombinant C5a stimulates transcription rather than translation of interleukin-1 (IL-1) and tumor necrosis factor: translational signal provided by lipopolysaccharide or IL-1 itself. *Blood* 1990; **76**:1631–8.
17. Brunn GJ, Saadi S, Platt JL. Differential regulation of endothelial cell activation by complement and interleukin 1alpha. *Circ Res* 2006; **98**:793–800.