

CASE REPORT

ENGINEERING & APPLIED SCIENCES; PATHOLOGY/BIOLOGY

Waltraud Baier,¹ Ph.D.; Michael J. Donnelly,¹ M.Eng.; Mark Payne,² M.B.A.; and Mark A. Williams,¹ Ph.D.

A Holistic Multi-Scale Approach to Using 3D Scanning Technology in Accident Reconstruction

ABSTRACT: Three-dimensional scanning and documentation methods are becoming increasingly employed by law enforcement personnel for crime scene and accident scene recording. Three-dimensional documentation of the victim's body in such cases is also increasingly used as the field of forensic radiology and imaging is expanding rapidly. These scanning technologies enable a more complete and detailed documentation than standard autopsy. This was used to examine a fatal pedestrian-vehicle collision where the pedestrian was killed by a van while crossing the road. Two competing scenarios were considered for the vehicle speed calculation: the pedestrian being projected forward by the impact or the pedestrian being carried on the vehicle's bonnet. In order to assist with this, the impact area of the accident vehicle was scanned using laser surface scanning, the victim was scanned using postmortem CT and micro-CT and the data sets were combined to virtually match features of the vehicle to injuries on the victim. Micro-CT revealed additional injuries not previously detected, lending support to the pedestrian-carry theory.

KEYWORDS: road traffic collision, scene scanning, micro-CT, 3D modelling, scene reconstruction, visualization

Nearly, 400 pedestrians are killed in vehicle collisions every year in the U.K. (1). Forensic collision investigation is a crucial element of such cases as it sheds light on whether the incident was an unavoidable accident or caused by a more serious driving fault. Careful scene examination, vehicle testing, and the application of physical principles are combined to reconstruct the incident. Digital scanning tools are increasingly being used to assist forensic investigators capturing every detail at the scene for later analysis and visualization. This is the case for crime scenes (2) as well as road traffic collisions (3). These tools range from simple recording of individual points of interest to the creation of accurately scaled, photo-realistic 3D models of the scene (3,4). Previous studies have demonstrated the added benefit of using such complementary 3D data sets, for example, to help distinguish between accident or homicide (5) or to prove the driver's correct response in a vehicle-bicycle collision (6).

The case reported here provides another example of the use of such digital technologies. In contrast to previously reported cases, the present one incorporates micro-CT as one imaging modality which is a unique addition to accident investigation. Micro-CT is an increasingly employed imaging technology in

forensics that offers a wide range of possible applications within the discipline (7-12). Similar to standard medical CT, multiple radiographic projections are acquired throughout the object's full 360° rotation and then reconstructed to produce a three-dimensional volume file (13). Micro-CT achieves a much higher resolution than medical-grade CT allowing for a more detailed examination which has been shown to be essential when examining small features and subtle damage (14).

While micro-CT is used to examine an item's internal structures, laser scanning can be employed to characterize its external features. This applies to entire scenes, both outdoors and indoors, but also to individual objects such as vehicle parts (15). As laser scanning technology is mobile, it is particularly useful where the area of interest forms part of a larger object or one that cannot be transported. Combining these different tiers of scanning technology provides a multi-scale perspective of the same incident, thus maximizing the information gained from it. This case report focusses on the contributions of micro-CT and laser scan data sets to a road traffic collision. However, these data sets constitute only some aspects of the overall investigation and other expert findings will be referenced to provide additional context and to illustrate how the data were used.

Case Background

A pedestrian was hit and fatally injured by a van while crossing a dual carriageway at a signal-controlled pedestrian crossing. A postmortem CT (PMCT) scan of the victim was conducted in hospital, identifying severe head trauma and injury to the major

¹Warwick Manufacturing Group, International Manufacturing Centre, University of Warwick, Coventry, CV4 7AL, England.

²West Midlands Police Police Headquarters, Lloyd House, Colmore Circus, Birmingham, B4 6NQ, England.

Corresponding author: Waltraud Baier, Ph.D. E-mail: v.baier@warwick.ac.uk

Received 30 Jan. 2020; and in revised form 20 Mar. 2020; accepted 25 Mar. 2020.

organs, along with a fractured right ankle. The postmortem examination further detailed a gaping laceration at the inner aspect of the anterior left femur. The injury appeared to involve the periosteum and possibly the underlying bone and silver paint fragments, matching the color of the accident vehicle, were embedded in the injury. This area was micro-CT scanned to determine the extent of the skeletal injury.

The vehicle's driver claimed that they observed the 30 mph speed limit but witness accounts contradicted this statement, suggesting the driver was speeding. Witnesses further stated that the traffic lights at the crossing had been on red as the van approached but they had not seen any break lights on the van prior to the impact. In addition to standard scene examination by collision experts, the impact area of the van was subsequently laser surface scanned to create a virtual 3D model showing the damage and potentially link it to the victim's injuries. In order to calculate the vehicle speed, police collision investigators first had to determine whether the victim had been projected forward by the force of the impact or whether they had been carried on the vehicle before falling off and coming to a halt. These two scenarios use different formulae that would result in false speed calculations if applied incorrectly.

Method/Materials

Micro-CT

A section of the left femur was removed during the forensic postmortem examination and micro-CT scanned in order to establish whether the soft tissue injury observed at postmortem had damaged the underlying bone. The sample was scanned using a Nikon XT 225/320 LC micro-CT scanner (Nikon Metrology, Tring, UK) at the parameters of 110 kV, 30 W, 708 ms exposure, at a spatial resolution of 90.6 μm . The scan was reconstructed using the system's proprietary software CTPro and examined in VG Studio MAX2.2 (Volume Graphics, Heidelberg, Germany). Using the software's best fit algorithm, as detailed by Matthews and Du Plessis (16), the scan was then aligned with a volume-rendering of the PMCT scan to embed the sample into its original context (Fig. 1).

Laser Scanning

Laser scan data were collected from the front offside region of the Mercedes Sprinter van involved in the incident. The vehicle was scanned with a Nikon K610 Optical CMM system (Nikon Metrology, Derby, UK) at a resolution of 75 μm . This system uses infrared LED triangulation to capture an object's surface by measuring the distortion of a known projected pattern. The scans focused on areas of significant collision damage, namely the front offside wing, bonnet and front bumper, and the ground directly beneath the van to establish a base-plane. Investigators were only interested in the collision area, therefore the rest of the vehicle was disregarded for scanning. The scans were processed in Geomagic Studio 2014 (3D Systems, Hemel Hempstead, UK) to produce a surface mesh 3D model. An anthropometrically accurate 3D CAD model of a 20- to 60-year-old European female (from 3DHumanModel.com, Slimdesign, Amsterdam, Netherlands) was scaled to correlate with the deceased's BMI, provided retrospectively in the postmortem report. Images of the injuries taken during the postmortem were also overlaid onto the 3D human CAD model for additional visualization. Both 3D models of the van and the deceased were aligned using the established base-plane. This model was then provided to collision experts who used it to recreate the suggested collision scenario between van and the deceased in the 3D workspace. The models were exported as a 3D PDF file for investigators to use on less powerful computers/laptops for presentation purposes. This proved valuable during the ensuing trial as collision investigation experts presented the file to the jury to illustrate their interpretation of how the injuries had been caused.

Results

Micro-CT

The anterior surface of the femur displayed four separate marks, shown in Fig. 2, at the approximate location of the flesh injury. A subtle (A) groove measuring $2.3 \times 1.3 \text{ mm}$ was observed at the superior aspect which was too shallow to obtain

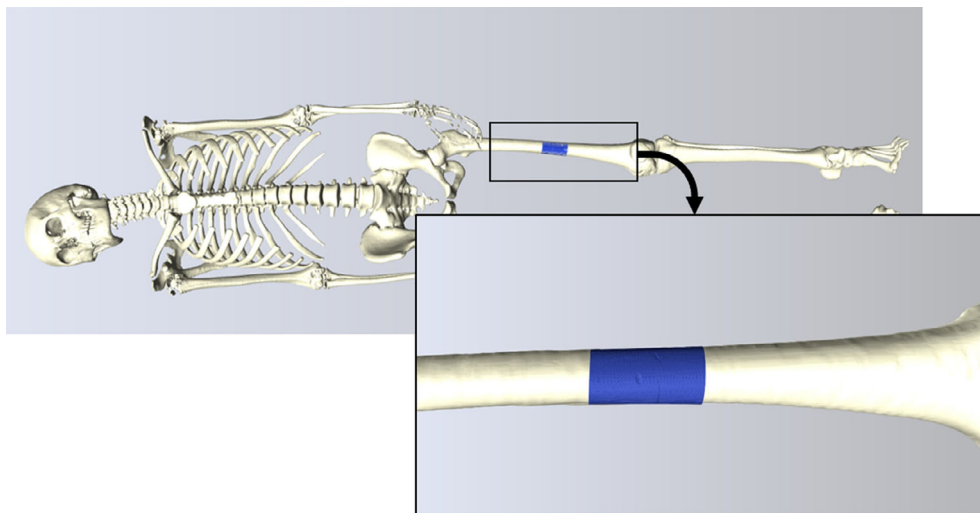


FIG. 1—Overlay of the micro-CT scan (in blue) with the hospital CT scan to visualize the original position of the sample in relation to the victim's height.

a depth measurement. Directly inferior to this was a deeper approximately rectangular defect (B) of 4.5×2.4 mm. This is the deepest injury, still only 0.4 mm deep. Just below this were two further linear grooves, orientated approximately horizontally. They were very shallow and measured 17.9 mm (C) and 15.4 mm (D) in length, measured circumferentially on the bone surface. They are wider at the lateral end, with maximal dimensions of 2.3 and 2.4 mm respectively and depth of up to 0.3 mm. Further toward the inferior end there was a microscopic fracture of the cortical bone. None of these injuries were visible on the postmortem CT scans.

Laser Scanning

The scan of the collision vehicle clearly showed the deformation on the offside wing where the metal had created a sharp pointed fold (Fig. 3). This appeared to have been caused by the impact as the vehicle was seen on CCTV to be structurally intact prior to the collision.

When the scaled human CAD model with the aligned micro-CT/PMCT scans and the overlaid injury images was placed next to the scanned vehicle at standing height, the skeletal leg injury lined up with the metal fold (Fig. 4). Two scenarios were brought before the pathologist: that the victim was projected by the impact to the position where they had come to rest, or that the victim had been conveyed by the vehicle before sliding off and coming to rest on the ground. The pathologist interpreted with the scan results and the overall injury pattern, shown in Fig. 5, and the lack of windscreen damage as supportive of the latter scenario.

Discussion

The 3D scanning is increasingly being used by police departments although it is predominantly focused on scanning the accident scene (3,17). The advantages of combining different

imaging modalities in pedestrian-vehicle collisions had been realized early on. Thali et al. (18), for example, use a combination of surface scanning, photogrammetry, and Postmortem CT to document the injuries and match them onto the damage on the vehicle in another pedestrian-vehicle collision. As in the present case, the interpretation of how these injuries were caused relied on pathological expertise. This demonstrates how the use of these imaging modalities assists with and improves current practices. With all the positive examples of holistic uses of forensic imaging technologies, one has to bear in mind that, as Bolliger et al. (19) point out, the raw data of such scanning constitutes only the primary information and still requires secondary interpretation by a subject expert. In the case presented here, the injuries were interpreted by the pathologist and this information was subsequently used by police collision investigators to interpret events, including calculating vehicle speed at impact. The speed calculations were influenced by the view that the deceased had been impaled and carried on the vehicle for some distance before hitting the ground. No further experiments were conducted to support this opinion although this could contribute valuable insight into the injury dynamics in traffic collisions in the future.

Many case reports that employ such an approach use a complete photogrammetric 3D model or the volume-rendered CT scan of the victim in their reconstruction (6,20). While this gives a maximum realism, it might not be suitable for all audiences. Therefore, in the case reported here, an anonymized scaled dummy model was chosen as the images were shared with investigators, judges, and the jury. Body mapping of the injuries sustained is already common practice for visualization, using the scaled human CAD model increases the accuracy of such displays.

Postmortem CT is often used as a standard examination for trauma victims and has proven valuable for detecting and visualizing gross skeletal trauma in road traffic collisions (21). However, the resolution of hospital CT scanners is limited and subtle




FIG. 2—(A) Volume-rendering of the micro-CT scan of the victim's left femur, anterior view. The superior mark A is only very faintly visible. All other marks B–D are clearly shown on the scan despite being very shallow. (B) Vertical 2D section through mark B showing its shallow depth of less than 0.5 mm.




FIG. 3—Laser scan of the accident vehicle. The black plane in the left image is the ground level which was used to align the dummy model of the victim to match the injuries to certain areas of the van. A pointed metal fold at the front offside wing (shown in detail on the right) was later identified as having caused the femoral injury.

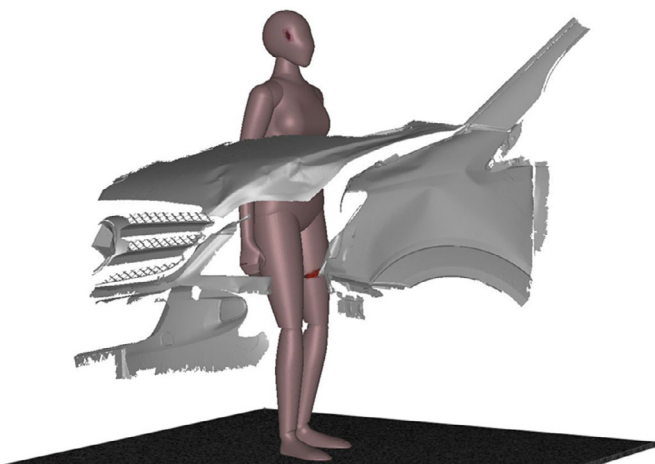


FIG. 4—Alignment of the dummy model with the van model showing the match between the leg injury and the metal fold on the bonnet.

injuries might not be identified. This is where micro-CT has shown to be of advantage. It can be used to examine areas of particular interest at more detail, as done in this case example. The presence of damage to the bone was essential in matching the wound to a specific area of the accident vehicle which was then used in the speed calculations. Having established that the victim had been carried on the vehicle before coming to a halt on the ground, investigators were able to choose the correct speed formula. This formula is different for cases where the pedestrian is projected away from the vehicle or carried as in this case (22-24) and results in different vehicle speeds. This led to the conclusion that the van driver was speeding at the time of collision.

Conclusion

This case demonstrates how different digital scanning methods complement each other when investigating scenes involving a pedestrian and a vehicle. The evidence provided using combined 3D scanning technologies revealed previously unidentified injuries and assisted investigators applying the appropriate speed

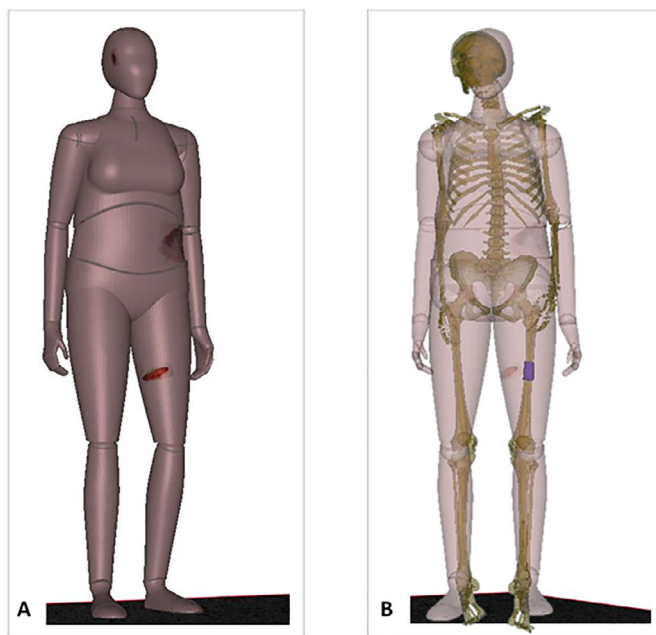


FIG. 5—(A) Anthropometric dummy scaled to the victim's BMI with the postmortem photographs of the main injuries on the head, left flank, and left femur, overlaid. (B) The combined PMCT and micro-CT (blue section) scans aligned with the dummy model. The slight misalignment of the two models stems from the different body position during the CT scan; the hip and knee joints were used as the main alignment points.

calculation formula, thus helping to prove that the driver was exceeding the speed limit. The driver was, therefore, convicted for causing death by dangerous driving and was sentenced to 7 years imprisonment. Had it not been for the 3D scans the Crown would have only been able to secure a conviction for the lesser offense of causing death by careless driving which carries a maximum sentence of 5 years (25).

Acknowledgments

We are grateful to Adam Green (West Midlands Police) for providing the collision investigation aspects of this case.

References

- Department for Transport. Statistical data set of reported road accidents, 2018. <https://www.gov.uk/government/statistical-data-sets/ras10-reported-road-accidents#accidents-by-type-of-accident> (accessed July 6, 2019).
- Engström P. Virtual reality for crime scene visualization. In: Javidi B, Son JY, Matoba O, editors. *Proceedings of SPIE 10666 Three-Dimensional Imaging, Visualization, and Display*; 2018 May 15–16; Orlando, FL. Bellingham, WA: SPIE, 2018. <https://doi.org/10.1117/12.2304653>.
- Forman P, Parry I. Rapid data collection at incident scenes using three-dimensional laser scanning techniques. In: Sanson LD, editor. *Proceedings of the 35th IEEE International Carnahan Conference on Security Technology*; 2001 Oct 16–19; London, England. Piscataway, NJ: IEEE, 2001;60–7. <https://doi.org/10.1109/CCST.2001.962814>.
- Dustin D, Liscio E. Accuracy and repeatability of the laser scanner and total station for crime and accident scene documentation. *J Assoc Crime Scene Recon* 2016;20:57–67.
- Buck U, Naether S, Räss B, Jackowski C, Thali MJ. Accident or homicide – virtual crime scene reconstruction using 3D methods. *Forensic Sci Int* 2013;225:75–84.
- Buck U, Naether S, Braun M, Bolliger S, Friederich H, Jackowski C, et al. Application of 3D documentation and geometric reconstruction methods in traffic accident analysis: with high resolution surface scanning, radiological MSCT/MRI scanning and real data based animation. *Forensic Sci Int* 2007;170:20–8.
- Rutty G, Brough A, Biggs M, Robinson C, Lawes S, Hainsworth S. The role of micro-computed tomography in forensic investigations. *Forensic Sci Int* 2013;225:60–6.
- Tsai A, McDonald AG, Rosenberg AE, Gupta R, Kleinman PK. High-resolution CT with histopathological correlates of the classic metaphyseal lesion of infant abuse. *Pediatr Radiol* 2014;44(2):124–40. <https://doi.org/10.1007/s00247-013-2813-z>.
- Fais P, Giraudo C, Viero A, Miotto D, Bortolotti F, Tagliaro F, et al. Micro computed tomography features of laryngeal fractures in a case of fatal manual strangulation. *Leg Med* 2016;18:85–9.
- Baier W, Norman DG, Warnett JM, Payne M, Harrison NP, Hunt NC, et al. Novel application of three-dimensional technologies in a case of dismemberment. *Forensic Sci Int* 2017;270:139–45.
- Norman DG, Watson DG, Burnett B, Fenne P, Williams MA. The cutting edge- micro-CT for quantitative toolmark analysis of sharp force trauma to bone. *Forensic Sci Int* 2018;283:156–72.
- Norman DG, Baier W, Watson DG, Burnett B, Painter M, Williams MA. Micro-CT for saw mark analysis on human bone. *Forensic Sci Int* 2018;293:93–100.
- Welkenhuyzen F, Kiekens K, Pierlet M, Dewulf W, Bleys P, Kruth JP, et al. Industrial computer tomography for dimensional metrology: overview of influence factors and improvement strategies. In: Dirckx J, Buytaert J, editors. *Proceedings of the 4th International Conference on Optical Measurement Techniques for Structures and Systems*; 2009 May 25–26; Antwerp, Belgium. Maastricht, Netherlands: Shaker Publishing, 2009;401–10.
- Baier W, Mangham C, Warnett JM, Payne M, Williams MA. Using histology to evaluate micro-CT findings of trauma in three post-mortem samples — first steps towards method validation. *Forensic Sci Int* 2019;297:27–34.
- Fröhlich C, Mettenleiter M. Terrestrial laser scanning—new perspectives in 3D surveying. In: Thies M, Koch B, Spiecker H, Weinacker H, editors. *ISPRS Archives – Volume XXXVI-8/W2 Laser-Scanners for Forest and Landscape Assessment*; 2004 Oct 3–6; Freiburg, Germany. Göttingen, Germany: Copernicus Publications, 2004;7–13.
- Matthews T, du Plessis A. Using X-ray computed tomography analysis tools to compare the skeletal element morphology of fossil and modern frog (*Anura*) species. *Palaeontol Electron* 2016;19:1–46.
- Osman MR, Tahar KN. 3D accident reconstruction using low-cost imaging technique. *Adv Eng Softw* 2016;100:231–7.
- Thali MJ, Braun M, Buck U, Aghayev E, Jackowski C, Vock P, et al. VIRTOPSY—scientific documentation, reconstruction and animation in forensic: individual and real 3D data based geo-metric approach including optical body/object surface and radiological CT/MRI scanning. *J Forensic Sci* 2005;50(2):428–42.
- Bolliger MJ, Buck U, Thali MJ, Bolliger SA. Reconstruction and 3D visualisation based on objective real 3D based documentation. *Forensic Sci Med Path* 2012;8:208–17.
- Benali L, Gromb S, Bou C. Post-mortem imaging in traffic fatalities: from autopsy to reconstruction of the scene using freely available software. *Int J Legal Med* 2013;127:1045–9.
- Shiotani S, Shiigai M, Ueno Y, Sakamoto N, Atake S, Kohno M, et al. Postmortem computed tomography findings as evidence of traffic accident-related fatal injury. *Radiat Med* 2008;26(5):253–60.
- Searle JA, Searle A. The trajectories of pedestrians, motorcycles, motorcyclists, etc., following a road accident. *Proceedings of the 27th Stapp Car Crash Conference*; 1988 Oct 17–19; San Diego, CA. Warrendale, PA: SAE International, 1988. <https://doi.org/10.4271/831622>.
- Hague D. Calculation of speed from pedestrian slide distance. In: *Proceedings of the 5th Institute of Traffic Investigators (ITAI) Conference*; 2001 Nov; York, U.K. Shrewsbury, U.K.: The Institute of Traffic Accident Investigators, 2001.
- Evans AK, Smith R. Vehicle speed calculation from pedestrian throw distance. *Proc Inst Mech Eng D* 1999;213(5):441–7.
- Sentencing Council. Causing death by careless or inconsiderate driving, 2019. <https://www.sentencingcouncil.org.uk/offences/magistrates-court/item/causing-death-by-careless-or-inconsiderate-driving/> (accessed August 8 2019).