

# Kent Academic Repository

## Full text document (pdf)

### Citation for published version

Erdelyi, Ralph-Alexandru and Duma, Virgil-Florin and Dobre, George M. and Bradu, Adrian and Podoleanu, Adrian G. H. (2020) A combination of imaging techniques for dental medicine: from X-rays radiography and 3D CBCT to OCT. In: Proceedings of Biomedical Spectroscopy, Microscopy, and Imaging. Proceedings of Biomedical Spectroscopy, Microscopy, and Imaging.

### DOI

<https://doi.org/10.1117/12.2542008>

### Link to record in KAR

<https://kar.kent.ac.uk/80814/>

### Document Version

Publisher pdf

#### Copyright & reuse

Content in the Kent Academic Repository is made available for research purposes. Unless otherwise stated all content is protected by copyright and in the absence of an open licence (eg Creative Commons), permissions for further reuse of content should be sought from the publisher, author or other copyright holder.

#### Versions of research

The version in the Kent Academic Repository may differ from the final published version.

Users are advised to check <http://kar.kent.ac.uk> for the status of the paper. **Users should always cite the published version of record.**

#### Enquiries

For any further enquiries regarding the licence status of this document, please contact:

[researchsupport@kent.ac.uk](mailto:researchsupport@kent.ac.uk)

If you believe this document infringes copyright then please contact the KAR admin team with the take-down information provided at <http://kar.kent.ac.uk/contact.html>

# PROCEEDINGS OF SPIE

[SPIDigitalLibrary.org/conference-proceedings-of-spie](https://SPIDigitalLibrary.org/conference-proceedings-of-spie)

## A combination of imaging techniques for dental medicine: from X-rays radiography and 3D CBCT to OCT

Erdelyi, Ralph-Alexandru, Duma, Virgil-Florin, Dobre, George, Bradu, Adrian, Podoleanu, Adrian G.

Ralph-Alexandru Erdelyi, Virgil-Florin Duma, George Dobre, Adrian Bradu, Adrian G. H. Podoleanu, "A combination of imaging techniques for dental medicine: from X-rays radiography and 3D CBCT to OCT," Proc. SPIE 11359, Biomedical Spectroscopy, Microscopy, and Imaging, 113591E (1 April 2020); doi: 10.1117/12.2542008

**SPIE.**

Event: SPIE Photonics Europe, 2020, Online Only, France

# A combination of imaging techniques for dental medicine: from X-rays radiography and 3D CBCT to OCT

Ralph-Alexandru Erdelyi<sup>a,b 1</sup>, Virgil-Florin Duma<sup>a,b 2</sup>,  
George Dobre<sup>c</sup>, Adrian Bradu<sup>c</sup>, Adrian Gh. Podoleanu<sup>c</sup>

<sup>a</sup>3OM Optomechatronics Group, Aurel Vlaicu University of Arad, 77 Revolutiei Ave.,  
Arad 310130, Romania

<sup>b</sup>Doctoral School, Polytechnic University of Timisoara, 1 Mihai Viteazu Ave.,  
Timisoara 300222, Romania

<sup>c</sup>Applied Optics Group, School of Physical Sciences, University of Kent,  
Canterbury, CT2 7NH, United Kingdom

## ABSTRACT

The assessment of dental issues is done nowadays both clinically and radiologically. The latter includes radiographs that are based on X-ray radiation, i.e. intraoral radiography, panoramic radiography, and three-dimensional (3D) cone beam computed tomography (CBCT). In several cases, radiographs have limitations, as they do not reveal dental issues such as small cavities, enamel cracks, or tooth erosion. These aspects can be visible with another medical imaging technique, Optical Coherence Tomography (OCT). The aim of this study is to present a few results obtained with an in-house developed swept-source OCT (SS-OCT) system on several dental issues that cannot be visible on radiographs. These results prove that OCT can be utilized in dentistry, with advantages such as radiation free technique and superior resolution. This study presents both radiography and OCT images for different dental issues which include small cavities, metal crowns cracks, or crowns manufactured with different materials (i.e., zirconia, ceramics, or composite). Firstly, samples have been analyzed radiologically and some abnormalities could be detected, but they could be correctly assessed. Secondly, these abnormalities have been analyzed with the SS-OCT system and finally all images and collected data from both medical imaging techniques have been compared. One of the conclusions is that OCT is more appropriate than radiography for several dental issues such as those presented in this study. These two medical imaging techniques can therefore be complementary in dental medicine.

**Keywords:** dental radiography, optical coherence tomography (OCT), optical measurements, image characterization, X-ray radiation, dental imaging, Cone Beam Computed Tomography (CBCT).

## 1 INTRODUCTION

A major impact on the success of dental treatment is influenced by the very beginning diagnosis phase. In dentistry a correct diagnosis is provided nowadays by a clinical and imaging investigation [1-4]. The most utilized medical imaging techniques in dentistry are based on X-ray radiation, which has ionizing effects; this is a disadvantage of the technique.

Both two-dimensional (2D) investigations (intraoral and panoramic radiographs) and three-dimensional (3D) investigations, i.e. cone beam computed tomography (CBCT) are utilized. Differences exist regarding the level of details provided by each type of radiograph. For example, connections between an implant and laboratory components are not visible on a 3D CBCT, even if the resolution and the image quality for 3D CBCT is superior to that of intraoral and panoramic radiographs. There are also situations in which radiology is not enough, therefore the dentist cannot utilize radiographs for both diagnose and treatment because they are not reliable. In this case, other medical imaging techniques could provide those images that are needed to correctly assess a dental issue or the work of the dentist-after treatment.

---

<sup>1</sup> Email: [ralph.erdelyi@student.upt.ro](mailto:ralph.erdelyi@student.upt.ro);

<sup>2</sup> Email: [duma.virgil@osamember.org](mailto:duma.virgil@osamember.org); phone: +40-751-511451; sites: <http://3om-group-optomechatronics.ro/>;  
<https://www.researchgate.net/lab/3OM-Optomechatronics-Group-Virgil-Florin-Duma>

Considering dental issues, one should always choose the medical imaging technique that reveals them in detail, to have them correctly assessed by the dentist.

OCT is an imaging technique that does fit this description [5-8]. It is useful when the region of interest is at the surface or near the surface of the investigated sample [6-9], because of the limited (up to 1-2 mm) penetration depth of OCT. Such cases include teeth (with small cavities, enamel damage, or incorrect adaptation), dental crowns/prosthesis, as well as implants, i.e. metallic surfaces investigations [10,11]. It is well-known that OCT has lower penetration power than other techniques; despite this, OCT has the advantage of not exposing the patient to ionizing radiation, as it is using solely non-invasive IR radiation.

These are the differences between techniques when the main interest is the amount of information gathered from the final image. The aim of this study is to find a way to correlate a technique with another, as well as to compare the techniques between them. Our hypothesis is that radiology alongside OCT could provide all the images required by a dental clinic.

This study is realized by investigating several extracted teeth and dental crowns (manufactured from different materials) with both types of medical imaging techniques. Teeth have been extracted from different patients and they belong to different types, from incisive to molars. All samples have been obtained from 'Dental Experts', a dental clinic situated in Timisoara, Romania. The radiological investigations have also been performed in this dental clinic. The Laboratory of Optomechatronics and Biomedical Photonics from the 'Aurel Vlaicu' University Arad is equipped with the in-house developed SS-OCT system, Master-Slave (MS) enhanced [12], utilized to investigate teeth and other samples using the OCT method. Results from several relevant cases are presented and specific conclusions are extracted.

## 2 MATERIALS AND METHODS

### 2.1. Radiology

Intraoral radiographs presented in this study have been performed with *Gendex Oralix (Danaher Corporation, Washington DC, United States)* at 68 kV, 9 mA, with a 0.8 s exposure time, in order to avoid to over/underexpose the photostimulable phosphor plate (PSP), which is the X-ray detector in this case. The PSP was furthermore processed, with the aim to obtain a high-quality intraoral radiography.

Panoramic radiographs alongside 3D CBCT have been performed with *Planmeca ProMax 3D Plus (Planmeca, Helsinki, Finland)* [13], at 72 kV, 11 mA, with a 15 s exposure time for panoramic, and 90 kV, 11 mA, with a 5 s exposure time for 3D CBCT.

The X-ray equipment was properly calibrated, with the maximum achievable resolution of 75  $\mu\text{m}$  at the smallest amount of X-ray radiation [14,15], with the purpose of obtaining images that can be used by dentists for diagnose or treatment assessment. The panoramic radiographs, 3D CBCT, and some of intraoral radiographs presented in this study have been performed on real patients. The cases selected are dental crowns/fillings adaptation [16], early stage cavities and enamel defects [17], dental cavities [18], and bone diseases [19,20]). Teeth obtained from the patients were extracted because of medical reasons and not for realizing this study.

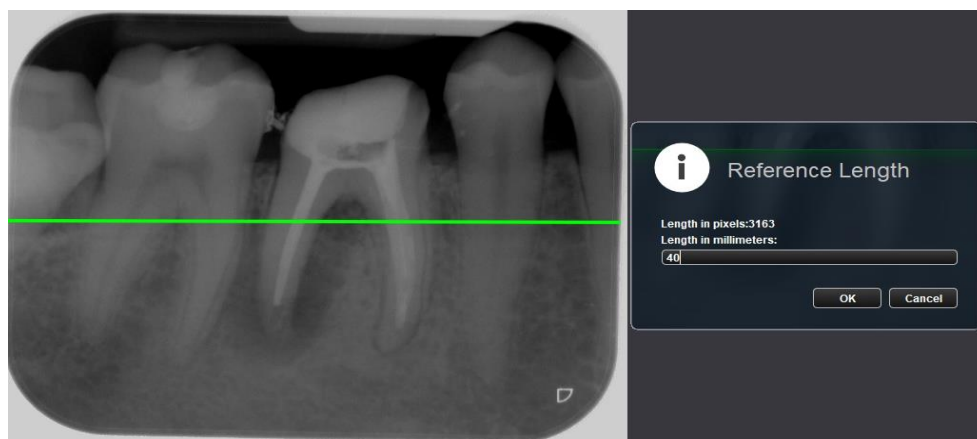

Figure 1. Calibrating images imported in the Romexis software.

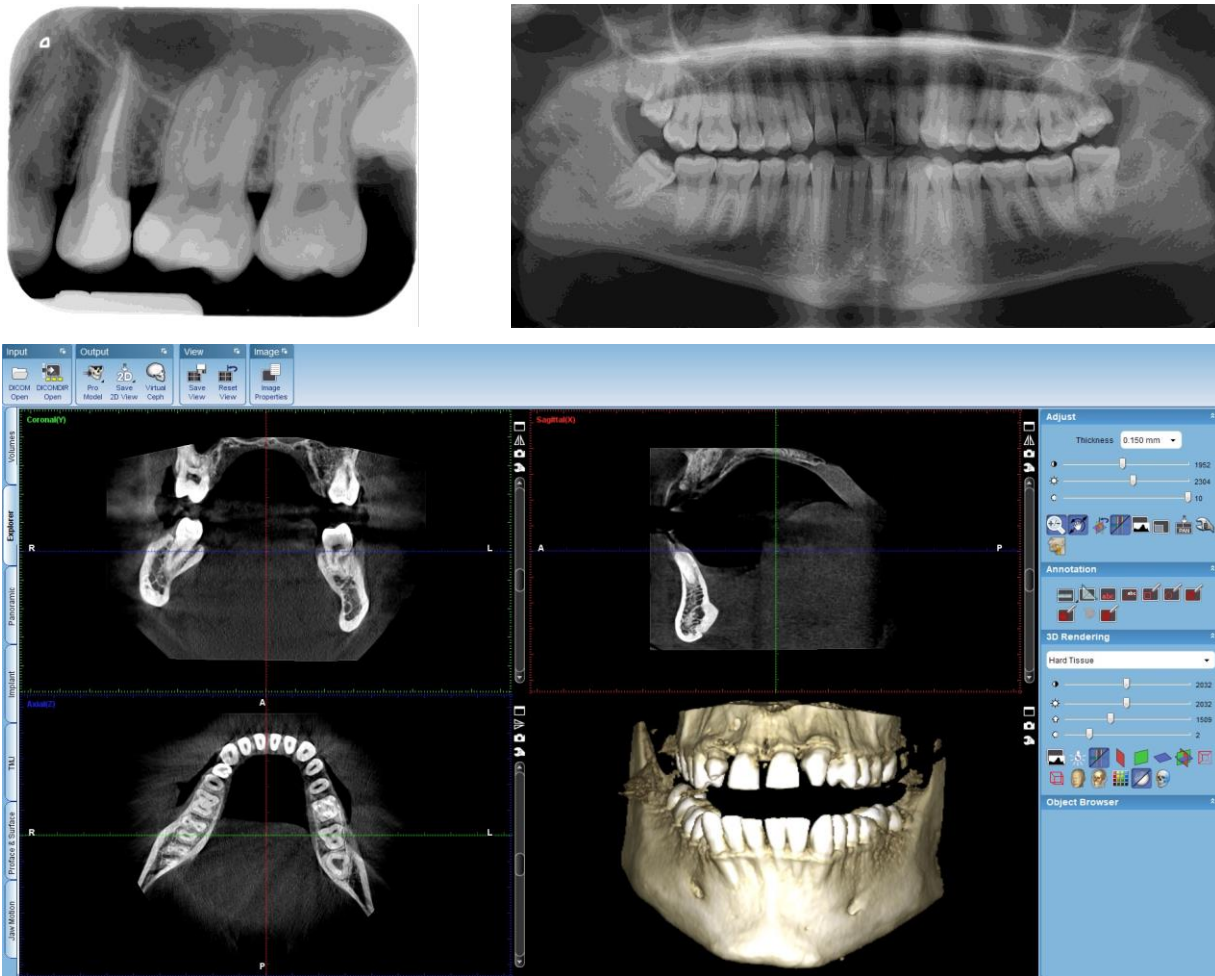


Figure 2. Examples of intraoral radiographs, panoramic radiographs, as well as 3D CBCT images obtained with the X-ray equipment available.

The extracted teeth have been cleaned and furthermore prepared for both X-ray and OCT investigations. In addition to X-ray equipment, which is constituted by a X-ray unit, a reconstruction PC and a work-station, the Romexis software (*Planmeca, Helsinki, Finland*), installed on the work-station contains all the tools needed for the assessment of obtained radiographs. It also allows users to import other medical images that must be assessed, but only after a correct calibration, as described in Fig. 1.

## 2.2. OCT

The in-house developed SS-OCT utilized to investigate samples has been described in detail in [21]. The utilized PC is equipped with an in-house developed software.

When all OCT images are collected (500 B-scans/2D cross-sections), they are further analyzed with the ImageJ open source image processing software (Wayne Rasband, NIH/LOCI, University of Wisconsin). The 500 OCT B-scans can also be rendered into a 3D image/volumetric reconstruction. To assess OCT images, the OCT B-scans selected from ImageJ while the sample is investigated are imported in the Romexis Software. All measurements for both radiographs and OCT images are realized in this latter software because in this way all images are passing through the same process of calibration. The workflow of an such assessment consists of three steps: import of the image, its calibration, and measurement of issues

that appear on the image. In some cases, issues discovered on images do not have to be measured. They must only be observed and evaluated, for example in the case of correct adaptations of the filling/crown. Digital intraoral radiography is the daily basis method nowadays for assessing this adaptation [22], but OCT, besides being radiation free and more accurate, provide in addition volumetric reconstruction of the analyzed sample.




Figure 3. Examples of OCT images of teeth surfaces: (a) B-scan, (b) volumetric/3D reconstruction.

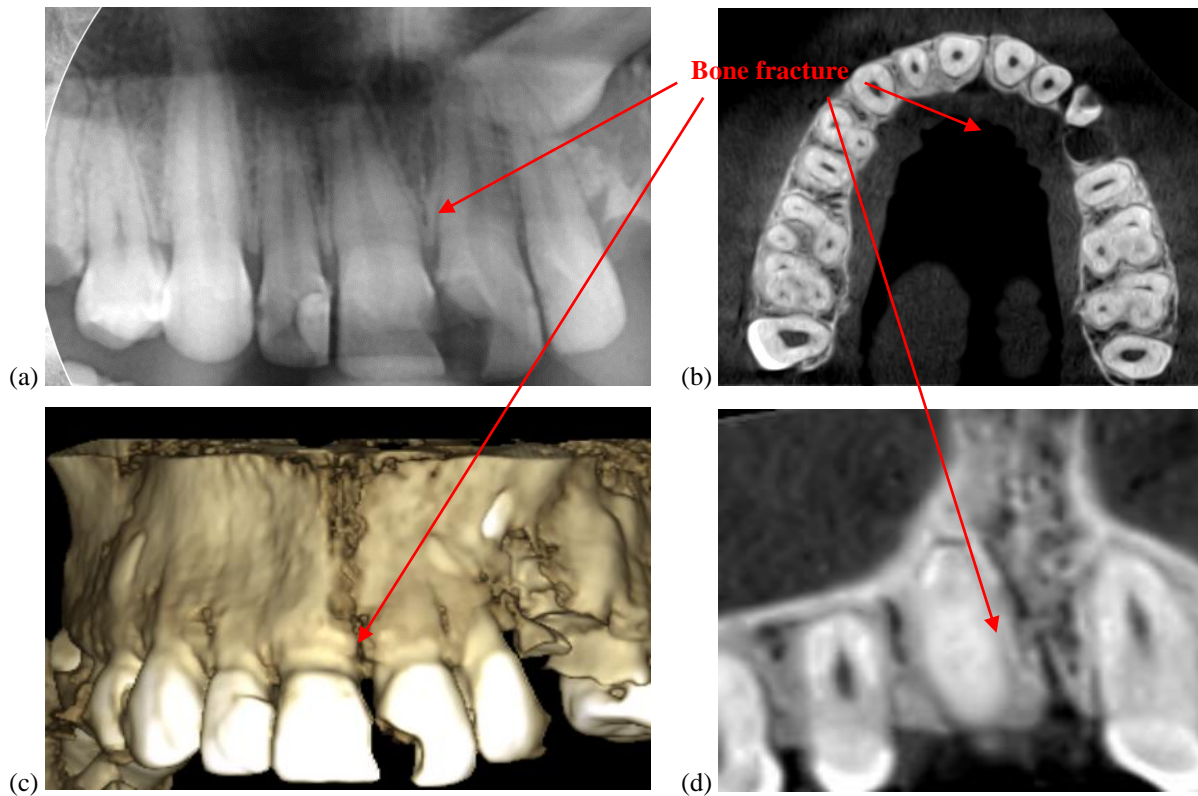


Figure 4. Images of maxillary fracture: (a) section of a panoramic radiography, (b) Axial view (on the z-axis) from 3D CBCT, (c) volumetric reconstruction, and (d) coronal view (on the y-axis) from 3D CBCT.

The maximum area of investigation is 5 x 5 mm of the probe. The axial resolution provided by OCT technique is 10  $\mu\text{m}$ , which is 7.5 times better than 3D CBCT, where the best-achievable resolution obtained with the Planmeca X-ray unit (but only after careful calibration [14]) is 75  $\mu\text{m}$ . The penetration depth of the SS-OCT system utilized for this study is around 1.5 mm. This means that the maximum volume rendered has the maximum dimensions of 5 x 5 x 2 mm. These dimensions are important when the OCT B-scan is calibrated in the Romexis software (Fig. 1).

### 3 RESULTS

#### a) Bone assessment: fractures (Fig. 4); density (Fig. 5)

In dentistry investigations, there are hard tissue (bone and teeth) and soft tissue (i.e. gingiva, tongue, lips, buccal and vestibular mucosa, etc.). Some dental issues are related not only to teeth, but also to bone. There are bone diseases that have to be investigated, such as cysts, tumors or bone lesions, infections, and periodontitis. For all these bone issues, panoramic radiography is appropriate for spotting them, and 3D CBCT is the best method to assess them, because of the volumetric information available only with this type of medical investigation. OCT offers volumetric information as well, but the fact that its penetration power is limited to 1-2 mm makes OCT technique insufficient for bone issues.

In the case of small cavities or secondary cavities, OCT provides exact information about the dimensions of the cavities, while on radiographs cavities cannot be accurately measured, not even detected. Some examples about this can also be found in previous studies [9,23,24]. In addition to small cavities and secondary cavities, large cavities are also hard to assess when it comes to exact dimensions. It is important to know the exact dimensions of cavities because, taking into account this aspect the treatment can vary. For example, if the cavity is so deep that it goes into the pulp cavity or close to it, the treatment must include root canal. In case of a cavity with a smaller depth, the treatment just includes a dental filling.

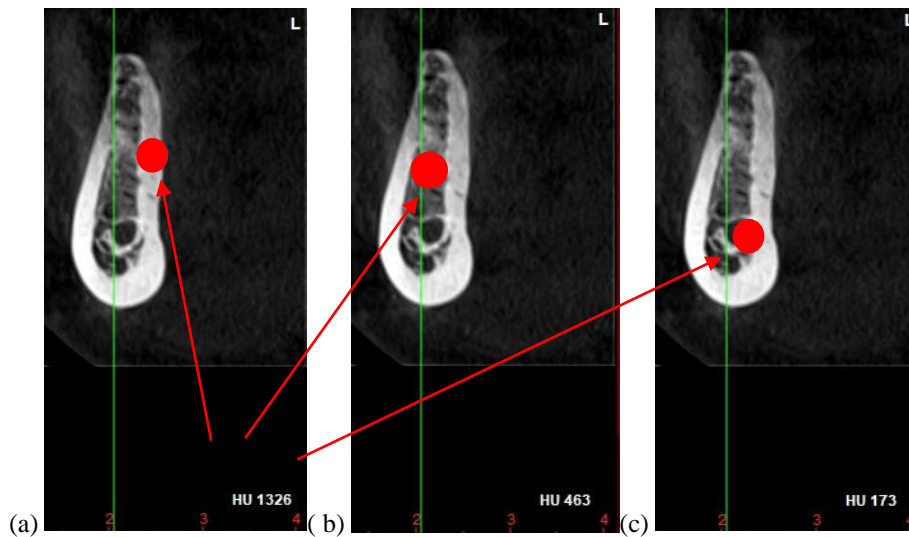


Figure 5. Images of bone density measured in Hounsfield Units: (a) compact bone density, (b) spongy bone density, (c) nerve canal density.

#### b) Cavities assessment – Fig. 6

#### c) Demineralization/enamel damage – Fig. 7

Tooth demineralization or enamel damage are other dental issues which are not visible on any type of radiograph. OCT can however spot these issues. In addition to this advantage, images obtained with OCT have such a quality in terms of resolution that such aspects can be detected in early stages.

#### d) Treatment assessment – Figs. 8 and 9

In the interest of assessing the treatment completed by a doctor, medical imaging methods are also utilized. In dentistry, the cases where images are achieved after a treatment usually occur after surgical interventions (for example implant insertion or bone augmentation), root canal, some dental fillings, or dental prosthetic cases.

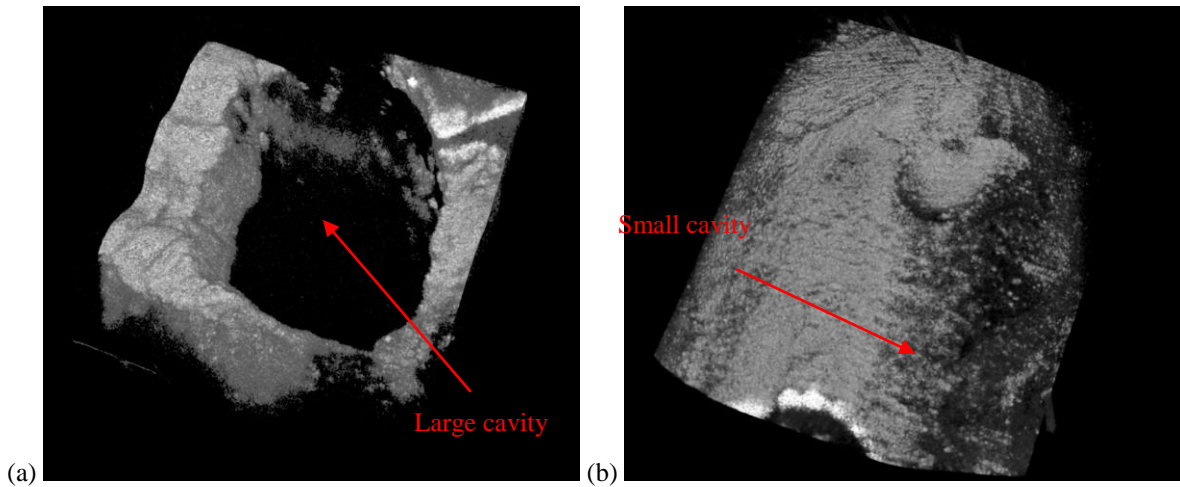


Figure 6. OCT volumetric reconstruction for: (a) a large cavity, (b) a small cavity.

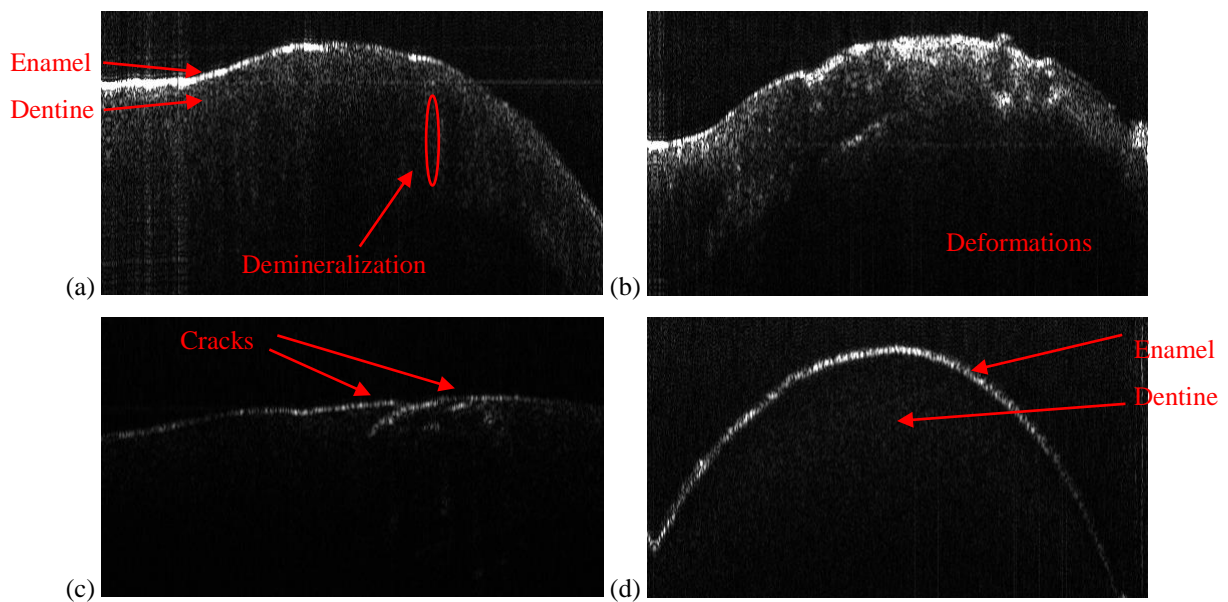


Figure 7. OCT B-Scans of: (a) a demineralized tooth, (b) a tooth with enamel deformations and dentine abnormalities, (c) a tooth with enamel cracks, and (d) a healthy tooth.

Because implants are made of titanium alloys, post-operative images can be obtained only radiologically. OCT cannot penetrate deep enough in gingiva and bone for images of the inserted implant to be taken.

When it comes to adaptation assessments of the dental crowns or dental fillings, because of its higher resolution, OCT offers better images than radiographs.



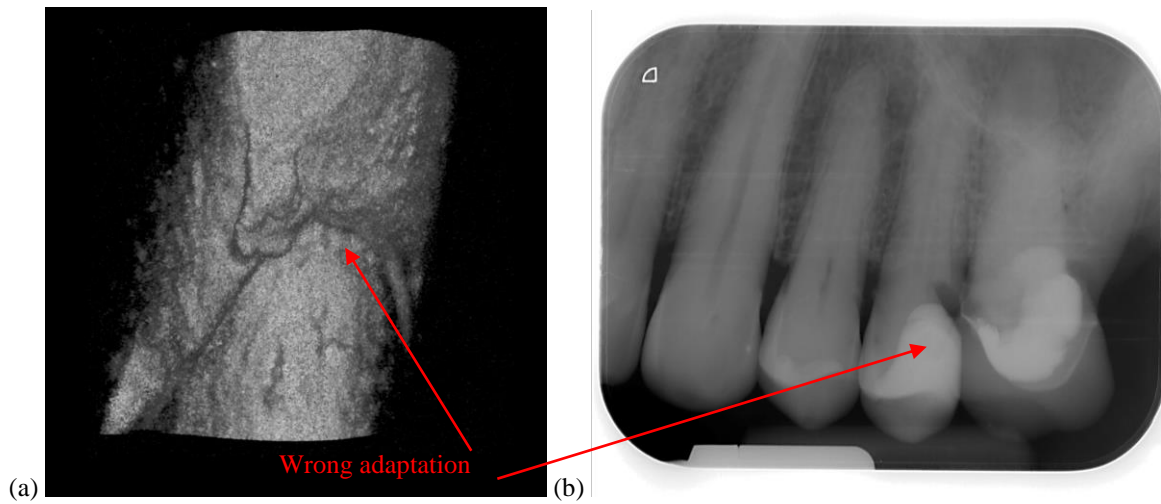


Figure 8. Examples of wrong adaptation: (a) OCT volumetric reconstruction, (b) intraoral radiography.

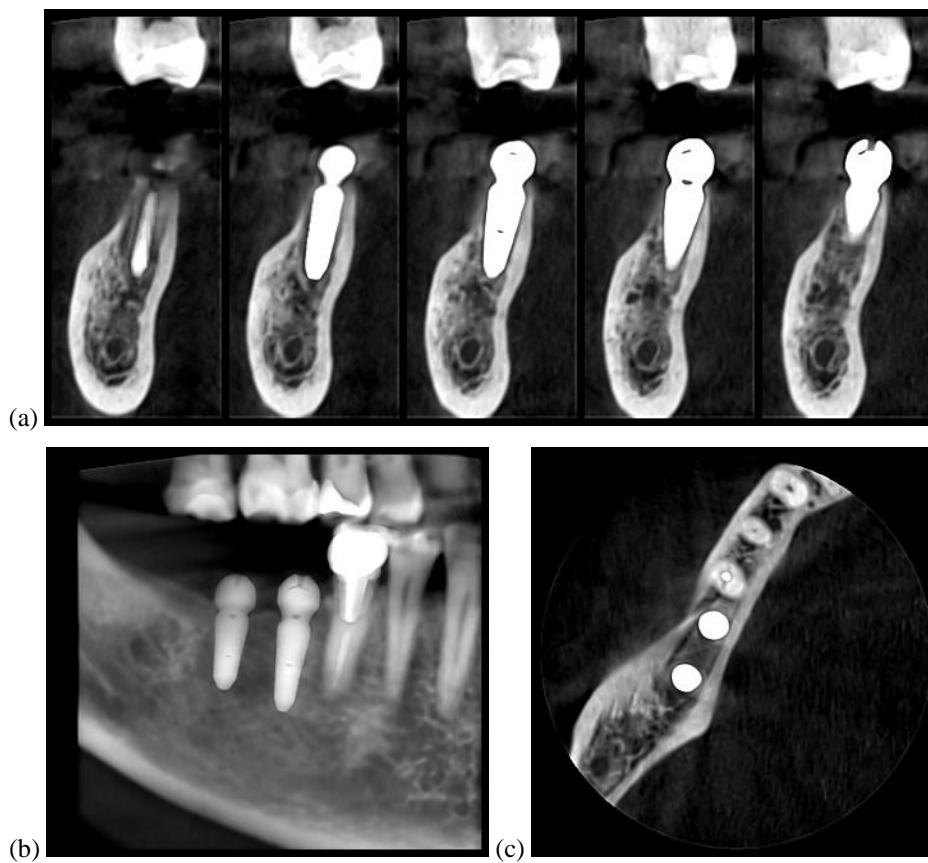


Figure 9. 3D CBCT after implant insertion on different views: (a) implant, (b) panoramic, (c) axial.

#### 4 DISCUSSION AND CONCLUSIONS

In Tab. 1 one can see a few differences between the information provided by radiology and OCT in different aspects of dental medicine.

On the other hand, as it can be seen in Tab. 2 as a conclusion of this study, OCT and radiography are complementary. Radiographs are appropriate for imaging large areas and to image inside hard tissue, while OCT offers high-quality resolution for small investigated areas. OCT can also be used when radiographs cannot provide any information (i.e., tooth demineralization, cracks, or small cavities).

Table 1. Some differences between 2D radiographs, 3D CBCT, and OCT.

Type of sample or dental case	2D Radiographs	3D CBCT	OCT
Small cavities	Barely detectable on intraoral radiographs	Not visible	Correct assessment of small cavities
Metal crowns	Good contrast. Some defects may be missed	In cases with a thick crown, artefacts may appear	Suitable for checking the crown for defects
Orthodontics	Not revealing needed information	Not revealing needed information	Numerous enamel defects can be assessed
Maxillary and mandible bone fractures	Issues are detected	Issues are correctly assessed	Not enough penetration power to observe the fracture

Table 2. Suitable medical imaging technique for dentistry in several cases.

Case	Situation	RX intraoral	Panoramic	3D CBCT	OCT
<b>Bone assessment</b>	fractures	Bad	Bad	Excellent	Bad
	density	Bad	Bad	Medium	Good
<b>Cavities assessment</b>	Small/secondary	Good	Medium	Bad	Excellent
	Large	Good	Medium	Medium	Excellent
<b>Enamel damage</b>	Demineralization/small cracks	Bad	Bad	Bad	Excellent
<b>Soft tissue assessment</b>	Periodontitis	Good	Good	Good	Bad
	Damage gingiva	Bad	Bad	Bad	Excellent
<b>Treatment assessment</b>	Implants	Good	Good	Excellent	Bad
	Root canal	Excellent	Good	Good	Bad
	Adaptation (crowns/fillings)	Good	Good	Bad	Excellent

Apart from the present study, other medical issues than those analyzed here can be investigated with both OCT and radiographs. Our research group, alongside the dental clinic, is working on dental implants, radio-opacity, as well as different types of materials utilized for dental crowns. Development of handheld scanning probes for OCT systems is also subject of previous and future work [21,25], to be able to obtain results *in vivo*, in dental offices.

In conclusion, the results presented in this study prove that OCT has advantages (radiation-free technique and superior resolution), as well as the capability of being utilized in dentistry. Also, results from another related study on OCT in dentistry [7] prove that this imaging technique could be utilized alongside radiographs as a daily-basis technique and that OCT can be useful by both dentists and dental technicians [26,27].

## ACKNOWLEDGEMENTS

This work was funded by the European Union through the European Regional Development Fund under the Competitiveness Operational Program (BioCell-NanoART = Novel Bio-inspired Cellular Nano-architectures, POC-A1-A1.1.4-E nr. 30/2016), as well by the Romanian National Authority for Scientific Research, CNDI–UEFISCDI project PN-III-P2-2.1-PTE-2016-181 (<http://3om-group-optomechatronics.ro/>). The support of the Polytechnic University of Timisoara, through its Doctoral School Program, for the participation at the Conference, is also gratefully acknowledged.

## REFERENCES

- [1] Jung, R. E., Schneider, D., Ganeles, J., Wismeijer, D., Zwahlen, M., Hammerle, C. H., Tahmeseb, A., “Computer Technology Applications in Surgical Implant Dentistry: A Systematic Review,” *The International J. of Oral & Maxillofacial Implants*, 24, 92-109 (2009).
- [2] Garg, A. K., Vicari, A., Radiographic modalities for diagnosis and treatment planning in implant dentistry, *The Implant Society* 5(5), 7-11 (1995).
- [3] İplikçioğlu, H., Akça, K., Çehreli, M. C., “The Use of Computerized Tomography for Diagnosis and Treatment Planning in Implant Dentistry,” *J Oral Implantol.* 28(1), 29-36 (2002).
- [4] Guerrieri, A., Gaucher, C., Bonte, E., et al., “Minimal intervention dentistry: part 4. Detection and diagnosis of initial caries lesions,” *Br. Dent. J.* 213, 551-557 (2012).
- [5] Huang, D., Swanson, E. A., Lin, C. P., Schuman, J. S., Stinson, W. G., Chang, W., Hee, M. R., Flotte, T., Gregory, K., Puliafito, C. A. and Fujimoto, J. G., “Optical coherence tomography,” *Science* 254(5035), 1178-1181 (1991).
- [6] Drexler, W., Liu, M., Kumar, A., Kamali, T., Unterhuber, A., Leitgeb, R. A., “Optical coherence tomography today: speed, contrast, and multimodality,” *J. Biomed. Opt.* 19, 071412 (2014).
- [7] Hsieh, Y.-S., Ho, Y.-C., Lee, S.-Y., Chuang, C.-C., Tsai, J., Lin, K.-F., and Sun, C.-W., “Dental Optical Coherence Tomography,” *Sensors* 13, 8928-8949 (2013).
- [8] Otis, L., Everett, M. J., Sathyam, U.S., Colston Jr., B. W., “Optical Coherence Tomography: A New Imaging: Technology for Dentistry,” *The J. of the American Dental Association* 131(4), 511-514 (2000).
- [9] Canjau, S., Todea, C., Negrutiu, M. L., Sinescu, C., Topala, F. I., Marcauteanu, C., Manescu, A., Duma, V.-F., Bradu, A., Podoleanu, A., “Optical Coherence Tomography for Non-Invasive ex vivo Investigations in Dental Medicine - a Joint Group Experience (Review),” *Modern Technologies in Medicine* 7(1), 97–115 (2015).
- [10] Hutiu, Gh., Duma, V.-F., Demian, D., Bradu, A., Podoleanu, A., “Surface imaging of metallic material fractures using optical coherence tomography,” *Applied Optics* 53(26), 5912-5916 (2014).
- [11] Hutiu, Gh., Duma, V.-F., Demian, D., Bradu, A., Podoleanu, A., “Assessment of ductile, brittle, and fatigue fractures of metals using optical coherence tomography,” *Metals* 8(2), 117 (2018).
- [12] Podoleanu, A., Bradu, A., Master–slave interferometry for parallel spectral domain interferometry sensing and versatile 3D optical coherence tomography, *Opt. Express* 21, 19324-19338 (2013).
- [13] Imaging Manual, “en 3D s/Classic with ProTouch”, 21.05.2019, <https://materialbank.planmeca.com/> (20.09.2019).
- [14] Erdelyi, R. A., Duma, V.-F., “Optimization of radiation doses and patients’ risk in dental radiography”, *AIP Proceedings* 2071, 040013 (2019).
- [15] Poppe, B., Looe, H. K., Pfaffenberger, A., Chofor, N., Eenboom, F., Sering, M., Rühmann, A., Poplawski, A., Willborn, K., “Dose-area product measurements in panoramic dental radiology,” *Radiation Protection Dosimetry* 123(1), 131-134 (2007).
- [16] Alshahni, R. Z., Shimada, Y., Zhou, Y., Yoshiyama, M., Sadr, A., Sumi Y., and Tagami, J., “Cavity adaptation of composite restorations prepared at crown and root: Optical assessment using SS-OCT,” *Dental Materials Journal* (2019).
- [17] Ko, A. C.-T., Choo-Smith, L.-P., Hewko, M. D., Leonardi, L., Sowa, M. G., Dong, C. C. C. S., Williams, P., Cleghorn, B., “Ex vivo detection and characterization of early dental caries by optical coherence tomography and Raman spectroscopy,” *J. of Biomed. Opt.* 10(3), 031118 (2005).
- [18] Amaechi, B. T., Higham, S. M., Podoleanu, A. G., Rogers, J. A., Jackson, D. A., “Use of optical coherence tomography for assessment of dental caries: quantitative procedure,” *Journal of Oral Rehabilitation* 28(12), 1092-1093 (2001).

- [19] Tyndall, D. A., Rathore, S., "Cone-Beam CT Diagnostic Applications: Caries, Periodontal Bone Assessment, and Endodontic Applications", *Dental Clinics of North America* 52 (4), 825-841 (2008).
- [20] Cassetta, M., Stefanelli, L.V., Pacifici, A., Pacifici, L., Barbato, E., "Bone Density Assessment," *Clinical Implant Dentistry and Related Research* 16, 471-478 (2014).
- [21] Duma, V.-F., Dobre, G., Demian, D., Cernat, R., Sinescu, C., Topala, F. I., Negrutiu, M. L., Hutiu, Gh., Bradu, A., Podoleanu, A. Gh., "Handheld scanning probes for optical coherence tomography," *Romanian Reports in Physics* 67(4), 1346-1358 (2015).
- [22] Versteeg, C. H., Sanderink, G. C. H., van der Stelt, P. F., "Efficacy of digital intra-oral radiography in clinical dentistry," *J. of Dentistry* 25(3-4), 215-224 (1997).
- [23] Oancea, R., Bradu, A., Sinescu, C., Negru, R. M., Negrutiu, M. L., Antoniac, I., Duma, V.-F., Podoleanu, A., "Assessment of the sealant/tooth interface using optical coherence tomography," *J. of Adhesion Science and Technology* 29(1), 49-58 (2015).
- [24] Erdelyi, R. A., Duma, V.-F., Dobre, G., Bradu, A., Podoleanu, A., "Investigations of dental cavities: between X-ray radiography and OCT," *Proc. SPIE* 11385, 1138504 (2019).
- [25] Demian, D., Duma, V.-F., Sinescu, C., Negrutiu, M. L., Cernat, R., Topala, F. I., Hutiu, Gh., Bradu, A., Podoleanu, A., "Design and testing of prototype handheld scanning probes for optical coherence tomography," *Proc. of the Institution of Mechanical Engineers, Part H: J. of Eng. in Medicine* 228(8), 743-753 (2014).
- [26] Duma, V.-F., Sinescu, C., Bradu, A., Podoleanu, A., "Optical Coherence Tomography Investigations and Modeling of the Sintering of Ceramic Crowns," *Materials* 12(6), 947 (2019).
- [27] Luca, R., Todea, C. D., Duma, V.-F., Bradu, A., Podoleanu, A., "Quantitative assessment of rat bone regeneration using complex master-slave optical coherence tomography," *Quantitative Imaging in Medicine and Surgery (QIMS)* 9(5), 782-798 (2019).