

## Hepato Cellular Carcinoma: Case Report

Henri Kolani<sup>1\*</sup>, Islam Mamica<sup>1</sup>, Manser Çili<sup>1</sup>, Leart Berdica<sup>1</sup>, Etmond Çeliku  
*University Hospital Center "Mother Theresa", Tirana, Albania, Albania*

*\*Corresponding author: [henri.kolani@yahoo.com](mailto:henri.kolani@yahoo.com)*

### Abstract

Hepatoma is a tumoral disease that consists in an abnormal proliferation of the hepatic cells. According to the augmentation of the risks factors such as smoking, alcohol abuse, consuming no healthy food and different types of viral and bacterial infections. Nowadays, this disease is becoming more evident even in the young ages. Here, we present a 63 old female with this disease.

**Keywords:** *Hetapoma, tumoral, disease*

**DOI:** 10.7176/ALST/78-06

**Publication date:** March 1<sup>st</sup> 2020

### Introduction

Hepatoma is malignant disease that is also known as hepatocarcinoma ( HCC ) and is one of the most expressed tumoral disease of liver. It is seen a strong correlation between hepatocarcinoma and other chronic liver disease such as Hepatitis B, C, diabetes mellitus type 2, or cirrhosis etc.

Also is evidenced that being exposed to harmful factors such as alcohol abuse or being malnourished and with hypercaloric diet mainly in cholesterol and triglycerides ( that cause the fat's accumulation in liver ) can bring an augmentation of Hepato cellular carcinoma disease. However, this disease is very similar in appearance with the metastasis that originates from the other organs such as colon, stomach etc.

Most cases are treated with surgical resection and chemotherapy, but the prognosis is not very hopeful.

### Case report

Here, we present a 63 years old woman with a poor symptomatic clinic. She referred light pain located in the dexter hypochondriac region of abdomen for about 6 months. Also she referred for weight reduction during the last 2 months and reduction of orexia. The feeling of being tired was becoming more and more evident and present day after day.

A physical examination performed on her, did not show to us anything special except a little bit abdominal pain mainly in the dexter hypochondriac region during a deep breathing. The others regions of abdomen were quiet and without muscular defense.

An abdominal echography and thoraco/abdominal CT scan showed us a big neoformation (Ø48-51 mm ), located in the VII segment of hepar and infiltration of V and VIII segments.

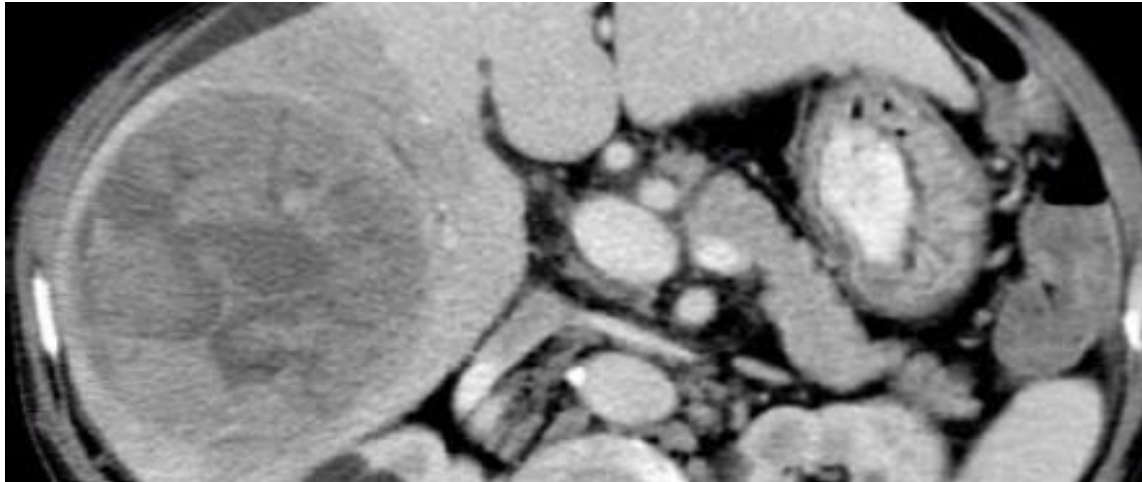


Fig.1. Liver Neof ormation

According to the examinations we decided for a surgical treatment and realized a rezection of right lobe of liver.

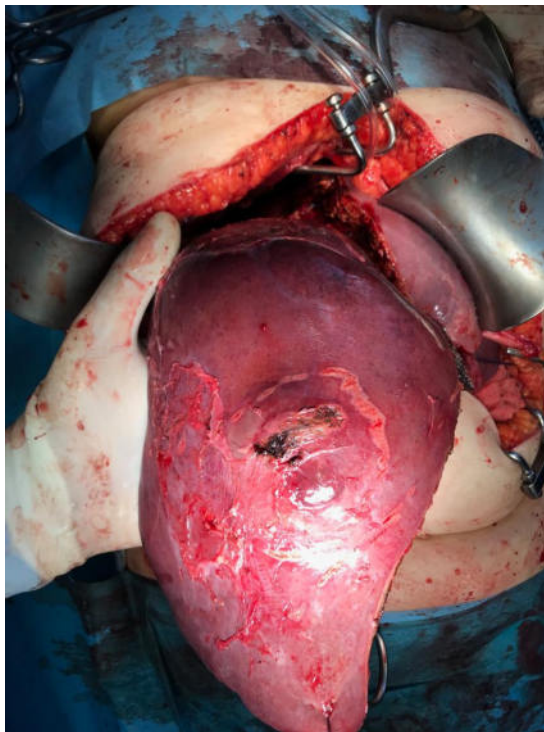


Fig.2 Lobectomy dexter

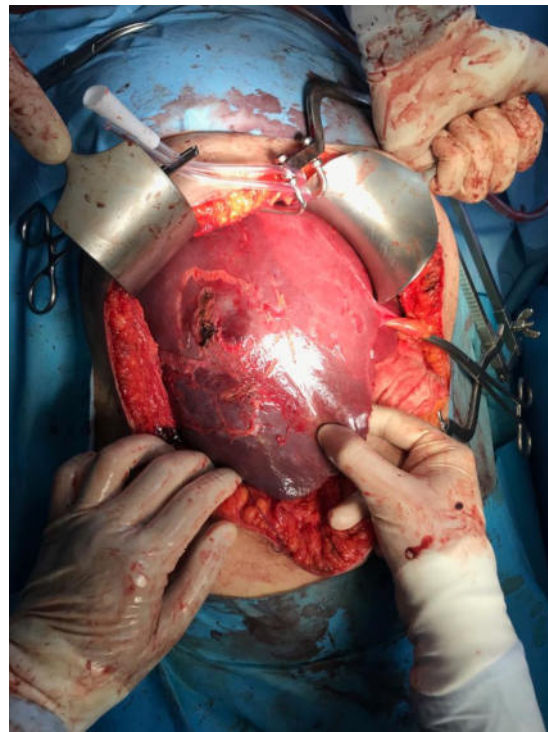


Fig.3. Liver Neof ormation

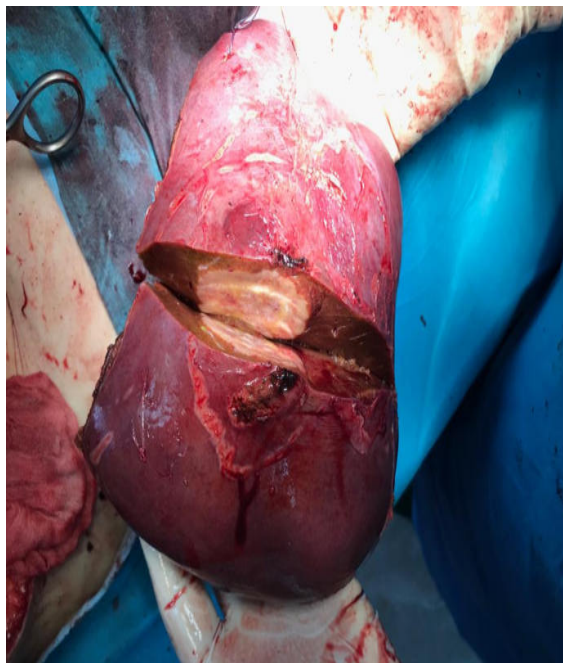


Fig.4 Liver Neoformation

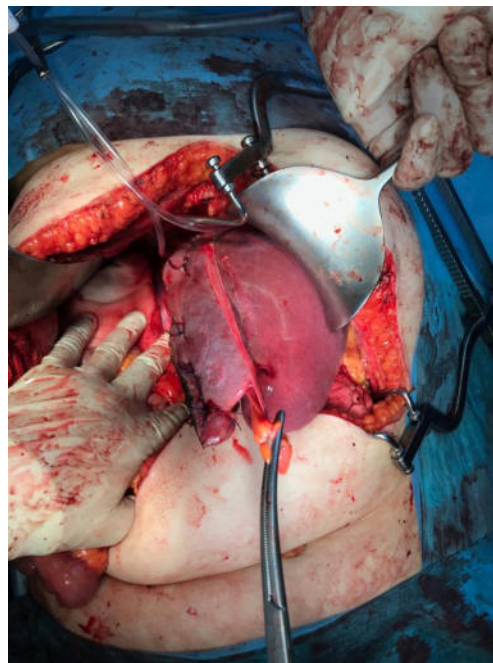


Fig.5.Lobectomy dexter

## Discussion

Surgery rests as therapy of choice in patients with a minor, restricted number of tumor nodules. Up to date, no preoperative treatment has been validated useful. Adjuvant treatments involving systemic chemotherapy, intra-arterial infusion, or chemoembolization failed to increase survival, while immune therapy, retinoids, radiolabeled isotopes, and antiangiogenic agents appear encouraging. Systemic therapy with cytotoxic agents remains disappointing as to recent data.

## Conclusion

Hepatocarcinoma is very malignant disease that interests the liver and beyond, including physiological reactions processes and with a high spread metastasis to other organs as well. A surgical approach along with chemotherapy was the most suitable management approach in this case. That we do have today the patient alive with clinical health aspects improved.

## References

1. Gbolahan, Olumide B.; Schacht, Michael A.; Beckley, Eric W.; LaRoche, Thomas P.; O'Neil, Bert H.; Pyko, Maximilian (April 2017). "Locoregional and systemic therapy for hepatocellular carcinoma". *Journal of Gastrointestinal Oncology*
2. El-Serag HB; Hampel H; Javadi F (2006). "the association between diabetes and hepatocellular carcinoma: a systematic review of epidemiological evidence". *Clinical Gastroenterology and Hepatology*. 4 (3): 369–380

3. Donadon V, Balbi M, Ghersetti M, et al. (2009). "Antidiabetic therapy and increased risk of hepatocellular carcinoma in chronic liver disease". *World Journal of Gastroenterology*.
4. Heimbach, Julie K.; Kulik, Laura M.; Finn, Richard; Sirlin, Claude B.; Abecassis, Michael; Roberts, Lewis R.; Zhu, Andrew; Murad, M. Hassan; Marrero, Jorge (2017-01-01). "Aasld guidelines for the treatment of hepatocellular carcinoma". *Hepatology*
5. El-Serag HB, Marrero JA, Rudolph L, Reddy KR (May 2008). "Diagnosis and treatment of hepatocellular carcinoma". *Gastroenterology*.
6. Thomas M, Zhu A (2005). "Hepatocellular carcinoma: the need for progress". *Journal of Clinical Oncology*. **23** (13): 2892–9. doi:10.1200/JCO.2005.03.196. PMID 15860847.