



Efficacy of electrical Russian current stimulation after end-to-side neurorrhaphy of the common fibular nerve: electroneuromyography and muscle strength analysis

Eficácia da estimulação elétrica com corrente russa após neurografia término-lateral do nervo fibular comum: análise electroneuromiográfica e de força muscular

Eficacia de la estimulación eléctrica con la corriente rusa tras la neurografia término-lateral del nervio fibular común: análisis electroneuromiográfico y de fuerza muscular muscular

Mariana Moreno Gabira¹, Geraldo Marco Rosa Junior², Guilherme Eleutério Alcalde³, Cleber Ferraresi⁴, Luis Henrique Simionato⁵, Carlos Henrique Fachin Bortoluci⁶

ABSTRACT | Peripheral nerve injury leads to a high functional loss of muscle tissue. Thus, many studies have investigated surgical techniques, such as neurorrhaphies, and therapeutic resources, such as electrical stimulation, to improve the functionality of reinnervated muscle after peripheral injury. This study aims to investigate the effects of electrical stimulation with Russian Current (2,500Hz, 4ms, 10:20 sec contraction/relaxation, modulated at 10Hz and 100Hz) in the functional recovery after section and end-to-side neurorrhaphy of the peroneal nerve distal stump common to the lateral face of the tibial nerve in rats. In this study, 25 male Wistar rats with 80 days of life were used, provided by the Universidade Sagrado Coração (USC), Bauru, SP, Brazil. The animals were randomly divided into five groups: Initial Control Group (ICG), Final Control Group (FCG), Untreated Experimental Group (UEG), End-to-Side Neurorrhaphy with Russian Stimulation Group (ENRSG), and Denervated Control Group (DCG). The Russian Current was started 5 days after neurorrhaphy and applied to the cranial tibial muscle of the ENRSG, 3 times a week, totaling 36 sessions. We observed that the electrical stimulation with Russian Current (ENRSG) was effective to increase amplitude (mV) and to decrease the latency (ms) of the reinnervated muscle, besides

increasing the muscle strength when compared with the denervated control group. Therefore, we concluded that the average frequency electrical stimulation (Russian current) was efficient in the functional recovery of the cranial tibial muscle after the end-lateral neurorrhaphy of the common fibular nerve.

Keywords | Electric Stimulation; Transcutaneous Electric Nerve Stimulation; Rats, Wistar; Peroneal Nerve.

RESUMO | Lesões de nervos periféricos levam a perda funcional elevada no tecido muscular. Assim, muitas pesquisas têm investigado técnicas cirúrgicas, como neurografias, e recursos terapêuticos, como eletroestimulação, para melhorar a funcionalidade de um músculo reinervado após lesão periférica. Este estudo tem como objetivo investigar os efeitos da eletroestimulação com corrente russa (2.500Hz, 4ms, 10 seg. de contração por 20 seg. de relaxamento, modulação de 10Hz e 100 Hz) na recuperação funcional após secção e neurografia término-lateral do coto distal do nervo fibular comum à face lateral do nervo tibial em ratos. Foram utilizados 25 ratos Wistar, machos, com 80 dias de vida, fornecidos pelo Biotério Central da Universidade Sagrado Coração (Bauru, SP, Brasil).

¹Universidade do Sagrado Coração (USC) – Bauru (SP), Brazil. E-mail: marianagabira17@gmail.com. Orcid: 0000-0003-1330-3740

²Universidade do Sagrado Coração (USC) – Bauru (SP), Brazil. E-mail: geraldo.junior@usc.br. Orcid: 0000-0003-1787-3396

³Universidade do Sagrado Coração (USC) – Bauru (SP), Brazil. E-mail: geafisio@hotmail.com. Orcid: 0000-0002-5505-4378

⁴Universidade Brasil (UB) – São Paulo (SP) – Bauru (SP), Brazil. E-mail: cleber.ferraresi@gmail.com. Orcid: 0000-0002-1361-8390

⁵Universidade do Sagrado Coração (USC) – Bauru (SP), Brazil. E-mail: ssimionato@terra.com.br. Orcid: 0000-0002-5603-6702

⁶Universidade do Sagrado Coração (USC) – Bauru (SP), Brazil. E-mail: carlos.fachin743@hotmail.com. Orcid: 0000-0002-2613-4766

Os animais foram divididos aleatoriamente em cinco grupos: grupo-controle Inicial (GCI), grupo-controle final (GCF), grupo experimental não tratado (GENT), grupo neurografia término-lateral com estimulação russa (GNTLER) e grupo-controle desnervado (GCD). A corrente russa foi iniciada cinco dias após neurografia e aplicada no músculo tibial cranial do GNTLER, 3 vezes por semana, totalizando 36 sessões. A estimulação elétrica foi eficaz para aumentar a amplitude e diminuir a latência do músculo reinervado, além de aumentar a força muscular em comparação ao GCD. Diante disso, conclui-se que a eletroestimulação de média frequência (corrente russa) foi eficiente na recuperação funcional do músculo tibial cranial após neurografia término-lateral do nervo fibular comum.

Descritores | Estimulação Elétrica; Estimulação Elétrica Nervosa Transcutânea; Ratos Wistar; Nervo Fibular.

RESUMEN | Las lesiones de los nervios periféricos ocasionan una elevada pérdida funcional en el tejido muscular. De esta manera, en muchos estudios se han investigado técnicas quirúrgicas, como neurografías, y recursos terapéuticos, como la electroestimulación, para mejorar la funcionalidad del músculo reinervado tras una lesión periférica. El presente estudio tiene como objetivo investigar los efectos de la electroestimulación

con corriente rusa (2.500Hz, 4ms, 10 seg. de contracción por 20 seg. de relajación, modulación de 10Hz y 100Hz) en la recuperación funcional tras la sección y neurografía término-lateral del muñón distal del nervio fibular común en la parte lateral del nervio tibial en ratas. Se utilizaron 25 ratas Wistar, machos, con 80 días de vida, proporcionadas por el Biotério Central de la Universidade do Sagrado Coração (Bauru, SP, Brasil). Se dividieron aleatoriamente los animales en cinco grupos: grupo de control inicial (GCI), grupo de control final (GCF), grupo experimental no tratado (GENT), grupo de neurografia término-lateral con estimulación rusa (GNTLER) y grupo de control denervado (GCD). La corriente rusa se inició cinco días tras la neurografia, siendo que la aplicó al músculo tibial craneal del GNTLER 3 veces a la semana, con un total de 36 sesiones. La estimulación eléctrica se mostró efectiva para aumentar la amplitud y disminuir la latencia del músculo reinervado, además de aumentar la fuerza muscular en comparación con el GCD. Por lo tanto, se concluye que la estimulación eléctrica de frecuencia media (corriente rusa) fue eficaz en la recuperación funcional del músculo tibial craneal tras la neurografia término-lateral del nervio fibular común.

Palabras clave | Estimulación Elétrica; Estimulación Elétrica Transcutánea del Nervio; Ratas Wistar; Nervo Fibular.

INTRODUCTION

Peripheral nerve injury is common in physical therapy, being scientifically complex and little explored. The compromise in transmission of nerve impulses is one of the consequences of this injury and produces several changes in the muscular system such as atrophy^{1,2}.

Related to the anatomic involvement, peripheral nerve injuries are classified into three types: neuropraxia, characterized by blockage of electrical conduction without interruption of axonal continuity or degeneration; axonotmesis, when is observed a break in the axon continuity, but the endoneurial tubes remain intact; and neurotmesis, which occurs when one or more layers of connective tissue are disrupted^{2,3}.

Among microsurgical nerve repair techniques, there is the end-to-side neuroorrhaphy (ESN), which consists in the coaptation of an injured nerve segment at the side surface of another adjacent intact nerve, restoring physiological characteristics⁴. In the study by

Viterbo et al.⁵ was performed a section of the peroneal nerve, which innervates the cranial tibial muscle. Its distal stump was sutured to the lateral aspect of the tibial nerve intact, without removing the epineurium. Thus, first, muscle reinnervation was obtained without damage to the donor nerve, which represents a valuable contribution, once that any surgical technique nerve can be used as donor nerve.

Electrical stimulation with regenerative purpose became an study object in functional recovery as it has been used as a therapeutic tool to prevent muscle atrophy and in some cases, prevent the loss of muscle tissue resulting from downtime or denervation^{6,7}. Used in this type of electrical stimulation, the Russian current is an alternating current with frequency in the range 2.500 Hz and 4 milliseconds of pulse duration, indicated for peripheral nerve injury and thought an effective and safe alternative⁸.

Previous studies show the effectiveness of electrical stimulation on nerve regeneration. However, until now no investigating studies are known regarding

the effects of electrical stimulation Russian current in functional recovery of peripheral nerve injury after neurorrhaphies. Our hypothesis is that medium-frequency electrical stimulation with Russian current can have a beneficial effect on the functional recovery of the cranial tibial denervated muscle of Wistar rats submitted to neurorrhaphy. Thus, we investigated the effects of electrical stimulation with Russian current in functional recovery after section, and end-to-side neurorrhaphy of the peroneal nerve distal stump common to the lateral face of the tibial nerve in rats.

METHODOLOGY

Randomization

In the study, 25 male rats (*Rattus norvegicus*) from Wistar strain aged 80 days old were randomly divided into five groups: (1) Initial control group (ICG); (2) final control group (FCG); (3) untreated experimental group (UEG); (4) end-to-side neurorrhaphy Russian stimulation group (ENRSG); and (5) denervated control group (DCG). The animals of ICG, FCG, UEG, ENRSG and DCG were sacrificed 90 days after the start of the experiment.

Surgery

The animals were kept in appropriate boxes lined with wood shavings at controlled temperature ($25\pm 2^{\circ}\text{C}$) with 12-hour light-dark cycle and food and water *ad libitum* until the time of euthanasia. For each surgical procedure, animals were anesthetized with ketamine (80mg/kg) and xylazine (10mg/kg) intraperitoneally.

The procedures were performed by a single researcher to ensure reliability and standardization with aid of a DF Vasconcellos surgical microscope, with 10x to 16x magnification. After the procedure, the incision was sutured in layers with simple stitches using 4-0 nylon monofilament into musculature and animal skin.

After the surgery, the animals were observed and their pain assessed by the following signs: vocalization, piloerection, hunched posture, hypothermia, ocular discharge, self-licking, aggressiveness, reluctance to interact, change in the water and food consumption, and weight loss. Analgesic was used until no further signs of pain were visible. Postoperative analgesia was

performed with acetaminophen (paracetamol) 2mg/mL added to drinking water.

Electrical stimulation protocol

Electrical stimulation started five days after surgery. The animals of ENRSG underwent three sessions per week for 90 days, totaling 36 sessions. These animals received the electrical stimulation in the cranial tibial muscle; Russian current with 2,500Hz frequency, lasting 4 ms pulse duration, 10 seconds of contraction time per 20 seconds of relaxation and 20 minutes of total duration.

The Endphasys KLD® electrical stimulator was used, as well as the initial current which was enough to promote muscular contraction. The animals were stimulated awake and without anesthesia. Then they were placed into a metal capsule with rear opening for the tail and two lateral openings for fixing the hindlimbs. After immobilization, self-adhesive electrodes with 1 cm² were fixed on the muscle belly.

Evaluative measures

Evaluative measures of electromyoneurography and muscle strength were taken immediately after the electrical stimulation protocol of ENRSG, except for the ICG, whose measurements were performed in the first week of study.

Electromyoneurography

For the electrophysiology study, performed before euthanasia, ambient temperature was maintained at 25°C. After anesthesia with ketamine (80mg/kg) and xylazine (10mg/kg) intramuscularly, the animals were immobilized in prone position. Shaving and wide incision were performed in the previously operated hindlimb, allowing access to the sciatic and common peroneal nerve. The compound action potential was recorded by active and reference electrodes.

The Red electrode (reference) was placed in the tendon of the cranial tibial muscles; black electrode (active), in the belly of the cranial tibial muscle; and the green electrode (dispersive), in a distant location of the study area (Figure 1).

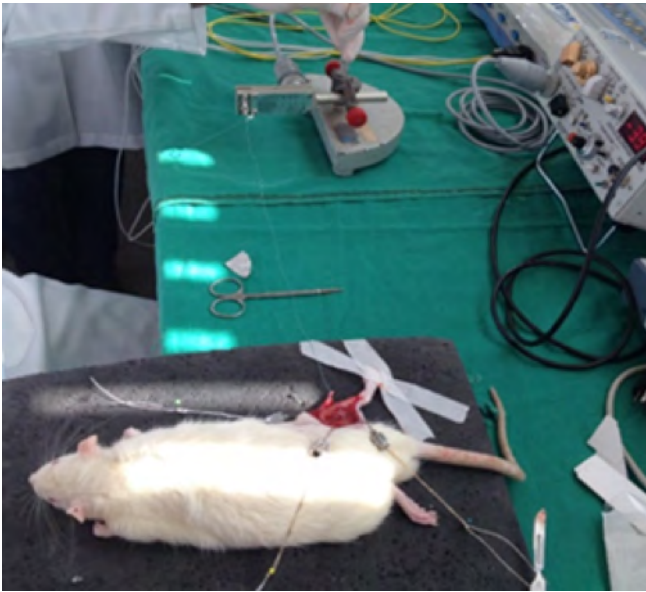


Figure 1. Muscle strength analysis

The electrodes recorded the duration, amplitude and latency of muscle action potential. Three sets of measurements were taken for each animal with an intact tibial nerve, and three with the portion of the tibial nerve distally transected to end-to-side neurorrhaphy (ESN), being chosen a set with intact tibial nerve and a set with the sectioned tibial nerve. The sets with higher amplitude recorded were selected. The amplitude and latency data were compared between groups. Sapphire II 4ME[®] electromyography was used.

Muscle strength assessment

After the electrophysiology study, the distal tendon of the cranial tibial muscles was cut and connected to a force transducer (FT03, Grass Technologies) using a nylon suture with 4-0. The muscle was retracted by the nylon thread, increasing its length until the draw tension was determined with 0.18N load. This preload value was determined during device calibration and adjusted among the tests.

The electrical stimulator electrodes were directly placed on the exposed cranial tibial muscle. The muscle contraction test was performed in three sequential applications of one second in the same current used in the treatment of animals of the ENRSG. A computer recorded force peaks. Muscular tension was adjusted between measurements. The tetanic contraction was performed using 100 milliamps and frequency range of 10Hz and 100Hz (Figure 2).

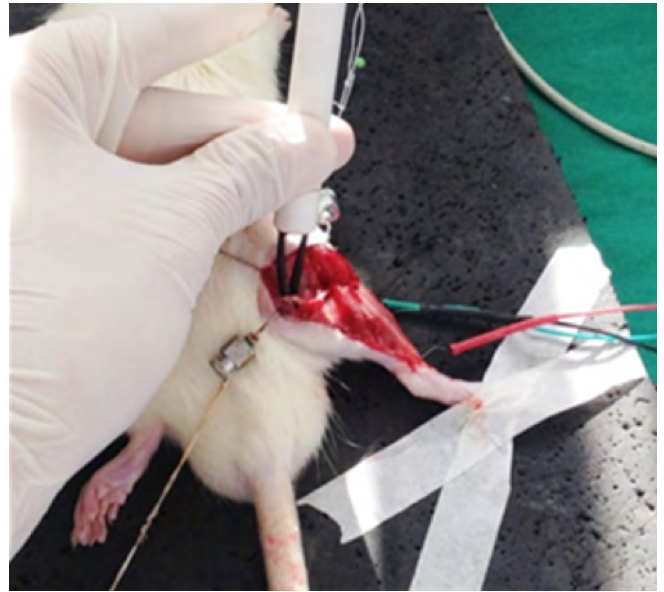


Figure 2. Electromyoneurography

Statistical analysis

Data normality was verified using the Shapiro-Wilk test. The groups were compared by single factor analysis of variance (one-way ANOVA) and post hoc Tukey for multiple comparisons. The result $p \leq 0.05$ was considered significant. This analysis used GraphPad Prism 5.2 software.

RESULTS

Amplitude

Figure 3 shows the amplitude mean results (millivolt, [Mv]) measured by electromyoneurography.

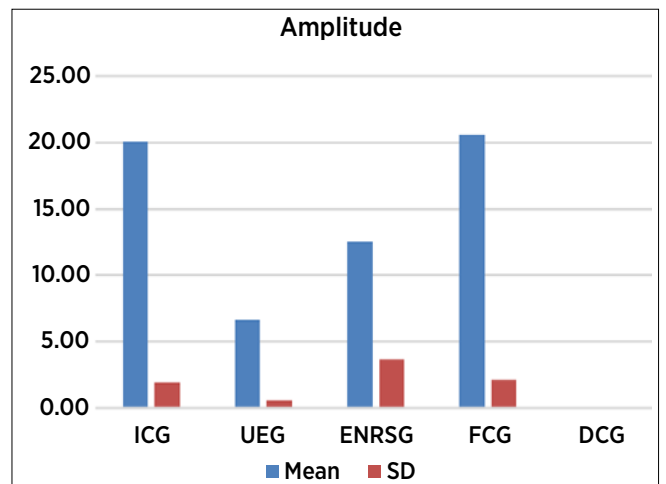


Figure 3. Mean and standard deviation of the amplitude (mV) measured by electromyoneurography

ICG: initial control group; UEG: untreated experimental group; ENRSG: end-to-side neurorrhaphy Russian stimulation group; FCG final control group; DCG: denervated control group.

The mean amplitude of ENRSG was greater and showed significant difference ($p=0.05$) compared with UTEG. ICG and FCG showed no statistical differences ($p=0.05$). However, ENRSG showed significantly lower amplitude when compared with ICG ($p=0.05$) and FGC ($p=0.05$).

Latency

Figure 4 shows the means of latency results (ms), also measured by electromyoneurography.

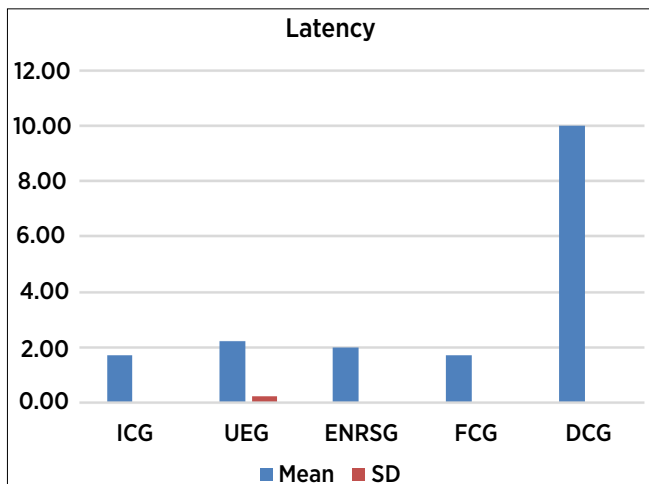


Figure 4. Mean and standard deviation of the latency (ms) measured by electromyoneurography
 ICG: initial control group; UEG: untreated experimental group; ENRSG: end-to-side neurorrhaphy Russian stimulation group; FCG final control group; DCG: denervated control group.

The mean of latency of ENRSG was smaller and showed significant difference ($p=0.05$) compared with UEG. The ICG and FCG showed no statistically significant differences. Finally, the ENSRG presented increased latency when compared with ICG ($p=0.05$) and FCG ($p=0.05$).

Muscular strength (N)

Figure 5 shows the means of muscle strength measured with force transducers (FT03, Grass Technologies).

The results of muscle strength showed no significant difference between ENRSG and UEG. The ICG and FCG showed significant differences ($p=0.05$), which can be justified by the animals' growth. However, ENRSG showed significantly lower amplitude when compared with ICG ($p=0.05$) and FGC ($p=0.05$).

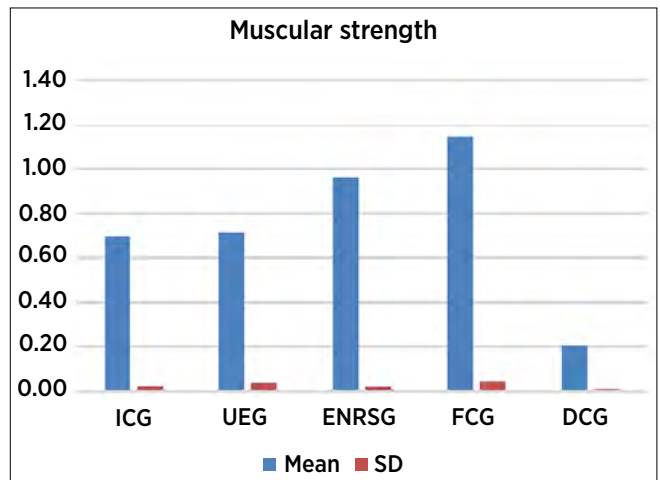


Figure 5. Mean and standard deviation of muscle strength
 ICG: initial control group; UEG: untreated experimental group; ENRSG: end-to-side neurorrhaphy Russian stimulation group; FCG final control group; DCG: denervated control group.

DISCUSSION

Considering the results of electromyoneurography and muscular strength, we found that electrical stimulation of medium frequency (Russian current) was effective in functional recovery of rats subjected to section and end-to-side neurorrhaphy of the peroneal nerve distal stump common to the lateral face of the tibial nerve.

End-to-side neurorrhaphy reaches clinically satisfactory results, as effective results have led practitioners to use it in clinical trials, as technical, theoretical and scientific basis inspired by animal experimental studies is important⁹. However, only the end-to-side neurorrhaphy was unable to restore the initial values of animal muscle strength (Figure 5).

Electromyography studies the peripheral nervous and muscular system, assessing the functional integrity of neurons and sensory peripheral engines, myoneural plates and muscles. Thus, electromyography is a complementary examination that assesses the intensity of injury during the electrophysiology study^{10,11}.

The electrophysiology study provides latency and amplitude data. The latency reflects the nerve conduction, that is, the number of myelinated fibers. Moreover, amplitude reports the number of muscle fibers that respond to electrical stimuli and, consequently, the number of excitable axons¹². In this context, end-to-side neurorrhaphy associated with electrical stimulation with Russian current (ENRSG) was superior to isolated neurorrhaphy (UEG) and the group without nerve repair (DCG), increasing the

number of excitable muscle fibers electrically (larger amplitude in mV) (Figure 3). Still, considering the latency, ENRSG showed results very similar to ICG and FCG, suggesting better nerve conduction (Figure 4).

Electrical stimulation with Russian current consists of a medium frequency current, 2,500Hz modulated to 50Hz. This current produces 50 polyphasic pulses per second, with 50Hz of firing repetition and 400 milliseconds duration between each pulse, i.e. within the range of biological stimulus range (between 0.1Hz and 200Hz), which makes the stimulation relatively comfortable¹³.

In the study by Maciel et al.¹⁴, rats were used in the end-to-side neurorrhaphy, receiving electrical stimulation with 1KHz current. The group receiving electrical stimulation obtained more significant improvement of functional fibular index (60.5%) compared with the group without stimulation (9.5%). The increased muscle strength was another factor that contributed to functional improvement, and the stimulated group showed a statistically significant result compared with unstimulated group.

In the experiment of Willand et al.¹⁵, the sciatic nerve of rats was transected, and lesion repair was delayed for different periods. Electrical stimulation was applied later to promote regeneration, 24 weeks after nerve repair. However, recent results show the most effective time to perform the electrical stimulation is up to one month after nerve repair.

This study confirms these previous results, from neurorrhaphy to the start of electrical stimulation. However, it is noteworthy that, despite the good results obtained in this investigation, the literature lacks studies to establish optimal protocols for treatment of peripheral nerve injuries. In this sense, other features such as laser therapy or phototherapy (photobiomodulation), have also been investigated^{16,17}.

Finally, it is concluded that experimental model of common peroneal nerve end-to-side neurorrhaphy, electrical stimulation associated with Russian current, was effective in functional recovery of rats, contributing to future studies and clinical practice of rehabilitation.

Limitation

This study assessed the functional recovery of the denervated muscles by muscular strength, amplitude (mV), and latency (ms), but the progress could also be used in future studies. Furthermore, we suggest the

investigation of the effects of electrical stimulation with Russian current for periods longer than 12 weeks (36 sessions).

CONCLUSION

Based on the experimental model of this study, we concluded that the medium frequency electrical stimulation (Russian current) was effective in functional recovery of the cranial tibial denervated muscle, considering the amplitude and muscular latency after the end-to-side neurorrhaphy.

REFERENCES

1. Cavalcante VEV, Montenegro EJM, Pontes NTF. Efeito da eletroestimulação no músculo desnervado de animais: revisão sistemática. *Fisioter Mov.* 2012;25(3):669-78. doi: 10.1590/S0103-51502012000300022
2. Viterbo F. *Neurorrafia látero-terminal: estudo experimental no rato [tese]*. Botucatu (SP): Universidade Estadual Paulista; 1992.
3. Rovak JM, Cederna PS, Kuzon WM. Terminolateral neurorrhaphy: a review of the literature. *J Reconstr Microsurg.* 2001;17(8):615-24. doi: 10.1055/s-2001-18817
4. Souza FI, Santos GB, Silva CF, Mattar Júnior R, Zumiotti AV. Avaliação histológica da neurorrafia término-lateral: estudo experimental em ratos. *Acta Ortop Bras.* 2011;19(3):129-31. doi: 10.1590/S1413-78522011000300002
5. Viterbo F, Trindade JC, Hoshino K, Mazzoni Neto A. Latero-terminal neurorrhaphy without removal of the epineural sheath: experimental study in rats. *Rev Paul Med.* 1992;110(6):267-75. doi: 10.1590/S1516-31801998000500005
6. Carvalho DCI, Rosim CG, Gama LOR, Tavares MR, Tribioli RA. Tratamentos não farmacológicos na estimulação da osteogênese. *Rev Saúde Pública.* 2002;36(5):647-54. doi: 10.1590/S0034-89102002000600017
7. Viterbo F, Trindade JC, Hoshino K, Mazzoni Neto A. End-to-side neurorrhaphy with removal of the epineurial sheath: an experimental study in rats. *Plastic Reconstr Surg.* 1994;94(7):1038-47. doi: 10.1590/s0102-865020170090000002
8. Ward AR, Lucas TS. Lowering of sensory, motor and pain-tolerance thresholds with burst duration using kHz frequency alternating current electrical stimulation. *Arch Phys Med Rehabil.* 2007;88(8):1036-41. doi: 10.1016/j.apmr.2007.04.009
9. Papalia I, Ronchi G, Muratori L, Mazzucco A, Magauidda L, Geuna S. Direct muscle neurotization after end-to end and end-to-side neurorrhaphy: an experimental study in the rat forelimb model. *Neural Regen Res.* 2012;7(29):2273-8. doi: 10.3969/j.issn.1673-5374.2012.29.005
10. Udina E, Puigdemasa A, Navarro X. Passive and active exercise improve regeneration and muscle reinnervation after peripheral

- nerve injury in the rat. *Muscle Nerve*. 2011;43(4):500-9. doi: 10.1002/mus.21912
11. Thompson NJ, Sengelaub DR, English AW. Enhancement of peripheral nerve regeneration due to treadmill training and electrical stimulation is dependent on androgen receptor signaling. *Dev Neurobiol*. 2014;74(5):531-40. doi: 10.1002/dneu.22147
 12. Nemeth PM. Electrical stimulation of denervated muscle prevents decreases in oxidative enzymes. *Muscle Nerve*. 1982;5(2):134-9. doi: 10.1002/mus.880050210
 13. Viterbo F, Trindade JC, Hoshino K, Mazzoni Neto A. Two end-to side neurorrhaphies and nerve graft with removal of the epineural sheath: experimental study in rats. *Br J Plastic Surg*. 1994;47(2):75-80. doi: 10.1590/S0102-86502012000300010
 14. Maciel FO, Viterbo F, Chinaque LDFC, Souza BM. Effect of electrical stimulation of the cranial tibial muscle after end-to-side neurorrhaphy of the peroneal nerve in rats. *Acta Cir Bras*. 2013;28(1):39-47. doi: 10.1590/S0102-86502013000100007
 15. Willand MP, Chiang CD, Zhang JJ, Kemp SWP, Borschel GH, Gordon T. Daily electrical muscle stimulation enhances functional recovery following nerve transection and repair in rats. *Neurorehabil Neural Repair*. 2015;29(7):690-700. doi: 10.1177/1545968314562117
 16. Rosso MPO, Rosa Júnior GM, Buchaim DV, German IJS, Pomini KT, Souza RG, et al. Stimulation of morphofunctional repair of the facial nerve with photobiomodulation, using the end-to-side technique or a new heterologous fibrin sealant. *J Photochem Photobiol B*. 2017;175:20-8. doi: 10.1016/j.jphotobiol.2017.08.023
 17. Buchaim DV, Andreo JC, Ferreira Junior RS, Barraviera B, Rodrigues AC, Macedo MC, et al. Efficacy of laser photobiomodulation on morphological and functional repair of the facial nerve. *Photomed Laser Surg*. 2017;35(8):442-9. doi: 10.1089/pho.2016.4204