

Idiopathic Bilateral Simultaneous Facial Nerve Palsy (B-FNP)

Theresia Christin¹, Ratri Wulandari¹, Luther Theng², Selly Marisdina²

¹Department of Neurology, RSUP DR. Mohammad Hoesin, Faculty of Medicine,
Sriwijaya University, Palembang

Email: dr.theresiachristinsp.s@gmail.com

ABSTRACT

Background: Bilateral facial nerve palsy (*B-FNP*) is a rare clinical manifestation with incidence of 1 per 5 million people. Furthermore, it approximately accounts for 0.3 – 2 % of facial palsy cases. This *B-FNP* case is intricate in the diagnosis, finding the aetiology, and treatment that need hospitalization.

Case Report: A male 64-year-old with bilateral facial nerve palsy that happened suddenly followed by difficulty in closing both eyes and facial abnormality without clear cause within 7 days of onset. Risk factor is hypertension stage 2. During neurological examination, there was bilateral peripheral facial nerve palsy grade IV in right side and grade III in the left side (*House Brackmann grading system*) that was not followed by other cranial nerve abnormality and motoric examination is normal. Supporting examinations such as lumbar puncture, thorax photo, and head MRI with contrast shows normal result. ENMG examination shows absent of blink reflex. Prednisone 60 mg orally was given with tapering off dosage 10 mg per day. Patient was hospitalized for 12 days and was discharge with good clinical improvement with bilateral peripheral facial nerve paralysis grade II in right side and grade I in left side.

Conclusion: Bilateral facial nerve paralysis is a rare clinical manifestation and challenging in diagnosis. It is important to have a differential diagnosis in cases with bilateral cranial nerve palsy. Careful physical examination and appropriate supporting examinations such as laboratory and radiology in necessary to evaluate the underlying cause.

Keywords: B-FNP, Idiopathic

INTRODUCTION

Facial paralysis is still a challenging clinical problem. The underlying causes range from life-threatening conditions to idiopathic causes that can heal on their own. Although unilateral facial paralysis is relatively common, reported incidence of around 20 to 25 per 100,000 population, bilateral facial paralysis (BFP) is a rare clinical occurrence. With an incidence of 1 per 5 million population and are accounted for 0.3 to 2 percent of cases of facial paralysis. Although Bell's Palsy is the most common cause of unilateral facial paralysis, the etiologic factors underlying BFP are usually other medical conditions such as Lyme disease, Guillain Barre's Syndrome, leukemia, infectious mononucleosis, or trauma and require hospital treatment to diagnose and treat.

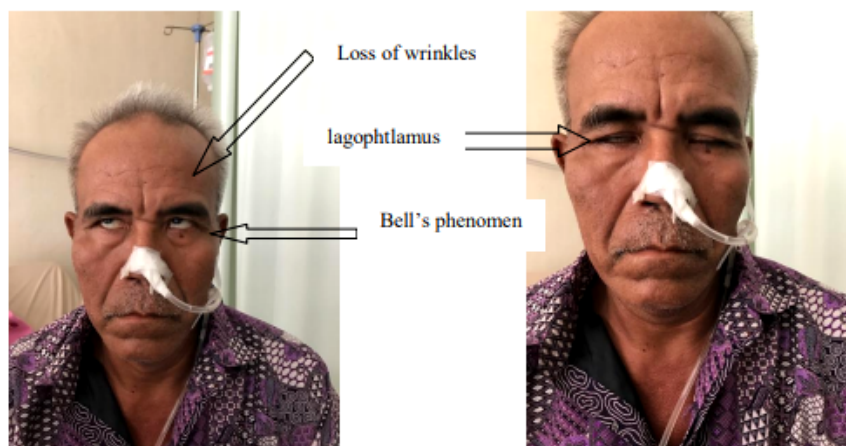
CASE REPORT

A 64-year-old man was treated in the neurology department of dr. Mohammad Hoesin Hospital Palembang with complaints of difficulty moving the face, unable to close both eyes, difficulty to chew food, gargle, saliva flowing from the mouth that occurs suddenly since 1 week ago. The patient has no history of head trauma, ear infections, joint pain, fever, rashes on the face or limbs. On examination vital signs are within normal limits except for uncontrolled hypertension which he has since 5 years ago. Blood pressure is at 150/90 mmHg (stage 1). Head, eyes, ears, nose and throat examinations are normal. The trachea is not deviated, no palpable mass in the neck. There is no enlargement of the thyroid gland, enlarged parotid glands and adenopathy. Auscultation examination of the heart and lungs are within normal limits. No abnormalities on abdominal examination, no enlargement of organs and normal bowel sounds.

Neurological examination showed bilateral peripheral facial paralysis with Grade IV on the right side and Grade III on the left side (House-Brackmann grading system). Tasting ability is still normal, and there are signs of the Bell phenomenon, flattening of nasolabial plica, reduced forehead folds, delayed left mouth corners movement that indicates an LMN type facial paralysis.

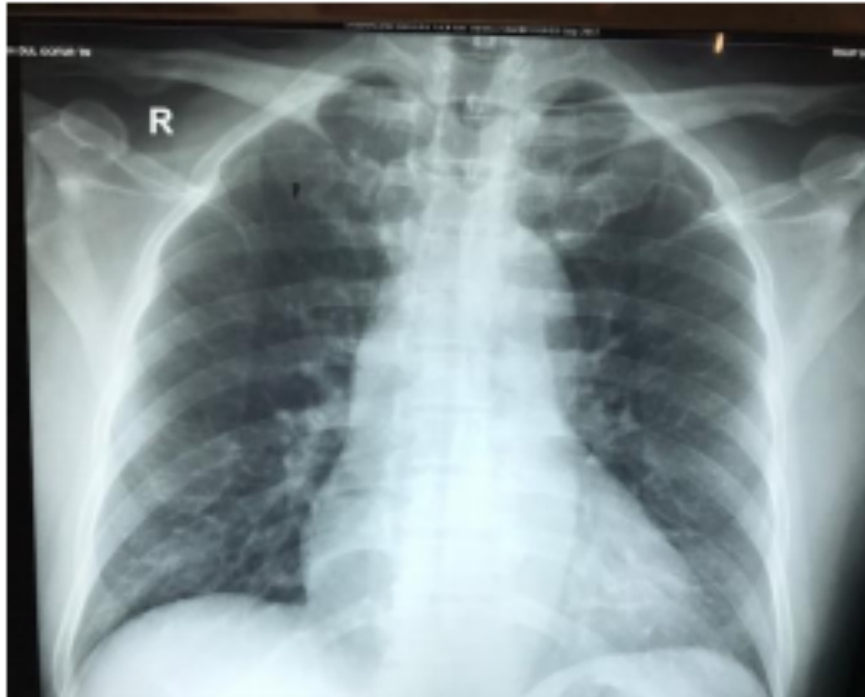
Status lokalis NVII

	Dekstra	Sinistra
Mengerutkan dahi	-	-
Menutup mata	-	-
Mengangkat sudut bibir	-	-
Tersenyum	-	+/-
Pengecapan rasa manis	+	+
Mata	Lagophthalmus 4 mm	Lagophthalmus 2 mm
Epifora	+	+

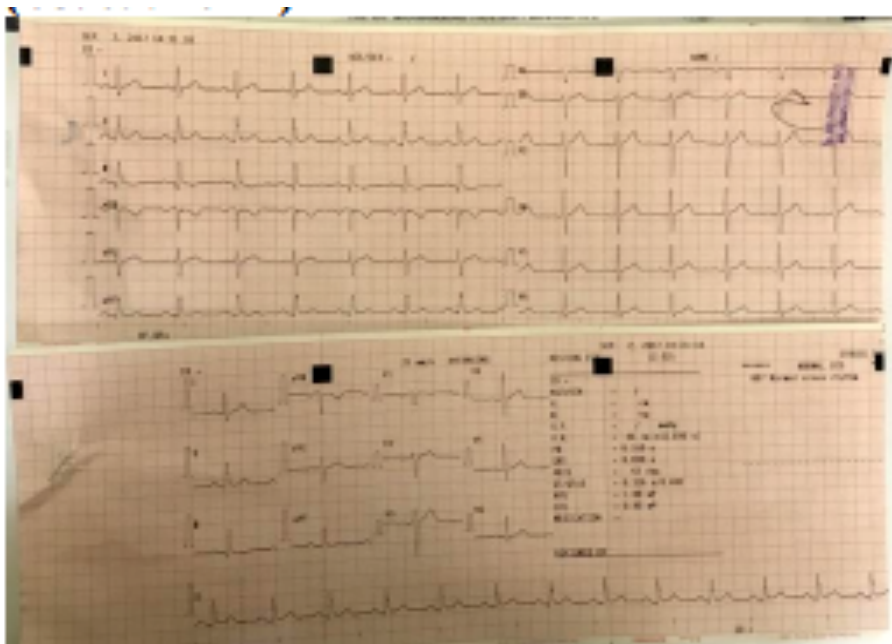


Picture 1. Clinical Signs of Bilateral Facial Paralysis

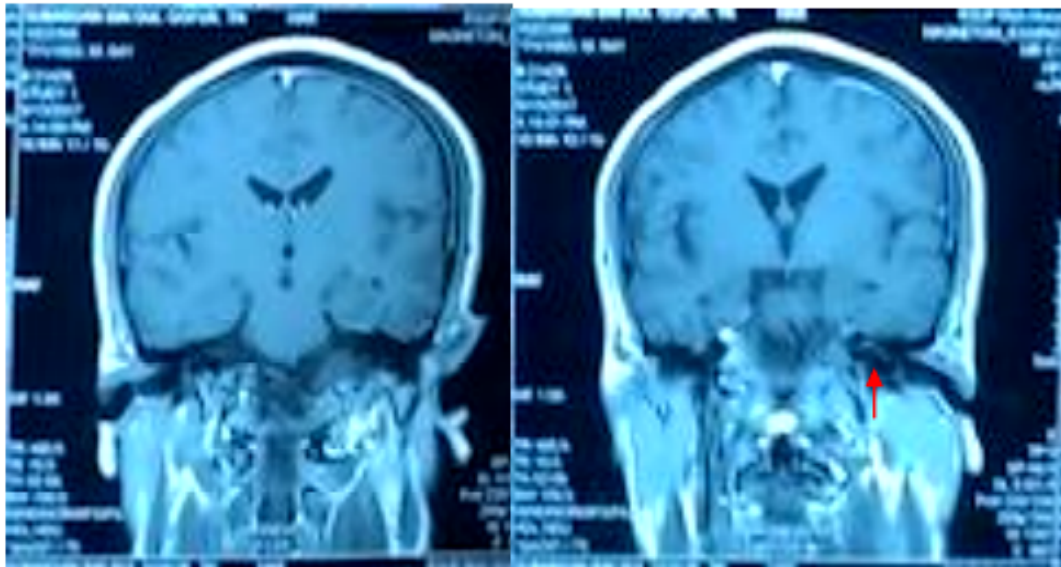
Laboratory tests, including routine blood test, chemistry, and hemostasis are within normal limits, except lipid profile which is increased. Lumbar puncture, which is the analysis of CSF did not show dissociation of sitoalbumin, other parameters are within normal limits. Serological tests for HIV, CMV, HSV, and syphilis are negative. Unfortunately, we were unable to examine EBV and borrelia serology



Picture 2. Cardiomegaly on chest X-ray



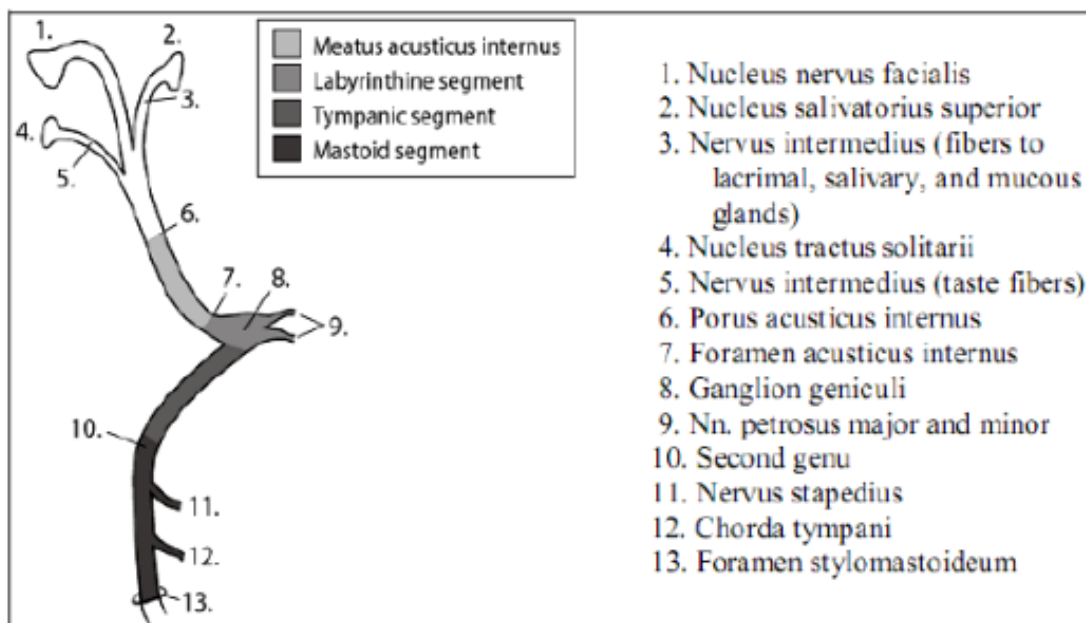
Picture 3. Electrocardiogram



MRI Kepala potongan Coronal Sekuens T1 (kiri) Kontras Gadolinium (kanan)

Picture 4. Coronal slice MRI of the head, T1 sequence (left), and Gadolinium (right) that showed no suspicious or Space Occupying lesion.

There is a mild cerebral atrophy. Brainstem, cerebellum and CPA showed no abnormalities. There is no sign of sinusitis or mastoiditis.



Letak Lesi	Kelainan motorik	Gangguan pengecapan	Gangguan pendengaran	Hiposekresi saliva	Hiposekresi lakrimalis
Pons-meatus akustikus internus	+	+	+ tuli/hiperakusis	+	+
Meatus akustikus internus-ganglion genikulatum	+	+	+ Hiperakusis	+	+
Ganglion genikulatum-N. Stapedius	+	+	+ Hiperakusis	+	-
N.stapedius-chorda tympani	+	+	+	+	-
Chorda tympani	+	+	-	+	-
Infra chorda tympani-skitar foramen stilomastoideus	+	-	-	-	-

Topical diagnosis of the patient can be concluded according to the course of the facial nerve and clinical signs that occurs. In this patient there are motor abnormalities without taste disturbance, hearing loss, salivary or lacrimal hyposalivation therefore the possible topical lesion is in the stylomastoid foramen area. Laboratory tests, including routine blood test, chemistry, and hemostasis are within normal limits, except lipid profile which is increased. Lumbar puncture, which is the analysis of CSF did not show dissociation of sialalbumin, other parameters are within normal limits. Serological tests for HIV, CMV, HSV, and syphilis are negative. Unfortunately, we were unable to examine EBV and borrelia serology. Chest X-ray examination showed cardiomegaly. This is because the patient has a history of uncontrolled hypertension for 5 years. Contrast head MRI examination results are normal as well.

ENMG (Electroneuromyography) examination is important in patients with Bell's Palsy. A normal ENMG excludes abnormalities from Guillain Barre syndrome. Blink reflexes or studies on it provide useful information about the neurophysiological status of the trigeminal nerve and the face, brain stem, and cranial end of the cervical segment in the spinal cord, and show a high degree of correlation with magnetic resonance imaging (MRI) findings. This test is very useful in Bell's palsy patients with hemifacial spasm and synkinesis. This test can show hyperexcitability of central motor neurons and its return to normal levels after recovery. This test can also show the lower quality brain function, such as the process of eating, prolonged blink reflex latency and amplitude decrease in peripheral facial paralysis, some polyneuropathies (eg, diabetes and uremic), Guillain Barre's syndrome, Behcet's disease, Chiari II malformations, and Wallenberg's syndrome.

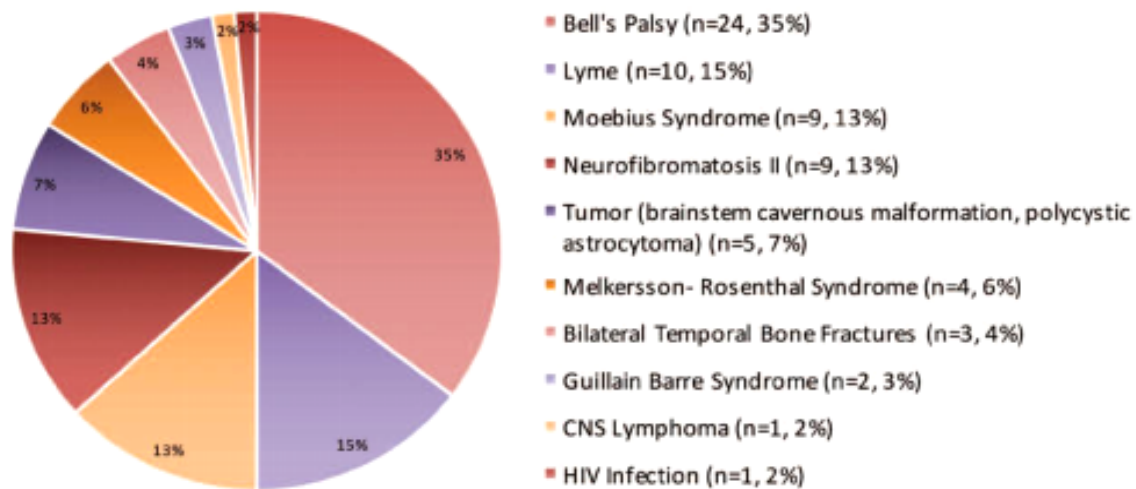
Although blink reflexes have been long accepted as valuable diagnostic tools, there has been little research on specific blink reflex parameters, that explain which specific parameters are useful in diagnostic and prognostic, and in what cases and when. In our clinical practice, we observe that peripheral facial paresis inhibits blink reflexes and that abnormalities that are found previously precede other clinical and neurophysiological changes. This disorder seems to correlate with disease outcome, or more specifically, with residual motor deficit.

In this case ENMG test was performed on the facial and Blink reflexes. As such, on the first examination, the amplitude of M. Facialis orbicularis and M. Facialis branch decreased and distal latency was elongated. Blink Reflex is absent from R1 and R2 Ipsilateral and R2 Contralaterally. In needle examination, M. Frontalis has no pathological waves in spontaneous activity. MUAP of M. Frontalis showed decreased recruitment, amplitude and poor effort. After 10 days of treatment, the ENMG was re-examined. The results of M. Facialis orbicularis amplitude and M. Facialis branch were normal and distal latency was normal. This is in accordance with the clinical improvement of the patient.

Bilateral facial paralysis remains a diagnostic challenge. Although the pathophysiology of asynchronous bilateral facial paralysis is usually associated with local inflammatory conditions that are believed to cause nerve ischemia (eg viral reactivation, granulomatous disease), the pathophysiology of synchronous bilateral facial paralysis usually involves more systemic problems, including neurotoxic or autoimmune processes. (eg Lyme disease, human immunodeficiency virus, Guillain-Barré syndrome) and major trauma (for example, bilateral temporal fractures). In contrast to unilateral facial paralysis, bilateral facial paralysis often appears as a manifestation of a serious systemic condition.²

Thus, a comprehensive history and physical examination together with proper blood and imaging studies are needed to establish the correct diagnosis is very important. Acute synchronous bilateral facial paralysis that appears acutely (ie, rapidly developing paralysis) is often caused by trauma or infectious or autoimmune diseases (eg Lyme disease, human immunodeficiency virus, Guillain-Barré syndrome), whereas bilateral slow progressive facial paralysis is very likely to lead to neoplastic diseases such as central nervous system lymphoma. Diagnostic tests must include complete blood cell counts, neon treponemal antibody tests, human immunodeficiency virus testing, fasting glucose levels, erythrocyte sedimentation rates, Lyme titers, antinuclear antibody levels, antineutrophil cytoplasmic antibodies, antiphospholipid antibodies, and imaging with fine contrast, enhanced magnetic resonance imaging or computerized tomography of the temporal bone. In addition, lumbar puncture can be performed to evaluate cell numbers and to confirm bacterial or viral infections through enzyme-linked immunosorbent testing, Western blot, or polymerase chain reaction. Each disease has a unique initial pathophysiology, diagnosis, and treatment.

Diagnoses of Bilateral Facial Paralysis



Bagan Diagnosis dari Paralisis fasial bilateral²

Bell's palsy is an acute peripheral facial nerve palsy in patients whose physical examination and history is unusual, consisting of deficit that affect all facial zones that equally evolved within 72 hours. Until now, it remains a clinical diagnosis of exclusion. Strong evidence shows the reactivation of herpes simplex virus type 1 in the geniculate ganglion as the underlying cause, with reactivation of herpes simplex virus type 1 which causes damage to ganglion cells, and Schwann cell infection that causes demyelination, nerve inflammation, and resultant ischemic compression at the level of meatal foramen. Complete recovery of normal facial function occurs in about 70 percent of untreated cases, with permanent facial dysfunction that occurs at a mild level in 13 percent and advanced in 16 percent of cases. Synchronous bell palsy is very rare. In the acute phase, management options for Bell palsy include corneal protection measures, eyelid stretching, pharmacological treatments, and consideration of facial neurosurgical decompression; Patients who continue to develop non-flaccid facial paralysis may be offered physical therapy, chemodeneration.

The final diagnosis in these patients can be concluded with a bilateral Bell's palsy (idiopathic) by getting rid of several differential diagnoses from B-FNP. After 12 days of treatment the patient returned home in good condition, almost completely healed, namely with bilateral peripheral Grade II facial paralysis on the right side and Grade I on the left side (House-Brackmann grading system). During treatment the patient only received neurotonic which is the injection of 500uq mecobalamin every 8 hours and corticosteroid which is 5 mg tablet of prednisone. Administration of prednisone at a dose of 1 mg / kg / day with a maximum of 60 mg / day and is reduced every 5 days at 10 mg increments. There are two studies that use prednisone in the treatment of Bell's palsy.

The first study conducted by Engstrom et al (2008) used an oral prednisone dose of 60 mg / day for 5 days, then reduced by 10 mg daily, with a total treatment time of 10 days. The drug is given within 72 hours after onset. Bell's palsy. Follow up was carried out between days 11-17, and at 1,2,3,6,12 months after randomization by assessing facial nerve function using the House-Brackmann (HB) grading system. The result showed that patients who received prednisone had shorter time to complete recovery and a better outcome after 12 months (fewer synkinesia events) than patients who did not get prednisone.

Another study was carried out by Sullivan et al (2007) who used prednisone at a dose of 25 mg twice daily for 10 days given within 72 hours after onset. Assessment of facial nerve function using the HB grading system. This study showed that patients who were given prednisone had better outcomes with complete cure of 90% patients treated with prednisone and 75% in patients who did not get prednisolone. In this case antivirals were not given because the patient came on day 7. The possibility of HSV-1 in the etiology of Bell's palsy has been considered but in this case the blood serology results on HSV-1 are still within normal limits.

Although the 2004 Cochrane review found insufficient evidence to support the use of this antiviral alone⁷, two recent placebo-controlled trials showed full recovery in a higher percentage from patients treated with antiviral drugs combined with prednisolone rather than prednisolone alone. (100 percent versus 91 percent and 95 percent versus 90 percent) .^{8,9} However, no observed benefit was seen when treatment was delayed for more than four days after symptom onset. (86 percent versus 87 percent) .⁹ The role of physiotherapy is quite important in healing patients with Bell's palsy.

ENMG (Electroneuromyografi):

Tanggal 06-09-2017

NCV Motorik N. Medianus normal, amplitudo normal dan distal latensi normal
 NCV Sensorik N. Medianus normal, amplitudo normal dan distal latensi normal
 NCV Motorik N. Ulnaris normal, amplitudo normal dan distal latensi normal
 NCV Sensorik N. Ulnaris normal, amplitudo normal dan distal latensi normal
 NCV Motorik N. Tibialis normal, amplitudo normal dan distal latensi normal
 NCV Motorik N. Peroneal normal, amplitudo normal dan distal latensi normal
 NCV Sensorik N Suralis normal, amplitudo normal dan distal latensi normal
 Amplitudo M. Facialis orbicularis branch menurun dan distal latensi memanjang
 Amplitudo M. Facialis frontalis branch menurun dan distal latensi memanjang

Tanggal 08-09-2017

Pada pemeriksaan Blink Reflek didapatkan absent dari R1 dan R2 Ipsilateral dan R2 Kontralateral
 Pada pemeriksaan Needle :
 Pada M.Frontalis tidak didapatkan gelombang patologis pada spontan activity
 MUAP M.Frontalis didapatkan recruitment menurun, amplitudo menurun dan poor effort

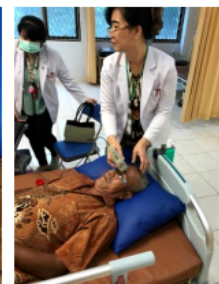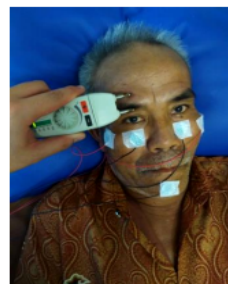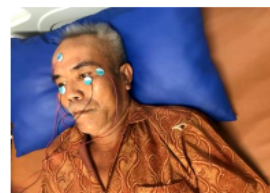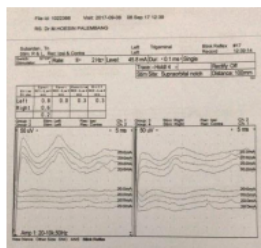
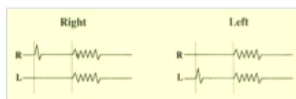
Conclusions :

Sesuai dengan gambaran demyelinating peripheral neuropathy??

Tanggal 15-09-2017

Amplitudo M. Facialis orbicularis branch normal dan distal latensi normal
 Amplitudo M. Facialis frontalis branch normal dan distal latensi normal

BLINK REFLEX PATTERNS



Picture 5. ENMG result that fits the image of demyelinating peripheral neuropathy



Picture 6. Clinical Improvement of the patient

CONCLUSION

Unilateral facial paralysis is usually idiopathic or associated with viral disease. On the other hand, bilateral facial nerve palsy is a rare and diagnostic challenge. Emergency physicians must be aware of various diagnostic possibilities, some of which are life-threatening and potentially fatal. We emphasize the importance of considering differential diagnoses in all cases accompanied by bilateral facial nerve palsy. These patients require careful assessment and examination and proper laboratory and radiological examinations for evaluation of the underlying cause and further relevant management. Thus, our bilateral FNP case, that presents a dilemma in diagnosing, is thought to be an idiopathic.

REFERENCES

- [1]. Tiemstra JD, Khatkhate N. Bell's palsy: Diagnosis and management. *Am Fam Physician*. 2007;76(7). doi:10.1288/00005537-197412000-00004.
- [2]. Gaudin RA, Jowett N, Banks CA, Knox CJ, Hadlock TA. Bilateral facial paralysis. *PRSJournal*. 2016;98(14):879. doi:10.1097/PRS.0000000000002599.
- [3]. Mikula Ivan, Miskov Snjezana, Negovetic Ruzica, Demarin Vida. Blink Reflex in the Prediction of Outcome of Idiopathic Peripheral Partial.
- [4]. Greenberg MR, Urquhart MC, Eygnor JK, et.al. I can't move my face! A Case of bilateral facial palsy. *J. Am Osteopath assoc*.2013;113:778-790.

- [5]. Lindsay RW, Robinson M, Hadlock TA. Comprehensive facial rehabilitation improves function in people with facial paralysis: A 5 year experience at the Massachusetts Eye and Ear Infirmary. *Phys Ther.* 2010;90:391-397.
- [6]. Hohman MH, Hadlock TA. Etiology, diagnosis and management of facial palsy: 2000 patients at a facial nerve center. *Laryngoscope* 2014;124:E283-E293.
- [7]. Allen D, Dunn L. Aciclovir or valaciclovir for Bell's palsy (idiopathic facial paralysis). *Cochrane Database Syst Rev* 2004;(3):CD001869.
- [8]. Hato N, Yamada H, Kohno H, Matsumoto S, Honda N, Gyo K, et al. Valacyclovir and prednisolone treatment for Bell's palsy: a multicenter, randomized, placebo-controlled study. *Otol Neurotol* 2007;28:408-13.
- [9]. Hato N, Matsumoto S, Kisaki H, Takahasi H, et al. Efficacy of early treatment of Bell's palsy with oral acyclovir and prednisolone. *Otol Neurotol* 2003;24:948-51.