

JGG 2020;68:1-10
doi: 10.36150/2499-6564-337

CLINICAL GERIATRICS - ORIGINAL INVESTIGATION

Chest ultrasound in Italian geriatric wards: use, applications and clinicians' attitudes

Andrea Ticinesi¹, Fulvio Lauretani¹, Antonio Nouvenne¹, Andrea Ungar², Raffaele Antonelli Incalzi³, Simone Scarlata³, On behalf of the GRETA (Gruppo di Ricerca sull'Ecografia Toracica nell'Anziano) Group of the Italian Society of Gerontology and Geriatrics (SIGG)

¹ Geriatric-Rehabilitation Department, Azienda Ospedaliero-Universitaria di Parma and Department of Medicine and Surgery, University of Parma, Italy; ² Geriatrics and Intensive Care Unit, Department of Experimental and Clinical Medicine, University of Florence and AOU Careggi, Florence, Italy; ³ Unit of Geriatrics and Unit of Respiratory Pathophysiology and Thoracic Endoscopy, Campus Bio-Medico University and Teaching Hospital, Rome, Italy

Received: May 23, 2019
Accepted: February 21, 2020

Correspondence

Andrea Ticinesi

Geriatric-Rehabilitation Department, Azienda Ospedaliero-Universitaria di Parma and Department of Medicine and Surgery, University of Parma, via Antonio Gramsci 14, 43126 Parma, Italy
Tel. +39 0521 703871. Fax +39 0521 702383.
E-mail: aticinesi@ao.pr.it
Orcid ID: 0000-0001-9171-8592

Conflict of interest

The Authors declare no conflict of interest

How to cite this article: Ticinesi A, Lauretani F, Nouvenne A, et al. Chest ultrasound in Italian geriatric wards: use, applications and clinicians' attitudes. *Journal of Gerontology and Geriatrics* 2020;68:1-10. <https://doi.org/10.36150/2499-6564-337>

© Copyright by Società Italiana di Gerontologia e Geriatria (SIGG)



OPEN ACCESS

This is an open access article distributed in accordance with the CC-BY-NC-ND (Creative Commons Attribution-NonCommercial-NoDerivatives 4.0 International) license. The article can be used by giving appropriate credit and mentioning the license, but only for non-commercial purposes and only in the original version. For further information: <https://creativecommons.org/licenses/by-nc-nd/4.0/deed.en>

Background and aims. Bedside chest ultrasound has emerged as a versatile and accurate diagnostic tool for the management of respiratory conditions in several clinical settings, integrating traditional imaging. The current utilization of this technique in geriatric hospital wards is still unknown. Our aim was to assess availability, uses and applications of chest ultrasonography in a convenience sample of 25 Italian geriatric wards.

Methods. A questionnaire, based on the current literature state-of-the-art, was e-mailed to head doctors of geriatric wards of Italian hospitals. The questionnaire explored ultrasound equipment availability, practice of chest ultrasound, expertise of ward physicians, clinical indications, and perceived impact on patient care.

Results. Ultrasound equipment was available in 92% of wards, and chest ultrasound was performed in 82% of cases. Among the wards where chest ultrasound was performed, it was considered as routine assessment in only 52% of cases, mainly for diagnosis of pleural effusions (95%) and acute heart failure (89%), assessment of volemic state (79%), and assistance to invasive procedures (79%). It was used in emergency/urgency assessment of acute dyspnea in only 53% of cases. In most wards, only three or less physicians were able to perform chest ultrasound. In 53% of cases, head doctors declared that they perceived benefits of chest ultrasound in patient care in only selected cases.

Conclusions. Chest ultrasound utilization in Italian geriatric wards is inhomogeneous, and the number of trained physicians is still limited. Geriatricians' attitude towards chest ultrasound is generally cautious. Research and training programs are needed to spread the correct use of this technique in geriatric practice.

Key words: lung ultrasound, point-of-care ultrasound, survey, ultrasound training, elderly patients

INTRODUCTION

Point-of-care ultrasonography is becoming more and more popular in acute-care hospital wards, quickly providing diagnostic information directly at the bedside and exactly at the moment of need, and assisting clinicians in guiding invasive procedures¹. Although the acoustic impedance

of the lungs does not allow direct visualization of most chest anatomical structures, chest ultrasound has proven useful for assisting the diagnostic process of the main cardio-respiratory diseases that can be found in acute-care medicine, including pneumonia, pleural effusion, heart failure and pneumothorax ^{2,3}. Each of these conditions may in fact be associated with specific ultrasonographic patterns, that help solving a wide range of diagnostic dilemmas raised by patient history and physical examination ^{2,3}.

Point-of-care chest ultrasound was originally developed in Emergency Departments (EDs) and Intensive Care Units (ICUs) for assisting the diagnostic workup of acute respiratory failure and for guiding thoracentesis, pleural tube and central venous line placement ¹. In the last decade, it also gained popularity in internal medicine and pulmonology wards, for improving patient diagnosis and follow-up ⁴. Its versatility, simplicity and safety have upgraded this technique to the status of a real pillar to bedside physical examination, integrating chest inspection, palpation, percussion and auscultation ⁵.

Critical care physicians increasingly perceive ultrasonography as an essential complement to physical examination ⁶, emphasizing its importance for altering clinical decision making and improving patient care ⁷. However, the availability of chest ultrasonography in the hospital care of developed countries is still inhomogeneous ⁸, particularly outside EDs and ICUs ⁹.

The diffusion of point-of-care ultrasound and practice of chest ultrasound in geriatric wards is still unknown. Despite increasing interest in the topic, ultrasonography is perhaps less popular among geriatricians than any other specialists dealing with acute care ¹⁰. Mobility-limitations, reduced collaboration due to cognitive impairment, multimorbidity and age-related modifications of the respiratory system, typical of geriatric patients, are probably the most important barriers to chest ultrasonography diffusion in geriatric wards ¹¹. Changes of acoustic impedance of the chest wall related to aging and age-related chronic diseases should be also considered as another important factor limiting the use of thoracic ultrasound in geriatric medicine ¹². However, the scientific literature supports the use of chest ultrasound even in older patients with the worst clinical conditions and performance status for assisting the diagnostic workup of respiratory diseases, implying several positive consequences on clinical decision making ¹³⁻¹⁵. In 2018, the Italian Society of Gerontology and Geriatrics (SIGG) has promoted a research group on chest ultrasound in geriatrics (Gruppo di Ricerca sull'Ecografia Toracica nell'Anziano – GRETA), to improve the understanding of the current use of chest ultrasound in Italian geriatric wards and promote research projects on this

theme. The aim of the present investigation was thus to assess availability, uses and applications of chest ultrasonography in a convenience sample of Italian geriatric wards, and understand geriatricians' attitudes towards it.

METHODS

Basing on the current literature state-of-the-art, a questionnaire was developed to explore the topics of interest of chest ultrasound application in Italian geriatric wards. After reviewing the available literature up to April 2018 ¹⁵ GRETA members selected six topics of interest (see the following paragraph) which were discussed and approved by the full GRETA board. All the members of the board were involved in producing the questions, which were submitted and further revised by two external reviewers with experience in geriatric care and ultrasound practice.

A convenience sample of 25 Italian geriatric hospital wards, located throughout the entire nation, was selected. The head doctors of each unit were contacted by e-mail and requested to fill an online form hosted by the SIGG web site.

The questionnaire explored these areas (see Supplementary Material for a sample):

- availability of equipment for performing thoracic ultrasound;
- location where ultrasound is generally performed (i.e., at the bedside vs in a dedicated room);
- expertise of ward physicians on thoracic ultrasound and frequency of utilization;
- most frequent indications for performing thoracic ultrasound in clinical practice;
- perceived or codified role of this technique in different diagnostic paths, with special regard to its integration with X-ray and CT diagnostics;
- impact of thoracic ultrasound on the timing and quality of management of selected conditions and diagnoses (acute dyspnea, volemic state, pleural effusion, pneumonia, acute heart failure).

Data were analyzed anonymously and in aggregated way, as number and percentages, in order to obtain a description of the current chest ultrasound practice and perception in Italian geriatric hospital wards. The software SAS (version 8.2; SAS Institute Inc., Cary, NC, USA) was used for analyses.

RESULTS

The geriatric hospital units, that participated to the survey, are mainly located in academic hospitals (18/25), and host an overall number of 680 beds. A portable

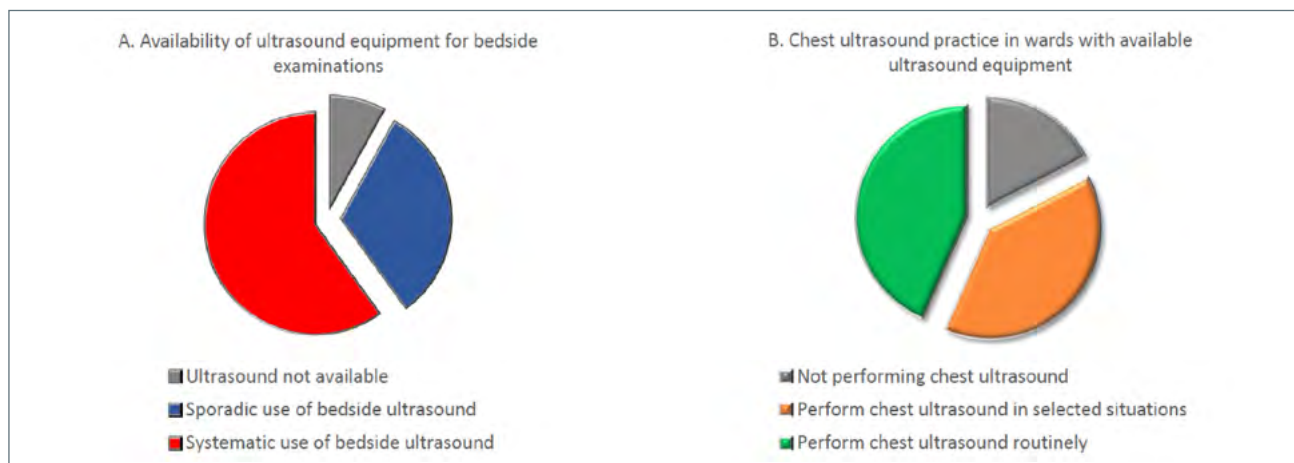


Figure 1. Pie charts showing the availability of ultrasound equipment (A) and the practice of bedside chest ultrasound (B) in a convenience sample of 25 Italian geriatric wards.

ultrasound equipment for performing bedside examinations was present, and used in everyday practice, in 23/25 wards (92%). Bedside ultrasonography was performed systematically in all patients with pertinent clinical indications in fifteen wards (58%), while in the remaining wards ultrasound was performed only sporadically, basing on clinical presentation of patients or due to limitations in the availability of equipment (Figure 1A). Among those who performed bedside ultrasound, chest examinations were performed in the majority of cases (19/23, 82%). However, the ultrasonographic assessment was considered routine in only 10 wards out of 19 (52%), while in other cases it was applied only in selected situations (Fig. 1B).

The number of team members able to perform chest ultrasound was limited: three or less physicians in 13/19 wards (68%), more than 3 physicians in 6/19 wards (32%). However, in 15 academic wards some residents were able to perform thoracic ultrasound.

The main setting of application of thoracic ultrasound was acute-care beds in most cases (17 out of 19),

but in some wards the technique was also applied in subintensive care beds, long-term care beds and even outpatient clinics (4 wards each). In 75% of wards, chest ultrasonography was performed directly at the bedside, while in the remaining wards the setting was a dedicated room outside the ward.

The main indications of chest ultrasound are summarized in Table I. Most head doctors declared that chest ultrasound is performed as a complement to chest X-ray (18/19), either routinely (15/19) or only in case of inconclusive X-ray results (3/19). In one unit, ultrasound was even considered a substitute for X-ray in selected clinical situations. The timing of ultrasound examination is summarized in Table II.

Chest ultrasound was integrated with bedside echocardiography in 14 out of 19 wards (77%). Diaphragmatic ultrasound evaluation was performed in only 4 wards (21%).

With respect of traditional radiography, most head doctors (16/19, 84%) perceived that chest ultrasound can ameliorate the diagnostic process in all cases, while

Table I. Overview of the main clinical indications for which chest ultrasound is performed in a convenience sample of Italian geriatric wards.

Indication	Number of wards	%
Differential diagnosis of acute dyspnea	10/19	53%
Evaluation of volemic state (dry or wet?)	15/19	79%
Diagnosis and follow-up of pleural effusion	18/19	95%
Diagnosis and follow-up of pneumonia	13/19	68%
Diagnosis and follow-up of acute heart failure	17/19	89%
Clinical follow-up of respiratory diseases diagnosed with other methods	9/19	47%
Invasive procedures (thoracentesis, central venous lines)	15/19	79%
Diaphragmatic motility assessment during noninvasive mechanical ventilation	2/19	11%

Table II. Overview of the timing in which chest ultrasound is performed in a convenience sample of Italian geriatric wards.

Timing	Number of wards	%
During physical examination, at the moment of the first evaluation of the patient	13/19	68%
In case of need, during emergency/urgency situations	13/19	68%
In election, following a scheduled agenda	8/19	42%
During clinical follow-up of inflammatory or hemodynamic conditions	12/19	63%

others declared that ultrasound can be useful only in selected cases according to their clinical experience. Forty-seven percent of head doctors (9/19) declared that ultrasound results determined a change in the patient management in a substantial proportion of cases, while 53% (10/19) felt that the diagnostic pathway can benefit from ultrasound results only in selected cases.

DISCUSSION AND CONCLUSIONS

Our survey demonstrated that, in a convenience sample of 25 Italian geriatric hospital wards, bedside ultrasound is generally available, and quite used for exploring the chest in case of respiratory symptoms. However, thoracic ultrasound is not widely applied as a complement to physical examination in around one third of wards, being executed only in selected situations such as assistance to invasive procedures, diagnosis of heart failure and monitoring of pleural effusions. These situations represent the most conventional and consolidated applications of chest ultrasonography.

The use of chest ultrasound in emergency-urgency situations in Italian geriatric wards is limited, since around a half of questionnaire responders declared that this technique is not routinely used for the diagnostic workup of acute dyspnea. This circumstance is probably a consequence of the reduced number of geriatricians trained in chest ultrasonography, since in most wards only three or less staff members are able to perform the examination. It may also be the consequence of a limited confidence in the diagnostic capacity of chest ultrasound. In fact, around a half of geriatric head doctors felt that chest ultrasound was able to change the patient management in only selected cases. However, ultrasound was recognized as potentially able to improve the diagnostic pathway of respiratory diseases by most questionnaire responders. Thus, in a significant percentage of wards chest ultrasound is considered a promising diagnostic examination, but it has not completely entered everyday clinical practice.

This cautious attitude towards chest ultrasound is not in accordance with some of the most recent literature findings, supporting the usefulness of chest ultrasonography in guiding clinical reasoning in the management

of acute dyspnea and for improving the clinical and radiological diagnosis of heart failure, pneumonia, pneumothorax and pleural effusion^{2,3,15-17}. These findings however come from studies performed in EDs, with a case-mix that may not be completely overlapping with geriatric wards.

The cautious attitude of Italian geriatricians towards chest ultrasound could also depend on the knowledge of some intrinsic limitations of the technique, that may be emphasized in older patients. In fact, ultrasound cannot investigate deeper regions of the chest and as much as 30% of the pleural surface, leading to a significant number of false negative scans in pneumonia, lung cancer and pneumothorax¹⁸⁻²⁰. For example, according to a recent study, in a large series of chest radiography-confirmed pneumonia, thoracic ultrasound missed the detection of 26.5% of lesions, proving useful only for follow-up of viewable consolidations²¹. Moreover, B-lines, the comet-tail artifacts commonly associated with pulmonary congestion, do not allow to distinguish pulmonary edema from alternative causes of congestion in a small, but significant number of cases²².

Besides this attitude, there is also a significant number of wards where chest ultrasound is performed in many different clinical situations, including also advanced applications, such as diaphragm ultrasound assessment during non-invasive ventilation and integration with transthoracic echocardiography. M-mode diaphragm ultrasound is a highly reproducible technique²³, that can help to predict the outcome of mechanical ventilation even in geriatric patients²⁴. In one ward, the integration of chest ultrasound with clinical data could even be utilized as a replacement for X-ray, especially for monitoring the course of different respiratory diseases. This advanced utilization is supported by data from the scientific literature, highlighting that the diagnostic capacity, in terms of Area Under the Receiver Operating Characteristic curve, of ultrasound for the diagnosis of pneumonia is significantly better than that of traditional X-ray^{25,26}.

Chest ultrasound is also particularly popular among young geriatricians and geriatricians in training. In two thirds of the wards participating to the survey, residents are trained in chest ultrasonography. This circumstance is particularly qualifying for Italian post-graduate

geriatric training courses, and adherent to the most recent recommendations by scientific societies that support the necessity of providing ultrasound training to young physicians²⁷⁻²⁹. However, the ultrasound training of geriatric residents is not generally formalized into a scheduled education program. The recent development of a European curriculum in Geriatric Emergency Medicine, identifying the essential skills of geriatricians delivering acute care, should represent a great opportunity to include chest ultrasound training in geriatric education³⁰.

Chest ultrasound is useful for assisting the diagnostic process even in the hands of physicians in training with limited clinical and ultrasonographic experience, particularly when the integration of ultrasound with clinical data suggests a focused diagnostic question³¹⁻³³. Unlike abdominal ultrasound, a limited number of examinations seems to be required to achieve a sufficient level of competency in basic chest ultrasound³¹⁻³³ while prolonged and continuous training is of course necessary for advanced applications. This is probably one of the most important points of strength of this technique, that should be particularly developed in the geriatric setting, where the complexity of patients in many cases prevents the prescription of advanced imaging tests. Standardization of training methods and rigorous definition of reporting is however required, to avoid inhomogeneity and misuse of applications³⁴.

Our survey has certainly some limitations, due to the relatively reduced number of participating wards and methodology of data collection (e-mailed questionnaire). However, we believe that it provides a quite reliable pictures of the current utilization of chest ultrasound, and attitudes towards it, in Italian acute-care geriatric wards. Some critical issues highlighted by our survey (reduced number of trained physicians, lack of a formalized training pathway, disparity in utilization) consistently overlap with the findings of similar surveys conducted in EDs, ICUs and acute-care units of other countries^{7-9,35,36}. However, the attitude of geriatricians towards chest ultrasound is generally more cautious than that of emergency physicians, that consider this technique as an essential skill for everyday practice^{7,36}. Chest ultrasound should therefore be implemented in geriatric practice and research, promoting training courses among geriatricians and making them aware of the advantages of this diagnostic method in the patient care. The GRETA Group is currently planning research and training initiatives to spread chest ultrasound techniques in geriatric wards, standardize its applications and promote education for young geriatricians, with the ultimate aims of advancing knowledge for a better patient care and filling the gap of ultrasound competency with other internal medicine specialties.

References

- 1 Moore CL, Copel JA. Point-of-care ultrasonography. *N Engl J Med* 2011;364:749-57. <https://doi.org/10.1056/NEJMra0909487>
- 2 Volpicelli G, Elbarbary M, Blavais M, et al. International evidence-based recommendations for point-of-care lung ultrasound. *Intensive Care Med* 2012;38:577-591. <https://doi.org/10.1007/s00134-012-2513-4>
- 3 Staub LJ, Mazzali Biscaro RR, Kaszubowski E, et al. Lung ultrasound for the emergency diagnosis of pneumonia, acute heart failure, and exacerbations of chronic obstructive pulmonary disease/asthma in adults: a systematic review and meta-analysis. *J Emerg Med* 2019;56:53-69. <https://doi.org/10.1016/j.jemermed.2018.09.009>
- 4 Arienti V, Camaggi V. Clinical applications of bedside ultrasonography in internal and emergency medicine. *Intern Emerg Med* 2011;6:195-201. <https://doi.org/10.1007/s11739-010-0424-3>
- 5 Narula J, Chandrashekar Y, Braunwald E. Time to add a fifth pillar to bedside physical examination: inspection, palpation, percussion, auscultation, and insonation. *JAMA Cardiol* 2018;3:346-50. <https://doi.org/10.1001/jamacardio.2018.0001>
- 6 Dulohery MM, Stoven S, Kurklinsky A, et al. Ultrasound for internal medicine physicians: the future of the physical examination. *J Ultrasound Med* 2014;33:1005-1011. [Doi: 10.7863/ultra.33.6.1005](https://doi.org/10.7863/ultra.33.6.1005).
- 7 Smallwood N, Matsa R, Lawrenson P, et al. A UK wide survey on attitudes to point of care ultrasound training amongst clinicians working on the Acute Medical Unit. *Acute Med* 2015;14:158-68.
- 8 Bobbia X, Abou-Badra M, Hansel N, et al. Changes in the availability of bedside ultrasound practice in emergency rooms and prehospital settings in France. *Anaesth Crit Care Pain Med* 2018;37:201-5. <https://doi.org/10.1016/j.accpm.2017.06.008>
- 9 Stowell JR, Kessler R, Lewiss RE, et al. Critical care ultrasound: a national survey across specialties. *J Clin Ultrasound* 2018;46:167-77. <https://doi.org/10.1002/jcu.22559>
- 10 Leone AF, Schumacher SM, Krotish DE, et al. Geriatricians' interest to learn bedside portable ultrasound (GEBUS) for application in the clinical practice and in education. *J Am Med Dir Assoc* 2012;13:308.e7-308.e10. <https://doi.org/10.1016/j.jamda.2011.06.002>
- 11 Ciccarese F, Chiesa AM, Feletti F, et al. The senile lung as a possible source of pitfalls on chest ultrasonography and computed tomography. *Respiration* 2015;90:56-62. <https://doi.org/10.1159/000430994>
- 12 Occhipinti M, Larici AR, Bonomo L, et al. Aging airways: between normal and disease. A multidimensional diagnostic approach by combining clinical, functional, and imaging data. *Aging Dis* 2017;8:471-85. <https://doi.org/10.14336/AD.2016.1215>
- 13 Ticinesi A, Lauretani F, Nouvenne A, et al. Lung ultrasound and chest X-ray for detecting pneumonia in an acute-care geriatric ward. *Medicine* 2016;95:e4153. <https://doi.org/10.1097/MD.0000000000004153>

- 14 Fröhlich E, Beller K, Muller R, et al. Point of care ultrasound in geriatric patients: prospective evaluation of a portable handheld ultrasound device. *Ultraschall Med* 2019. <https://doi.org/10.1055/1-0889-8070> [Epub ahead of print]
- 15 Ticinesi A, Scarlata S, Nouvenne A, et al. The geriatric patient: the ideal one for chest ultrasonography? a review from the chest ultrasound in the Elderly Study Group (GRETA) of the Italian Society of Gerontology and Geriatrics (SIGG). *J Am Med Dir Assoc* 2019; in press. <https://doi.org/10.1016/j.jamda.2019.06.018> [Epub ahead of print]
- 16 Wallbridge P, Steinfurt D, Tay TR, et al. Diagnostic chest ultrasound for acute respiratory failure. *Respir Med* 2018;141:26-36. <https://doi.org/10.1016/j.rmed.2018.06.018>
- 17 Alzahrani SA, Al-Salamah MA, Al-Madani WH, et al. Systematic review and meta-analysis for the use of ultrasound versus radiology in diagnosing of pneumonia. *Crit Ultrasound J* 2017;9:6. <https://doi.org/10.1186/s13089-017-0059-y>
- 18 Sperandeo M, Rotondo A, Guglielmi G, et al. Transthoracic ultrasound in the assessment of pleural and pulmonary diseases: use and limitations. *Radiol Med* 2014;119:729-470. <https://doi.org/10.1007/s11547-014-0385-0>
- 19 Trovato G, Sperandeo M. Lung ultrasound in pneumothorax: the continuing need for radiology. *J Emerg Med* 2016;51.2:189-91. <https://doi.org/10.1016/j.jemermed.2015.01.045>
- 20 Tinti MG, Cipriani C, De Cosmo S, et al. Pneumothorax and air bronchogram in transthoracic ultrasound: basic considerations. *Ultrasound Med Biol* 2019;45:1500. <https://doi.org/10.1016/J.ultrasmedbio.2019.02.006>
- 21 D'Amato M, Rea G, Carnevale V, et al. Assessment of thoracic ultrasound in complementary diagnosis and in follow-up of community-acquired pneumonia (cap). *BMC Med Imaging* 2017;17:52. <https://doi.org/10.1186/s12880-017-0225-5>
- 22 Trovato GM, Sperandeo M. Sounds, ultrasounds, and artifacts: which clinical role for lung imaging? *Am J Respir Crit Care Med* 2013;187:780-1. <https://doi.org/10.1164/ajrccm.187.7.780>
- 23 Scarlata S, Mancini D, Laudisio A, et al. Reproducibility and clinical correlates of supine diaphragmatic motion measured by M-mode ultrasonography in healthy volunteers. *Respiration* 2018;96:259-66. <https://doi.org/10.1159/000489229>
- 24 Huang D, Ma H, Zhong W, et al. Using M-mode ultrasonography to assess diaphragm dysfunction and predict the success of mechanical ventilation weaning in elderly patients. *J Thorac Dis* 2017;9:3177-86. <https://doi.org/10.21037/jtd.2017.08.16>
- 25 Chavez MA, Shams N, Ellington LE, et al. Lung ultrasound for the diagnosis of pneumonia in adults: a systematic review and meta-analysis. *Respir Res* 2014;15:50. <https://doi.org/10.1186/1465-9921-15-50>
- 26 Ye X, Xiao H, Chen B, et al. Accuracy of lung ultrasonography versus chest radiography for the diagnosis of adult community-acquired pneumonia: review of the literature and meta-analysis. *PLoS One* 2015;10(6):e0130066. <https://doi.org/10.1371/journal.pone.0130066>
- 27 Ma IWY, Arishenkoff S, Wiseman J, et al. Internal medicine point-of-care ultrasound curriculum: consensus recommendations from the Canadian Internal Medicine Ultrasound (CIMUS) Group. *J Gen Intern Med* 2017;32:1052-7. <https://doi.org/10.1007/s11606-017-4071-5>
- 28 Cantisani V, Dietrich CF, Badea R, et al. EFSUMB statement on medical student education in ultrasound. *Ultrasound Int Open* 2016;2:E2-7. <https://doi.org/10.1055/s-0035-1569413>
- 29 Arienti V, Di Giulio R, Cogliati C, et al. Bedside ultrasonography (US), echoscopy and US point of care as a new kind of stethoscope for Internal Medicine Departments: the training program of the Italian Internal Medicine Society (SIMI). *Intern Emerg Med* 2014;9:805-14. <https://doi.org/10.1007/s11739-014-1113-4>
- 30 Conroy S, Nickel CH, Jónsdóttir AB, et al. The development of a European curriculum in Geriatric Emergency Medicine. *Eur Geriatr Med* 2016;7:315-21. <https://doi.org/10.1016/j.eurger.2016.03.011>
- 31 Andersen GN, Viset A, Mjølstad OC, et al. Feasibility and accuracy of point-of-care pocket-size ultrasonography performed by medical students. *BMC Med Educ* 2014;14:156. <https://doi.org/10.1186/1472-6920-14-156>
- 32 Begot E, Grumann A, Duvoid T, et al. Ultrasonographic identification and semiquantitative assessment of unoculated pleural effusions in critically ill patients by residents after a focused training. *Intensive Care Med* 2014;40:1475-80. <https://doi.org/10.1007/s00134-014-3449-7>
- 33 Mozzini C, Fratta Pasini AM, Garbin U, et al. Lung ultrasound in internal medicine: training and clinical practice. *Crit Ultrasound J* 2016;8:10. <https://doi.org/10.1186/s13089-016-0048-6>
- 34 Pietersen PI, Madsen KR, Graumann O, et al. Lung ultrasound in training: a systematic review of published literature in clinical lung ultrasound training. *Crit Ultrasound J* 2018;10:23. <https://doi.org/10.1186/s13089-018-0103-6>
- 35 Fischer LM, Woo MY, Lee AC, et al. Emergency medicine point-of-care ultrasonography: a national needs assessment of competencies for general and expert practice. *Can J Emerg Med* 2015;17:74-82. <https://doi.org/10.2310/8000.2013.131205>
- 36 Hansen W, Mitchell CE, Bhattarai B, et al. Perception of point-of-care ultrasound performed by Emergency Medicine physicians. *J Clin Ultrasound* 2017;45:408-15. <https://doi.org/10.1002/jcu.22443>



GRETA: Gruppo di Ricerca Ecografia Toracica nell'Anziano della SIGG



SURVEY ON THORACIC ULTRASOUND AVAILABILITY, PRACTICE AND PERCEPTION IN ITALIAN GERIATRIC WARDS

Number of ward beds _____

Academic Hospital: YES NO

Teaching ward: YES NO

1. Is portable ultrasound equipment available in your ward?

- YES
- NO

2. Is clinical bedside ultrasound (abdomen, vascular, thyroid, fast protocols for trauma assessment) performed in your ward?

- YES
- NO

3. If yes, how much frequently?

- Every day, in all patients who have a clinical indication for it
- Only in selected situations and not every day, based on clinical conditions and ultrasound availability
- Not applicable

4. Is bedside chest ultrasound performed in your ward?

- YES
- NO

If no, please go to question number 20.

**GRETA: Gruppo di Ricerca Ecografia Toracica nell'Anziano della SIGG**

5. If yes, how much frequently is chest ultrasound performed?
- Every day, in all patients who have a clinical indication for it
 - Only in selected situations and not every day, based on clinical conditions and ultrasound availability
6. How many physicians are able to perform chest ultrasound in your ward? _____
7. In your ward, are there any physicians in training or residents able to perform chest ultrasound under the supervision of a tutor?
- YES
 - NO
8. In which clinical setting is chest ultrasound performed in your ward? (Multiple answers allowed)
- Intensive or Subintensive Care
 - Acute-care ward
 - Long-term care ward
 - Outpatient clinic
9. Where is chest ultrasound performed?
- At the bedside
 - In a separate room, devoted to ultrasound, inside the ward
 - In a separate room, devoted to ultrasound, outside the ward
 - Not applicable
10. For what clinical questions is chest ultrasound performed in your ward? (Multiple answers allowed)
- Differential diagnosis of acute dyspnea/respiratory insufficiency
 - Volemic state evaluation (dry or wet?)



GRETA: Gruppo di Ricerca Ecografia Toracica nell'Anziano della SIGG



- Diagnosis/follow-up of pleural effusions
- Diagnosis/follow-up of pneumonia
- Diagnosis/follow-up of acute heart failure
- Clinical monitoring of respiratory conditions diagnosed with other examinations
- Invasive procedures (thoracentesis, central venous line, pleural drainage)
- Evaluation of diaphragm motility
- Other (please specify _____)

11. With respect to traditional chest X-ray, how is chest ultrasound used in your ward practice?

- Ultrasound is performed as a substitute for chest X-ray
- Ultrasound is used to integrate chest X-ray irrespective of X-ray findings
- Ultrasound is used to integrate chest X-ray only if X-ray yields negative or uncertain results, or results that are not in accordance with the clinical presentation
- Other (please specify _____)

12. When is chest ultrasound performed on acute patients in your ward's clinical practice? (Multiple answers allowed)

- In combination with the physical examination, at the moment of the first evaluation
- In case of urgency
- Following a scheduled program
- For monitoring inflammatory and circulatory conditions, without a specified schedule
- Chest ultrasound is not performed on acute patients

**GRETA: Gruppo di Ricerca Ecografia Toracica nell'Anziano della SIGG**

13. Is chest ultrasound integrated with bedside transthoracic echocardiography in your ward's practice?

- YES
- NO

14. Is chest ultrasound integrated with ultrasound evaluation of diaphragmatic motility in your clinical practice?

- YES
- NO

15. Based on your personal experience, do you feel that chest ultrasound improves the diagnostic pathway of older patients with dyspnea or other acute respiratory symptoms, as compared to X-ray?

- In every situation
- Only if chest X-ray results negative
- Only in selected situations
- Never

16. How much frequently do chest ultrasound findings change the clinical management of geriatric patients admitted to your ward?

- Very often
- Only in some selected cases
- Rarely
- Never

17. Do you feel that the use of chest ultrasound has contributed to decrease the number of chest Computed Tomography prescriptions in your ward?

- YES
- NO
- NOT ABLE TO JUDGE