

Endoscopic management of bile leaks after liver transplantation: An analysis of two high-volume transplant centers

United European Gastroenterology Journal
2018, Vol. 6(1) 89–96
© Author(s) 2018
Reprints and permissions:
sagepub.co.uk/journalsPermissions.nav
DOI: 10.1177/2050640617712869
journals.sagepub.com/home/ueg



Oriol Sendino^{1,2}, Alejandro Fernández-Simon^{1,3}, Ryan Law⁴,
Barham Abu Dayyeh⁵, Michael Leise⁵, Karina Chavez-Rivera^{1,2},
Henry Cordova^{1,2}, Jordi Colmenero^{2,6}, Gonzalo Crespo^{2,6},
Cristina Rodriguez de Miguel^{1,2}, Constantino Fondevila^{2,7}, Josep Llach^{1,2},
Miquel Navasa^{2,6}, Todd Baron⁸ and Andrés Cárdenas^{1,2,6}

Abstract

Background: Bile leak after liver transplantation (LT) is commonly treated with endoscopic retrograde cholangiopancreatography (ERCP); however, there are limited data regarding the optimal treatment strategy.

Objective: We aimed to examine the role of ERCP in LT recipients with bile leaks at two large institutions.

Methods: We reviewed all ERCPs performed in LT recipients with bile leak and duct-to-duct biliary anastomosis at two high-volume transplant centers.

Results: Eighty patients were included. Forty-seven (59%) patients underwent ERCP with plastic stent placement (with or without sphincterotomy) and 33 patients (41%) underwent sphincterotomy alone. Complete resolution was obtained in 94% of the stent group vs. 58% of the sphincterotomy group ($p < 0.01$). There was no difference in three-month survival among both groups. Percutaneous transhepatic therapy and surgery were required in 4% and 6% in the stent group vs. 12% and 42% in the sphincterotomy group, respectively ($p = 0.22$ and $p < 0.001$). The only predictive factor of bile leak resolution was stent placement.

Conclusion: ERCP with plastic stent placement is highly successful and more effective than sphincterotomy alone for post-LT bile leak treatment. These results indicate that ERCP and plastic stent placement should be considered the standard of care for the treatment of bile leaks in LT.

Keywords

Bile leak, liver transplantation, biliary complications, endoscopic retrograde cholangiopancreatography, sphincterotomy, biliary strictures, plastic stents, biliary stenting

Received: 20 February 2017; accepted: 6 May 2017

Introduction

Biliary adverse events constitute an important cause of morbidity and mortality in patients after liver transplantation (LT). Among the different types of biliary adverse events after LT, bile leak is the second most

⁵Division of Gastroenterology and Hepatology, Mayo Clinic, Rochester, MN, USA

⁶Liver Unit, Institut de Malalties Digestives i Metabòliques, Hospital Clínic and University of Barcelona, Spain

⁷General and Digestive Surgery, Institut de Malalties Digestives i Metabòliques, Hospital Clínic, and University of Barcelona, Spain

⁸Division of Gastroenterology and Hepatology, University of North Carolina, Chapel Hill, NC, USA

O.S. and A.F.-S. contributed equally to this manuscript.

Corresponding author:

Andrés Cárdenas, Institut de Malalties Digestives i Metabòliques, University of Barcelona, Hospital Clínic-Villarroel 170, Esc 3-2, 08036 Barcelona, Spain.

Email: acardena@clinic.ub.es

¹GI/Endoscopy Unit, Institut de Malalties Digestives i Metabòliques, Hospital Clínic, and University of Barcelona, Spain

²Institut d'Investigacions Biomèdiques August Pi-Sunyer (IDIBAPS), Ciber de Enfermedades Hepáticas y Digestivas (CIBEREHD), Barcelona, Spain

³GI Unit, Hospital Sant Joan Despí Moises Broggi, Barcelona, Spain

⁴Department of Medicine and Division of Gastroenterology, University of Michigan, MI, USA

frequent with an incidence of 2% to 25%.¹⁻⁷ Bile leaks are classified as anastomotic, T-tube-related, cystic duct-related or, in the case of living donor liver transplants (LDLT), cut-surface-related.⁶ Common risk factors for the development of bile leaks are related to surgical technique, hepatic artery thrombosis, LT from donors after cardiac death, ABO mismatch, prolonged warm and cold ischemia times, and T-tube use.⁸ The standard of care for the treatment of bile leaks after LT is not well established. Patients with a peri-T-tube leak can sometimes be managed conservatively by keeping the T-tube drainage open for a prolonged period of time.⁹ Endoscopic retrograde cholangiopancreatography (ERCP) is also very effective and high-resolution rates are near 90%.^{1-4,6-8} A variety of ERCP techniques have been described for managing leaks, including: nasobiliary drainage,¹⁰⁻¹³ sphincterotomy alone,¹⁴⁻¹⁷ plastic biliary stent placement with or without sphincterotomy,^{3,4,6,7,18-24} and placement of fully covered self-expandable metallic stents (FCSEMS).²⁵⁻²⁷ Regardless of method used, the suggested mechanism of healing relates to the equalization of pressures in the bile duct and duodenum, which allows antegrade bile flow into the duodenum.^{8,10} Nevertheless, the optimal endoscopic approach has not yet been established and to date there are very few studies that compare the different endoscopic treatment options. In addition, there are no data that define factors predictive of endoscopic success in patients with post-LT bile leaks. The aim of this analysis was to evaluate data from two large institutions to determine the role of ERCP in the treatment of bile leaks following LT.

Materials and methods

This study was approved by the Ethical and Institutional Review Board at the Hospital Clinic of Barcelona (Barcelona, Spain) and Mayo Clinic (Rochester, MN, USA). The protocol, Evaluation of Endoscopic Therapy of Bile Leaks after Liver Transplantation, was approved at both institutions in May and August 2015. The study protocol conforms to the ethical guidelines of the 1975 Declaration of Helsinki as reflected in a prior approval by the institutions' human research committee. Informed consent of the procedures was obtained from all patients included in the study. LT recipients with clinical or radiologic suspicion of a bile leak referred for ERCP were included. We reviewed all ERCPs in patients following LT at Mayo Clinic from July 2000 to June 2013 and at Hospital Clinic from January 2003 through January 2015. Mayo Clinic performs between 100 and 120 LTs and approximately 2000 ERCPs yearly. Hospital Clinic performs between 80 and 90 LTs and

approximately 450 ERCPs yearly. Data were collected and entered after each case. The electronic medical records and endoscopy database of both institutions were accessed to abstract demographic, clinical, surgical, and endoscopic data. All procedures were performed with sedation, with levels from moderate to general anesthesia. All patients received intravenous broad-spectrum prophylactic antibiotics. Administration of pharmacologic agents and pancreatic stent placement for prevention of post-ERCP pancreatitis were not routinely performed.

ERCP was performed using standard techniques. After cannulation, cholangiography was performed to confirm the leak. If necessary, an occlusion cholangiogram using a balloon catheter was performed to determine the leak site. After confirmation of the bile leak, endoscopic intervention (complete sphincterotomy or stent with or without complete sphincterotomy) was performed at the proceduralist's discretion. Biliary stents were placed across the site of the bile leak, when technically feasible; in some cases patients were treated with biliary sphincterotomy alone.

Definitions

Bile leaks were diagnosed based on the following criteria: (1) clinical symptoms (i.e. abdominal pain, ascites, fever and/or jaundice); (2) the presence of a new fluid collection consistent with a leak on cross-sectional imaging; (3) increasing or persistent bilious output from an intra-abdominal drain; (4) extravasation of contrast seen on T-tube cholangiography. Intrahepatic leaks were defined as extravasation of contrast due to bile duct rupture and extravasation of bile into the hepatic parenchyma. Patients with a peri-T-tube leak were referred for an ERCP only if the condition persisted after leaving the T-tube to open drainage. We only included patients with a suspected bile leak confirmed by ERCP.

We defined resolution of the bile leak as the cessation of symptoms and drain output, and/or the absence of contrast extravasation on ERCP performed eight weeks after the initial ERCP, with a maximum of two more ERCP treatments. In contrast to postcholecystectomy leaks, where the stent is usually removed in four weeks, in post-LT leaks it is preferred the stent be left in place for approximately eight weeks because of potential problems with delayed healing that may occur because of immunosuppression.⁶ If initial resolution was not achieved after the placement of one biliary stent, a posterior ERCP was performed using a larger diameter biliary stent or by placement of an additional biliary stent. FCSEMS were not placed in any patient. Those patients with persistent leaks were referred for surgery or percutaneous transhepatic

biliary drainage (PTBD) and were categorized as failures. Definitions of individual adverse events and their severity after ERCP (i.e. pancreatitis, cholangitis, hemorrhage, perforation) were defined by criteria as established by Cotton et al.^{28,29} Mild events were considered when hospitalization was prolonged by two to three days, moderate by 4–10 days, and severe by more than 10 days.

Statistical analysis

Patient demographics, clinical and procedure data and outcomes were analyzed. χ^2 or Fisher exact test were used for categorical variables and the Student *t*-test for continuous variables. Univariate analysis was conducted to explore the relationships between the patients' characteristics, the type of transplantation, the presence of a T-tube, immunosuppression therapy, the type of leak, the location of the leak, the presence of a stricture, resolution of the bile leak, the time of resolution and the need for percutaneous transhepatic cholangiography (PTC) or surgery. Independent factors associated with resolution of bile leak were studied using a stepwise multivariate logistic regression model that used initial inclusion criteria with a significance of $p \leq 0.05$, using SPSS statistical packages (version 20.0; SPSS Inc, Chicago, IL). For this purpose, patients with a resolved bile leak (resolution group) were compared with those who presented with persistent bile leak after follow-up (persistent leak group), as defined previously. A $p \leq 0.05$ was considered statistically significant.

Results

A total of 80 patients were included, 45 at Hospital Clinic and 35 at the Mayo Clinic (mean age 55 years, 73% male). The baseline characteristics of patients are shown in Table 1. Overall, 75% were recipients of a cadaveric liver and 24% were living donor recipients. Two-thirds of the patients had a T-tube after LT. The incidence of known risk factors for bile leak was low: hepatic artery thrombosis (9%), donors after cardiac death (5%) and ABO blood group mismatch (1%).

Endoscopic findings are shown in Table 2. The location of bile leaks was as follows: biliary anastomosis (45%), T-tube (34%), intrahepatic (10%), cystic duct remnant (9%), cut surface (2%). A concomitant anastomotic biliary stricture was identified in 28% of patients (Figure 1). The median time from LT to ERCP was 32.25 (16–73.5) days. Biliary stent placement was performed in 47 patients, 41 with sphincterotomy and six without sphincterotomy. The median number of biliary stents placed per case was one. All were plastic stents and the majority (31/47) were 10F stents. Thirty-three patients (41%) underwent biliary

Table 1. Patient baseline characteristics.

PATIENT CHARACTERISTICS	n (%)
Gender (M/F)	58/22 (72.5%/22.5%)
Age (years)	54.7 ± 10.3
Indication/etiology of LT	
HCV	33 (41.3%)
Alcohol	14 (17.5%)
HCC	23 (28.8)
Others	10 (12.5%)
Type of LT	
DDLT	60 (75%)
LDLT	19 (24%)
Split	1 (1%)
T-tube	60 (75%)
Risk factors for bile leakage	
Hepatic artery thrombosis.	7 (9%)
Donor after cardiac death	4 (5%)
ABO mismatch	1 (1%)
Immunosuppression therapy	
Tacrolimus	61 (76.3%)
Cyclosporine	9 (11.3%)
Prednisone	75 (93.8%)
Mycophenolic acid	48 (60%)
Sirolimus	5 (6.3%)

M: male; F: female; LT: liver transplant; HCV: hepatitis C virus; HCC: hepatocellular carcinoma; DDLT: deceased donor liver transplant; LDLT: living donor liver transplant.

Table 2. Endoscopic findings.

TYPE OF LEAK	n (%)
Anastomotic leak	36 (45%)
Peri-T-tube leak	27 (34%)
Spontaneous	13 (16%)
After removal of T-tube	14 (17%)
Intrahepatic	8 (10%)
Cystic	7 (9%)
Cut surface leak	2 (2%)
Anastomotic stricture	22 (28%)

sphincterotomy alone (30 at Hospital Clinic and three at Mayo Clinic-Rochester). The mean number of ERCPs performed per patient was 1.8. The majority of patients (60, 75%) required only one ERCP procedure for bile leak resolution and 19 (23.8%) required two ERCP procedures. One patient with a non-anastomotic bile leak required three ERCPs. There were 12 cases of a failed attempt to place a biliary stent. Of these 12

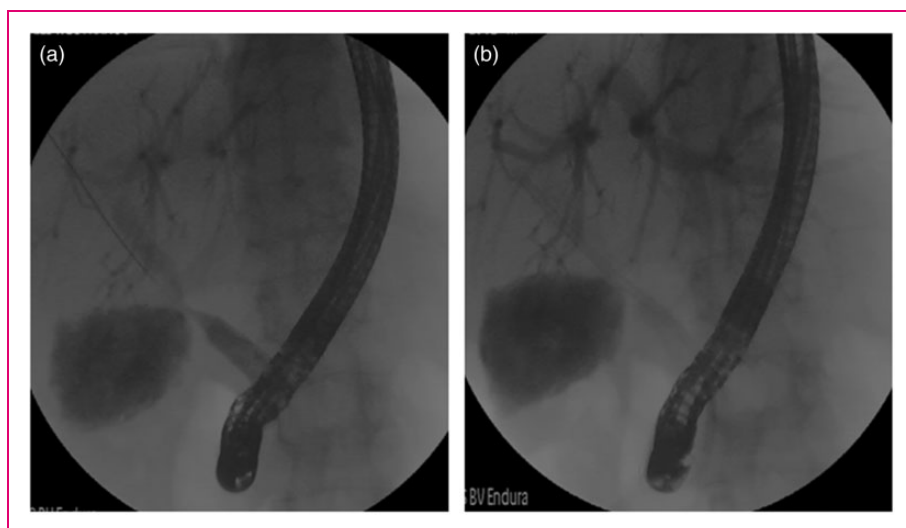


Figure 1. Characteristic findings of a bile leak with an anastomotic stricture. (a) Bile leak and anastomotic stricture. (b) Stent placement across the bile leak site.

Table 3. Factors associated with bile leak resolution.

	Resolution group (n = 63)		Persistent leak group (n = 17)		p value
Univariate analysis					
Sex (M/F)	45/18		13/4		NS
Arterial thrombosis rate (n (%))	5	(7.9%)	2	(11.8%)	NS
ABO mismatch rate (n (%))	0	0	1	(5.9%)	NS
LDLT (n (%))	3	(4.8%)	1	(5.9)	NS
HCV (n (%))	27	(42.9%)	6	(35.3%)	NS
HCC (n (%))	19	(30.2%)	4	(23.5)	NS
Use of T-tube (n (%))	48	(76.2%)	12	(70.6%)	NS
Tacrolimus (n (%))	51	(81%)	10	(58.8%)	0.06
Cyclosporine (n (%))	5	(7.9%)	4	(23.5%)	0.09
Sirolimus (n (%))	3	(4.8%)	2	(11.8%)	NS
Mycophenolic acid (n (%))	43	(68.3%)	5	(29.4%)	.005
Corticosteroids (n (%))	59	(93.7%)	16	(94.1%)	NS
Anastomotic location (n (%))	26	(41.3%)	10	(58.8%)	NS
Anastomotic stricture (n (%))	15	(23.8%)	7	(41.2%)	NS
Time of LT > 3 months (n (%))	12	(19%)	2	(11.8%)	NS
Stent placement (n (%))	44	(69.8%)	3	(17.6%)	<0.001

M: male; F: female; LDLT: living donor liver transplant; HCV: hepatitis C virus; HCC: hepatocellular carcinoma; LT: liver transplant.

cases in two the stent could not be placed because of a large disruption and inability to pass the guidewire into a proximal bile duct. In the remaining 10 cases the stent was not placed because of concomitant stricture that could not be traversed with a guidewire in order to place a stent.

Factors associated with bile leak resolution were analyzed with univariate and multivariate analysis as shown in Table 3 and 4. The only predictive factor of bile leak resolution on the multivariate analysis was ERCP with stent placement (odds ratio, 8.36; 95% confidence interval, 1.79–39.03; $p = 0.007$)

Table 4. Multivariate logistic regression model assessing factors associated with resolution of bile leaks after liver transplantation.

	Coefficient	Standard error	OR	(CI 95%)	<i>p</i> value
Tacrolimus	1.028	0.920	2.79	(0.46–16.95)	0.264
Cyclosporine	0.504	1.153	1.65	(0.17–15.86)	0.662
Mycophenolic acid	0.925	0.665	2.52	(0.68–9.28)	0.167
Stent placement	2.124	0.786	8.36	(1.79–39.03)	0.007

OR: odds ratio; CI: confidence interval.

Table 5. ERCP and patient-related outcomes.

	Stent group (<i>n</i> = 47)	Sphincterotomy alone group (<i>n</i> = 33)	<i>p</i> value
RESOLUTION (<i>n</i> (%))	44 (93.6%)	19 (57.6%)	<0.001
NEED FOR PTBD (<i>n</i> (%))	2 (4.3%)	4 (12.1%)	NS
NEED FOR SURGERY (<i>n</i> (%))	3 (6.4%)	14 (42.4%)	<0.001
SURVIVAL (3 months) (<i>n</i> (%))	44 (93.6%)	30 (90.9%)	NS

ERCP: endoscopic retrograde cholangiopancreatography; PTBD: percutaneous transhepatic biliary drainage.

(Table 4). ERCP and patient-related outcomes are outlined in Table 5. Overall resolution of bile leaks with ERCP therapy was observed in 63 out of 80 (79%) patients. The resolution rate per location was: anastomotic leak (72.2%), T-tube-related leak (88.9%), intrahepatic (87.5%), cystic remnant leak (71.4%) and cut surface leak (50%), (Supplementary table). Successful resolution of bile leak occurred in 93.6% of patients in the biliary stent group and 57.6% of the sphincterotomy group ($p < 0.01$). There was no difference in three-month survival between groups.

Failure of ERCP therapy occurred in 14 (42.4%) patients in the sphincterotomy group and three patients in the stent group (6.4%). In these cases, two patients underwent PTBD, two patients underwent PTBD plus surgery and 11 underwent surgery without prior PTBD. In two patients no further therapy was performed. Eight (10%) patients developed post-ERCP adverse events: mild acute pancreatitis ($n = 5$), mild bleeding ($n = 2$), and mild pancreatitis with concomitant cholangitis ($n = 1$). All adverse events were managed conservatively.

Discussion

We sought to analyze ERCP-guided treatment approaches for patients with bile leaks after LT. The results of this analysis from two large academic medical centers indicate that ERCP therapy with placement of a biliary plastic stent (with or without biliary sphincterotomy) is highly successful and significantly more effective than biliary sphincterotomy alone.

Bile leaks are the second most common biliary adverse event following LT and constitute significant morbidity for LT recipients. In addition, bile leaks are considered an independent risk factor for the development of early or late anastomotic biliary strictures and thus require a prompt, safe and highly effective therapy.^{8,30–32} In this analysis 75% of patients had T-tube placement. T-tubes have been routinely placed as a prophylactic measure for anastomotic stricture development. However, the results of several comparative studies, systematic reviews and meta-analyses suggest no major differences in the incidence of biliary complications, and the current trend has favored more the abandonment of the use of T-tubes after LT in most centers.³³ Most bile leaks can be resolved non-operatively with early intervention. The most widely accepted treatment approach in patients with a duct-to-duct biliary anastomosis is early ERCP-guided endoscopic therapy.^{1–4,6–8} ERCP-guided endoscopic therapy of bile leaks can be performed with a combination of biliary sphincterotomy and plastic stent placement or with sphincterotomy alone. Some authors propose the use of biliary sphincterotomy alone as it is easy to perform and patients do not require a subsequent ERCP for stent removal; however, most of the available data supporting this practice stem from patients with bile leaks following cholecystectomy.^{14,16,34,35} In the case of bile leaks after LT, available data regarding the use of biliary sphincterotomy alone for bile leaks are scant and limited to large series of patients treated for an array of biliary adverse events after LT.^{14–17} The success rate of this approach in LT is poorly understood as no randomized controlled trials have directly compared this strategy to sphincterotomy plus biliary plastic stent placement. We believe plastic stent placement for bile leaks after LT has the advantage of preferentially diverting bile flow to the duodenum through the elimination of the transpapillary pressure gradient, and perhaps could be the reason why stent placement was responsible for better outcomes when compared to sphincterotomy alone. In this analysis, a center effect was clear as most of the cases with sphincterotomy alone were performed at Hospital Clinic. The resolution rate at Hospital Clinic was 69% vs. 91% at Mayo Clinic ($p = 0.014$). That said, the center effect is driven only by the fact that sphincterotomy alone was

performed mostly at Hospital Clinic. We did not find other differences in relation to the type of surgical technique or risk factors for bile leaks. Therefore, we believe this approach should be preferred over sphincterotomy alone as it appears to increase antegrade bile flow, subsequently promoting healing at the leakage site.

Several studies have reported outcomes of endoscopic therapy for bile leaks after LT, but to our knowledge this is the only study that has analyzed the effectiveness of biliary sphincterotomy alone vs. plastic stent placement with or without sphincterotomy in two high-volume centers. Among the factors associated with the resolution of the bile leak after LT, multivariate analysis identified ERCP with stent placement as the only factor predictive of bile leak resolution (odds ratio, 8.36; 95% confidence interval, 1.79–39.03; $p=0.007$). Simmons et al. investigated whether sphincterotomy should routinely be performed along with stent placement when managing bile leaks.³⁶ In this study, the investigators identified a higher rate of post-ERCP pancreatitis after placement of large-bore biliary stents when sphincterotomy was not performed suggesting that sphincterotomy might be protective of post-ERCP pancreatitis when 10Fr stents are placed, and that otherwise sphincterotomy alone did not confer additional benefit for the treatment of bile leak.³⁶ Our findings confirm the results of a recent multicenter study of patients with post-cholecystectomy bile leaks.³⁷ In this study, 162 out of 178 patients (91%) had complete resolution of their bile leak after therapy with biliary sphincterotomy and biliary plastic stent placement. Although there are centers that perform sphincterotomy alone for bile leaks, a recent study in patients with bile leaks after liver resection showed that endoscopic sphincterotomy without stent insertion ($p=0.002$) was significantly associated with failure of endoscopic therapy.²⁰

Though controversial, some authors recommend different endoscopic techniques based on the size of the bile leak, suggesting that small leaks may be managed with sphincterotomy alone.^{14,24} In contrast, our findings suggest that placement of a biliary stent with or without sphincterotomy for the treatment of bile leaks results in a high rate of resolution compared to sphincterotomy alone regardless of the bile leak location. Aside from these two approaches (sphincterotomy alone and sphincterotomy with plastic stent placement), some authors also advocate the use of FCSEMS for patients with bile leaks (mainly post-cholecystectomy leaks) given the high resolution rates (93%–95%) in early studies.^{26,27,38,39} In our clinical experience FCSEMS are useful in some LT recipients with large or refractory bile leaks, though FCSEMS were not placed during the present study. While FCSEMS may

be effective for bile leaks, some stents carry a risk of new stricture formation in LT recipients, thus more information is needed in these patients.²⁵

A number of studies indicate that the location of the bile leak is a key factor predicting ERCP-directed treatment success. Pfau et al.⁴ described a significantly lower success rate of endoscopic treatment of anastomotic leaks (42.9%) compared with T-tube-related leaks (95.2%). In a recent study by Tewani et al.²¹ that included a variety of post-surgical bile leaks (i.e. post-cholecystectomy, hepatobiliary surgery, LT), post-cholecystectomy bile leak was identified as a predictive factor for ERCP therapy success compared with leaks after hepatobiliary surgery. Interestingly, in a subgroup analysis 90% of post-LT bile leaks were successfully treated after a single ERCP with stent placement.²¹ Finally, one group proposed classifying post-cholecystectomy leaks into low-grade and high-grade. Leaks visualized at the intrahepatic biliary branches were considered low grade, while those seen below the intrahepatics were considered high grade. Low-grade leaks managed with sphincterotomy alone had a high success and high-grade leaks managed with stents and sphincterotomy also had very high success.²⁴ Our study focuses only on LT recipients and we found that the majority of bile leaks occurred at the anastomotic site (45%) and peri-T-tube site (34%); however, leak site was not a predictor of endoscopic success.

There are inherent limitations in our study. Although this analysis was carried out at two high-volume centers, it is a retrospective analysis including a relatively low number of patients. The study is a descriptive analysis of the ERCP practices at two centers and not a true comparative study of two endoscopic approaches. Also, we were unable to record the bile duct mismatch and size of the bile leaks. Finally, the management strategy for patients in which the first ERCP failed to resolve the bile leak was at the discretion of each proceduralist.

In summary, our study indicates that ERCP with biliary plastic stent placement with or without sphincterotomy is a highly effective therapy for bile leaks after LT and should be considered the standard of care in this clinical situation.

Acknowledgments

Author contributions are as follows: O Sendino: acquired, analyzed and interpreted the results, performed the statistical analysis and drafted and revised the manuscript.

A Fernández-Simon: acquired, analyzed and interpreted the results, performed the statistical analysis and drafted and revised the manuscript.

R Law: acquired, analyzed and interpreted the results, performed the statistical analysis and drafted and revised the manuscript.

B Abu Dayyeh: acquired, analyzed and interpreted the results; performed the statistical analysis and drafted and revised the manuscript.

M Leise: acquired, analyzed and interpreted the results; performed the statistical analysis and drafted and revised the manuscript.

K Chavez-Rivera: acquired, analyzed and interpreted the results and revised the manuscript.

H Cordova: interpreted the results and revised the manuscript.

J Colmenero: interpreted the results and revised the manuscript.

G Crespo: interpreted the results and revised the manuscript.

C Rodriguez de Miguel: acquired, analyzed and interpreted the results.

C Fondevila: interpreted the results and revised the manuscript.

J Llach: interpreted the results and revised the manuscript.

M Navasa: interpreted the results and revised the manuscript.

TH Baron: acquired, analyzed and interpreted the results; conceived the study and participated in its design; drafted and revised the manuscript.

A Cárdenas: acquired, analyzed and interpreted the results; conceived the study and participated in its design; performed the statistical analysis and drafted and revised the manuscript. All authors read and approved the final manuscript.

Declaration of conflicting interests

None declared.

Funding

Part of the research reported in this article was funded by the Institut d'Investigacions Biomèdiques August Pi-Sunyer (IDIBAPS) and Ciber de Enfermedades Hepáticas y Digestivas (CIBERHED), Barcelona, Spain.

Ethics approval

This study was approved by the Ethical and Institutional Review Board at the Hospital Clinic of Barcelona (Barcelona, Spain) and Mayo Clinic (Rochester, MN, USA).

Informed consent

Informed consent was obtained from all patients included in the study.

References

1. Londoño MC, Balderramo D and Cárdenas A. Management of biliary complications after orthotopic liver transplantation: The role of endoscopy. *World J Gastroenterol* 2008; 14: 493–497.
2. Karimian N, Westerkamp AC and Porte RJ. Biliary complications after orthotopic liver transplantation. *Curr Opin Organ Transplant* 2014; 19: 209–216.
3. Rerknimitr R, Sherman S, Fogel EL, et al. Biliary tract complications after orthotopic liver transplantation with choledochocholedochostomy anastomosis: Endoscopic findings and results of therapy. *Gastrointest Endosc* 2002; 55: 224–231.
4. Pfau PR, Kochman ML, Lewis JD, et al. Endoscopic management of postoperative biliary complications in orthotopic liver transplantation. *Gastrointest Endosc* 2000; 52: 55–63.
5. Welling TH, Heidt DG, Englesbe MJ, et al. Biliary complications following liver transplantation in the model for end-stage liver disease era: Effect of donor, recipient, and technical factors. *Liver Transpl* 2008; 14: 73–80.
6. Thuluvath PJ, Pfau PR, Kimmey MB, et al. Biliary complications after liver transplantation: The role of endoscopy. *Endoscopy* 2005; 37: 857–863.
7. Thuluvath PJ, Atassi T and Lee J. An endoscopic approach to biliary complications following orthotopic liver transplantation. *Liver Int* 2003; 23: 156–162.
8. Seehofer D, Eurich D, Veltzke-Schlieker W, et al. Biliary complications after liver transplantation: Old problems and new challenges. *Am J Transplant* 2013; 13: 253–265.
9. Shuhart MC, Kowdley KV, McVicar JP, et al. Predictors of bile leaks after T-tube removal in orthotopic liver transplant recipients. *Liver Transpl Surg* 1998; 4: 62–70.
10. Bjorkman DJ, Carr-Locke DL, Lichtenstein DR, et al. Postsurgical bile leaks: Endoscopic obliteration of the transpapillary pressure gradient is enough. *Am J Gastroenterol* 1995; 90: 2128–2133.
11. Liao JZ, Zhao Q, Qin H, et al. Endoscopic diagnosis and treatment of biliary leak in patients following liver transplantation: A prospective clinical study. *Hepatobiliary Pancreat Dis Int* 2007; 6: 29–33.
12. Ostroff JW, Roberts JP, Gordon RL, et al. The management of T tube leaks in orthotopic liver transplant recipients with endoscopically placed nasobiliary catheters. *Transplantation* 1990; 49: 922–924.
13. Sherman S, Jamidar P, Shaked A, et al. Biliary tract complications after orthotopic liver transplantation. Endoscopic approach to diagnosis and therapy. *Transplantation* 1995; 60: 467–470.
14. Llach J, Bordas JM, Elizalde JI, et al. Sphincterotomy in the treatment of biliary leakage. *Hepatogastroenterology* 2002; 49: 1496–1498.
15. Ward EM, Wiesner RH, Hughes RW, et al. Persistent bile leak after liver transplantation: Biloma drainage and endoscopic retrograde cholangiopancreatographic sphincterotomy. *Radiology* 1991; 179: 719–720.
16. Davids PH, Rauws EA, Tytgat GN, et al. Postoperative bile leakage: Endoscopic management. *Gut* 1992; 33: 1118–1122.
17. Saraswat VA, Choudhuri G, Sharma BC, et al. Endoscopic management of postoperative bile leak. *J Gastroenterol Hepatol* 1996; 11: 148–151.
18. Oh DW, Lee SK, Song TJ, et al. Endoscopic management of bile leakage after liver transplantation. *Gut Liver* 2015; 9: 417–423.
19. Solmi L, Cariani G, Leo P, et al. Results of endoscopic retrograde cholangiopancreatography in the treatment of biliary tract complications after orthotopic liver transplantation: Our experience. *Hepatogastroenterology* 2007; 54: 1004–1008.

20. Dechêne A, Jochum C, Fingas C, et al. Endoscopic management is the treatment of choice for bile leaks after liver resection. *Gastrointest Endosc* 2014; 80: 626–633.e1.
21. Tewani SK, Turner BG, Chuttani R, et al. Location of bile leak predicts the success of ERCP performed for postoperative bile leaks. *Gastrointest Endosc* 2013; 77: 601–608.
22. Morelli J, Mulcahy HE, Willner IR, et al. Endoscopic treatment of post-liver transplantation biliary leaks with stent placement across the leak site. *Gastrointest Endosc* 2001; 54: 471–475.
23. Wadhawan M, Kumar A, Gupta S, et al. Post-transplant biliary complications: An analysis from a predominantly living donor liver transplant center. *J Gastroenterol Hepatol* 2013; 28: 1056–1060.
24. Sandha GS, Bourke MJ, Haber GB, et al. Endoscopic therapy for bile leak based on a new classification: Results in 207 patients. *Gastrointest Endosc* 2004; 60: 567–574.
25. Phillips MS, Bonatti H, Sauer BG, et al. Elevated stricture rate following the use of fully covered self-expandable metal biliary stents for biliary leaks following liver transplantation. *Endoscopy* 2011; 43: 512–517.
26. Traina M, Tarantino I, Barresi L, et al. Efficacy and safety of fully covered self-expandable metallic stents in biliary complications after liver transplantation: A preliminary study. *Liver Transpl* 2009; 15: 1493–1498.
27. Wang AY, Ellen K, Berg CL, et al. Fully covered self-expandable metallic stents in the management of complex biliary leaks: Preliminary data—a case series. *Endoscopy* 2009; 41: 781–786.
28. Cotton PB, Lehman G, Vennes J, et al. Endoscopic sphincterotomy complications and their management: An attempt at consensus. *Gastrointest Endosc* 1991; 37: 383–393.
29. Cotton PB, Eisen GM, Aabakken L, et al. A lexicon for endoscopic adverse events: Report of an ASGE workshop. *Gastrointest Endosc* 2010; 71: 446–454.
30. Verdonk RC, Buis CI, Porte RJ, et al. Anastomotic biliary strictures after liver transplantation: Causes and consequences. *Liver Transpl* 2006; 12: 726–735.
31. Balderramo D, Sendino O, Burrel M, et al. Risk factors and outcomes of failed endoscopic retrograde cholangiopancreatography in liver transplant recipients with anastomotic biliary strictures: A case-control study. *Liver Transpl* 2012; 18: 482–489.
32. Sharma S, Gurakar A and Jabbour N. Biliary strictures following liver transplantation: Past, present and preventive strategies. *Liver Transpl* 2008; 14: 759–769.
33. López-Andújar R, Orón EM, Carregnato AF, et al. T-tube or no T-tube in cadaveric orthotopic liver transplantation: The eternal dilemma: Results of a prospective and randomized clinical trial. *Ann Surg* 2013; 258: 21–29.
34. Binmoeller KF, Katon RM and Shneidman R. Endoscopic management of postoperative biliary leaks: Review of 77 cases and report of two cases with biloma formation. *Am J Gastroenterol* 1991; 86: 227–231.
35. Foutch PG, Harlan JR and Hoefler M. Endoscopic therapy for patients with a post-operative biliary leak. *Gastrointest Endosc* 1993; 39: 416–421.
36. Simmons DT, Petersen BT, Gostout CJ, et al. Risk of pancreatitis following endoscopically placed large-bore plastic biliary stents with and without biliary sphincterotomy for management of postoperative bile leaks. *Surg Endosc* 2008; 22: 1459–1463.
37. Canena J, Horta D, Coimbra J, et al. Outcomes of endoscopic management of primary and refractory postcholecystectomy biliary leaks in a multicentre review of 178 patients. *BMC Gastroenterol* 2015; 15: 105.
38. Mangiavillano B, Manes G, Baron TH, et al. The use of double lasso, fully covered self-expandable metal stents with new ‘anchoring flap’ system in the treatment of benign biliary diseases. *Dig Dis Sci* 2014; 59: 2308–2313.
39. Irani S, Baron TH, Law R, et al. Endoscopic treatment of nonstricture-related benign biliary diseases using covered self-expandable metal stents. *Endoscopy* 2015; 47: 315–321.