

## SPECIAL ARTICLE

# Perioperative Management of Adult Patients With External Ventricular and Lumbar Drains: Guidelines From the Society for Neuroscience in Anesthesiology and Critical Care

*Abhijit V. Lele, MBBS, MD, MS,\* Amie L. Hoefnagel, MD,†*

*Nina Schloemerkemper, MD, Dr. med., FRCA,‡ David A. Wyler, MD,§*

*Nophanan Chaikittisilpa, MD,|| Monica S. Vavilala, MD,¶ Bhiken I. Naik, MBBCh,#*

*James H. Williams, MD, PhD,\*\**

*Lakshmikumar Venkat Raghavan, MBBS, MD, FRCA, FRCPC,†† and*

*Ines P. Koerner, MD, PhD,‡‡ Representing SNACC Task Force for Developing Guidelines for Perioperative Management of External Ventricular and Lumbar Drains*

**Abstract:** External ventricular drains and lumbar drains are commonly used to divert cerebrospinal fluid and to measure cerebrospinal fluid pressure. Although commonly encountered in the perioperative setting and critical for the care of neurosurgical patients, there are no guidelines regarding their management in the perioperative period. To address this gap in the literature, The Society for Neuroscience in Anesthesiology & Critical Care tasked an expert group to generate evidence-based guidelines. The document generated targets clinicians involved in perioperative care of patients with indwelling external ventricular and lumbar drains.

**Key Words:** external ventricular drain, ventriculostomy, lumbar drain, guidelines, perioperative, management, leveling, transport, checklist, competency

(*J Neurosurg Anesthesiol* 2017;00:000–000)

External ventricular drains (EVDs) and lumbar drains (LDs) are temporary devices placed into the lateral ventricles of the brain and lumbar subarachnoid space, respectively, to facilitate external cerebrospinal fluid (CSF) drainage and to monitor CSF pressure. Their

Received for publication December 22, 2016; accepted December 27, 2016.

From the Departments of \*Anesthesiology & Pain Medicine, Neurocritical Care Service; ||Anesthesiology and Pain Medicine; ¶Anesthesiology and Pediatrics, Harborview Injury Prevention and Research Center (HIPRC), Harborview Medical Center, University of Washington, Seattle, WA; †Department of Anesthesiology, University of Florida, UF Health, Jacksonville, FL; ‡Department of Anesthesiology & Pain Medicine, University of California Davis Medical Center, Sacramento, CA; §Jefferson Hospital of Neuroscience, Sidney Kimmel Medical College, Thomas Jefferson University, Philadelphia, PA; #Department of Anesthesiology & Neurosurgery, University of Virginia Health System, Charlottesville, VA; \*\*Department of Anesthesiology, University of North Carolina at Chapel Hill, N2201 UNC Hospitals, Chapel Hill, NC; ††Department of Anesthesia and Pain Medicine, Toronto Western Hospital, Toronto, ON, Canada; and ‡‡Department of Anesthesiology & Perioperative Medicine, Neurosciences ICU, Oregon Health Sciences University, Portland, OR.

A.V.L.: manuscript design, manuscript write-up, Tables 1 to 6, Figures 1A, 1B, 2A, 2B, Sections 1 to 6, developing clinical competencies for EVD/LD among clinicians involved in perioperative care, continued medical education and following a perioperative checklist for management of EVD/LD, review and approve final manuscript. A.L.H. and N.S.: manuscript write-up, Section 1: Introduction, indications and contraindications, review and final approve manuscript. D.A.W.: manuscript write-up, Section 2: Preoperative assessment of patients with EVD or LD, review and approve final manuscript. N.C. and M.S.V.: manuscript write-up, Section 3: Transporting patients with EVD or LD, review and approve final manuscript. B.I.N. and J.H.W.: manuscript write-up, Section 4: Intraoperative management of external ventricular and lumbar drains, review and approve final manuscript. L.V.R. and I.P.K.: manuscript write-up, Section 5: Management of external ventricular drains (EVD)/lumbar drains (LD) in special clinical scenarios, review and approve final manuscript.

A.L.H. has received honoraria from Design Science Consulting Inc.; N.S. has received consulting fee from Mizuho OSI. The other authors have no conflicts of interest to disclose.

Address correspondence to: Abhijit V. Lele, MBBS, MD, MS, Department of Anesthesiology & Pain Medicine, Neurocritical Care Service, Harborview Medical Center, University of Washington, 325, 9th Avenue, Seattle, WA 98104 (e-mail: abhijit2@uw.edu).

Supplemental Digital Content is available for this article. Direct URL citations appear in the printed text and are provided in the HTML and PDF versions of this article on the journal's Website, [www.jnsa.com](http://www.jnsa.com).

Copyright © 2017 Wolters Kluwer Health, Inc. All rights reserved.

DOI: 10.1097/ANA.0000000000000407

placement is considered one of the most frequently performed procedures in neurologically critically ill patients,<sup>1-3</sup> with the majority placed in patients with subarachnoid hemorrhage (SAH), intracerebral hemorrhage, and obstructive hydrocephalus.<sup>4</sup> Although the worldwide incidence of placement of EVD and LD is largely unknown, it is estimated that 500,000 ventriculostomies were placed in the United States alone between 1988 and 2010.<sup>4</sup> Since its first placement in 1744, EVDs have undergone numerous changes in materials, techniques, and indications.<sup>5-7</sup>

EVDs are commonly encountered in perioperative care by clinicians, specifically the anesthesia providers who might have limited experience in their management. Furthermore, mismanagement of EVDs can have catastrophic consequences. Despite their importance, there are currently no guidelines for the perioperative management of EVD and LD.

## METHODOLOGY

### Purpose of the Guidelines

These evidence-based guidelines aim to provide recommendations related to EVD and LD regarding (1) common indications, contraindications, complications, and patient preparation for placement and maintenance; (2) preoperative assessment of patients; (3) transporting patients; (4) intraoperative management including monitoring and CSF drainage; (5) management of these drains under special circumstances; and (6) creating a perioperative checklist, clinical competency, and continued medical education.

### Application

These guidelines are intended for the use by clinicians involved in perioperative care of adult patients with EVDs and LDs.

### Task Force Members

The initial concept and design of “Society for Neuroscience in Anesthesiology & Critical Care (SNACC) EVD/LD project” began in November 2015, and an EVD/LD task force was finalized in December 2015. This task force comprised of 10 neuroanesthesiologists and neurointensivists practicing at academic medical centers across the United States and Canada. These 10 individuals were chosen after an e-mail invitation was sent to all active SNACC members seeking project membership. Applicants were required to have published peer-reviewed neuroscience research or have documented experience in the care of patients with EVD and LD. The task force members agreed on criteria for evidence and then evaluated peer-reviewed studies pertaining to EVD and LD (search strategies described in next section). The document was compiled of 6 sections, with each section equally coauthored by 2 project members, and was subsequently reviewed and approved by all members of the task force. The completed draft was submitted to the SNACC Board of Directors. After

incorporating the inputs and suggestions from the SNACC Board of Directors, the approved version was placed on the SNACC Web site (<http://www.snacc.org>) for member review and comments for a period of 1 month, with the final version of the guideline confirmed after incorporating member input.

## AVAILABILITY AND STRENGTH OF EVIDENCE

The task force worked with a medical librarian to create a systematic strategy to search PubMed: (external ventricular drain\*[tw] OR external ventricle drain\*[tw] OR extraventricular drain\*[tw] OR extra ventricular drain\*[tw] OR ventricular catheter\*[tw] OR ventricular access device\*[tw] OR lumbar drain\*[tw] OR cerebrospinal fluid drain\*[tw] OR csf drain\*[tw]) OR (ventriculostom\*[tw] AND (drain\*[tw] OR catheter\*[tw])). The format of this search was adapted for Embase through Elsevier. Search results were limited to journal articles and conference papers published in English and last updated on December 26, 2016. The total search results (7936 references) were downloaded to Endnote. After 2729 duplicates were removed, 5207 articles were imported to a Covidence database for team review. Authors had previously identified 119 additional articles, and 91 articles were found by the authors including checks of reference lists as the review progressed.

Several rounds of screening were conducted, with review of each of the titles and abstracts from the original search by 2 reviewers. Inclusion criteria were all study types in adults, and exclusion criteria were nonhuman studies, laboratory investigations, and pediatric literature. References addressing infectious complications and prevention strategies published before the 2015 Neurocritical Care Society (NCS) guidelines<sup>8</sup> and those addressing CSF drainage for spinal cord protection published before the 2010 ACC guidelines<sup>9</sup> were eliminated. Ultimately a pool of 646 references were identified and organized by topic for the individual section authors to draw upon in construction of the guidelines.

We used the American Heart Association methodology for the level of evidence for each recommendations proposed<sup>10</sup> (Table 1).

## SECTION 1: INTRODUCTION TO EVDs AND LDs

### Common Indications for Placement of EVDs and LDs

EVDs function as intracranial pressure (ICP) monitors and as conduits for external CSF diversion. LDs, in contrast, function primarily as a conduit for external CSF drainage, and are not used for ICP monitoring. Although both parenchymal ICP monitors and EVDs provide reliable and accurate ICP data, EVDs are preferred in patients with hydrocephalus.<sup>11</sup>

Major indications for placement of EVD and LD are presented in Table 2.

**TABLE 1.** Summary of Class (Strength) of Recommendation and Level (Quality) of Evidence

Class (strength) of recommendation	
Class I (strong) benefit > > risk	
Class IIa (moderate) benefit > > risk	
Class IIb (weak) benefit ≥ risk	
Class III: no benefit (benefit = risk)	
Class III: harm (strong) risk > benefit	
Level (quality of evidence)	
Level A	High-quality evidence from > 1 RCTs Meta-analyses of high-quality RCTs ≥ 1 RCTs corroborated by high-quality registry studies
Level B: randomized	Moderate-quality evidence from ≥ 1 RCTs  Meta-analyses of moderate-quality RCTs
Level B: nonrandomized	Moderate-quality evidence from ≥ 1 well-designed, well-executed nonrandomized studies, observational studies, or registry studies Meta-analyses of such studies
Level C	Randomized or nonrandomized observational or registry Studies with limitations of design or execution Meta-analyses of such studies Physiological or mechanistic studies in human subjects
Level E	Consensus of expert opinion based on clinical experience when evidence is insufficient, vague, or conflicting

RCT indicates randomized controlled trial.

**Placement of EVDs and LDs**

EVDs are frequently inserted emergently at bedside rather than in the operating room (OR).<sup>47,48</sup> The frontal horn of the right lateral ventricle is the preferred destination as this is assumed to be in the nondominant side for speech and language in most patients.<sup>47,49</sup> Although different techniques for EVD placement have been described in the literature,<sup>3,50-52</sup> anatomic landmarks are frequently used and the drain is placed free handed.<sup>49,51,53-57</sup>

LDs are placed in a manner similar to a lumbar puncture, epidural, or intrathecal catheter placement.<sup>58</sup> Placement of an LD may be done preoperatively in an awake patient, or after the induction of anesthesia. Coagulation profile and anticoagulation medications should be reviewed and anticoagulants held per current American Society of Regional Anesthesia and Pain Medicine (ASRA) guidelines (refer to Supplement 1, Supplemental Digital Content 1, <http://links.lww.com/JNA/A46>). The patient is placed in the lateral decubitus or sitting position. Using strict aseptic technique, the lumbar catheter is typically inserted at the L3-L4 or L4-L5 level through a 14-G Tuohy needle. A special, kink-resistant, flexible catheter is passed through the Tuohy needle into the intrathecal space.<sup>58</sup> The catheter with the guidewire is threaded approximately 5 to 8 cm past the needle into the intrathecal space and secured with a clear dressing. It should be stressed that the catheter should thread easily, like an epidural catheter. If resistance is felt, or the catheter is unable to be placed, both the needle and catheter should be removed as a single unit to prevent

**TABLE 2.** Major Indications for Placement of External Ventricular and Lumbar Drains

External ventricular drains
Acute symptomatic hydrocephalus
Aneurysmal SAH <sup>12-14</sup>
ICH and IVH with decreased level of consciousness <sup>15</sup>
Acute ischemic cerebellar stroke in concurrence with decompressive craniectomy <sup>16,17</sup>
ICP monitoring in TBI
TBI with postresuscitation GCS of 3-8, and abnormal CT scan defined as one with hematomas, contusions, swelling, herniation, or compressed basal cisterns <sup>18-20</sup>
Severe TBI with a normal CT scan if ≥ 2 of the following features are noted on admission (age over 40 y, unilateral or bilateral motor posturing, or SBP < 90 mm Hg <sup>18,19</sup> )
Management of patients with intracranial hypertension after TBI <sup>21,22</sup>
Malfunctioning or infected ventriculoperitoneal shunts, and other neurological emergencies occurring due to infective and neoplastic diseases <sup>23-26</sup>
Facilitation of intraoperative brain relaxation <sup>27,28</sup>
Targeted therapeutic interventions
rTPA in patients with IVH <sup>29,30</sup> (efficacy and safety uncertain) and in patients with SAH <sup>31,32</sup>
Treatment of vasospasm after aneurysmal SAH <sup>33-35</sup>
Antibiotics in management of central nervous system infections <sup>36,37</sup>
Lumbar drains
Acute symptomatic hydrocephalus in SAH <sup>12</sup>
Spinal cord-protective strategy in open and endovascular thoracic aortic repair for patients at high risk of spinal cord injury <sup>9,24,38-40</sup>
Active CSF leak (due to craniofacial trauma) <sup>41</sup> or those at risk for CSF leak during skull base procedures <sup>42-44</sup> ; however, lumbar drains do not prevent postoperative CSF leaks <sup>44,45</sup>
Facilitate intraoperative brain relaxation <sup>27</sup> and intraoperative exposure <sup>46</sup>

CSF indicates cerebrospinal fluid; CT, computed tomography; GCS, Glasgow Coma Score; ICH, intracerebral hemorrhage; IVH, intraventricular hemorrhage; rTPA, recombinant tissue plasminogen activator; SAH, subarachnoid hemorrhage; SBP, systolic blood pressure; TBI, traumatic brain injury.

inadvertent shearing of the catheter. The catheter should be flushed with 10 mL sterile saline flush and connected to a sterile pressure monitoring kit and a closed collection system. The transducer should not be connected to any pressured flushing system. When connecting the transducer to a collection system ensure a continuous fluid column. This can be achieved by allowing CSF to drain back to the stopcock at the transducer. Bloody CSF or aspiration of blood during placement requires avoidance of anticoagulation for 24 hours.

**Optimizing Patients Before Placement of EVDs or LDs**

Contraindications to placement of EVD or LD include coagulopathy and infection at the entry site. LD also needs careful screening to rule out non-communicating hydrocephalus and large intracranial mass lesions.<sup>24</sup> The ASRA guidelines on anticoagulation should be consulted to determine appropriateness of placement and removal of the LD.<sup>59</sup> It is generally advised to diagnose and promptly correct coagulopathies before placement of either monitor.<sup>8,60</sup>

**TABLE 3. Complications Associated With EVD and LD**

Hemorrhage	
Intracerebral hemorrhage, tract hematoma, or tract hemorrhages (0%-41%) <sup>1,8,63-66</sup>	
Neuraxial hematoma (0%-3.2%) <sup>67</sup>	
Neural injury <sup>68</sup>	
Infection (0%-28% EVD, 0%-50% LD) <sup>8,69-75</sup>	
Malposition <sup>2,76</sup>	
Occlusion and malfunction <sup>77-79</sup>	
Overdrainage of CSF	
Subdural or epidural hematoma <sup>80-83</sup>	
Rebleeding from a ruptured cerebral aneurysm <sup>84</sup>	
Intracranial hypotension <sup>85-87</sup>	
Cerebellar tonsillar herniation <sup>79,88-91</sup>	
Paradoxical herniation <sup>92</sup>	
Pneumocephalus <sup>79,93</sup>	
Iatrogenic vascular injury (arteriovenous fistula, cerebral pseudoaneurysm) <sup>94</sup>	
Fracture of catheters, <sup>95</sup> with retained fragment of catheter <sup>96,97</sup>	
Inadvertent injections of drugs into EVDs <sup>98-105</sup>	
Postdural puncture headache <sup>106</sup>	
CSF indicates cerebrospinal fluid; EVD, external ventricular drain; LD, lumbar drain.	

### Complications Associated With EVDs and LDs

Complications associated with EVD placement are common<sup>61</sup> requiring revision in 10% to 22% of cases.<sup>47,62</sup> Table 3 highlights complications associated with EVDs and LDs. Although hemorrhage, infections, and overdrainage of CSF are the most recognized complications, clinicians involved in perioperative care must be familiar with other possible complications.

### Hemorrhagic Complications Associated With EVD and LD

There are 2 main risk factors for hemorrhagic complications: (1) coagulopathy and (2) overdrainage of CSF. Factors such as cerebrovascular disease, size of catheter,<sup>107</sup> use of antiplatelet agents,<sup>108</sup> and INR > 1.6,<sup>109</sup> place patients at risk for ventriculostomy-associated hemorrhage. Although most of these bleeds are clinically insignificant,<sup>2,110,111</sup> they can be potentially devastating.<sup>8,66</sup> Removal of EVD also poses risk for hemorrhage. In a retrospective study of 482 EVDs by Miller and Tummala,<sup>66</sup> hemorrhage was seen in 22.5% of those patients who underwent post-EVD neuroimaging. Factors associated with hemorrhage included bedside placement of EVD. Interestingly, the investigators were unable to demonstrate impact of INR value, platelet count, and antiplatelet agents on incidence of hemorrhage. Proposed mechanisms of hemorrhage associated with removal of EVD include: injury to and release of any tamponade effect on a small vessel, tracking of scalp bleeding along EVD track, and possible adherence of EVD to choroid plexus that may contribute to bleeding on removal. Majority of the hemorrhages in this series were small and asymptomatic.<sup>66</sup>

*Hemorrhagic Complications Associated With Chemical Prophylaxis Against Venous Thromboembolism.*

Contrary to popular concern, chemical prophylaxis against venous thromboembolism started within 24 hours of admission and therapeutic heparinization initiated within 24 hours of placement of the EVD does not increase bleeding risk.<sup>112,113</sup> The incidence of hemorrhage during removal of EVD can be higher than during placement,<sup>66</sup> and similar indices of coagulopathy must be maintained before removal of EVD.

*Placement of LD in Patients Requiring Systemic Anticoagulation.* Placing a LD in an anesthetized patient is safe, even in patients requiring subsequent heparinization and cardiopulmonary bypass.<sup>74,114</sup> The risk of hematoma and neurological injury is rare, and can be minimized by following certain guidelines, that is, delaying surgery 24 hours in the event of a traumatic tap (blood freely aspirated), delaying heparinization for > 60 minutes after catheter insertion, and maintaining tight perioperative control of anticoagulation.<sup>115</sup> Neuraxial hematoma associated with placement or removal of a LD is a rare but potentially serious complication. The reported incidence of surgical decompression required after epidural catheterization varied between 1/22,189 and 1/4330 in a cohort of 62,450 nonaortic surgery patients.<sup>116</sup> Of note, 4 of the 7 patients who developed a neuraxial hematoma had perioperative anticoagulation management deviated from current ASRA guidelines.<sup>116,117</sup>

There are limited data on the incidence of neuraxial hematoma associated with LDs during aortic surgery requiring systemic anticoagulation, but has been reported as between 0% and 4%.<sup>67,72,73</sup>

A summary of the ASRA guidelines pertinent to LDs<sup>117</sup> and NCS consensus statement<sup>8</sup> on management of EVD can be found in the supplement document attached to the guidelines (refer to Supplement 1, Supplemental Digital Content 1, <http://links.lww.com/JNA/A46>).

### Infectious Complications

Infections associated with EVD (0% to 28%) and LD (0% to 50%) are among the most serious of complications.<sup>8,69-75</sup> Factors associated with increased infection risk include nontunneled catheters, nonsterile conditions, intraventricular hemorrhage, frequent sampling, irrigation of catheters, and longer in situ duration.<sup>70,118</sup> Adherence to an aseptic technique, that is, cleaning the insertion site using an antimicrobial agent per local antibiogram, and using a dressing as a part of a management bundle, institution of pre-EVD-insertion antibiotics, using antimicrobial-impregnated catheters whenever possible,<sup>8,62,119-125</sup> avoiding routine CSF sampling, and limited manipulation of the CSF collecting system, all feature in the recommendations provided in the recently published NCS consensus statement on EVD insertion and management.<sup>8</sup> To limit potential for *Clostridium difficile* diarrhea and antimicrobial-resistant organisms, as well as lack of efficacy, antibiotics are not routinely recommended for the duration of the EVD.<sup>8</sup>

Although there are no guidelines or consensus statements regarding intraoperative periprocedural

administration of antibiotics before LD placement for aortic and nonaortic surgery, this task force recommends following standards such as those used for EVD insertion and management.

**Summary**

Although there are many indications for the placement of EVD or LD, they are critical to monitor intracerebral or intraspinal pressure (ISP). Thorough knowledge of indications, contraindications, complications, and cautions associated with the monitoring modality, along with strict adherence to local, national, and international standards will likely enhance patient safety.

Prevention of Hemorrhagic and Infectious Complications Associated with EVDs and LDs (Class of Recommendation and Level of Evidence):

- (1) Before insertion of EVD and LD, prompt diagnosis and correction of coagulopathy utilizing institutional practice guidelines is recommended (Class I Recommendation; Level of Evidence E).
- (2) Perioperative anticoagulation management with LD placement and removal during aortic or nonaortic surgery should be performed within the framework of the current ASRA guidelines (Class I Recommendation; Level of Evidence E).
- (3) Antibiotics should only be administered before placement of an EVD and LD with the choice based on institutional practice (Class I Recommendation; Level of Evidence E).
- (4) It is recommended to practice strict aseptic technique based on national and institutional guidelines (Class I Recommendation; Level of Evidence E).

**SECTION 2: PREOPERATIVE EVALUATION OF PATIENT WITH EVD AND LD**

**Background**

A thorough preanesthetic evaluation of patients with EVD and LD is critical for optimal perioperative care. Table 4 describes components of history, physical examination, laboratory, and imaging data that should be incorporated into the preanesthetic assessment.

Parts of evaluation that are unique to EVDs include reviewing indication for placement, relevant history, medications given, ICP trends, qualitative evaluation of components of ICP waveforms, and any data available from EVD clamp trials. P1:P2 waveform evaluation would be significant to understand ICP compliance curve, and EVD clamp trial data would be significant to understand impact of EVD clamping on ICP during patient transport.

**Inspection of the EVD or LD System**

Inspection of EVD and LD system must be performed to provide information regarding (1) integrity of the system, (2) color and consistency of CSF, and (3) leveling and zeroing of the transducer system.

Baseline color and consistency of CSF, as well as presence of air bubbles or debris should be noted in the

**TABLE 4. Preoperative Assessment of Patients With External Ventricular and Lumbar Drain**

History	Comments
Diagnosis	SAH, ICH, IVH, AIS, TBI, skull base surgery, CSF leak
Medications	Anticoagulant drugs, antiplatelet drugs
Liver or renal disease	Associated with coagulopathy
Cancer or hematological disorders	Associated with coagulopathy
Physical examination	
Vital signs	SpO <sub>2</sub> , PO <sub>2</sub> , EtCO <sub>2</sub> , PCO <sub>2</sub> , MAP, CPP
ICP data	ICP range, ICP waveform, P1:P2 ratio EVD clamp trial results
CSF data	Hourly CSF output, output over 24h Color of CSF (clear, xanthochromia, bloody, etc.)
Multimodal monitoring data	PbtO <sub>2</sub> , microdialysis, and autoregulation studies
Focused neurological examination	GCS, FOUR score, cranial nerve paresis, brainstem reflexes, presence or absence of focal neurodeficits
Inspection of EVD or LD system	Tunneled catheter system Setting of EVD with reference to zero Leveling of EVD at EAM Leveling of LD at phlebostatic axis/EAM
Laboratory data	
Complete blood count	Correct thrombocytopenia
PT, INR, PTT	Prompt reversal of coagulopathy
Imaging data	
CT or MRI findings	Site and location of EVD Midline shift, cerebral edema

AIS indicates acute ischemic stroke; CPP, cerebral perfusion pressure; CSF, cerebrospinal fluid; CT, computed tomography; EAM, external auditory meatus; EtCO<sub>2</sub>, end-tidal carbon dioxide; FOUR, Full Outline of Responsiveness Score; GCS, Glasgow Coma Score; ICH, intracerebral hemorrhage; ICP, intracranial pressure; INR, international normalized ratio; IVH, intraventricular hemorrhage; MAP, mean arterial pressure; MRI, magnetic resonance imaging; PbtO<sub>2</sub>, brain tissue oxygenation; PCO<sub>2</sub>, partial pressure of carbon dioxide; PO<sub>2</sub>, partial pressure of oxygen; PT, prothrombin time; PTT, partial thromboplastin time; SAH, subarachnoid hemorrhage; SpO<sub>2</sub>, pulse oximetry; TBI, traumatic brain injury.

catheter and the burette (rather than the collecting bag), and sudden change in color of CSF at any given time deserves attention (see Section 5 for further details).

EVDs are leveled at the external auditory meatus using either a Carpenter bubble or a laser level. LDs, in contrast, are leveled at the right atrium (phlebostatic axis) or at the lumbar catheter insertion site.

**Understanding “Drain Dynamics” or “Setting of EVD and LD”**

CSF drainage through EVD and LD is performed under controlled conditions to prevent overdrainage. Establishing CSF drain volume goals is an important part of this with a goal of 10 to 20 mL/h as this is the typical hourly CSF production and volume that resides in the ventricular system.<sup>126</sup> To avoid overdrainage, bridging vein tear, and ultimately subdural bleed, drainage of EVD/LD > 15 to 20 mL in any hour should accompany consultation of a neurosurgeon. The bedside notes should clearly indicate whether the goals are hourly drainage of

certain predetermined CSF volume or whether ICP data can drive the drainage volume.

Setting of EVD depends upon indication for placing catheters. In patients with aneurysmal SAH, EVDs are typically set at +20 cm H<sub>2</sub>O, before clipping or coiling of ruptured cerebral aneurysm, and EVD setting is lowered to +10 cm H<sub>2</sub>O after aneurysm repair has been completed. Although these are arbitrary numbers, clinicians involved in perioperative care must familiarize themselves to their respective institutional practices. Sudden over-drainage of CSF in a patient with unsecured ruptured cerebral aneurysm predisposes to rebleeding due to sudden widening of transmural pressure gradient (MAP-ICP) across the aneurysm wall.<sup>84</sup> A recent survey of US-based neurointensivists and neurosurgeons revealed that most institutions utilize a strategy involving continuously open EVD to enhance CSF drainage in a patient with secured cerebral aneurysm along with a gradual weaning strategy.<sup>127</sup>

In patients with ICH, EVDs are set to provide drainage so that an intraventricular clot does not develop by stasis, and thus avoids blocking ventricular system passages and egresses that lead to noncommunicating hydrocephalus and impending herniation.<sup>128</sup>

### Results of Clamping Trials

EVDs and LDs are routinely clamped during change in patient positioning, such as occurring during turning patients in the intensive care unit (ICU) and getting patients out of bed to chair or during ambulation, and remains the recommended standard of practice.<sup>129</sup>

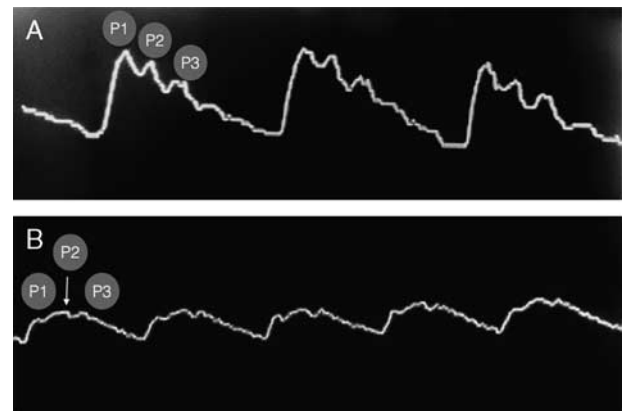
Tolerance of patients to any period of clamping depends upon the primary reason for placement of EVD or LD, ICP trends, and dependency on external CSF diversion. Patients at risk for clamp failure include those dependent on external CSF diversion, such as occurring with acute hydrocephalus, and in situations of elevated ICP.<sup>8</sup>

The preoperative evaluation of all patients with an indwelling EVD/LD should also include clinical (worsening headache, depressed level of consciousness, cranial nerve deficits, ICP elevation) and radiographic findings (worsening hydrocephalus) that confirm clamping trial intolerance.

Although clamping trials are performed periodically, they are not standardized, and initiation and frequency of such trials vary in different institutions. It is imperative that any clamping trial data be sought for and documented in the preoperative evaluation to ensure that clamping can be safely done during patient transport to and from the OR, and in the OR.

### Importance of ICP and Multimodality Monitoring Data

Often, ICP monitoring and CSF drainage is part of a multimodal monitoring plan, which includes brain tissue oxygenation, brain temperature, and continuous electroencephalography.



**FIGURE 1.** A, Normal ICP waveforms. P1 percussion wave, reflections off choroid plexus. P2 tidal wave, indicates brain compliance. P3 dicrotic wave, correlates to closure of aortic valve. P1 wave is the tallest, sharpest wave. P2 wave is no greater than 80% of the P1 wave. B, Abnormal ICP waveforms. Note here that P2 wave is higher than P1, which may indicate reduced cerebral compliance. ICP indicates intracranial pressure.

The analysis of the continuous ICP waveform can give indications of cerebral dysfunction.<sup>130</sup> Normal ICP waveform has 3 components: P1 (percussion wave), P2 (tidal wave), and P3 (dicrotic wave). The P1 wave is the tallest and the sharpest wave, and results from arterial pressure being transmitted from the choroid plexus. The P2 wave follows P1, and is usually 80% as tall as the P1 wave, and correlates to brain compliance. The P3 wave is caused by closure of the aortic valve (Fig. 1A).

Certain patients may have an abnormally high P2 waveform (Fig. 1B) demonstrating poor compliance. In this case, the compensatory mechanism defined by the compliance curve in the Monro-Kellie doctrine may be exhausted at a lower ICP than expected. Certain patients may have an abnormally high P2 waveform demonstrating poor compliance requiring therapy. In this case, the compensatory mechanism defined by the compliance curve in the Monro-Kellie doctrine may be exhausted at a lower ICP than expected. In the noncompliant brain, this reflection is stronger than the initial energy pulse P1, whereas a normally compliant brain will absorb the energy generating a less intense P2 response. Dampened waveform can be observed in patients with cerebral vasospasm, postcraniectomy, and other skull-fusion defects.

The preoperative evaluation of all patients with an indwelling EVD/LD should include recent ICP values, trends, indices, and relationship with CPP and other multimodality values made available.

### Summary

To safely conduct an anesthetic on a patient with CNS injury or risk thereof, a thorough preoperative evaluation should include all important details of the EVD and LD management. Communication with the intensive care/ward staff and a thorough investigation of

the ICP and other multimodal monitoring data and EVD/LD drain settings is paramount.

Preoperative Assessment of Patients with EVDs and LDs (Class of Recommendation and Level of Evidence):

- (1) A thorough preoperative evaluation should be performed in all patients with an indwelling EVD and LD that includes a focused history and physical exam (Class I Recommendation; Level of Evidence E).
- (2) Recommended preoperative evaluation of all patients with an indwelling EVD and LD should include all of the following (Class I Recommendation; Level of Evidence E).
  - (a) CSF color and consistency.
  - (b) ICP values, ICP trends, autoregulation indices, and relationship with CPP and other multimodal monitoring data.
  - (c) Clinical (worsening headache, depressed level of consciousness, cranial nerve deficits, ICP elevation) and radiographic evidence of clamp trial intolerance (worsening hydrocephalus).
- (3) Incorporate all information pertinent to the EVD and LD into a standardized preoperative handoff between ICU/ward providers and anesthesia providers (Class I Recommendation; Level of Evidence E.)

### SECTION 3: TRANSPORTING PATIENTS WITH EVDs

#### Introduction

Neurocritically ill patients with indwelling EVDs frequently require transport from the ICU to other sites for diagnostic and/or therapeutic procedures. These patients may be at risk of intracranial complications such as high ICP during intrahospital transport (IHT) because of direct patient movement and stimulation and/or discontinuation of ICP treatment. However, change in patient position can also lead to CSF overdrainage and result in complications such as rebleeding of intracranial aneurysm,<sup>131-133</sup> subdural hemorrhage from disruption of bridging veins,<sup>80-82</sup> and reverse brain herniation.<sup>92</sup> Anesthesiology providers are often involved in the transport of these patients to and from the ICU and to angiography and/or to and from the OR. There are no guidelines regarding EVD management during IHT.

#### Background

The majority of guidelines for the transport of critically ill patients, including those with ICP monitoring lack recommendations specific to EVD management.<sup>134-138</sup> The American Association of Neuroscience Nurses Guideline recommends routine clamping of EVD before and during IHT to prevent CSF overdrainage but does not address ICP monitoring or documentation during IHT.<sup>129</sup>

The lack of recommendations regarding EVD management is problematic because published studies document several complications associated with IHT of neurocritically ill patients, including unwanted alteration

in systemic blood pressure, respiration, and neurological conditions.<sup>139-142</sup> Andrews and colleagues prospectively observed 50 IHTs of patients with traumatic brain injury (TBI) who underwent computed tomography (CT) scanning, magnetic resonance imaging, and transport to the OR. Investigators reported high ICP as the most common secondary insult (16%) during IHT.<sup>143</sup> Picetti et al<sup>144</sup> conducted a prospective observational study of 160 neurocritically ill patients undergoing 288 CT transports; 32% of these IHTs were associated with EVDs. Although ICP was monitored in only 32 of the 127 patients with pretransport ICP monitoring, the incidence of ICP > 20 mm Hg was high (66%). However, neither of these 2 studies distinguished between ICP monitoring types. Moreover, in a case series of 7 patients with indwelling EVDs who were transported for CT, there was a 27% increase in average ICP from the initial value, and the highest ICP noted during CT exam was 35 mm Hg. Kleffmann et al<sup>145</sup> recently published a prospective observational study of 56 IHTs to CT of 43 patients with ICP monitoring (50% were EVD). The authors reported an 85% increase in average ICP from baseline during CT scan and ICP therapy was required in 26% of IHTs. Recently, Chaikittisilpa et al<sup>146</sup> reported on the largest series of 178 IHTs among 19 neurocritically ill cerebrovascular patients whose EVD was clamped before IHT. They reported that 12% of IHTs were associated with post-IHT high ICP.<sup>21</sup> ICP complications were only observed among IHTs of patients who had an open EVD setting in the ICU before transport. Pre-IHT ICP values 15 to 19 mm Hg (odds ratio, 3.4 [1.08-10.76]), pre-IHT ICP values  $\geq$  20 mm Hg (odds ratio, 12.94 [4.08-41.01]), IHT for therapeutic procedure (odds ratio, 5.82 [1.76-19.19]), and high hourly CSF output (odds ratio for every mL/h, 1.11 [1.01-1.23]) are risk factors for ICP-related complications during IHT.

Although these guideline focuses on perioperative management, the transport recommendations should be applicable to all IHTs. Personnel accompanying patient during transport should be trained and competent in management of intracranial hemodynamic perturbations such as intracranial hypertension and cerebral hypoperfusion.

#### Summary

Best evidence from observational studies suggests that neurocritically ill patients with indwelling EVDs are at risk of intracranial hypertension during IHT. Routine clamping of EVD for IHT may predispose the patients to intracranial complications, particularly in patients with open EVD status before IHT, those with pretransport ICP > 15 mm Hg, and high hourly CSF output in the ICU. Patients with LDs may experience similar complications but there are no data specific to IHT among patients with LDs.

Transporting Patients With Indwelling EVDs (Class of Recommendation and Level of Evidence):

- (1) While transporting patients with EVD and LD, it is recommended to use a dedicated intravenous pole to



mount the transducer and drainage system (Class I Recommendation; Level of Evidence E).

- (2) Do not routinely clamp EVD during IHT. The decision whether to open or clamp EVD for IHT should be individualized. Factors in pretransport evaluation that may influence decision to travel with EVD open or clamped to cerebrospinal drainage (CSF) include: (1) hourly and daily CSF output and setting of EVD, (2) EVD clamp status in the ICU, (3) patient's tolerance to clamping of EVD in ICU, and (4) reason transport is undertaken (diagnostic vs. therapeutic procedure). Test tolerance to EVD clamping before making clamping decision as patients at high risk for high ICP may benefit from opening of EVD during IHT (Class I Recommendation; Level of Evidence B-NR).
- (3) If the EVD is clamped during transport, clamping should be undertaken at 2 sites: (1) proximal port on the EVD and (2) distal port on collecting system of EVD (Class I Recommendation; Level of Evidence E).
- (4) It is recommended to continue all pretransport ICU monitoring, including intermittent clamping of EVD for accurate ICP monitoring, and documentation of ICP and other vital signs including end-tidal carbon dioxide during IHT (Class I Recommendation; Level of Evidence B-NR).
- (5) Transport personnel should be prepared to treat intracranial hypertension in patients with indwelling EVDs during IHT (Class I Recommendation; Level of Evidence E).

## SECTION 4: INTRAOPERATIVE MANAGEMENT OF EVD AND LD

### Introduction

EVD and LD function as diagnostic and therapeutic devices, and planning for a procedure requires knowledge of the basic goals of management. Addition of a pressure transducer allows monitoring and waveform display of the ICP or ISP.

### Setting Up an EVD or LD System in the OR

Some aspects of EVD or LD use can be idiosyncratic for the specific device (Figs. 2A, B). Consistency within an institution is important for choices such as the reference level and measurement scale. The reference level is most commonly the external auditory meatus for EVDs. However, this convention is not followed rigorously in clinical practice and published studies,<sup>94,147</sup> which can lead to significant measurement errors if the head of the bed is elevated above zero degrees.<sup>148</sup> For vascular surgery patients with LDs, common reference levels include the right atrium (phlebostatic axis) or lumbar catheter insertion site. The reference level is the zero-pressure point for both an attached transducer and the EVD/LD. The device is leveled by aligning the zero-pressure point on the device with the reference level on the patient; this is more accurate when a Carpenter (bubble) or laser level is utilized.<sup>149,150</sup>

A flushless pressure transducer (Fig. 2B) is used with EVD/LD that is connected to the patient through a fluid column. This is the most common configuration with the transducer located externally on the device and measurement of the ICP or ISP by the fluid column in the drainage catheter.<sup>151,152</sup> In stark contrast to commonly used transducer-based monitoring systems such as invasive arterial blood pressure, central venous, or pulmonary artery catheter, this flushless system is not pressurized in any way. Under no circumstances should a pressure transducer system with a pressure bag be assembled or used in conjunction with EVD or LD.

Extra catheter systems are increasingly available and separate the pressure transducer from the drainage catheter by placing the transducer at the tip of the catheter.<sup>153,154</sup> ICP can also be measured separately from the EVD at a variety of anatomic sites utilizing several available technologies.<sup>11,151,152,155–157</sup>

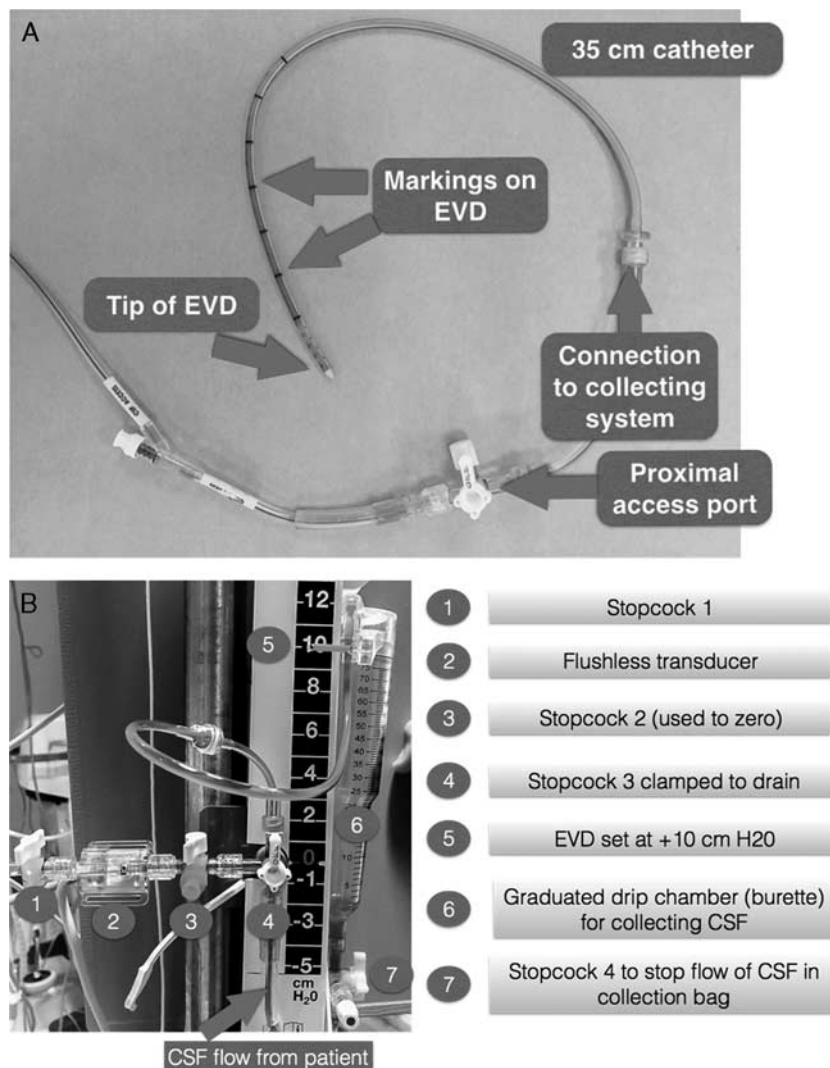
The following steps can be followed when setting up an EVD or LD intraoperatively (refer to educational document that accompanies this article, Supplemental Digital Content 2, <http://links.lww.com/JNA/A47>):

- (1) Choose the appropriate reference level and measurement scale (cm H<sub>2</sub>O). The reference level is most commonly the external auditory meatus for EVDs or the right atrium (phlebostatic axis) for vascular surgery patients who have LDs.
- (2) Mount the device upright<sup>158</sup> by attaching to an intravenous pole or to the patient's bed. Make appropriate changes to the drainage system when the patient's position changes relative to the drainage system. It is good practice to clamp the EVD or LD during changes in the position of the patient until it can be releveled.<sup>156,159</sup>
- (3) Level the device by aligning the zero point of the device and the reference level on the patient using a Carpenter (bubble) or laser level.<sup>149</sup>
- (4) Monitor ICP by EVD or ISP by LD with an attached transducer, if possible.
- (5) Adjust the collection chamber to the specified height based on the requirements of the procedure.
- (6) The fluid path of the EVD/LD is a sterile system. There should be a careful assessment of the risks/benefits before opening any of these systems to reduce the risk of infectious complications.

### EVD/LD Management During Changes in Position

The orientation of the patient can alter the ICP,<sup>148,160–162</sup> which must be accounted for in the management of EVD/LD. Intraoperatively there are frequent changes in the position of the patient such as moving the height of the table, altering the head elevation, and others. In addition, there may be times when the position of the device is moved relative to the patient such as from one pole to another or if the height of the collection chamber is altered. During such changes, it is good practice to clamp the EVD/LD if clinically feasible until the device and any attached transducer can be





**FIGURE 2.** A, Components of an EVD (a representative example of antimicrobial-impregnated EVD). B, CSF collecting system. CSF indicates cerebrospinal fluid; EVD, external ventricular drain.

releaved.<sup>156,159,163</sup> If changes in position are not accounted for, then there is the risk of both overdrainage<sup>159,163</sup> and underdrainage of CSF as well as inaccurate pressure measurements. Nevertheless, there are clinical situations such as impending herniation where it is not feasible to clamp the EVD/LD even briefly for position changes.

Positioning the patient for an intraoperative procedure is a unique phase of the case. The final patient position during the intraoperative procedure may be quite different from that in the ICU or the ward. In addition, there are very significant and dynamic changes in CSF pressure with postural changes<sup>164</sup> as might occur as the patient is moved between beds, turned prone, and others to meet the requirements of the procedure. The EVD/LD should be closed to drainage during positioning if clinically feasible, and the management reassessed once in the intraoperative position.

### Inaccurate Pressure Measurements With Simultaneous Drainage

Transducers that measure pressure by the fluid column in the drainage catheter are always inaccurate if the EVD or LD is simultaneously open for drainage.<sup>153,154,157,165</sup> For fluid-coupled systems, accurate pressure measurements require a static fluid column without simultaneous drainage allowing the transducer to directly interface with the patient line.<sup>157,165-167</sup> This concern is relevant to transducers that are mounted externally and transducers placed within the tip of the drainage catheter.<sup>166</sup> Although a value for ICP can be trended while the device is simultaneously draining,<sup>168</sup> the EVD/LD should be closed for accurate measurement at least hourly.<sup>166,168</sup> In some situations such as an anesthetized patient with elevated ICP, it would be indicated to obtain accurate pressure measurements more frequently than hourly.

Dramatic measurement errors are possible with transducers that measure with fluid coupling while at the same time draining.<sup>165</sup> Notable situations reported or discussed in the literature are compressed or slit ventricles, catheter blockage by debris, or catheter dislodgement into the parenchyma.<sup>153,154,165,166</sup> Accurately measuring the pressure by stopping drainage and connecting the transducer directly to the patient line can sometimes overcome this limitation.<sup>165,166</sup>

### Continuous Drainage Versus Continuous Monitoring

A common management decision is whether to utilize continuous drainage with intermittent monitoring (open EVD) versus continuous monitoring with intermittent drainage (monitor EVD).<sup>169,170</sup> Continuous drainage impacts the ability of the EVD as a monitor to detect trends.<sup>11</sup> The decision to choose a specific management option is dependent on the indication for drain placement and close consultation with the surgical team is important. In adult severe TBI, continuous drainage (open EVD) has been associated with better ICP control,<sup>19,170</sup> but in patients with aneurysmal SAH, open EVD management is associated with a higher rate of complications.<sup>169,171,172</sup>

### Documentation on Anesthesia Record for Patients With EVD or LD

There are 5 items that should be documented in the anesthesia record in patients with EVD or LD.

- (1) Pressure = ICP/ICP or ISP/spinal cord perfusion pressure (SCPP).
- (2) Amount of CSF drainage (expressed in mL).
- (3) Color of CSF and any change in color of CSF observed during the procedure.
- (4) Drain height relative to the reference level.
- (5) EVD/LD status as set by the stopcocks in the device (ie, open, clamped).

These items should be recorded at least hourly. However, it is reasonable that frequency of ICP documentation follow clinical situations as changes in ventilation, exposure to anesthetics, and hemodynamic changes all cause frequent perturbations in ICP and CPP. In such clinical scenarios, it may be desirable to document ICP more frequently such as every 5 to 15 minutes. CSF characteristics such as color, and any sudden change in color including the presence of blood should also be documented.<sup>129,156,173,174</sup>

With an electronic health record that automatically imports patient data, care should be exercised to prevent inaccuracies.<sup>171</sup> This may occur due to technical issues with the monitoring system or if automatic systems continue to import inaccurate data such as when the EVD system is open for continuous drainage.

### Summary

Intraoperative management of EVD and LD includes review of basic management goals, knowledge of the device in use, and the ability to make accurate

measurements. This section includes recommendations for preparing the EVD/LD, device management during positioning, and best practice for documentation in the anesthetic record. There is also a discussion of inaccuracies that arise with traditional fluid-coupled systems if simultaneously open for drainage, and evidence that is accumulating for various management strategies.

Intraoperative Management of Patients with EVDs and LDs (Class of Recommendation and Level of Evidence):

- (1) Anesthesia providers should be knowledgeable about the specific EVD and LD device in use locally as details vary (Class I Recommendation; Level of Evidence E).
- (2) It is recommended to set up your anesthetizing location following the standards of your institution, including a consistent choice of reference level and measurement scale (Class I Recommendation; Level of Evidence E).
- (3) It is recommended to level EVD or LD using a Carpenter (bubble) or laser level rather than by visual inspection (Class I Recommendation; Level of Evidence B-NR).
- (4) It is recommended to close the EVD/LD to drainage during any changes in position if clinically feasible (Class I Recommendation; Level of Evidence C).
- (5) It is recommended to relevel the transducer after changing patient position to ensure accurate monitoring of ICP and adequate drainage of CSF (Class I Recommendation; Level of Evidence C).
- (6) It is recommended to monitor ICP or ISP with an attached transducer that is appropriately leveled and zeroed according to manufacturer guidelines (Class I Recommendation; Level of Evidence E).
- (7) A pressure bag and pressurized flush system should not be attached to the EVD/LD (Class III; Level of Evidence E).
- (8) Pressure measurements should not be made while the EVD or LD is simultaneously draining. Accurate pressure measurements require a static fluid column from the monitoring site to the externally mounted transducers without simultaneous drainage (Class III Recommendation; Level of Evidence B-NR).
- (9) If open for continuous drainage, it is recommended to close the EVD or LD to measure pressure at least once per hour or more often if clinically indicated (Class I Recommendation; Level of Evidence E).
- (10) The decision for either continuous drainage or continuous monitoring should be made in consultation with the surgical team. Continuous monitoring with intermittent drainage may be considered in patients with aneurysmal SAH, and continuous drainage may be considered for adults with severe TBI (Class IIb Recommendation; Level of Evidence B-R).
- (11) It is recommended to document the following information pertinent to EVD and LD on the anesthesia record at least hourly (Class I Recommendation; Level of Evidence E): (1) pressure =

ICP/ CPP or ISP/ SCPP, (2) amount of CSF drainage (expressed in mL), (3) color of CSF and any change in color of CSF observed during the procedure, (4) drain height relative to the reference level, and (5) EVD/ LD status as set by the stopcocks in the device (ie, open, clamped)

## SECTION 5: MANAGEMENT OF EVD AND LD IN SPECIAL CLINICAL SCENARIOS

### Background

Despite careful maintenance and vigilance, complications may arise given the invasive nature of the devices. EVD and LD need monitoring with the same attention provided to other invasive monitoring devices. Safety can be enhanced using dedicated protocols and bundles that standardize the handling of EVD and LD.

### Accidental Disconnection of EVD and LD

As an immune privileged organ, the brain is at high risk for infections from bacterial contamination of drainage devices. Standardized bundles for EVD placement have significantly reduced rates of ventriculitis/ meningitis associated with EVD placement.<sup>123,175</sup> Relevant guidelines were recently published by the Society for Neurocritical Care and emphasize the importance of maintaining a closed, sterile drainage system.<sup>8</sup> If drains become inadvertently disconnected, the most immediate threat to the patient is from uncontrolled leakage of CSF as discussed below. A clamp should immediately be put on the free end of the catheter to stop leakage. As the system becomes contaminated by disconnection, all distal parts should be replaced with new, sterile tubing.<sup>129</sup> As replacement of the proximal catheter carries new procedural risk,<sup>129</sup> it will not routinely be replaced after accidental disconnection. There is no evidence to support empiric antibiotic treatment after disconnection of an EVD or LD system. After a new system is connected, patency must be confirmed, especially in situations where the catheter may have been displaced. In doubt, CT imaging can confirm appropriate position of an EVD catheter.

### Drain Occlusion and Troubleshooting

No studies exist in the literature that compares methods to troubleshoot EVD or LD. Published recommendations represent expert opinion and practice surveys.<sup>123,129,150</sup> Sudden reduction in the hourly volume of CSF drained can indicate an obstruction in the drainage system. Similarly, if the ICP waveform is dampened, the EVD may be occluded.<sup>176</sup> Patency can be tested by briefly lowering the drainage system. This may also be sufficient to remove small amounts of material such as air bubbles, blood clots, or tissue that may obstruct the tubing. If patency is not restored by briefly lowering the system, troubleshooting should continue by examining the drainage tubing distal to the patient. If any occluding material is present, the tubing can be flushed away from the patient to remove the debris. Alternatively, the entire

drainage system can be changed, if necessary. Occlusion of the proximal catheter can sometimes be resolved by flushing the catheter toward the patient. This may increase ICP, as the irrigation solution adds to the intracranial volume. In patients with poor intracranial compliance, irrigation with even small volumes can create disproportionately large and dangerous increases of ICP, possibly causing brain herniation. Proximal flushing should only be attempted after discussion with the neurosurgeon. Volumes of 0.5 to 2 mL of sterile, preservative-free isotonic sodium chloride solution can be used to flush the EVD catheter, although a variety of antibiotic solutions are sometimes used as well.<sup>177</sup> Maintaining aseptic conditions are essential. The technique should be guided by institutional protocol and include, as a minimum, sterile gloves, mask, and hair cover.<sup>175,178,179</sup> The drainage system should be relevelled and rezeroed after manipulation.

### Overdrainage of CSF

Rapid drainage of large volumes of CSF from the ventricles (ie, more than the 15 to 20 mL produced in an hour) can collapse the ventricles (especially when communication to the extraventricular subarachnoid space is compromised, as in noncommunicating hydrocephalus), thus shrinking the cerebral hemispheres away from the skull and dura. This creates tension on the bridging veins and can cause acute subdural hematomas.<sup>180</sup> In patients with aneurysmal SAH and an unsecured aneurysm, rapid drainage of CSF while the dura is closed can increase the transmural pressure of the aneurysm and provoke rebleeding.<sup>181</sup> Overdrainage from an EVD occurs most commonly when the patient's position is changed (eg, the head of the bed or operating table is raised) without simultaneously adjusting the position of the EVD drainage system.<sup>163</sup> Drainage systems should be clamped whenever patient position is changed. Patients with critically elevated ICP may not tolerate even brief clamping of their EVD during transport, in which case extra care needs to be taken to secure the drainage system to the bed and to monitor output. Once a new position is achieved, the drain should be relevelled and rezeroed.

Inadvertent overdrainage of significant amounts of CSF is a more common problem with LDs, as they are more prone to covert leakage of CSF around the drain or through a persistent dural defect after removal. There are many case reports describing complications from overdrainage related to LDs.<sup>86,182–184</sup> The most serious complication is herniation,<sup>185–187</sup> which is more likely to occur when there is a differential in intracranial and spinal CSF pressure.<sup>188</sup> Acute herniation from lumbar overdrainage of CSF can present with cranial nerve deficits, hypertension, or bradycardia,<sup>189</sup> and can lead to brainstem hemorrhage.<sup>64</sup> It can often be corrected by lowering the head of the bed to Trendelenburg position.<sup>190</sup> Injection of sterile isotonic saline solution into the LD to replace lost CSF has also been used as an emergency intervention. Patients after decompressive hemicraniectomy are at increased risk for paradoxical herniation from lumbar

drainage of CSF. Their skull defect exposes the brain to ambient pressure, so that relatively small decreases in CSF pressure can cause significant brain sag and herniation (syndrome of the trephined).<sup>191,192</sup> Tension pneumocephalus and subdural hematoma from brain sag have also been described as complications from LDs.<sup>93,193</sup>

### CSF Drainage at Different Points During a Case (eg, Before Craniotomy Bone Flap, Before Dural Reflection, After Durotomy, or After Dural Closure)

LDs are often placed electively for procedures that carry a risk of postoperative CSF leak, such as skull base surgery.<sup>194</sup> They are used to drain CSF and improve exposure during the procedure, and 10 to 20 mL of CSF is usually drained immediately before durotomy to “relax”

**TABLE 5.** Perioperative Checklist for Patients With External Ventricular and Lumbar Drain

Preoperative assessment
<input type="checkbox"/> Obtain baseline neurological examination
<input type="checkbox"/> Review EVD (cm H <sub>2</sub> O) and LD setting (in mL/h of CSF drained)
<input type="checkbox"/> Review hourly CSF output to obtain baseline
<input type="checkbox"/> Review baseline ICP mm Hg, ICP trends, and available multimodal monitoring data
<input type="checkbox"/> Review baseline CSF color and consistency
<input type="checkbox"/> Review clamp trials data if available
<input type="checkbox"/> Review coagulopathy profile
<input type="checkbox"/> Review antibiotic plan if anticipating new EVD/LD insertion in the operating room
<input type="checkbox"/> Provide EVD and LD details during preoperative handoff between intensive care/ward providers and the anesthesia providers
Transporting patients with EVD and LD
<input type="checkbox"/> Confirm decision to travel with EVD or LD clamp vs. open
<input type="checkbox"/> If traveling with EVD clamp, ensure clamping at both proximal port on EVD and distal port on CSF collecting system
<input type="checkbox"/> Confirm HOB status during transport
<input type="checkbox"/> Confirm availability of dedicated intravenous pole for EVD/LD mount
<input type="checkbox"/> Confirm leveling EVD at external auditory meatus and LD at phlebostatic axis or at lumbar catheter insertion site
<input type="checkbox"/> Enable ICP monitoring during transport
<input type="checkbox"/> Confirm availability of medications needed to treat intracranial hypertension during transport
Intraoperative management of indwelling drains
<input type="checkbox"/> Prepare transducer cable
<input type="checkbox"/> Identify EVD/LD tubing by appropriate unique labeling
<input type="checkbox"/> Confirm HOB status during surgical procedure
<input type="checkbox"/> Confirm leveling of EVD at external auditory meatus and LD at phlebostatic axis
<input type="checkbox"/> Obtain ICP waveform and baseline ICP value
<input type="checkbox"/> Record q 1-h EVD/LD setting
<input type="checkbox"/> Record at least q 1-h ICP values (recorded with EVD closed to drain)
<input type="checkbox"/> Record at least q 1-h EVD/LD drain output (expressed in mL)
<input type="checkbox"/> Provide EVD and LD details during intraoperative handoffs between anesthesia providers
Inform surgeon if any $\geq 1$ of the following
<input type="checkbox"/> Sudden decline in CSF drainage or no drainage from EVD or LD, or occlusion of EVD or LD
<input type="checkbox"/> If drain output is > 15-20 mL at any time or in any given hour
<input type="checkbox"/> Sudden change in CSF color
<input type="checkbox"/> Dampening or loss of ICP waveform

cm H<sub>2</sub>O indicates centimeters of water; CSF, cerebrospinal fluid; EVD, external ventricular drain; HOB, head-of-bed; ICP, intracranial pressure; LD, lumbar drain.

the brain, while the drain remains clamped for the rest of the procedure. LDs are also used to reduce CSF pressure and optimize SCPP during repair of thoracoabdominal aortic aneurysms. CSF is usually drained to a pressure goal, for example, 10 mm Hg of CSF pressure (zeroed at the right atrium). Use of CSF drainage for spinal cord protection during thoracoabdominal aortic aneurysm repair has recently been reviewed,<sup>195,196</sup> and is not the focus of the current document.

EVDs are not commonly placed for intraoperative CSF drainage, but rather to treat ICP elevation caused by noncommunicating hydrocephalus. Most patients will come from the ICU with an EVD in place. CSF can be drained from an EVD to reduce ICP and improve surgical conditions, like a LD, with the difference that if the patient has noncommunicating hydrocephalus, CSF will be removed only from the intraventricular space. Rapid removal of a large volume of CSF will cause sudden decrease in ICP and can cause subdural hematoma, as discussed above. In patients with aneurysmal SAH, sudden CSF drainage before durotomy in patients can result in precipitous decrease in ICP and widening of transmural pressure gradient and can cause fatal rerupture of cerebral aneurysm and should be avoided.<sup>197</sup>

### Monitoring and Patient Safety

Changes in EVD output can provide important clues into changes in patient condition. Increasing output can indicate an increase in intracranial volume from edema or hemorrhage, or rising ICP. Bright red output from an EVD suggests an intraventricular hemorrhage or SAH, such as from rerupture of an unsecured aneurysm. This is a life-threatening emergency, and thus should be communicated immediately to the surgical team. Alternatively, blood from a previous intraventricular hemorrhage may have been mobilized and transiently color the CSF more brightly red. Although this is a much more benign scenario, suspicion should remain high for a fresh hemorrhage, especially if there are changes in vital signs, such as hypertension or bradycardia, or if ICP increases. Close communication is key to safe management.

### Avoiding Accidental Injections Into EVD or LD

EVD tubing routinely has at least one 3-way stopcock that allows access to the system. Commonly used EVD systems use the Luer-lock standard and most EVD tubing is not specifically marked to differentiate it from intravenous tubing. This creates the opportunity for providers to inadvertently inject drugs into the ventricular system that are meant for intravenous use. There are many case reports and case series that describe accidental intrathecal injection of agents as varied as anesthetic drugs,<sup>98,99</sup> antibiotics, chemotherapeutic agents, or gadolinium contrast, frequently with devastating or fatal consequences.<sup>102-105</sup> Care should be taken to prevent this severe complication by carefully labeling EVD tubing and access ports, and using color-coded caps (please refer to educational document that accompanies this publication, Supplemental Digital Content 2, <http://links.lww.com/JNA/A47>). In the future,

**TABLE 6.** EVD and LD Clinical Competency Checklist for Clinicians Involved in Perioperative Care

Name of Provider _____ Date _____ Validated by _____	Date/Initials of Validator
<b>Steps</b>	
Has the anesthesia technician already tightened the connection between the bottom of the burette and the bag (loose from the manufacturer, similar to pressure tubing for arterial lines) and primed the system using sterile technique (wearing face mask, making sure not to touch sterile connections with bare hands or only clean gloves). Only a flushless transducer system is used for EVD and LD	
Leveling and zeroing EVD system	
<input type="checkbox"/> Level flushless transducer and red “0” on drainage system at EAM. State why EAM level is typically chosen for neurosurgical CSF drainage systems (Answer: approximate level of Foramen of Monro, drainage channel between lateral ventricles)	
<input type="checkbox"/> Raise burette to desired level (EAM or EAM ± _____ cm H <sub>2</sub> O). State rationale (Answer: ICP must rise above pressure-level indicator of drip chamber to drain CSF)	
<input type="checkbox"/> Turn stopcocks on patient line off until ready to connect and drain	
<input type="checkbox"/> Use sterile technique to connect ventricular catheter with CSF drainage system (face mask and sterile gloves)	
<input type="checkbox"/> Once system is attached to ventricular catheter, attach pressure cable to flushless transducer. Open panel mount (reference) stopcock port to the right of the flushless transducer (remove injection cap); turn stopcock off to the patient and open the system to air. Press, “zero” on bedside monitor. When monitor says “0,” return stopcock, upright, and replace injection cap	
Monitoring ICP and draining CSF	
<input type="checkbox"/> Demonstrate correct position of stopcock to monitor true ICP (not trend) (Answer: stopcock should be at 12 o’clock)	
State requirements for true ICP determination (Answer: corresponding waveform and numeric display; ICP is a mean value in mm Hg)	
<input type="checkbox"/> Demonstrate correct position of stopcock to trend ICP (not true ICP) and drain (Answer: 3 o’clock)	
<input type="checkbox"/> Demonstrate correct position of stopcock to prevent drainage and not transduce ICP (Answer: 6 o’clock and may also turn stopcock toward patient on patient line closest to ventricular catheter)	
<input type="checkbox"/> Demonstrate correct position of stopcock to transport and monitor true ICP at the same time (Answer: 12 o’clock)	
Complications of EVD	
<input type="checkbox"/> State common complications of EVD	
<input type="checkbox"/> (Answer: underdrainage; overdrainage, infection, possibly rebleeding. Overdrainage may result in subdural hematoma or herniation)	
<input type="checkbox"/> State the usual recommended CSF drainage rate (Answer: 20 mL/h; adults make 500 mL/24 h which is 22 mL/h; so drain the amount that is made in an hour)	
<input type="checkbox"/> State normal ICP (Answer: <20 mm Hg)	
<input type="checkbox"/> State calculation of CPP (Answer: MAP-ICP = CPP. 60 mm Hg is generally considered acceptable)	
<input type="checkbox"/> State that CSF drainage may be desired continuously or intermittently. Defer to neurosurgery; however, do not drain, in general over 20 mL/h	
<input type="checkbox"/> Record ICP/ CPP and CSF output at least hourly in electronic record	
<input type="checkbox"/> Why would it be bad practice to attach the transducer to a pressure bag set-up? If so, the answer of course would be, you will deliver 3 mL/h of fluid to an already tight space and if someone activates the fast flush, you could have sustained ICPs with herniation (EVD) or if a LD for aortic aneurysm repair, possibly create/increase spinal cord ischemia with paraplegia	
Transport	
<input type="checkbox"/> Demonstrate position of CSF drainage system during transport and position of stopcock (Answer: CSF drainage system upright on IV pole, leveled; flushless transducer zeroed with transport monitor and stopcock at 12 o’clock to allow accurate monitoring of ICP in transport but no drainage during transport). Only leave CSF drainage system open to transport if herniation is pending. If left open during transport must observe CSF drainage constantly and avoid overdrainage	
Has the anesthesia technician already tightened the connection between the bottom of the burette and the bag (loose from the manufacturer, similar to pressure tubing for arterial lines) and primed the system using sterile technique (wearing face mask, making sure not to touch sterile connections with bare hands or only clean gloves). Only a flushless transducer system is used for EVD and LD	
Leveling external LD system	
<input type="checkbox"/> Level the red “0” on drainage system at phlebostatic axis	
<input type="checkbox"/> Raise burette to desired level (EAM or EAM ± _____ cm H <sub>2</sub> O). State rationale (Answer: ICP must rise above reference level of drip chamber to drain CSF)	
Turn stopcocks on patient line off until ready to connect and drain	
Use sterile technique to connect lumbar catheter with CSF drainage system	
Draining CSF	
<input type="checkbox"/> Demonstrate correct position of stopcock to drain CSF	
<input type="checkbox"/> (Answer: 3 o’clock or 9 o’clock)	
<input type="checkbox"/> Demonstrate correct position of stopcock to prevent drainage	
<input type="checkbox"/> (Answer: 6 o’clock and may also turn stopcock toward head at port on patient line closest to lumbar catheter)	
Complications of LD	
<input type="checkbox"/> State common complications of LD	
<input type="checkbox"/> (Answer: underdrainage; overdrainage, infection, possibly rebleeding. Overdrainage may result in subdural hematoma or herniation)	
<input type="checkbox"/> State the usual recommended CSF drainage rate	
<input type="checkbox"/> (Answer: 10-15 mL/h; for a LD; the risk of herniation may be greater than with a LD related to downward pull of CSF drainage at the lumbar level)	
<input type="checkbox"/> Record CSF output at least hourly in electronic record	
Why would it be bad practice to attach the transducer to a pressure bag set-up? If so, the answer of course would be, you will deliver 3 mL/h of fluid to an already tight space and if someone activates the fast flush, you could have sustained ICPs with herniation (EVD) or if a LD for aortic aneurysm repair, possibly create/increase spinal cord ischemia with paraplegia	
Transport	
<input type="checkbox"/> Demonstrate position of CSF drainage system during transport and position leveled at EAM and turned off to drainage, stopcock at 12 or 6 o’clock	

CPP indicates cerebral perfusion pressure; EAM, external auditory meatus; EVD, external ventricular drainage; ICP, intracranial pressure; LD, lumbar drain.

manufacturers should design access ports that cannot be confused with intravenous access ports, similar to the safety pin system used for anesthetic gases.<sup>102</sup> Treatment of accidental intrathecal injection is supportive. Aspiration of CSF and replacement with isotonic sodium chloride to “lavage” the intrathecal space has been suggested as an emergent intervention to reduce neurotoxicity, especially when caustic agents such as chemotherapeutic drugs have been injected inadvertently.<sup>100,101</sup> No controlled studies exist, however, and success of this intervention is mixed in reported cases.

### **Intrathecal Injection of Fluorescein Dye for CSF Leak**

Intrathecal injection of fluorescein dye through the LD is sometimes indicated intraoperatively during repair of CSF leaks to identify the location of actual defect. In addition, it is useful to assist in locating additional leak sites and to confirm the watertight closure of the defect. Although it has been used worldwide for this purpose, the intrathecal fluorescein is an off-label use of the product; hence, informed consent is required in many centers.

The usual dose range used is 10 to 50 mg (0.1 to 0.5 mL of 10% fluorescein with 9.5 mL of CSF) injected over 30 minutes.<sup>198</sup> Complications are mostly related to meningeal irritation that include headache, nausea and vomiting, dizziness, nuchal pain, limb weakness, generalized seizures,<sup>199</sup> and cranial nerve palsy. Most complications are dose related and transient, and typically resolve within 7 to 10 days. Limited evidence suggests that fluorescein injection should be avoided in patients with history of seizures, hydrocephalus, spinal stenosis, and cerebral edema. We strongly recommend that individual institutions should develop their own protocols for intrathecal administration of fluorescein.

### **Summary of Management of EVDs and LDs in Special Clinical Scenarios**

Because of invasive nature of these devices, complications that occur perioperatively include accidental disconnection, drain occlusion, overdrainage, and inadvertent administration of drugs into the drains. Extra vigilance, clear labeling of the drains, and the development of standardized protocol on the handling of EVD/LDs are some of the measures that can minimize these complications.

Management of EVD and LD in Special Clinical Scenarios (Class of Recommendation and Level of Evidence):

- (1) EVD or LD tubing that is accidentally disconnected should be clamped immediately to prevent overdrainage of CSF (Class I Recommendation; Level of Evidence C).
- (2) If the EVD or LD systems are contaminated by disconnection, all distal parts should be replaced with new sterile tubing (Class IIa Recommendation; Level of Evidence E).
- (3) Routine flushing of the EVD or LD catheter should not be performed (Class III Recommendation; Level of Evidence E).

- (4) In patients with ruptured cerebral aneurysm, sudden excessive drainage of CSF before securing the aneurysm can provoke aneurysm rerupture and should be avoided (Class III Recommendation; Level of Evidence C).
- (5) Identification of EVD or LD tubing by appropriate labels and use of other visual aids is recommended to prevent confusion with intravenous ports (Class I Recommendation; Level of Evidence E).
- (6) Accidental intrathecal injection should be recognized and reported to the neurosurgeon (Class IIa Recommendation; Level of Evidence E).
- (7) Lavage of the intrathecal space after accidental injection is not recommended (Class III Recommendation; Level of Evidence C).
- (8) Establish institutional standards to ensure safe intrathecal injection of fluorescein dye through LD in patients with suspected CSF leak (Class I Recommendation; Level of Evidence E).

## **SECTION 6: PERIOPERATIVE CHECKLIST, DEVELOPING CLINICAL COMPETENCIES FOR EVD/LD, AND CONTINUED MEDICAL EDUCATION**

### **Use of a Perioperative EVD and LD Checklist**

The material presented above provides a framework from which a perioperative checklist can be constructed. Such a checklist (Table 5) incorporated into a shared mental model<sup>200–202</sup> is intended to reduce systematic errors during perioperative management of patients with EVD or LD. This perioperative checklist can be used for all patients undergoing perioperative care, and may be included in preoperative handoffs between ICU/ward providers and anesthesia providers, and during intraoperative handoffs between various anesthesia providers. Checklist can be modified and used during IHT of neurocritically ill patients.

### **Clinical Competence and Continued Medical Education Related to Management of Patients With EVD/LD**

For clinicians involved in perioperative care of patients, one of the core competencies is the ability to administer safe and reliable care on a consistent basis. In relationship to patients with EVD and LD, this translates to acquiring knowledge about the basics of EVD and LD relevant to the perioperative period, at the same time, possessing essentially the same skills as neuroscience nursing while managing these drains within the confines of perioperative care.

Although management of patients with EVD and LD may be expected from all clinicians involved in perioperative care of patients, there is lack of published perioperative guidelines and standards.<sup>203–205</sup> However, there are various educational materials that are available on the World Wide Web that provide institutional guidance to practitioners regarding EVD and ICP monitoring.<sup>159,173,174,205–207</sup> A comprehensive clinical competency checklist can be found in Table 6.

This or a modification of this checklist may be used by institutions to establish competency standards for clinicians involved in perioperative care of patients with EVD and LD. It is recommended that institutions establish an annual evaluation of competency, a continued medical education program, and a refresher course<sup>208</sup> for all clinicians involved in perioperative care of patients with EVD and LD.

## Summary

A clinical competency checklist comprising setting up and maintenance of EVD or LD, along with a comprehensive checklist covering preoperative assessment, transporting patients, intraoperative management, and evaluation of patient under special circumstances provides a framework to clinicians involved in perioperative care of patients with EVD or LD.

Perioperative Checklist, Clinical Competency, and Continued Medical Education (Class of Recommendation and Level of Evidence):

- (1) It is recommended that clinicians involved in perioperative care of patients must familiarize themselves with information regarding indications, contraindications, leveling, zeroing of transducer, and current standards related to transporting and intraoperative care of patients with EVD or LD (Class I Recommendation; Level of Evidence E).
- (2) It is reasonable to provide educational material aimed at perioperative management of EVD and LD in form of text and/or multimedia to all clinicians involved in perioperative care of patients (Class IIa Recommendation; Level of Evidence E).
- (3) To standardize care of patients with EVD and LD, and to promote a shared mental model, use of a perioperative checklist is recommended (Class I Recommendation; Level of Evidence E).
- (4) It is recommended that institutions set up competency standards for clinicians involved in perioperative care of patients with EVD and LD (Class I Recommendation; Level of Evidence E).

## ACKNOWLEDGMENTS

The authors thank Patricia (Pat) A. Blissitt (PhD, RN, CCRN, CNRN, SCRN, CCNS, CCM, ACNS-BC) for her contributions toward the clinical competency checklist.

The authors thank Kathleen A. McGraw, MA, MLS (Health Sciences Library, The University of North Carolina at Chapel Hill) for her contributions in developing and implementing a systematic literature search.

## REFERENCES

1. Dey M, Jaffe J, Stadnik A, et al. External ventricular drainage for intraventricular hemorrhage. *Curr Neurol Neurosci Rep*. 2012;12:24–33.
2. Sussman ES, Kellner CP, Nelson E, et al. Hemorrhagic complications of ventriculostomy: incidence and predictors in patients with intracerebral hemorrhage. *J Neurosurg*. 2014;120:931–936.
3. Stangl AP, Meyer B, Zentner J, et al. Continuous external CSF drainage—a perpetual problem in neurosurgery. *Surg Neurol*. 1998;50:77–82.
4. Rosenbaum BP, Vadera S, Kelly ML, et al. Ventriculostomy: Frequency, length of stay and in-hospital mortality in the United States of America, 1988–2010. *J Clin Neurosci*. 2014;21:623–632.
5. Srinivasan VM, O'Neill BR, Jho D, et al. The history of external ventricular drainage. *J Neurosurg*. 2014;120:228–236.
6. Tronnier V, Aschoff A, Hund E, et al. Commercial external ventricular drainage sets: unsolved safety and handling problems. *Acta Neurochir (Wien)*. 1991;110:49–56.
7. Weisenberg SH, TerMaath SC, Seaver CE, et al. Ventricular catheter development: past, present, and future. *J Neurosurg*. 2016;125:1504–1512.
8. Fried HI, Nathan BR, Rowe AS, et al. The insertion and management of external ventricular drains: an evidence-based consensus statement: a statement for healthcare professionals from the Neurocritical Care Society. *Neurocrit Care*. 2016;24:61–81.
9. Hiratzka LF, Bakris GL, Beckman JA, et al. 2010 ACCF/AHA/AATS/ACR/ASA/SCA/SCAI/SIR/STS/SVM guidelines for the diagnosis and management of patients with thoracic aortic disease: executive summary: a report of the American College of Cardiology Foundation/American Heart Association Task Force on Practice Guidelines, American Association for Thoracic Surgery, American College of Radiology, American Stroke Association. *Circulation*. 2010;121:e266–e369.
10. Powers WJ, Derdeyn CP, Biller J, et al. 2015 American Heart Association/American Stroke Association focused update of the 2013 guidelines for the early management of patients with acute ischemic stroke regarding endovascular treatment: a guideline for healthcare professionals from the American Heart Association/American Stroke Association. *Stroke*. 2015;46:3020–3035.
11. Chesnut R, Videtta W, Vespa P, et al. Participants in the International Multidisciplinary Consensus Conference on Multimodality Monitoring. Intracranial pressure monitoring: fundamental considerations and rationale for monitoring. *Neurocrit Care*. 2014;21(suppl 2):S64–S84.
12. Connolly ES Jr, Rabinstein AA, Carhuapoma JR, et al. Guidelines for the management of aneurysmal subarachnoid hemorrhage: a guideline for healthcare professionals from the American Heart Association/American Stroke Association. *Stroke*. 2012;43:1711–1737.
13. Solter VV, Roje-Bedeković M, Breitenfeld T, et al. Recommendations for the management of medical complications in patients following aneurysmal subarachnoid hemorrhage. *Acta Clinica Croatica*. 2014;53:113–138.
14. Park S, Yang N, Seo E. The effectiveness of lumbar cerebrospinal fluid drainage to reduce the cerebral vasospasm after surgical clipping for aneurysmal subarachnoid hemorrhage. *J Korean Neurosurg Soc*. 2015;57:167–173.
15. Hemphill JC III, Greenberg SM, Anderson CS, et al. Guidelines for the management of spontaneous intracerebral hemorrhage: a guideline for healthcare professionals from the American Heart Association/American Stroke Association. *Stroke*. 2015;46:2032–2060.
16. Wijedicks EF, Sheth KN, Carter BS, et al. Recommendations for the management of cerebral and cerebellar infarction with swelling: a statement for healthcare professionals from the American Heart Association/American Stroke Association. *Stroke*. 2014;45:1222–1238.
17. Paldor I, Rosenthal G, Cohen JE, et al. Intracranial pressure monitoring following decompressive hemicraniectomy for malignant cerebral infarction. *J Clin Neurosci*. 2015;22:79–82.
18. Bratton SL, Chestnut RM, Ghajar J, et al. VI. Indications for intracranial pressure monitoring. *J Neurotrauma*. 2007;24(suppl 1):S-37.
19. Carney N, Totten AM, O'Reilly C, et al. Guidelines for the management of severe traumatic brain injury, fourth edition. *Neurosurgery*. 2016. [Epub ahead of print].
20. Lescot T, Boroli F, Reina V, et al. Effect of continuous cerebrospinal fluid drainage on therapeutic intensity in severe traumatic brain injury. *Neurochirurgie*. 2012;58:235–240.
21. Papo I, Caruselli G, Luongo A. CSF withdrawal for the treatment of intracranial hypertension in acute head injuries. *Acta Neurochir (Wien)*. 1981;56:191–199.
22. Bhargava D, Alalade A, Ellamushi H, et al. Mitigating effects of external ventricular drain usage in the management of severe head injury. *Acta Neurochir (Wien)*. 2013;155:2129–2132.



23. Walker CT, Stone JJ, Jacobson M, et al. Indications for pediatric external ventricular drain placement and risk factors for conversion to a ventriculoperitoneal shunt. *Pediatr Neurosurg.* 2012;48:342–347.
24. Basauri LT, Concha-Julio E, Selman JM, et al. Cerebrospinal fluid spinal lumbar drainage: indications, technical tips, and pitfalls. *Crit Rev Neurosurg.* 1999;9:21–27.
25. Elvy J, Porter D, Brown E. Treatment of external ventricular drain-associated ventriculitis caused by *Enterococcus faecalis* with intraventricular daptomycin. *J Antimicrob Chemother.* 2008;61:461–462.
26. Hagel S, Bruns T, Pletz MW, et al. External ventricular drain infections: risk factors and outcome. *Interdiscip Perspect Infect Dis.* 2014;2014:708531.
27. Andrews RJ, Bringas JR. A review of brain retraction and recommendations for minimizing intraoperative brain injury. *Neurosurgery.* 1993;33:1052–1063. Discussion 1063.
28. Telischi FF, Landy H, Balkany TJ. Reducing temporal lobe retraction with the middle fossa approach using a lumbar drain. *Laryngoscope.* 1995;105:219–220.
29. Ziai W, Moullaali T, Nekoovaght-Tak S, et al. No exacerbation of perihematomal edema with intraventricular tissue plasminogen activator in patients with spontaneous intraventricular hemorrhage. *Neurocrit Care.* 2013;18:354–361.
30. Dey M, Stadnik A, Awad IA. Thrombolytic evacuation of intracerebral and intraventricular hemorrhage. *Curr Cardiol Rep.* 2012;14:754–760.
31. Ramakrishna R, Sekhar LN, Ramanathan D, et al. Intraventricular tissue plasminogen activator for the prevention of vasospasm and hydrocephalus after aneurysmal subarachnoid hemorrhage. *Neurosurgery.* 2010;67:110–117. Discussion 117.
32. Varelas PN, Rickert KL, Cusick J, et al. Intraventricular hemorrhage after aneurysmal subarachnoid hemorrhage: pilot study of treatment with intraventricular tissue plasminogen activator. *Neurosurgery.* 2005;56:205–213. Discussion 205–213.
33. Lu N, Jackson D, Luke S, et al. Intraventricular nicardipine for aneurysmal subarachnoid hemorrhage related vasospasm: assessment of 90 days outcome. *Neurocrit Care.* 2012;16:368–375.
34. Webb A, Kolenda J, Martin K, et al. The effect of intraventricular administration of nicardipine on mean cerebral blood flow velocity measured by transcranial Doppler in the treatment of vasospasm following aneurysmal subarachnoid hemorrhage. *Neurocrit Care.* 2010;12:159–164.
35. Goodson K, Lapointe M, Monroe T, et al. Intraventricular nicardipine for refractory cerebral vasospasm after subarachnoid hemorrhage. *Neurocrit Care.* 2008;8:247–252.
36. Remes F, Tomas R, Jindrak V, et al. Intraventricular and lumbar intrathecal administration of antibiotics in postneurosurgical patients with meningitis and/or ventriculitis in a serious clinical state. *J Neurosurg.* 2013;119:1596–1602.
37. Wang JH, Lin PC, Chou CH, et al. Intraventricular antimicrobial therapy in postneurosurgical Gram-negative bacillary meningitis or ventriculitis: a hospital-based retrospective study. *J Microbiol Immunol Infect.* 2014;47:204–210.
38. Coselli JS, LeMaire SA, Koksoy C, et al. Cerebrospinal fluid drainage reduces paraplegia after thoracoabdominal aortic aneurysm repair: results of a randomized clinical trial. *J Vasc Surg.* 2002;35:631–639.
39. Ling E, Arellano R. Systematic overview of the evidence supporting the use of cerebrospinal fluid drainage in thoracoabdominal aneurysm surgery for prevention of paraplegia. *Anesthesiology.* 2000;93:1115–1122.
40. Mancio J, Pires-Morais G, Bettencourt N, et al. Meningeal haemorrhage secondary to cerebrospinal fluid drainage during thoracic endovascular aortic repair. *Oxf Med Case Reports.* 2014;2014:56–59.
41. Albu S, Florian IS, Bolboaca SD. The benefit of early lumbar drain insertion in reducing the length of CSF leak in traumatic rhinorrhea. *Clin Neurol Neurosurg.* 2016;142:43–47.
42. Bell RB, Dierks EJ, Homer L, et al. Management of cerebrospinal fluid leak associated with craniomaxillofacial trauma. *J Oral Maxillofac Surg.* 2004;62:676–684.
43. Crowson MG, Cunningham CD III, Moses H, et al. Preoperative lumbar drain use during acoustic neuroma surgery and effect on CSF leak incidence. *Ann Otol Rhinol Laryngol.* 2016;125:63–68.
44. Bakhsheshian J, Hwang MS, Friedman M. What is the evidence for postoperative lumbar drains in endoscopic repair of CSF leaks? *Laryngoscope.* 2015;125:2245–2246.
45. Tien DA, Stokken JK, Recinos PF, et al. Cerebrospinal fluid diversion in endoscopic skull base reconstruction: an evidence-based approach to the use of lumbar drains. *Otolaryngol Clin North Am.* 2016;49:119–129.
46. Aghamohamadi D, Ahmadvand A, Salehpour F, et al. Effectiveness of lumbar drain versus hyperventilation to facilitate transphenoidal pituitary (suprasellar) adenoma resection. *Anesth Pain Med.* 2013;2:159–163.
47. Foreman PM, Hendrix P, Griessenauer CJ, et al. External ventricular drain placement in the intensive care unit versus operating room: evaluation of complications and accuracy. *Clin Neurol Neurosurg.* 2015;128:94–100.
48. Kakarla UK, Kim LJ, Chang SW, et al. Safety and accuracy of bedside external ventricular drain placement. *Neurosurgery.* 2008;63(suppl 1):ONS162–ONS166. Discussion ONS166–167.
49. Abdoh MG, Bekaert O, Hodel J, et al. Accuracy of external ventricular drainage catheter placement. *Acta Neurochir (Wien).* 2012;154:153–159.
50. Mura J, Figueiredo EG, Carmona P, et al. The anterior ventriculocisternostomy: the pioneers' work revisited. *J Neurol Surg A Cent Eur Neurosurg.* 2013;74:146–151.
51. Rehman T, Rehman AU, Rehman A, et al. A US-based survey on ventriculostomy practices. *Clin Neurol Neurosurg.* 2012;114:651–654.
52. Bohl MA, Almefty KK, Nakaji P. Defining a standardized approach for the bedside insertion of temporal horn external ventricular drains: procedure development and case series. *Neurosurgery.* 2016;79:296–304.
53. Park YG, Woo HJ, Kim E, et al. Accuracy and safety of bedside external ventricular drain placement at two different cranial sites: Kocher's point versus forehead. *J Korean Neurosurg Soc.* 2011;50:317–321.
54. Phillips SB, Delly F, Nelson C, et al. Bedside external ventricular drain placement: can multiple passes be predicted on the computed tomography scan before the procedure? *World Neurosurg.* 2014;82:739–744.
55. Saladino A, White JB, Wijdicks EF, et al. Malplacement of ventricular catheters by neurosurgeons: a single institution experience. *Neurocrit Care.* 2009;10:248–252.
56. Patil V, Gupta R, San Jose Estepar R, et al. Smart stylet: the development and use of a bedside external ventricular drain image-guidance system. *Stereotact Funct Neurosurg.* 2015;93:50–58.
57. Sarrafzadeh A, Smoll N, Schaller K. Guided (VENTRI-GUIDE) versus freehand ventriculostomy: study protocol for a randomized controlled trial. *Trials.* 2014;15:478.
58. Sladky JH, Piwinski SE. Lumbar puncture technique and lumbar drains. *Atlas Oral Maxillofac Surg Clin North Am.* 2015;23:169–176.
59. Narouze S, Benzon HT, Provenzano DA, et al. Interventional spine and pain procedures in patients on antiplatelet and anticoagulant medications: guidelines from the American Society of Regional Anesthesia and Pain Medicine, the European Society of Regional Anaesthesia and Pain Therapy, the American Academy of Pain Medicine, the International Neuromodulation Society, the North American Neuromodulation Society, and the World Institute of Pain. *Reg Anesth Pain Med.* 2015;40:182–212.
60. Bruder M, Schuss P, Konczalla J, et al. Ventriculostomy-related hemorrhage after treatment of acutely ruptured aneurysms: the influence of anticoagulation and antiplatelet treatment. *World Neurosurg.* 2015;84:1653–1659.
61. Dimitriou J, Levivier M, Gugliotta M. Comparison of complications in patients receiving different types of intracranial pressure monitoring: a retrospective study in a single center in Switzerland. *World Neurosurg.* 2016;89:641–646.
62. Winkler KM, Woernle CM, Seule M, et al. Antibiotic-impregnated versus silver-bearing external ventricular drainage catheters:

- preliminary results in a randomized controlled trial. *Neurocrit Care*. 2013;18:161–165.
63. Scholz C, Hubbe U, Deininger M, et al. Hemorrhage rates of external ventricular drain (EVD), intracranial pressure gauge (ICP) or combined EVD and ICP gauge placement within 48 h of endovascular coil embolization of cerebral aneurysms. *Clin Neurol Neurosurg*. 2013;115:1399–1402.
  64. Yuan X, Zhao H, Zhao C, et al. Duret hemorrhage after lumbar drainage. *J Craniofac Surg*. 2014;25:1551–1552.
  65. Ko JK, Cha SH, Choi BK, et al. Hemorrhage rates associated with two methods of ventriculostomy: external ventricular drainage vs. ventriculoperitoneal shunt procedure. *Neurol Med Chir (Tokyo)*. 2014;54:545–551.
  66. Miller C, Tummala RP. Risk factors for hemorrhage associated with external ventricular drain placement and removal. *J Neurosurg*. 2017;126:289–297.
  67. Weaver KD, Wiseman DB, Farber M, et al. Complications of lumbar drainage after thoracoabdominal aortic aneurysm repair. *J Vasc Surg*. 2001;34:623–627.
  68. Kwon YM, Jang SH. Neural injury by frontal approach of external ventricular drainage in stroke patients. *Int J Neurosci*. 2015;125:742–746.
  69. Kitchen WJ, Singh N, Hulme S, et al. External ventricular drain infection: improved technique can reduce infection rates. *Br J Neurosurg*. 2011;25:632–635.
  70. Liang H, Zhang L, Gao A, et al. Risk factors for infections related to lumbar drainage in spontaneous subarachnoid hemorrhage. *Neurocrit Care*. 2016;25:243–249.
  71. Scheithauer S, Burgel U, Bickenbach J, et al. External ventricular and lumbar drainage-associated meningoventriculitis: prospective analysis of time-dependent infection rates and risk factor analysis. *Infection*. 2010;38:205–209.
  72. Cheung AT, Pochettino A, Guvakov DV, et al. Safety of lumbar drains in thoracic aortic operations performed with extracorporeal circulation. *Ann Thorac Surg*. 2003;76:1190–1196. Discussion 1196–1197.
  73. Estrera AL, Sheinbaum R, Miller CC, et al. Cerebrospinal fluid drainage during thoracic aortic repair: safety and current management. *Ann Thorac Surg*. 2009;88:9–15. Discussion 15.
  74. Grady RE, Horlocker TT, Brown RD, et al. Neurologic complications after placement of cerebrospinal fluid drainage catheters and needles in anesthetized patients: implications for regional anesthesia. Mayo Perioperative Outcomes Group. *Anesth Analg*. 1999;88:388–392.
  75. Rafiq MF, Ahmed N, Ali S. Effect of tunnel length on infection rate in patients with external ventricular drain. *J Ayub Med Coll Abbottabad*. 2011;23:106–107.
  76. Chai FY, Farizal F, Jegan T. Coma due to malplaced external ventricular drain. *Turk Neurosurg*. 2013;23:561–563.
  77. Fargen KM, Hoh BL, Neal D, et al. The burden and risk factors of ventriculostomy occlusion in a high-volume cerebrovascular practice: results of an ongoing prospective database. *J Neurosurg*. 2016;124:1805–1812.
  78. Ngo QN, Ranger A, Singh RN, et al. External ventricular drains in pediatric patients. *Pediatr Crit Care Med*. 2009;10:346–351.
  79. Acikbas SC, Akyuz M, Kazan S, et al. Complications of closed continuous lumbar drainage of cerebrospinal fluid. *Acta Neurochir (Wien)*. 2002;144:475–480.
  80. Cohen-Gadol AA. Remote contralateral intraparenchymal hemorrhage after overdrainage of a chronic subdural hematoma. *Int J Surg Case Rep*. 2013;4:834–836.
  81. Niimura M, Takai K, Taniguchi M. Postoperative epidural haematomas associated with hydrocephalus caused by intraoperative overdrainage of cerebrospinal fluid: two case reports with a literature review of 19 cases. *BMJ Case Rep*. 2015;2015.
  82. Salunke P, Savardekar A, Chhabra R, et al. Subdural collections complicating third ventriculostomy: over-drainage or failure of ventriculostomy? *Neurol India*. 2012;60:254–255.
  83. Jeong YB, Choi WJ, Han SH, et al. Cerebral epidural hematoma following cerebrospinal fluid drainage during thoracoabdominal aortic repair. *Acta Anaesthesiol Scand*. 2009;53:1221–1222.
  84. Sakowitz OW, Raabe A, Vucak D, et al. Contemporary management of aneurysmal subarachnoid hemorrhage in Germany: results of a survey among 100 neurosurgical departments. *Neurosurgery*. 2006;58:137–145. Discussion 137–145.
  85. Hirono S, Kawauchi D, Higuchi Y, et al. Life-threatening intracranial hypotension after skull base surgery with lumbar drainage. *J Neurol Surg Rep*. 2015;76:e83–e86.
  86. Samadani U, Huang JH, Baranov D, et al. Intracranial hypotension after intraoperative lumbar cerebrospinal fluid drainage. *Neurosurgery*. 2003;52:148–151. Discussion 151–142.
  87. Hulou MM, Abd-El-Barr MM, Gormley WB, et al. The frequency and severity of intracranial hypotension post-intraoperative lumbar drainage using a Tuohy needle and the traditional needle. *Br J Neurosurg*. 2016;30:438–443.
  88. Leyvi G, Ramachandran S, Wasnick JD, et al. Case 3—2005 risk and benefits of cerebrospinal fluid drainage during thoracoabdominal aortic aneurysm surgery. *J Cardiothorac Vasc Anesth*. 2005;19:392–399.
  89. Estrera AL, Miller CC III, Huynh TT, et al. Preoperative and operative predictors of delayed neurologic deficit following repair of thoracoabdominal aortic aneurysm. *J Thorac Cardiovasc Surg*. 2003;126:1288–1294.
  90. Matsuda H, Ogino H, Fukuda T, et al. Multidisciplinary approach to prevent spinal cord ischemia after thoracic endovascular aneurysm repair for distal descending aorta. *Ann Thorac Surg*. 2010;90:561–565.
  91. Murakami H, Yoshida K, Hino Y, et al. Complications of cerebrospinal fluid drainage in thoracoabdominal aortic aneurysm repair. *J Vasc Surg*. 2004;39:243–245.
  92. Wang QP, Zhou ZM, You C. Paradoxical herniation caused by cerebrospinal fluid drainage after decompressive craniectomy. *Neurol India*. 2014;62:79–80.
  93. Saito K, Inamasu J, Kuramae T, et al. Tension pneumocephalus as a complication of lumbar drainage for cerebral aneurysm surgery—case report. *Neurol Med Chir (Tokyo)*. 2009;49:252–254.
  94. Kosty J, Pukenas B, Smith M, et al. Iatrogenic vascular complications associated with external ventricular drain placement: a report of 8 cases and review of the literature. *Neurosurgery*. 2013;72(suppl Operative):ons208–ons213. Discussion ons213.
  95. Wong AI, Gao S, Bain MD, et al. Physical characteristics of catheters used for subarachnoid drainage. *J Neurointerv Surg*. 2016;8:865–867.
  96. Simmerman SR, Fahy BG. Retained fragment of a lumbar subarachnoid drain. *J Neurosurg Anesthesiol*. 1997;9:159–161.
  97. Olivar H, Bramhall JS, Rozet I, et al. Subarachnoid lumbar drains: a case series of fractured catheters and a near miss. *Can J Anaesth*. 2007;54:829–834.
  98. Tiefenthaler W, Tschupik K, Hohlieder M, et al. Accidental intracerebroventricular injection of anaesthetic drugs during induction of general anaesthesia. *Anaesthesia*. 2006;61:1208–1210.
  99. Howell S, Driver RP Jr. Unintentional intracerebroventricular administration of etomidate and rocuronium. *Anesth Analg*. 2008;106:520–522. Table of contents.
  100. Ting HY, Tsui BC. Reversal of high spinal anesthesia with cerebrospinal lavage after inadvertent intrathecal injection of local anesthetic in an obstetric patient. *Can J Anaesth*. 2014;61:1004–1007.
  101. Makar G, Al-Zubaidi M, Amar S, et al. Successful large-volume cerebrospinal fluid aspiration for an accidental overdose of intrathecal cytarabine. *Med Oncol*. 2013;30:525.
  102. Singh S, Rejai S, Antongiorgi Z, et al. Misconnections in the critically ill: injection of high-dose gadolinium into an external ventricular drain. *A A Case Rep*. 2016;6:121–123.
  103. Pongudom S, Chinthammitr Y. Inadvertent intrathecal vincristine administration: report of a fatal case despite cerebrospinal fluid lavage and a review of the literature. *J Med Assoc Thai*. 2011;94(suppl 1):S258–S263.
  104. Lang EW, Weinert D, Behnke A, et al. A massive intrathecal cefazoline overdose. *Eur J Anaesthesiol*. 1999;16:204–205.
  105. Drake JM, Crawford MW. Near-miss injection of an anesthetic agent into a cerebrospinal fluid external ventricular drain: special report. *Neurosurgery*. 2005;56:E1161. Discussion E1161.

106. Riley SP, Donnelly MJ, Khatib D, et al. Post-dural puncture headaches following spinal drain placement during thoracoabdominal aortic aneurysm repair: incidence, associated risk factors, and treatment. *J Anesth*. 2015;29:544–550.
107. Maniker AH, Vaynman AY, Karimi RJ, et al. Hemorrhagic complications of external ventricular drainage. *Neurosurgery*. 2006;59(suppl 2):ONS419–ONS424. Discussion ONS424-415.
108. Sims-Williams HP, Weinberg D, Jadun CK, et al. Ventriculostomy associated haemorrhage: a complication of anti-platelet therapy during coiling. *Br J Neurosurg*. 2014;28:782–784.
109. Bauer DF, McGwin G Jr, Melton SM, et al. The relationship between INR and development of hemorrhage with placement of ventriculostomy. *J Trauma*. 2011;70:1112–1117.
110. Binz DD, Toussaint LG III, Friedman JA. Hemorrhagic complications of ventriculostomy placement: a meta-analysis. *Neurocrit Care*. 2009;10:253–256.
111. Dey M, Stadnik A, Riad F, et al. Bleeding and infection with external ventricular drainage: a systematic review in comparison with adjudicated adverse events in the ongoing Clot Lysis Evaluating Accelerated Resolution of Intraventricular Hemorrhage Phase III (CLEAR-III IHV) trial. *Neurosurgery*. 2015;76:291–300. Discussion 301.
112. Tanweer O, Boah A, Huang PP. Risks for hemorrhagic complications after placement of external ventricular drains with early chemical prophylaxis against venous thromboembolisms. *J Neurosurg*. 2013;119:1309–1313.
113. Hoh BL, Nogueira RG, Ledezma CJ, et al. Safety of heparinization for cerebral aneurysm coiling soon after external ventriculostomy drain placement. *Neurosurgery*. 2005;57:845–849. Discussion 845-849.
114. Safi HJ, Hess KR, Randel M, et al. Cerebrospinal fluid drainage and distal aortic perfusion: reducing neurologic complications in repair of thoracoabdominal aortic aneurysm types I and II. *J Vasc Surg*. 1996;23:223–228. Discussion 229.
115. Chaney MA. Intrathecal and epidural anesthesia and analgesia for cardiac surgery. *Anesth Analg*. 2006;102:45–64.
116. Bateman BT, Mhyre JM, Ehrenfeld J, et al. The risk and outcomes of epidural hematomas after perioperative and obstetric epidural catheterization: a report from the Multicenter Perioperative Outcomes Group Research Consortium. *Anesth Analg*. 2013;116:1380–1385.
117. Horlocker TT, Wedel DJ, Rowlingson JC, et al. Regional anesthesia in the patient receiving antithrombotic or thrombolytic therapy: American Society of Regional Anesthesia and Pain Medicine Evidence-Based Guidelines (Third Edition). *Reg Anesth Pain Med*. 2010;35:64–101.
118. Mayhall CG, Archer NH, Lamb VA, et al. Ventriculostomy-related infections. A prospective epidemiologic study. *N Engl J Med*. 1984;310:553–559.
119. Keong NC, Bulters DO, Richards HK, et al. The SILVER (Silver Impregnated Line Versus EVD Randomized trial): a double-blind, prospective, randomized, controlled trial of an intervention to reduce the rate of external ventricular drain infection. *Neurosurgery*. 2012;71:394–403. Discussion 403-394.
120. Shekhar H, Kalsi P, Dambatta S, et al. Do antibiotic-impregnated external ventriculostomy catheters have a low infection rate in clinical practice? A retrospective cohort study. *Br J Neurosurg*. 2016;30:64–69.
121. Atkinson RA, Fikrey L, Vail A, et al. Silver-impregnated external-ventricular-drain-related cerebrospinal fluid infections: a meta-analysis. *J Hosp Infect*. 2016;92:263–272.
122. Wang X, Dong Y, Qi XQ, et al. Clinical review: efficacy of antimicrobial-impregnated catheters in external ventricular drainage—a systematic review and meta-analysis. *Crit Care*. 2013;17:234.
123. Hepburn-Smith M, Dynkevich I, Spektor M, et al. Establishment of an external ventricular drain best practice guideline: the quest for a comprehensive, universal standard for external ventricular drain care. *J Neurosci Nurs*. 2016;48:54–65.
124. Chatzi M, Karvouniaris M, Makris D, et al. Bundle of measures for external cerebral ventricular drainage-associated ventriculitis. *Crit Care Med*. 2014;42:66–73.
125. Ciniulak Z, Aschoff A, Apedjinou A, et al. Current practice of external ventricular drainage: a survey among neurosurgical departments in Germany. *Acta Neurochir (Wien)*. 2016;158:847–853.
126. Yasuda T, Tomita T, McLone DG, et al. Measurement of cerebrospinal fluid output through external ventricular drainage in one hundred infants and children: correlation with cerebrospinal fluid production. *Pediatr Neurosurg*. 2002;36:22–28.
127. Chung DY, Leslie-Mazwi TM, Patel AB, et al. Management of external ventricular drains after subarachnoid hemorrhage: a multi-institutional survey. *Neurocrit Care*. 2016.
128. Andrews CM, Jauch EC, Hemphill JC III, et al. Emergency neurological life support: intracerebral hemorrhage. *Neurocrit Care*. 2012;17(suppl 1):S37–S46.
129. Slazinski T, Anderson TA, Cattell E, et al. Care of the patient undergoing intracranial pressure monitoring/external ventricular drainage or lumbar drainage Chicago, IL2011 [1-38]. Available from: <http://aann.org/publications/clinical-practice-guide-lines>. Accessed March 25, 2016.
130. Kawoos J, McCarron RM, Auken CR, et al. Advances in intracranial pressure monitoring and its significance in managing traumatic brain injury. *Int J Mol Sci*. 2015;16:28979–28997.
131. Hasan D, Lindsay KW, Vermeulen M. Treatment of acute hydrocephalus after subarachnoid hemorrhage with serial lumbar puncture. *Stroke*. 1991;22:190–194.
132. Kasuya H, Shimizu T, Kagawa M. The effect of continuous drainage of cerebrospinal fluid in patients with subarachnoid hemorrhage: a retrospective analysis of 108 patients. *Neurosurgery*. 1991;28:56–59.
133. Hellingman CA, van den Bergh WM, Beijer IS, et al. Risk of rebleeding after treatment of acute hydrocephalus in patients with aneurysmal subarachnoid hemorrhage. *Stroke*. 2007;38:96–99.
134. Warren J, Fromm RE Jr, Orr RA, et al. American College of Critical Care Medicine. Guidelines for the inter- and intrahospital transport of critically ill patients. *Crit Care Med*. 2004;32:256–262.
135. Farling PA, Andrews PJD, Cruikshank S, et al. Recommendations for the safe transfer of patients with brain injury. 2006. Available at: <http://www.aagbi.org/sites/default/files/braininjury.pdf>. Accessed March 25, 2016.
136. Fanara B, Manzon C, Barbot O, et al. Recommendations for the intra-hospital transport of critically ill patients. *Crit Care*. 2010;14:R87.
137. Quenot JP, Milesi C, Cravoisy A, et al. Intrahospital transport of critically ill patients (excluding newborns) recommendations of the Societe de Reanimation de Langue Francaise (SRLF), the Societe Francaise d'Anesthesie et de Reanimation (SFAR), and the Societe Francaise de Medecine d'Urgence (SFMU). *Ann Intensive Care*. 2012;2:1.
138. Australasian College for Emergency Medicine (ACEM), Australian and New Zealand College of Anaesthetists (ANZCA), College of Intensive Care Medicine of Australia and New Zealand (CICM). Guidelines for transport of critically ill patients. 2015. Available at: <http://www.anzca.edu.au/resources/professional-documents/pdfs/ps52-2015-guidelines-for-transport-of-critically-ill-patients.pdf>. Accessed March 25, 2016.
139. Kalisch BJ, Kalisch PA, Burns SM, et al. Intrahospital transport of neuro ICU patients. *J Neurosci Nurs*. 1995;27:69–77.
140. Lahner D, Nikolic A, Marhofer P, et al. Incidence of complications in intrahospital transport of critically ill patients—experience in an Austrian university hospital. *Wien Klin Wochenschr*. 2007;119:412–416.
141. Papson JP, Russell KL, Taylor DM. Unexpected events during the intrahospital transport of critically ill patients. *Acad Emerg Med*. 2007;14:574–577.
142. Doring BL, Kerr ME, Lovasik DA, et al. Factors that contribute to complications during intrahospital transport of the critically ill. *J Neurosci Nurs*. 1999;31:80–86.
143. Andrews PJ, Piper IR, Dearden NM, et al. Secondary insults during intrahospital transport of head-injured patients. *Lancet*. 1990;335:327–330.

144. Picetti E, Antonini MV, Lucchetti MC, et al. Intra-hospital transport of brain-injured patients: a prospective, observational study. *Neurocrit Care*. 2013;18:298–304.
145. Kleffmann J, Pahl R, Deinsberger W, et al. Intracranial pressure changes during intrahospital transports of neurocritically ill patients. *Neurocrit Care*. 2016;25:440–445.
146. Chaikittisilpa N, Lele AV, Lyons VH, et al. Risks of routinely clamping external ventricular drains for intrahospital transport in neurocritically ill cerebrovascular patients. *Neurocrit Care*. 2016. [Epub ahead of print].
147. Kosty JA, Leroux PD, Levine J, et al. Brief report: a comparison of clinical and research practices in measuring cerebral perfusion pressure: a literature review and practitioner survey. *Anesth Analg*. 2013;117:694–698.
148. Rosner MJ, Coley IB. Cerebral perfusion pressure, intracranial pressure, and head elevation. *J Neurosurg*. 1986;65:636–641.
149. Bisnaire D, Robinson L. Accuracy of levelling intraventricular collection drainage systems. *J Neurosci Nurs*. 1997;29:261–268.
150. Muralidharan R. External ventricular drains: management and complications. *Surg Neurol Int*. 2015;6(suppl 6):S271–S274.
151. Czosnyka M, Pickard JD. Monitoring and interpretation of intracranial pressure. *J Neurol Neurosurg Psychiatry*. 2004;75:813–821.
152. Ghajar J. Intracranial pressure monitoring techniques. *New Horiz*. 1995;3:395–399.
153. Raabe A, Stockel R, Hohrein D, et al. An avoidable methodological failure in intracranial pressure monitoring using fiberoptic or solid state devices. *Acta Neurochir Suppl*. 1998;71:59–61.
154. Raabe A, Stockel R, Hohrein D, et al. Reliability of intraventricular pressure measurement with fiberoptic or solid-state transducers: avoidance of a methodological error. *Neurosurgery*. 1998;42:74–79. Discussion 79.
155. Mayer SA, Chong JY. Critical care management of increased intracranial pressure. *J Intensive Care Med*. 2002;17:55–67.
156. Littlejohns LR, Bader MK. American Association of Critical-Care Nurses., & American Association of Neuroscience Nurses. *AACN-AANN Protocols for Practice*. Sudbury, MA: Jones and Bartlett Publishers; 2009.
157. Vender J, Waller J, Dhandapani K, et al. An evaluation and comparison of intraventricular, intraparenchymal, and fluid-coupled techniques for intracranial pressure monitoring in patients with severe traumatic brain injury. *J Clin Monit Comput*. 2011;25:231–236.
158. Czosnyka M, Czosnyka ZH, Richards HK, et al. Hydrodynamic properties of extraventricular drainage systems. *Neurosurgery*. 2003;52:619–623. Discussion 623.
159. Woodward S, Addison C, Shah S, et al. Benchmarking best practice for external ventricular drainage. *Br J Nurs*. 2002;11:47–53.
160. Mavrocordatos P, Bissonnette B, Ravussin P. Effects of neck position and head elevation on intracranial pressure in anaesthetized neurosurgical patients: preliminary results. *J Neurosurg Anesthesiol*. 2000;12:10–14.
161. Fan JY. Effect of backrest position on intracranial pressure and cerebral perfusion pressure in individuals with brain injury: a systematic review. *J Neurosci Nurs*. 2004;36:278–288.
162. Ng I, Lim J, Wong HB. Effects of head posture on cerebral hemodynamics: its influences on intracranial pressure, cerebral perfusion pressure, and cerebral oxygenation. *Neurosurgery*. 2004;54:593–597. Discussion 598.
163. Muraskin SI, Roy RC, Petrozza PH. Overdrainage of cerebrospinal fluid during central venous catheter exchange in a patient with an external ventricular drain. *Anesth Analg*. 2007;105:1519–1520.
164. Magnaes B. Body position and cerebrospinal fluid pressure. Part 1: clinical studies on the effect of rapid postural changes. *J Neurosurg*. 1976;44:687–697.
165. Wilkinson HA, Yarzelski J, Wilkinson EC, et al. Erroneous measurement of intracranial pressure caused by simultaneous ventricular drainage: a hydrodynamic model study. *Neurosurgery*. 1989;24:348–354.
166. Birch AA, Eynon CA, Schley D. Erroneous intracranial pressure measurements from simultaneous pressure monitoring and ventricular drainage catheters. *Neurocrit Care*. 2006;5:51–54.
167. Soehle M, Chatfield DA, Czosnyka M, et al. Predictive value of initial clinical status, intracranial pressure and transcranial Doppler pulsatility after subarachnoid haemorrhage. *Acta Neurochir (Wien)*. 2007;149:575–583.
168. Sunderland NE, Villanueva NE, Pazuchanics SJ. External ventricular catheters: is it appropriate to use an open/monitor position to adequately trend intracranial pressure in a neuroscience critical care environment? *J Neurosci Nurs*. 2016;48:274–277.
169. Olson DM, Zomorodi M, Britz GW, et al. Continuous cerebral spinal fluid drainage associated with complications in patients admitted with subarachnoid hemorrhage. *J Neurosurg*. 2013;119:974–980.
170. Nwachuku EL, Puccio AM, Fetzick A, et al. Intermittent versus continuous cerebrospinal fluid drainage management in adult severe traumatic brain injury: assessment of intracranial pressure burden. *Neurocrit Care*. 2014;20:49–53.
171. Amato A, Britz GW, James ML, et al. An observational pilot study of CSF diversion in subarachnoid haemorrhage. *Nurs Crit Care*. 2011;16:252–260.
172. Kim GS, Amato A, James ML, et al. Continuous and intermittent CSF diversion after subarachnoid hemorrhage: a pilot study. *Neurocrit Care*. 2011;14:68–72.
173. Great Ormond Street Hospital for Children. External ventricular drainage. 2015. Available at: <http://www.gosh.nhs.uk/health-professionals/clinical-guidelines/external-ventricular-drainage>. Accessed March 21, 2016.
174. The Royal Children's Hospital Melbourne. External ventricular drains and intracranial pressure monitoring. 2016. Available at: [http://www.rch.org.au/rchcpg/hospital\\_clinical\\_guideline\\_index/External\\_Ventricular\\_Drains\\_and\\_Intracranial\\_Pressure\\_Monitoring/](http://www.rch.org.au/rchcpg/hospital_clinical_guideline_index/External_Ventricular_Drains_and_Intracranial_Pressure_Monitoring/). Accessed March 21, 2016.
175. Flint AC, Rao VA, Renda NC, et al. A simple protocol to prevent external ventricular drain infections. *Neurosurgery*. 2013;72:993–999. Discussion 999.
176. Kirkness CJ, Mitchell PH, Burr RL, et al. Intracranial pressure waveform analysis: clinical and research implications. *J Neurosci Nurs*. 2000;32:271–277.
177. Kocan MJ. Ask the experts. *Crit Care Nurse*. 2002;22:70–73.
178. Camacho EF, Boszczowski I, Freire MP, et al. Impact of an educational intervention implanted in a neurological intensive care unit on rates of infection related to external ventricular drains. *PLoS One*. 2013;8:e50708.
179. Leverstein-van Hall MA, Hopmans TE, van der Sprenkel JW, et al. A bundle approach to reduce the incidence of external ventricular and lumbar drain-related infections. *J Neurosurg*. 2010;112:345–353.
180. Civelek E, Cansever T, Karasu A, et al. Chronic subdural hematoma after endoscopic third ventriculostomy: case report. *Turk Neurosurg*. 2007;17:289–293.
181. Fountas KN, Kapsalaki EZ, Machinis T, et al. Review of the literature regarding the relationship of rebleeding and external ventricular drainage in patients with subarachnoid hemorrhage of aneurysmal origin. *Neurosurg Rev*. 2006;29:14–18. Discussion 19–20.
182. Wang K, Liu Z, Chen X, et al. Clinical characteristics and outcomes of patients with cerebral herniation during continuous lumbar drainage. *Turk Neurosurg*. 2013;23:653–657.
183. Francel PC, Persing JA, Cantrell RW, et al. Neurological deterioration after lumbar cerebrospinal fluid drainage. *J Craniofac Surg*. 1992;3:145–148.
184. Sugrue PA, Hsieh PC, Getch CC, et al. Acute symptomatic cerebellar tonsillar herniation following intraoperative lumbar drainage. *J Neurosurg*. 2009;110:800–803.
185. Bloch J, Regli L. Brain stem and cerebellar dysfunction after lumbar spinal fluid drainage: case report. *J Neurol Neurosurg Psychiatry*. 2003;74:992–994.
186. Dagnew E, van Loveren HR, Tew JM Jr. Acute foramen magnum syndrome caused by an acquired Chiari malformation after lumbar drainage of cerebrospinal fluid: report of three cases. *Neurosurgery*. 2002;51:823–828. Discussion 828–829.
187. Manley GT, Dillon W. Acute posterior fossa syndrome following lumbar drainage for treatment of suboccipital pseudomeningocele. Report of three cases. *J Neurosurg*. 2000;92:469–474.

188. Borire AA, Hughes AR, Lueck CJ. Tonsillar herniation after lumbar puncture in idiopathic intracranial hypertension. *J Neuroophthalmol*. 2015;35:293–295.
189. Komotar RJ, Mocco J, Ransom ER, et al. Herniation secondary to critical postcraniotomy cerebrospinal fluid hypovolemia. *Neurosurgery*. 2005;57:286–292. Discussion 286-292.
190. Kawahara I, Tsutsumi K, Matsunaga Y, et al. Early awareness of cerebrospinal fluid hypovolemia after craniotomy for microsurgical aneurysmal clipping. *Acta Neurochir (Wien)*. 2013;155:1543–1548.
191. Fields JD, Lansberg MG, Skirboll SL, et al. “Paradoxical” transtentorial herniation due to CSF drainage in the presence of a hemispherectomy. *Neurology*. 2006;67:1513–1514.
192. Zhao J, Li G, Zhang Y, et al. Sinking skin flap syndrome and paradoxical herniation secondary to lumbar drainage. *Clin Neurol Neurosurg*. 2015;133:6–10.
193. Tan VE, Liew D. A case of chronic subdural hematoma following lumbar drainage for the management of iatrogenic cerebrospinal fluid rhinorrhea: pitfalls and lessons. *Ear Nose Throat J*. 2013;92:513–515.
194. Bien AG, Bowdino B, Moore G, et al. Utilization of preoperative cerebrospinal fluid drain in skull base surgery. *Skull Base*. 2007;17:133–139.
195. Etz CD, Weigang E, Hartert M, et al. Contemporary spinal cord protection during thoracic and thoracoabdominal aortic surgery and endovascular aortic repair: a position paper of the vascular domain of the European Association for Cardio-Thoracic Surgery. *Eur J Cardiothorac Surg*. 2015;47:943–957.
196. Khan NR, Smalley Z, Nesvick CL, et al. The use of lumbar drains in preventing spinal cord injury following thoracoabdominal aortic aneurysm repair: an updated systematic review and meta-analysis. *J Neurosurg Spine*. 2016;25:383–393.
197. Priebe HJ. Aneurysmal subarachnoid haemorrhage and the anaesthetist. *Br J Anaesth*. 2007;99:102–118.
198. Antunes P, Perdigao M. The use of intrathecal fluorescein in cerebrospinal fluid leak repair: management from an anesthesiologist’s point-of-view. *Acta Anaesthesiol Scand*. 2016;60:1323–1327.
199. Jacob AK, Dilger JA, Hebl JR. Status epilepticus and intrathecal fluorescein: anesthesia providers beware. *Anesth Analg*. 2008;107:229–231.
200. Evans JM, Baker GR, Berta W, et al. A cognitive perspective on health systems integration: results of a Canadian Delphi study. *BMC Health Serv Res*. 2014;14:222.
201. Petrosioniak A, Hicks CM. Beyond crisis resource management: new frontiers in human factors training for acute care medicine. *Curr Opin Anaesthesiol*. 2013;26:699–706.
202. Langan-Fox J, Code S, Langfield-Smith K. Team mental models: techniques, methods, and analytic approaches. *Hum Factors*. 2000;42:242–271.
203. American Society of Anesthesiologists. Standards & guidelines. Guidelines for patient care in anesthesiology. 2011. Available at: <https://www.asahq.org/quality-and-practice-management/standards-and-guidelines>. Accessed March 27, 2016.
204. American Society of Anesthesiologists. Standards & guidelines. Standards for basic anesthetic monitoring. 2015. Available at: <https://www.asahq.org/quality-and-practice-management/standards-and-guidelines>. Accessed March 27, 2016.
205. The American Board of Anesthesiology. Primary certification in anesthesiology. 2015. Available at: <http://www.theaba.org/PDFs/BASIC-Exam/Basic-and-Advanced-ContentOutline>. Accessed March 27, 2016.
206. Pope W. External ventriculostomy: a practical application for the acute care nurse. *J Neurosci Nurs*. 1998;30:185–190.
207. Thompson HJ. Managing patients with lumbar drainage devices. *Crit Care Nurse*. 2000;20:59–68.
208. Center for Professional Practice of Nursing. Assembly and management of external ventricular drain (EVD). 2016. Available at: [http://www.ucdmc.ucdavis.edu/cppn/resources/clinical\\_skills\\_refresher/evd/index.html](http://www.ucdmc.ucdavis.edu/cppn/resources/clinical_skills_refresher/evd/index.html). Accessed March 21, 2016.