

## RESEARCH ARTICLE

# Comparison of different methods to assess alveolar cleft defects in cone beam CT images

<sup>1</sup>Gabriella Lopes de Rezende Barbosa, <sup>2</sup>Jeyhan S Wood, <sup>3</sup>Luiz A Pimenta, <sup>1</sup>Solange Maria de Almeida and <sup>4</sup>Donald A Tyndall

<sup>1</sup>Department of Oral Diagnosis, Division of Oral Radiology, Piracicaba Dental School, University of Campinas, Piracicaba, São Paulo, Brazil; <sup>2</sup>Division of Plastic and Reconstructive Surgery, School of Medicine, University of North Carolina at Chapel Hill, Chapel Hill, NC, USA; <sup>3</sup>Department of Dental Ecology, School of Dentistry, University of North Carolina at Chapel Hill, Chapel Hill, NC, USA; <sup>4</sup>Department of Diagnostic Sciences, School of Dentistry, University of North Carolina at Chapel Hill, Chapel Hill, NC, USA

**Objectives:** This study aimed to evaluate the accuracy of three different methods for assessing the volume of cleft defects in CBCT images. The influence of field of view (FOV) and voxel sizes was also assessed.

**Methods:** Using three radio-opaque plastic skulls, unilateral defects were created to mimic alveolar clefts and were filled with wax following the contralateral side contours. They were scanned in a CBCT unit using four different acquisition protocols, varying FOV and voxel sizes. Using three different methods, the defect/wax volume was evaluated on the images by defining: (1) the width, height and facial-palatal length of the defect in maximum intensity projection; (2) the areas of the defect on axial slices; and (3) the threshold and segmentation of the region of interest. The values obtained from each method using different acquisition protocols were compared with the real volume of the wax (gold standard) using ANOVA and Tukey's test.

**Results:** Methods 2 and 3 did not differ from the gold standard ( $p > 0.05$ ). Conversely, Method 1 presented statistically significant overestimated values ( $p < 0.01$ ). No differences were found among the different FOV and voxel sizes ( $p > 0.05$ ).

**Conclusions:** CBCT volumes proved reliable for the volumetric assessment of alveolar cleft defects, when using Methods 2 and 3 regardless of FOV and voxel sizes. It may be possible to improve surgical planning and outcomes by knowing the exact volume of grafting material needed prior to the surgical intervention.

*Dentomaxillofacial Radiology* (2016) **45**, 20150332. doi: [10.1259/dmfr.20150332](https://doi.org/10.1259/dmfr.20150332)

**Cite this article as:** de Rezende Barbosa GL, Wood JS, Pimenta LA, Maria de Almeida S, Tyndall DA. Comparison of different methods to assess alveolar cleft defects in cone beam CT images. *Dentomaxillofac Radiol* 2016; **45**: 20150332.

**Keywords:** orofacial cleft; CBCT; alveolar bone grafting

## Introduction

Orofacial clefts (OFC) are congenital malformations characterized by incomplete formation of structures in the nasal and oral cavities, affecting approximately 1 child in 600 live births with considerable ethnic and geographical variations.<sup>1</sup> OFC can affect the lip,

alveolar process, and hard and soft palates. It may also vary in size, as well as occur unilaterally or bilaterally.

The alveolar involvement affects 75% of the patients with cleft lip.<sup>2</sup> This osseous defect of the alveolar process of the maxilla requires a particular osseous resolution that plays a special role in the OFC management. Alveolar bone grafting (ABG) is the method used to add bone for correction of these defects in order to restore function and form of the arch. ABG aims to stabilize

Correspondence to: Ms Gabriella Lopes de Rezende Barbosa. E-mail: [gabriellalopes@live.com](mailto:gabriellalopes@live.com)

Received 14 October 2015; revised 1 December 2015; accepted 7 December 2015

the maxillary segments,<sup>3</sup> provide bony support for adjacent teeth, close oronasal fistulae and improve support for the alar base.<sup>1</sup>

As OFC vary in size, extension and severity, patient-specific evaluation must be done during the treatment of patients with cleft. In ABG stages, the individualized pre-operative planning plays an important role in the procedure. The evaluation of the shape and measurement of the size of the bone defect is useful for an accurate pre-operative planning, which would result in a more predictable procedure, allowing a more precise assessment of the volume of grafting material needed and a successful ABG. This predictability may also result in decreased morbidity, reduction of total hospital stay and overall reduced cost.<sup>4</sup>

Initially, conventional two-dimensional (2D) radiographs were the available method for cleft assessment before surgery. As a result, most investigations relied on linear measurements and subjective evaluations of panoramic, occlusal and periapical radiographs.<sup>5-8</sup> However, the shifting from 2D to three-dimensional (3D) approach with the incorporation of CT images in the treatment of patients with clefts allowed the visualization of the defects in all three planes without superposition of structures.

Currently, CBCT is becoming increasingly more popular in dentistry and craniofacial care. This imaging modality has advantages as lower cost and lower radiation dose for the patients when compared with multislice CT (MSCT). The image quality of CBCT scans and its task-specific diagnostic ability can be influenced by several variables such as the scanning unit and different acquisition parameters, such as the field of view (FOV), tube voltage, tube amperage and voxel size.<sup>9,10</sup> Moreover, an accurate quantitative assessment of the dimensions of the defect is possible. And, for this task, few methods have been described in the literature.

Quereshy *et al*,<sup>11</sup> in 2012, proposed a volumetric estimation of the defect using anatomic landmarks: the cleft width, height and facial-palatal length. The authors indicated this process as an accurate alternative to quantitatively assess the cleft volume. Feichtinger *et al*,<sup>12</sup> 2007, also suggested a methodology for volumetric appraisal of the clefts. In this method, the areas of the defects were determined in every axial slice that comprised the cleft and posteriorly applied to a proposed formula for volume calculation. The latter one has been used in studies of patients with cleft.<sup>4,13</sup>

The above-mentioned methods use linear measurements and area calculation: one-dimensional and 2D attributes, respectively. In this sense, we hypothesized

that a 3D appraisal of the entire defect would be more accurate to determine its dimensions. Since segmentation is increasingly present in dental applications, it is now possible to isolate structures in the maxillofacial region even using CBCT images. Hereof, the segmentation of the cleft and calculation of its volume would be possible. It is worth mentioning that there is a paucity of literature regarding the influence of the acquisition parameters in this 3D evaluation. In this sense, the aim of the study was to evaluate the accuracy of three different methods for assessing the volume of cleft defects in CBCT images. In addition, the influence of FOV and voxel sizes was also assessed.

## Methods and materials

Three radio-opaque plastic skulls (3B Scientific, Hamburg, Germany) were used for the study. In order to simulate an alveolar cleft, unilateral defects varying in size and shape were created, by a plastic surgeon, on the left side of the skulls using a RemB reciprocating saw (Stryker Corporation, Kalamazoo, MI) and a thin extended blade (ref 5100-337-233, Stryker Corporation) for surgical bone removal and reshaping. The clefts were filled with utility wax following the contralateral side contours.

The skulls were then scanned in a CS9300 CBCT unit (Carestream Dental LLC, Atlanta, GA) operating at 85 kVp and 4 mA. Four different acquisition protocols (Table 1) were used, varying the FOV and voxel sizes: (1) 17 × 11 cm FOV, 0.25 mm voxel; (2) 17 × 11 cm FOV, 0.5 mm voxel; (3) 17 × 13.5 cm FOV, 0.3 mm voxel; and (4) 17 × 13.5 cm FOV, 0.5 mm voxel.

The 12 resultant CBCT volumes (3 skulls × 4 protocols) were saved in DICOM files. The assessments were performed in a secluded room with dim light by an oral and maxillofacial radiologist with experience in tomographic appraisal and cleft management. Three different methods were used to evaluate the volume of the cleft/wax in the images:

- (1) The first one, proposed by Quereshy *et al*, 2012, was performed using *inVivo* software (Anatomage, San Jose, CA). Initially, the 3D reconstruction in maximum intensity projection was created. Using landmarks, linear measurements corresponding to the cleft width, height and facial-palatal length were collected. These values were used to calculate the estimated volume of the defect (Figure 1).

**Table 1** Imaging protocols used in the research

Protocol	FOV (cm)	Voxel (mm)	kVp	mA	Time (s)	DAP (mGy cm <sup>2</sup> )
1	17 × 11	0.25	85	4	6.4	770
2	17 × 11	0.50	85	4	6.4	770
3	17 × 13.5	0.30	85	4	11.3	1359
4	17 × 13.5	0.50	85	4	11.3	1359

DAP, dose–area product; FOV, field of view.

- (2) The second method, first described by Feichtinger *et al*, 2007, was also executed using inVivo software (Anatomage). In this technique, the defects were outlined on each axial slice and the area was automatically given. After determination of the area in every slice that comprised the cleft, the volume was calculated using the following formula:  $\text{Volume} = [A1 \times S] + [A2 \times S] + \dots + [An \times S]$  (A, area; S, thickness of the slice; and  $n$ , number of slices) (Figure 2).
- (3) The third method consisted of a 3D evaluation using Mimics® software (v. 16.0, Materialise Medical, Leuven, Belgium). For this, the threshold comprising the region of interest (cleft/wax) was defined. The volumetric region of interest was cropped to comprise only the cleft for posterior segmentation. After threshold selection, 3D editing was used to obtain refined surfaces of the segmentation, resulting in a volumetric region of interest that was rendered into a shaded surface mesh, and the segmented volume was calculated (Figure 3).

In order to compare the methods, the calculation of the real volume of the wax was selected as the gold standard of the study. For this assessment, the skull was immersed in warm water and the entire wax was carefully removed using a dental floss. Next, a graduated cylinder was filled with water up to a reference line. The entire wax model was then submerged into the cylinder and the new volume occupied by the water was delimited. The real volume was measured using Archimedes' principle of water displacement. This analysis was performed twice for each wax model by one well-trained evaluator using a digital caliper. After a month of interval, the evaluations of all CBCT images were repeated to evaluate intra-observer reliability.

After data collection, the values obtained from each method using different acquisition protocols were compared with the real volume of the wax using two-way ANOVA and Tukey's test, using BioEstat for Windows (v. 5.0; BioEstat, Belém, PA, Brazil). For intra-observer analysis, Pearson's correlation coefficient was performed using SigmaStat® for Windows (v. 3.5; Systat Software Inc., Erkrath, Germany). The level of significance was set at  $p < 0.05$ . The values for agreement evaluation were interpreted as poor (0.00–0.20), fair (0.21–0.40),

moderate (0.41–0.60), substantial (0.61–0.80) or almost perfect (0.81+).

## Results

The final sample of the study consisted of 12 CBCT volumes of 3 skulls with simulated unilateral alveolar defects scanned under 4 different protocols each, varying the FOV and voxel sizes.

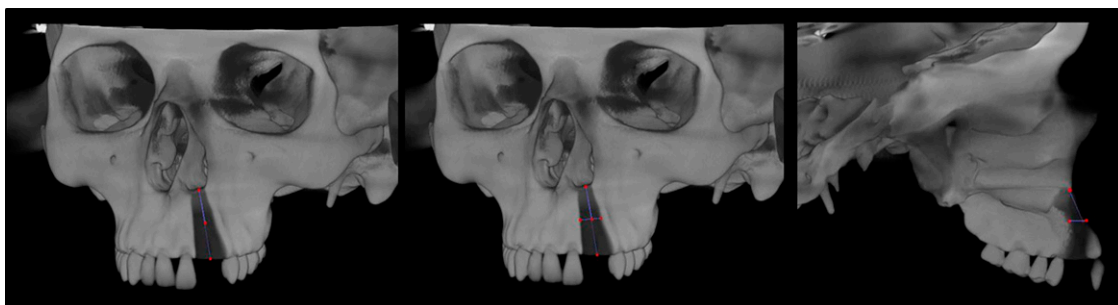
Intra-observer values indicated almost perfect agreement for all methods (Method 1 : 0.98, Method 2 : 0.99 and Method 3 : 0.98).

The overall values of the volumetric measurements for each skull and method are summarized in Table 2. In relation to the comparison among the methods for assessment of the cleft volume, Methods 2 and 3 did not differ from the gold standard ( $p > 0.05$ ). Conversely, Method 1 presented statistically significant over-estimated values ( $p < 0.01$ ).

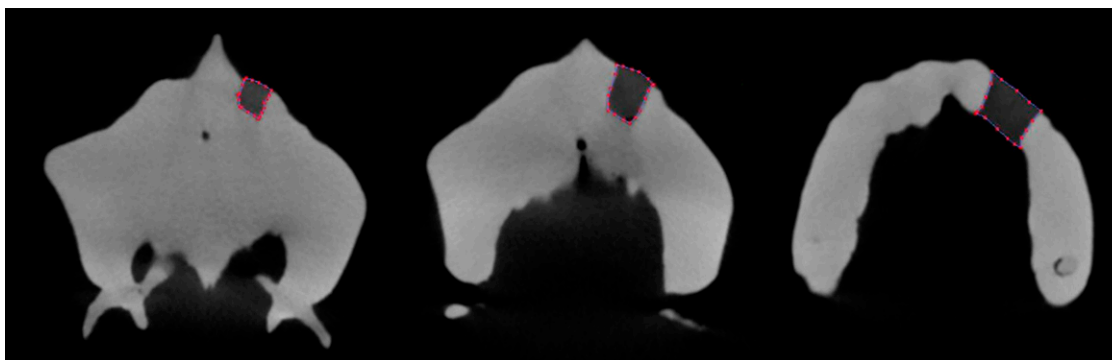
In relation to the influence of different acquisition parameters, no differences were found among the selected protocols. The variation of FOV and voxel sizes did not influence the reliability of the methods ( $p > 0.05$ ).

## Discussion

The increased utilization of faster CT examinations of lower cost allowed the increase in referrals for CBCT examinations by dental practitioners, including during pre-operative and treatment planning of the patients with cleft.<sup>14,15</sup> In addition, these examinations enable reductions up to 12.3-fold in the effective dose to which the patients are exposed when compared with MSCT, justifying the indication of CBCT examinations in cases of patients with cleft, according to SEDENTEXCT guidelines.<sup>16,17</sup> In the present study, the two different adopted FOV resulted in variation in exposure doses. The smallest FOV had a dose-area product of 770 mGy cm<sup>2</sup>, while the largest one presented an estimation of 1359 mGy cm<sup>2</sup> (Table 1). It is true that these values are estimated dose values provided by the manufacturer without weighting based on tissues. Even so, such values can provide an



**Figure 1** Method 1: measurement of the height, width and facial-palatal length of the cleft in maximum intensity projection.



**Figure 2** Method 2: measurement of the area of the cleft slice by slice on axial view.

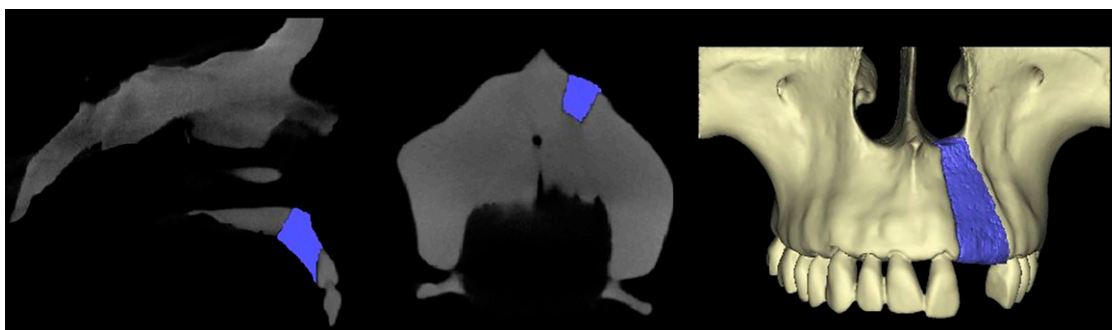
overall idea for the health practitioners and improve examination indication and selection of parameters.

Based on our results, the variation of FOV did not influence the methods' performance ( $p > 0.05$ ). For this reason, a protocol of lower dose exposure should be selected in accordance with SEDENTEXCT guidelines. Also, in several CBCT units, such as the one used in the present study, when a larger FOV is used, the scanning time increases and more likely the patient will move during image acquisition, leading to artefact movements and image degradation. In our study, only the two extended FOVs available in the CBCT unit were evaluated. They are the indicated volume for scanning patients with clefts in the Craniofacial Center where the study was conducted, as well as in many other centers. It allowed the clinical and practical application of our results, being the smallest volume size compatible with the situation and most indicated for scanning the  $17 \times 11$  cm FOV.

In relation to the voxel size, its influence on image resolution and diagnostic ability of different diseases has been the object of study of several reports.<sup>9</sup> In the evaluated CBCT unit, two options of voxel size per FOV are provided by the acquisition software. When using the  $17 \times 11$  cm FOV, 0.25 and 0.5 mm voxel sizes can be selected; and with the  $17 \times 13.5$  cm FOV, 0.3 and 0.5 mm voxel sizes can be selected. In our study, we tested all the available possibilities, and as observed for

FOV, the voxel size did not influence the performance of all three methods.

It is well known that CBCT linear measurements are accurate and do not show difference in relation to anatomical truths,<sup>18,19</sup> even when acquisition parameters are altered in a range of acceptable image quality.<sup>20,21</sup> These reports of the literature corroborate our findings that the imaging parameters did not influence the results when the methods that use linear measurements were performed (Methods 1 and 2). However, as little has been studied regarding the influence of acquisition parameters in the accuracy of 3D models for volumetric assessment, the present study aimed to evaluate the scanning possibilities in order to provide a better indication of these examinations for this purpose. The results observed disagree with the findings of da Silveira et al,<sup>22</sup> 2014, who detected that protocols with different voxel sizes in CBCT significantly changed volumetric measurements. However, these authors evaluated such measures in simulated internal root resorptions, lesions of much smaller dimensions than the defects assessed in our study. It is possible, or even probable, that voxel sizes do have an influence on accuracy in small defects. Furthermore, the lack of influence observed in Method 3 can be the foundation for further research for practitioners of craniofacial teams that aim to incorporate the segmentation in the treatment of patients with cleft. Moreover, no reports in the available literature



**Figure 3** Method 3: segmentation and volumetric measurement of the cleft.

**Table 2** Average volumes of the simulated defects according to the methods (mm<sup>3</sup>)

	<i>Gold standard</i>	<i>SD</i>	<i>Method 1</i>	<i>SD</i>	<i>Method 2</i>	<i>SD</i>	<i>Method 3</i>	<i>SD</i>
Skull 1	1384.40 A	0.10	1410.47 B	58.03	1355.57 A	37.39	1406.58 A	56.82
Skull 2	1582.80 A	0.08	2540.19 B	125.22	1471.84 A	37.89	1501.71 A	51.57
Skull 3	760.70 A	0.02	1117.70 B	46.75	680.25 A	14.61	681.33 A	28.66
Average volume	1242.6 A	428.99	1689.45 B	751.16	1169.22 A	427.43	1196.54 A	448.71

SD, standard deviation.

Means followed by different letters on the same line are significantly different ( $p < 0.05$ ).

regarding the influence of acquisition protocols in the assessment of cleft volumes were found.

Regarding the comparison of methods for volume assessment of clefts, Method 1 presented overestimated values, not being suitable for this purpose. This result disagrees with the reports of the study that suggested the method.<sup>11</sup> However, differently from our study, this previous report did not have a gold standard with known dimension for comparison. An overestimation of the necessary amount of bone for ABG would lead to unnecessary bone removal from the donor site, increasing morbidity.<sup>1</sup>

Conversely, Methods 2 and 3 proved reliable in our study. This finding is in agreement with previous studies.<sup>4,12,13</sup> Nonetheless, Feichtinger et al, 2007, and Choi et al, 2012, used images from patients who underwent ABG, and did not have a gold standard for comparison of the obtained volume and proper evaluation of the method itself. Even with the reports of Albuquerque et al, 2011, regarding the reliability of these methods using the same gold standard as our study, it was important to evaluate this methodology using CBCT images, since the technology is becoming increasingly more present in the treatment of clefts. Along with Albuquerque et al, 2011, the cited studies evaluated the method in MSCT images, which vary significantly in quality and resolution when compared with CBCT, which could lead to different results in different imaging modalities.

With reference to Method 3, no reports were found using the exact same method and software. However, studies that evaluate cleft volumes by 3D methods also found values that did not differ from a gold standard.<sup>23,24</sup> The edition of boundaries and volume of interest in previous reports was done slice by slice in the study of Amirlak et al, 2013, and applying an algorithm in the study of Kasaven et al, 2013. These studies were similar to ours in that they used simulated defects in skulls but differed from our study in the methodology

and software selected for volume assessment. The use of skulls for this type of research is a double-edged sword: the possibility of having a gold standard with accurate known dimensions at one side; on the other, the potential shortcoming of reproducing the true clinical situation. In studies similar to the present one, the evaluation of a method's reliability by a gold standard is mandatory, which makes the use of models such as skulls necessary and is also a limitation of the study at the same time.

Currently, the validation of assessments based on segmentation and 3D models of CBCT examinations is essential considering that such images were easily produced only by MSCT. The production and evaluation of these virtual models is a big advance for all types of treatment. In addition, Hamada et al,<sup>25</sup> 2005, stated that these images would be especially advantageous for pre-operative imaging of the morphology of residual alveolar clefts.

## Conclusion

CBCT volumes proved reliable for the volumetric assessment of alveolar cleft defects, when using methods of area determination in axial reconstructions and segmentation with 3D rendering of the volume, regardless of FOV and voxel sizes, in the evaluated methodology. It may be possible to improve surgical results by knowing the exact volume of grafting material needed prior to the surgery itself.

## Acknowledgments

We are grateful to CAPES Foundation (Brazil) for the scholarship support and to the University of North Carolina at Chapel Hill (NC, USA) for the technical support to the first author while she was a visiting postgraduate fellow.

## References

- Cobourne MT. *Cleft lip and palate: epidemiology, aetiology, and treatment (vol 16)*. Front oral biol. Basel: Karger; 2012.
- Bell WH, Proffit WR, White RP. Residual alveolar and palatal cleft. In: Bell WH, Proffit WR, White RP, eds. *Surgical correction of dentofacial deformities*. Philadelphia, PA: WB Saunders; 1980. pp. 1329–67.
- Turvey TA, Vig K, Moriarty J, Hoke J. Delayed bone grafting in the cleft maxilla and palate: a retrospective multidisciplinary analysis. *Am J Orthod* 1984; **86**: 244–56. doi: [10.1016/0002-9416\(84\)90376-2](https://doi.org/10.1016/0002-9416(84)90376-2)
- Choi HS, Choi HG, Kim SH, Park HJ, Shin DH, Jo DI, et al. Influence of the alveolar cleft type on preoperative estimation using 3D CT assessment for alveolar cleft. *Arch Plast Surg* 2012; **39**: 477–82. doi: [10.5999/aps.2012.39.5.477](https://doi.org/10.5999/aps.2012.39.5.477)
- Aurouze C, Moller KT, Bevis RR, Rehm K, Rudney J. The presurgical status of the alveolar cleft and success of secondary

- bone grafting. *Cleft Palate Craniofac J* 2000; **37**: 179–84. doi: [10.1597/1545-1569\(2000\)036<0179:TPSOTA>2.3.CO;2](https://doi.org/10.1597/1545-1569(2000)036<0179:TPSOTA>2.3.CO;2)
6. Bergland O, Semb G, Abyholm FE. Elimination of the residual alveolar cleft by secondary bone grafting and subsequent orthodontic treatment. *Cleft Palate J* 1986; **23**: 175–205.
  7. Helms JA, Speidel TM, Denis KL. Effect of timing on long-term clinical success of alveolar cleft bone grafts. *Am J Orthod Dentofacial Orthop* 1987; **92**: 232–40. doi: [10.1016/0889-5406\(87\)90417-3](https://doi.org/10.1016/0889-5406(87)90417-3)
  8. Long RE Jr, Spangler BE, Yow M. Cleft width and secondary alveolar bone graft success. *Cleft Palate Craniofac J* 1995; **32**: 420–7. doi: [10.1597/1545-1569\(1995\)032<0420:CWASAB>2.3.CO;2](https://doi.org/10.1597/1545-1569(1995)032<0420:CWASAB>2.3.CO;2)
  9. Spin-Neto R, Gotfredsen E, Wenzel A. Impact of voxel size variation on CBCT-based diagnostic outcome in dentistry: a systematic review. *J Digit Imaging* 2013; **26**: 813–20. doi: [10.1007/s10278-012-9562-7](https://doi.org/10.1007/s10278-012-9562-7)
  10. Kamburoğlu K, Murat S, Kolsuz E, Kurt H, Yüksel S, Paksoy C. Comparative assessment of subjective image quality of cross-sectional cone-beam computed tomography scans. *J Oral Sci* 2011; **53**: 501–8. doi: [10.2334/josnusd.53.501](https://doi.org/10.2334/josnusd.53.501)
  11. Qureshy FA, Barnum G, Demko C, Horan M, Palomo JM, Baur DA, et al. Use of cone beam computed tomography to volumetrically assess alveolar cleft defects—preliminary results. *J Oral Maxillofac Surg* 2012; **70**: 188–91. doi: [10.1016/j.joms.2011.01.027](https://doi.org/10.1016/j.joms.2011.01.027)
  12. Feichtinger M, Mossböck R, Kärcher H. Assessment of bone resorption after secondary alveolar bone grafting using three-dimensional computed tomography: a three-year study. *Cleft Palate Craniofac J* 2007; **44**: 142–8. doi: [10.1597/06-047.1](https://doi.org/10.1597/06-047.1)
  13. Albuquerque MA, Gaia BF, Cavalcanti MG. Oral cleft volumetric assessment by 3D multislice computed tomographic images. *Int J Oral Maxillofac Surg* 2011; **40**: 1280–8. doi: [10.1016/j.ijom.2011.05.015](https://doi.org/10.1016/j.ijom.2011.05.015)
  14. Mozzo P, Procacci C, Tacconi A, Martini PT, Andreis IA. A new volumetric CT machine for dental imaging based on the cone-beam technique: preliminary results. *Eur Radiol* 1998; **8**: 1558–64. doi: [10.1007/s003300050586](https://doi.org/10.1007/s003300050586)
  15. Scarfe WC, Farman AG, Sukovic P. Clinical applications of cone-beam computed tomography in dental practice. *J Can Dent Assoc* 2006; **72**: 75–80.
  16. Ludlow JB, Ivanovic M. Comparative dosimetry of dental CBCT devices and 64-slice CT for oral and maxillofacial radiology. *Oral Surg Oral Med Oral Pathol Oral Radiol Endod* 2008; **106**: 106–14. doi: [10.1016/j.tripleo.2008.03.018](https://doi.org/10.1016/j.tripleo.2008.03.018)
  17. SEDENTEXCT guidelines on CBCT for Dental and Maxillofacial Radiology. Radiation protection no. 172. 2012. Available from: <http://www.sedentext.eu/content/guidelines-cbct-dental-and-maxillofacial-radiology>
  18. Ganguly R, Ruprecht A, Vincent S, Hellstein J, Timmons S, Qian F. Accuracy of linear measurement in the Galileos cone beam computed tomography under simulated clinical conditions. *Dentomaxillofac Radiol* 2011; **40**: 299–305. doi: [10.1259/dmfr/72117593](https://doi.org/10.1259/dmfr/72117593)
  19. Stratemann SA, Huang JC, Maki K, Miller AJ, Hatcher DC. Comparison of cone beam computed tomography imaging with physical measures. *Dentomaxillofac Radiol* 2008; **37**: 80–93. doi: [10.1259/dmfr/31349994](https://doi.org/10.1259/dmfr/31349994)
  20. Torres MG, Campos PS, Segundo NP, Navarro M, Crusóe-Rebello I. Accuracy of linear measurements in cone beam computed tomography with different voxel sizes. *Implant Dent* 2012; **21**: 150–5. doi: [10.1097/ID.0b013e31824b93c](https://doi.org/10.1097/ID.0b013e31824b93c)
  21. Vasconcelos TV, Neves FS, Queiroz de Freitas D, Campos PS, Watanabe PC. Influence of the milliamperage settings on cone beam computed tomography imaging for implant planning. *Int J Oral Maxillofac Implants* 2014; **29**: 1364–8. doi: [10.11607/jomi.3524](https://doi.org/10.11607/jomi.3524)
  22. da Silveira PF, Vizzotto MB, Liedke GS, da Silveira HL, Montagner F, da Silveira HE. Detection of vertical root fractures by conventional radiographic examination and cone beam computed tomography—an *in vitro* analysis. *Dent Traumatol* 2013; **29**: 41–6. doi: [10.1111/j.1600-9657.2012.01126.x](https://doi.org/10.1111/j.1600-9657.2012.01126.x)
  23. Kasaven CP, Ivekovic S, McIntyre GT, Gillgrass T, Thomson DA, Menhinick A, et al. Validation of the volumetric measurement of a simulated maxillary alveolar bone defect using cone-beam computed tomography. *Cleft Palate Craniofac J* 2013; **50**: e115–120. doi: [10.1597/12-161](https://doi.org/10.1597/12-161)
  24. Amirlak B, Tang CJ, Becker D, Palomo JM, Gosain AK. Volumetric analysis of simulated alveolar cleft defects and bone grafts using cone beam computed tomography. *Plast Reconstr Surg* 2013; **131**: 854–9. doi: [10.1097/PRS.0b013e3182818e4f](https://doi.org/10.1097/PRS.0b013e3182818e4f)
  25. Hamada Y, Kondoh T, Noguchi K, Iino M, Isono H, Ishii H, et al. Application of limited cone beam computed tomography to clinical assessment of alveolar bone grafting: a preliminary report. *Cleft Palate Craniofac J* 2005; **42**: 128–37. doi: [10.1597/03-035.1](https://doi.org/10.1597/03-035.1)