



Aalborg Universitet

AALBORG UNIVERSITY
DENMARK

Fracture of an epicardial left ventricular lead implanted at open-heart surgery in anticipation of future need for cardiac resynchronization therapy

Larsen, Jacob Moesgaard; Bashir, Jamil; Laksman, Zachary William

Published in:
Clinical Case Reports

DOI (link to publication from Publisher):
[10.1002/ccr3.2669](https://doi.org/10.1002/ccr3.2669)

Creative Commons License
CC BY-NC-ND 4.0

Publication date:
2020

Document Version
Publisher's PDF, also known as Version of record

[Link to publication from Aalborg University](#)

Citation for published version (APA):
Larsen, J. M., Bashir, J., & Laksman, Z. W. (2020). Fracture of an epicardial left ventricular lead implanted at open-heart surgery in anticipation of future need for cardiac resynchronization therapy. *Clinical Case Reports*, 8(2), 383-386. <https://doi.org/10.1002/ccr3.2669>


General rights

Copyright and moral rights for the publications made accessible in the public portal are retained by the authors and/or other copyright owners and it is a condition of accessing publications that users recognise and abide by the legal requirements associated with these rights.

- ? Users may download and print one copy of any publication from the public portal for the purpose of private study or research.
- ? You may not further distribute the material or use it for any profit-making activity or commercial gain
- ? You may freely distribute the URL identifying the publication in the public portal ?

Take down policy

If you believe that this document breaches copyright please contact us at vbn@aub.aau.dk providing details, and we will remove access to the work immediately and investigate your claim.



Fracture of an epicardial left ventricular lead implanted at open-heart surgery in anticipation of future need for cardiac resynchronization therapy

Jacob Moesgaard Larsen^{1,2} | Jamil Bashir³ | Zachary William Laksman¹

¹Division of Cardiology, Cardiac Rhythm Services, University of British Columbia, Vancouver, BC, Canada

²Department of Cardiology, Aalborg University Hospital, Aalborg, Denmark

³Department of Cardiovascular Thoracic Surgery, University of British Columbia, Vancouver, BC, Canada

Correspondence

Jacob Moesgaard Larsen, Department of Cardiology, Aalborg University Hospital, Hobrovej 18-22, 9000 Aalborg, Denmark. Email: jaml@rn.dk

Abstract

Epicardial left ventricular leads can be implanted at open-heart surgery for cardiac resynchronization therapy. We report a 2-year-old fractured epicardial left ventricular lead detected at generator implant. It highlights the importance of good surgical implant technique and of rigorous lead evaluation for signs of impending failure at generator implant.

KEYWORDS

cardiac resynchronization therapy, epicardial lead, lead failure, open-heart surgery

1 | INTRODUCTION

Cardiac resynchronization therapy (CRT) improves survival and reduces morbidity in patients with heart failure with reduced left ventricular ejection fraction (LVEF) and significant interventricular conduction delay.^{1,2} Transvenous implantation of a left ventricular (LV) lead via the coronary sinus can be achieved in >90% of patients.² Alternatively, a transthoracic epicardial LV lead can be deployed in cases of failed transvenous implantation or de novo at the time of open-heart surgery if a future need for CRT is considered likely.³⁻⁵ However, outcome data on transthoracic epicardial LV leads and modes of failure are sparse.

This case report describes an inactive epicardial LV lead implanted at open-heart surgery in which multiple fractures caused by sternal wires were detected two years later during a CRT device implant. The contemporary literature on clinical outcomes and performance of surgically placed epicardial leads is briefly reviewed, and clinical considerations to detect

possible impending epicardial LV lead failure at later CRT device implant are suggested.

2 | CASE REPORT

In 2016, a 77-year-old man underwent open-heart surgery with aortic root replacement using a valve conduit for a stenotic bicuspid aortic valve and associated aortic root dilatation. Preoperatively, the patient had mild nonobstructive coronary artery disease, LVEF 45%, and Left Bundle Branch Block (LBBB) with QRS duration 172 ms. The cardiac surgeon implanted a lateral epicardial bipolar suture-on LV lead (Medtronic 4968-35 Capsure Epi) with the lead body exiting at the suprasternal angle and with the silicone capped header placed in the left pectoral subcutaneous tissue assuming a likely future need for CRT (Figure 1).

Two years later in 2018, the patient developed progressive clinical heart failure New York Heart Association (NYHA)

This is an open access article under the terms of the Creative Commons Attribution-NonCommercial-NoDerivs License, which permits use and distribution in any medium, provided the original work is properly cited, the use is non-commercial and no modifications or adaptations are made.

© 2020 The Authors. *Clinical Case Reports* published by John Wiley & Sons Ltd.

class III, LVEF 35%, and LBBB with QRS duration 176 ms. The patient had a class I indication for CRT.⁶ At implant, the header of the capped epicardial LV lead in the subcutaneous tissue was mobilized with electrocautery and with gentle traction, turned out to have multiple overt fractures near the level of the suprasternal notch most likely caused by shredding over the fractured sternal wires (Figures 2 and 3). Inadvertent capture of the lead body by the sternal wires at implant may have contributed to the lead damage. Hence, a transvenous LV lead was implanted instead in a posterolateral coronary sinus tributary. All three transvenous leads had excellent pacing parameters and were connected to a CRT-pacemaker in the subcutaneous pocket.

3 | DISCUSSION

The contemporary CRT implanter has a range of possible transvenous coronary sinus delivery sheath systems, and LV lead designs to overcome anatomical challenges and thereby increase the probability of a successful implant. However, in the 2018 AHA/ACC/HRS pacing guidelines, implanting an epicardial LV lead at open-heart surgery is still a class IIb indication if future CRT is considered likely.⁶ The present case report illustrates an example of what may be a rare mode of failure of an epicardial lead but highlights several key clinical issues to be considered in case a previously implanted inactive epicardial LV lead is to be used in a contemporary CRT system.

3.1 | How is the clinical response to CRT using a surgically placed epicardial LV lead versus a standard transvenous LV lead?

The response to CRT using a transvenous approach with reduced morbidity and mortality is well established.^{1,2} Optimal transvenous LV lead placement is limited by the variable coronary venous anatomy, but contemporary transvenous lead delivery systems and use of quadripolar leads yield implant success rates of up to 97% with postoperative possibility of vector optimization and multipoint pacing to optimize CRT response.⁷ The alternate option is to surgically place an epicardial LV lead. This can be performed at concomitant open-heart surgery or by less invasive video-assisted thoracoscopy and left-lateral mini-thoracotomy. There are no large randomized trials demonstrating noninferiority of CRT with a surgically placed LV leads compared to a transvenous LV lead. Two randomized trials with only 9⁸ and 22⁵ surgically placed epicardial leads did not show any difference in clinical CRT response evaluated by left ventricular remodeling, NYHA functional class and 6-minute walk test. Three small retrospective studies have demonstrated equivalent findings.^{3,4,9} Overall, limited clinical data suggest that patients

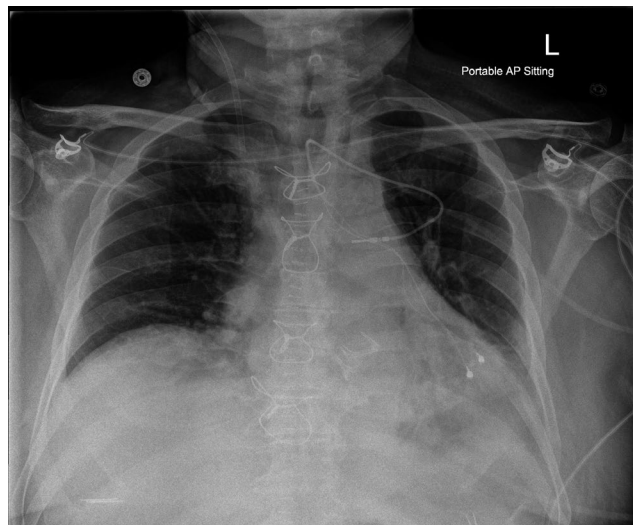


FIGURE 1 Postoperative chest X-ray after open-heart surgery in 2016 with aortic root replacement using a valve conduit and concomitant implant of a bipolar epicardial left ventricular lead with the silicone covered header placed in the subcutaneous tissue in the left pectoral area. No signs of damage to the epicardial lead at implant



FIGURE 2 Intraprocedure photo from the cardiac resynchronization therapy device implant in 2018 showing the proximal explanted fragment of the fractured epicardial lead

with epicardial and endocardial LV leads have comparable clinical response to CRT.

3.2 | What are the failure rate and modes of surgically implanted epicardial LV leads?

The reason for lead failure in the current case was most likely mechanical stress by the sternum and shredding of the lead by the fractured sternal wires which inadvertently may have tied down the lead body at implant. An equivalent failure mechanism is subclavian crush of transvenous pacing leads inadvertently caught in the costoclavicular soft tissue. This emphasizes the universal importance of the implanter of pacing leads being to be very diligent to avoid unnecessary mechanical lead stress by exerting good implant technique no matter it being transvenous or epicardial.

Data on electrical performance, failure rates, and modes of failure of surgically implanted epicardial LV leads in patients with an indication for CRT are sparse. The largest

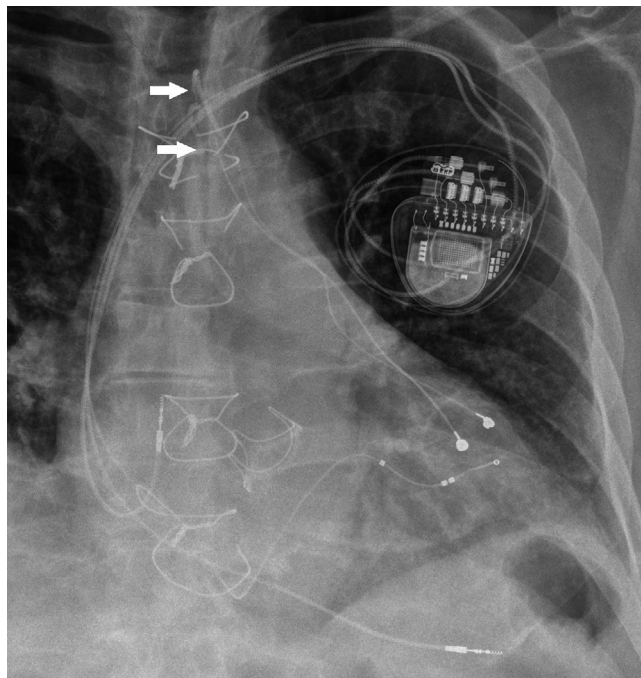


FIGURE 3 Focused postprocedure chest x-ray after the cardiac resynchronization therapy device implant in 2018 with three transvenous leads in the right atrium, right ventricle, and left ventricle via the coronary sinus, respectively. The abandoned part of the epicardial left ventricular lead was completely fractured at the suprasternal notch (superior arrow) with an isolated short extrathoracic subcutaneous fragment that also was severed from the explanted part of the lead at the level of one of the fractured sternal wires (inferior arrow)

report is a single-center study¹⁰ with 216 leads of the same kind as presented in the current case report (Medtronic 4968 Capsure Epi). They demonstrated excellent pacing thresholds, sensing, and impedance during a mean follow-up of 3 years. Two lead-related implant complications were observed, that is, permanent phrenic nerve damage and coronary artery stenosis with myocardial infarction which underline the importance of meticulous surgical implant technique. The 5-year LV lead failure rate was 1.6% with high pacing thresholds, and the 5-year device infection rate was 9.6%. A small study¹¹ with 19 mini-thoracotomy placed epicardial LV leads and 79 transvenous coronary sinus leads has demonstrated lower epicardial pacing thresholds 18 months postimplant with only 1 surgically placed lead needing repositioning. However, another small study⁸ with only 9 thoracoscopically placed epicardial leads and 12 transvenous coronary sinus leads demonstrated a contrasting finding with much higher epicardial pacing thresholds 12 months postimplant. This could be explained by challenges with the thoracoscopic implant technique, and myocardial damage at the epicardial implant site may with time result in higher pacing thresholds. A study¹² including 91 completely epicardial CRT systems

with a mean follow-up of 55 months has demonstrated a low lead failure rate of 1.5% and no infections. Similarly, a small study¹³ with 32 sutureless screw-in epicardial LV leads placed by thoracoscopy or mini-thoracoscopy has demonstrated excellent sensing, impedance, and thresholds with a mean follow-up of 2.6 years with no clinically significant differences between leads with and without steroid elusion. Overall, limited clinical data suggest that epicardial LV leads have relatively low failure rates, and good implant technique is imperative to keep these at an acceptable level.

3.3 | What should be considered by the CRT implanter when planning to utilize a previously implanted epicardial LV Lead?

There is an inherent risk of including a failing epicardial LV lead in a new CRT system as an indwelling inactive lead has no electrical track record. The present case report shows complete lead fractures of all conductors and insulation, and lead failure would therefore with certainty have been detected when connected to the device. Impending, but not overt, lead failure can be much more challenging to detect. We suggest the following steps to reduce the risk of introducing a failing epicardial LV lead to a new CRT system: *Preprocedure*: check available chest X-rays for signs of epicardial LV lead damage to insulation or conductors by using electronic image magnification with special focus on the thoracic exit point to the subcutaneous tissue; *Intraprocedure*: consider checking lead integrity with high frame rate fluoroscopy with special focus at the thoracic exit point to the subcutaneous tissue, and when testing the electrical integrity, include manual compression of the thoracic exit point of the lead while looking for lead noise and repeat impedance measurements. Furthermore, check that the position of the epicardial lead is basal posterolateral for optimal CRT and that the pacing threshold is acceptably low and without phrenic nerve stimulation. If not, consider implanting a new transvenous LV lead.

4 | CONCLUSIONS

Surgically implanted epicardial LV leads for use in CRT seem to perform well with low failure rates, but focus on good implant technique is imperative to reduce risk of lead failure. There are no large randomized trials directly comparing outcomes in CRT with bipolar surgical epicardial LV leads versus contemporary quadripolar transvenous leads with vector optimization. When possible, transvenous LV leads may, therefore, be preferable. Inactive epicardial LV leads have no electrical track record if implanted at open-heart surgery in anticipation

of future need for CRT. Meticulous visual and electrical lead evaluation is mandatory to reduce the risk of introducing an impending failing epicardial LV lead into a new CRT system.

CONFLICT OF INTEREST

None.

AUTHOR CONTRIBUTIONS

JML: drafting the initial and revised manuscript and corresponding author; JB: revision of the manuscript; ZWL: idea, conceptualization and revision of the manuscript.

ORCID

Jacob Moesgaard Larsen  <https://orcid.org/0000-0002-0574-2076>

REFERENCES

1. Cleland JGF, Daubert J-C, Erdmann E, et al. The effect of cardiac resynchronization on morbidity and mortality in heart failure. *N Engl J Med*. 2005;352:1539-1549.
2. Moss AJ, Hall WJ, Cannom DS, et al. Cardiac-resynchronization therapy for the prevention of heart-failure events. *N Engl J Med*. 2009;361:1329-1338.
3. Rickard J, Johnston DR, Price J, et al. Reverse ventricular remodeling and long-term survival in patients undergoing cardiac resynchronization with surgically versus percutaneously placed left ventricular pacing leads. *Heart Rhythm*. 2015;12:517-523.
4. Chen L, Fu H, Pretorius VG, et al. Clinical outcomes of cardiac resynchronization with epicardial left ventricular lead. *Pacing Clin Electrophysiol*. 2015;38:1201-1209.
5. van Dijk VF, Fanggiday J, Balt JC, et al. Effects of epicardial versus transvenous left ventricular lead placement on left ventricular function and cardiac perfusion in cardiac resynchronization therapy: A randomized clinical trial. *J Cardiovasc Electrophysiol*. 2017;28:917-923.
6. Writing Committee Members, Kusumoto FM, Schoenfeld MH, et al. 2018 ACC/AHA/HRS guideline on the evaluation and management of patients with bradycardia and cardiac conduction delay. *Heart Rhythm*. 2019;16:e227-e279.
7. Niazi I, Baker J, Corbisiero R, et al. Safety and efficacy of multi-point pacing in cardiac resynchronization therapy: the MultiPoint pacing trial. *JACC Clin Electrophysiol*. 2017;3:1510-1518.
8. Garikipati NV, Mittal S, Chaudhry F, et al. Comparison of endovascular versus epicardial lead placement for resynchronization therapy. *Am J Cardiol*. 2014;113:840-844.
9. Miller AL, Kramer DB, Lewis EF, Koplan B, Epstein LM, Tedrow U. Event-free survival following CRT with surgically implanted LV leads versus standard transvenous approach. *Pacing Clin Electrophysiol*. 2011;34:490-500.
10. Buiten MS, Van Der Heijden AC, Klautz RJM, Schalij MJ, Van Erven L. Epicardial leads in adult cardiac resynchronization therapy recipients: a study on lead performance, durability, and safety. *Heart Rhythm*. 2015;12:533-539.
11. Mair H, Sachweh J, Meuris B, et al. Surgical epicardial left ventricular lead versus coronary sinus lead placement in biventricular pacing. *Eur J Cardiothorac Surg*. 2005;27:235-242.
12. Romanov A, Goscinska-Bis K, Bis J, et al. Cardiac resynchronization therapy combined with coronary artery bypass grafting in ischaemic heart failure patients: Long-term results of the RESCUE study. *Eur J Cardiothorac Surg*. 2016;50:36-41.
13. Caliskan E, Fischer F, Schoenrath F, et al. Epicardial left ventricular leads via minimally invasive technique: a role of steroid eluting leads. *J Cardiothorac Surg*. 2017;12(1):95.

How to cite this article: Larsen JM, Bashir J, Laksman ZW. Fracture of an epicardial left ventricular lead implanted at open-heart surgery in anticipation of future need for cardiac resynchronization therapy. *Clin Case Rep*. 2020;8:383–386. <https://doi.org/10.1002/ccr3.2669>