



Aalborg Universitet

AALBORG UNIVERSITY  
DENMARK

## Lymphadenitis in a Greenlandic Inuit Boy after Bacillus Calmette-Guérin Vaccination

Penninga, L.; Lorentzen, A.K.; Mikkelsen, Carsten Sauer

*Published in:*  
Forum for Nordic Dermato-Venereology

*Creative Commons License*  
CC BY-NC 4.0

*Publication date:*  
2019

*Document Version*  
Publisher's PDF, also known as Version of record

[Link to publication from Aalborg University](#)

*Citation for published version (APA):*  
Penninga, L., Lorentzen, A. K., & Mikkelsen, C. S. (2019). Lymphadenitis in a Greenlandic Inuit Boy after Bacillus Calmette-Guérin Vaccination. *Forum for Nordic Dermato-Venereology*, 24(3), 102-103.  
<https://www.medicaljournals.se/forum/articles/24/3/102-103.pdf>

### General rights

Copyright and moral rights for the publications made accessible in the public portal are retained by the authors and/or other copyright owners and it is a condition of accessing publications that users recognise and abide by the legal requirements associated with these rights.

- ? Users may download and print one copy of any publication from the public portal for the purpose of private study or research.
- ? You may not further distribute the material or use it for any profit-making activity or commercial gain
- ? You may freely distribute the URL identifying the publication in the public portal ?

### Take down policy

If you believe that this document breaches copyright please contact us at [vbn@aub.aau.dk](mailto:vbn@aub.aau.dk) providing details, and we will remove access to the work immediately and investigate your claim.

## Lymphadenitis in a Greenlandic Inuit Boy after Bacillus Calmette-Guérin Vaccination

LUIT PENNINGA<sup>1</sup>, ANNE KATHRINE LORENTZEN<sup>1</sup> AND CARSTEN SAUER MIKKELSEN<sup>2</sup>

<sup>1</sup>Ilulissat Hospital, Ilulissat, Avannaar Region, Postbox 514, 3952 Ilulissat, Greenland, <sup>2</sup>Research Lab, Department of Dermatology, University of Aalborg, and Private Dermatology Practice, Brønderslev, Denmark. E-mail: LP@ctu.dk



As Greenland has an exceedingly high incidence of tuberculosis, the Bacillus Calmette-Guérin (BCG) vaccination is a part of the childhood immunization programme (1, 2). Severe complications to the BCG vaccination are very rare. One of the most well-known complications associated with BCG vaccination is lymphadenitis, which can usually be treated without sequelae (3). We report here a Greenlandic Inuit boy who developed non-suppurative lymphadenitis and was treated conservatively with good results.

### CASE REPORT

A Greenlandic Inuit boy was born at term after an uncomplicated pregnancy and normal vaginal delivery. Intracutaneous BCG vaccination was given in the left upper arm. He was discharged from the regional hospital and went home to the rural village in which the family lived. A few weeks later, the mother observed a swelling in the left armpit and contacted the hospital. A large swelling in the left axilla was found (Fig. 1). The swelling was painless, smooth, firm, and not fixed to the underlying tissue. There was no erythema or other cutaneous changes. The BCG inoculation site was without signs of infection (Fig. 2.) The child was thriving and gaining weight and did not show any signs of systemic affection. An ultrasound of the swelling did not detect any fluid. Neither biopsy nor excision was performed. After 3–4 months, the swelling decreased in size, and after 6 months it had disappeared.

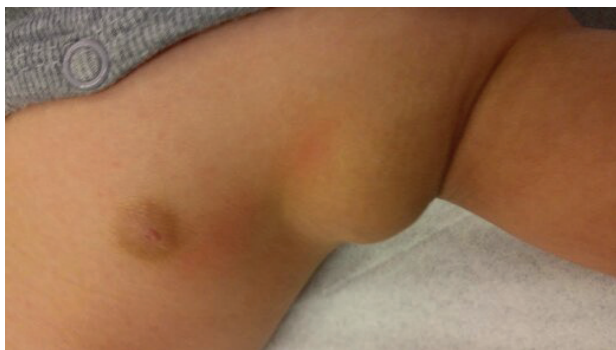

Fig. 1. Severe lymphadenitis of the axilla after Bacillus Calmette-Guérin vaccination of the ipsilateral arm.

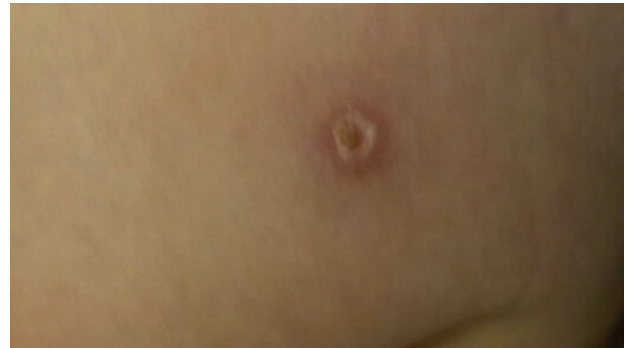


Fig. 2. No signs of infection were seen at the site of Bacillus Calmette-Guérin injection.

### DISCUSSION

In the 1950s, the population of Greenland had the highest rate of tuberculosis worldwide (1). Hence, a nationwide neonate vaccination programme with the BCG vaccination was introduced in 1955. In 1989, this intervention was phased out as tuberculosis was basically extinct in Greenland, and the vaccination programme ended in 1991 (1). From 1991 to 1997 the incidence of tuberculosis doubled and the vaccination programme was reinitiated (2). Children born between 1991 and 1997 were offered vaccination, but many failed to receive the offer or did not accept the vaccination (2). Therefore, there is a higher incidence of tuberculosis in people born between 1991 and 1997 compared to the rest of the population, and men are more often affected than women (2).

However, the incidence of tuberculosis in Greenland is declining due to better surveillance, management, and infection control. Tuberculosis is still endemic, and the BCG vaccination continues to be a part of the immunization programme in Greenland (2).

In this case report, we describe a rare complication to the BCG vaccination (3). Lymphadenitis occurs in 3/1,000 children who receive the vaccination (4). Lymphadenitis often occurs at the ipsilateral arm of the vaccination site (5). Normally, there are no signs of infection, and the patient has no fever. The lymphadenitis is characterized by isolated axillary, su-

praclavicular or cervical lymph node enlargement (5). The primary diagnostic modality is ultrasonography (5). Computed tomography can also be used, but is not recommended as it exposes the child to radiation (5).

Two forms of BCG lymphadenitis can occur; simple or non-suppurative lymphadenitis, and suppurative lymphadenitis. In non-suppurative lymphadenitis, there is no fluid collection, and the condition is best treated conservatively. Spontaneous regression usually occurs over a period of several weeks or months (3). Suppurative BCG lymphadenitis is characterized by the development of a fluid collection in the swelling, with erythema and oedema of the overlying skin. Suppurative lymphadenitis resolves through spontaneous perforation and sinus formation, followed by secondary closure of the sinus by scar tissue. Suppurative BCG lymphadenitis can be treated by aspiration with a needle to accelerate resolution and prevent spontaneous perforation and sinus formation. Surgical excision is rare and should only be applied in cases where needle aspiration has failed.

In our patient, ultrasonography showed no fluid collection, and this case of non-suppurative lymphadenitis was treated conservatively with good results.

#### REFERENCES

1. Birch E, Andersson M, Koch A, Stenz F, Søbørg B. Ten years of tuberculosis intervention in Greenland - Has it prevented cases of childhood tuberculosis? *Int J Circumpolar Health* 2014; 73. DOI:10.3402/ijch.v73.24843.
2. Søbørg C, Søbørg B, Poulsen S, Pallisgaard G, Thybo S, Bauer J. Doubling of the tuberculosis incidence in Greenland over an 8-year period (1990–1997). *Int J Tuberc Lung Dis* 2001; 5: 257–265.
3. Goraya JS, Viridi VS. Bacille Calmette-Guérin lymphadenitis. *Postgrad Med J* 2002; 78: 327–329.
4. Al-Salem AH, Kothari MR, AlHani HM, Oquaish MM, Khogeer SS, Desouky MS. Safety of intradermal Bacillus Calmette-Guerin vaccine for neonates in Eastern Saudi Arabia. *Saudi Med J* 2012; 33: 172–176.
5. Baek SO, Ko HS, Han HH. BCG vaccination-induced suppurative lymphadenitis: four signs to pay attention to. *Int Wound J* 2017; 14: 1385–1387.