

Western University  
**Scholarship@Western**

---

Medical Biophysics Publications

Medical Biophysics Department

---

11-1-2019

## Normalisation of MRI ventilation heterogeneity in severe asthma by dupilumab

Sarah Svenningsen

Ehsan Ahmed Haider

Rachel L Eddy

Grace Parraga

Parameswaran Nair

Follow this and additional works at: <https://ir.lib.uwo.ca/biophysicspub>



Part of the [Medical Biophysics Commons](#)

---

### Citation of this paper:

Svenningsen S, Haider EA, Eddy RL, et al. Normalisation of MRI ventilation heterogeneity in severe asthma by dupilumab. *Thorax* 2019;74:1087-1088.



## IMAGES IN THORAX

# Normalisation of MRI ventilation heterogeneity in severe asthma by dupilumab

Sarah Svenningsen,<sup>1,2</sup> Ehsan Ahmed Haider,<sup>3,4</sup> Rachel L Eddy,<sup>5,6</sup> Grace Parraga,<sup>5,6</sup> Parameswaran Nair<sup>1,2</sup>

► Additional material is published online only. To view, please visit the journal online (<http://dx.doi.org/10.1136/thoraxjnl-2019-213415>).

<sup>1</sup>Department of Medicine, McMaster University, Hamilton, Ontario, Canada

<sup>2</sup>Firestone Institute for Respiratory Health, St. Joseph's Healthcare, Hamilton, Ontario, Canada

<sup>3</sup>Department of Radiology, McMaster University, Hamilton, Ontario, Canada

<sup>4</sup>Department of Diagnostic Imaging, St. Joseph's Healthcare, Hamilton, Ontario, Canada

<sup>5</sup>Robarts Research Institute, Western University, London, Ontario, Canada

<sup>6</sup>Department of Medical Biophysics, Western University, London, Ontario, Canada

### Correspondence to

Dr Parameswaran Nair, Department of Medicine, McMaster University, Hamilton N6A5B7, Canada; [parames@mcmaster.ca](mailto:parames@mcmaster.ca)

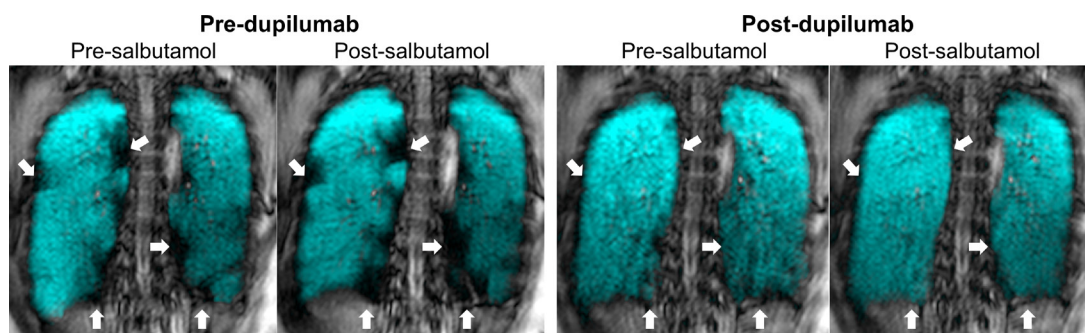
Received 1 April 2019  
Revised 17 June 2019  
Accepted 19 June 2019  
Published Online First 8 July 2019

### IMAGES IN THORAX

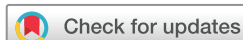Ventilation heterogeneity in asthma could be due to many reasons. Luminal obstruction due to inflammatory cells or mucus, smooth muscle constriction and airway wall thickness could all contribute individually or collectively to ventilation heterogeneity. Interleukin-4 and interleukin-13, acting through the common interleukin-4 receptor, have the potential to modulate all of these features of asthma.<sup>1</sup> Inhaled hyperpolarised gas MRI provides a way to regionally visualise and quantify the functional consequence of these features.<sup>2</sup> Dupilumab is a fully human monoclonal antibody directed against the alpha-subunit of the interleukin-4 receptor.<sup>3</sup> Here, we report a severe asthmatic who showed significant improvement and normalisation of MRI ventilation heterogeneity and associated clinical and physiological variables with dupilumab treatment, suggesting that dupilumab modulated various aspects of luminal airway obstruction.

A 39-year-old atopic woman (total serum immunoglobulin E 1009 kU/L and peripheral blood eosinophils 1200 cells/ $\mu$ L) was seen for asthma in January 2015. She had mixed obstructive and non-obstructive spirometry (forced expiratory volume in one second (FEV<sub>1</sub>) 1.42 L (44%<sub>pred</sub>), forced vital capacity (FVC) 1.72 L (44%<sub>pred</sub>) and total lung capacity (TLC) 3.78 L (71%<sub>pred</sub>), with 13% reversibility to salbutamol. Her asthma severity and symptoms (asthma control questionnaire (ACQ)

1.2) were driven by eosinophilic bronchitis (44% sputum eosinophils), airway hyperresponsiveness (42% decrease in FEV<sub>1</sub> (1.42 to 0.82 L) with 0.9% saline inhalation during a methacholine challenge) and mucus plugging (CT mucus score<sup>4</sup> 8), despite being on budesonide 200  $\mu$ g+formoterol 6  $\mu$ g three puffs two times per day, beclomethasone hydrofluoroalkane metered-dose inhaler 100  $\mu$ g four puffs two times per day and 2.5 mg prednisone. Exhaled nitric oxide (FeNO) was elevated at 47 ppb indicating increased NO synthase activity, an indirect reflection of signal transducer and activator of transcription 6 (STAT6) activation and interleukin-4 receptor signalling. She also previously had inadequate asthma control (ACQ>1.5) with omalizumab 375 mg administered subcutaneously every 4 weeks (for 6 months), mepolizumab 100 mg administered subcutaneously every 4 weeks (for 19 months) (both of which did not normalise her sputum eosinophil per cent) and reslizumab 3 mg/kg administered intravenously every 4 weeks (for 4 months) (normalised her sputum eosinophil per cent). She was then treated with dupilumab 300 mg administered subcutaneously every 2 weeks for 5 months. Her ACQ improved to 0.6 (from 1.2) and was associated with improvements in sputum eosinophilia (from 6.3% to 0% and no granules, but increased to 12.3% two weeks after last injection), airway mucus (CT mucus score<sup>4</sup> 1), hyperresponsiveness (7% decrease in FEV<sub>1</sub> (1.90 to 1.76 L) with 5%



**Figure 1** Inhaled hyperpolarised <sup>3</sup>He MRI for a patient with severe asthma who had complete normalisation of MRI ventilation heterogeneity following dupilumab 300 mg administered subcutaneously every 2 weeks for 5 months. A representative coronal slice of the <sup>3</sup>He MRI (in blue) co-registered to the <sup>1</sup>H anatomical MRI of the thorax (in grey scale) acquired pre-salbutamol and post-salbutamol before and after treatment with dupilumab. White arrows spatially identify ventilation defects (regions of the lung that are not ventilated in a single breath-hold) pre-dupilumab that responded to dupilumab (but not salbutamol) such that those regions became ventilated following treatment. Note that only a representative two-dimensional coronal slice from the posterior lung has been shown for visualisation purposes (all anterior to posterior slices are presented in the online supplementary file 1).



© Author(s) (or their employer(s)) 2019. No commercial re-use. See rights and permissions. Published by BMJ.

**To cite:** Svenningsen S, Haider EA, Eddy RL, et al. *Thorax* 2019;**74**:1087–1088.

saline inhalation during a sputum induction) and FeNO (from 27ppb to 11 ppb). These findings suggest multiple components of her airway disease were controlled by dupilumab, consistent with the drugs putative mechanism of action.

We measured the functional consequence of this response using  $^3\text{He}$  MRI (figure 1). Pre-dupilumab MRI revealed focal ventilation defects bilaterally, that were largely non-responsive to salbutamol (ventilation defect per cent: pre-salbutamol=8% and post-salbutamol=9%), a subset were spatially related to mucus plugging visualised by CT. Following 5 months of dupilumab, MRI ventilation improved such that no residual ventilation defects were observed (ventilation defect per cent: pre-salbutamol=3% and post-salbutamol=2%). Yet, spirometry continued to show severe airflow limitation with an FEV<sub>1</sub> of 1.69L (57%<sub>pred</sub>), which improved to 1.93L (65%<sub>pred</sub>) post-salbutamol.

This report suggests that MRI may be used to evaluate the functional consequence of normalising multiple contributors to airway obstruction and may contribute as an additional outcome measure to evaluate severe asthma therapeutics. By blocking both interleukin-4 and interleukin-13 signalling, dupilumab completely normalised ventilation defects and improved asthma control, suggesting that this may be a useful therapy when one component (e.g. eosinophils) is not the dominant contributor to asthma severity.

**Acknowledgements** We thank M Kjarsgaard and C Huang for patient management and assessment, and D Reese for MRI.

**Contributors** SS and PN were responsible for the study design and conceived the idea for the case report. SS and RLE were responsible for MRI data collection, analysis and interpretation. EAH was responsible for reviewing CT data sets to generate the CT mucus score and the interpretation of CT data. GP was responsible for MRI acquisition, analysis and interpretation as well as the guarantor of the integrity of the imaging data. PN was responsible for identifying and characterising the patient, clinical interpretation of the data as well as the guarantor of the integrity of the clinical data. SS prepared the first and all revised drafts of the case report. All the authors edited and reviewed the case report and approved the final version.

**Funding** The authors have not declared a specific grant for this research from any funding agency in the public, commercial or not-for-profit sectors.

**Competing interests** PN reports grants from AZ, Novartis, Teva and Sanofi; personal fees from Roche, Teva, Novartis and Knopp; and grants and personal fees from GSK, outside the submitted work.

**Patient consent for publication** Obtained.

**Provenance and peer review** Not commissioned; externally peer reviewed.

## REFERENCES

- Andrews A-L, Holloway JW, Holgate ST, *et al.* IL-4 receptor alpha is an important modulator of IL-4 and IL-13 receptor binding: implications for the development of therapeutic targets. *J Immunol* 2006;176:7456–61.
- Svenningsen S, Eddy RL, Lim HF, *et al.* Sputum Eosinophilia and Magnetic Resonance Imaging Ventilation Heterogeneity in Severe Asthma. *Am J Respir Crit Care Med* 2018;197:876–84.
- Rabe KF, Nair P, Brusselle G, *et al.* Efficacy and Safety of Dupilumab in Glucocorticoid-Dependent Severe Asthma. *N Engl J Med* 2018;378:2475–85.
- Dunican EM, Elicker BM, Gierada DS, *et al.* Mucus plugs in patients with asthma linked to eosinophilia and airflow obstruction. *J Clin Invest* 2018;128:997–1009.