



Prolonged Survival of the Patient with Head and Neck Cancer with Squamous Cell Carcinoma treated with Cetuximab: A Case Report

Pratap Kishore Das¹, and Jayanta Patowary^{2*}

¹ Apollo Cancer Institute, Indraprastha Apollo Hospitals, New Delhi, India

² Department of Medical Oncology, Apollo Cancer Institute, Indraprastha Apollo Hospitals
New Delhi, India

Abstract:

Introduction: Cetuximab, an epidermal growth factor (EGFR) inhibitor has radio sensitizing activity for locoregionally, advanced head and neck cancer (LAHNC). The drug is either used in combination with radiotherapy or in combination with other chemotherapeutic drugs.

Case Presentation: A 35-year-old male patient diagnosed with cancer of tongue at loco regional stage who had previously undergone hemiglossectomy was treated with TPF (docetaxel, cisplatin and 5-fluorouracil) as induction therapy (ICT) followed by concurrent local radiation therapy (RT) and cetuximab for 6 weeks. The first recurrence appeared 4 years after the surgery, which was treated with RT along with standard treatment with cetuximab for 6 weeks. Second recurrence was treated with cetuximab in combination with cisplatin and docetaxel. The patient survived for 8 years since he began his treatment.

Conclusion: Cetuximab in combination with RT and other chemotherapeutic drugs can offer a longer survival in patients with both recurrent, locally advanced and metastatic squamous cell carcinoma of head and neck cancer.

Keywords: Squamous cell carcinoma of head and neck cancer (SCCHN), Cetuximab, Epidermal growth factor (EGFR), Head and neck cancer (HNC)

Received: October 9, 2019; **Accepted:** November 3, 2019; **Published:** January 10, 2020

Competing Interests: The authors have declared that no competing interests exist.

Consent: Consent was taken from the patient's next of kin for publication of this case report.

Copyright: 2020 Patowary J *et al.* This is an open-access article distributed under the terms of the Creative Commons Attribution License, which permits unrestricted use, distribution, and reproduction in any medium, provided the original author and source are credited.

***Correspondence to:** Jayanta Patowary, Department of Medical Oncology, Apollo Cancer Institute, Indraprastha Apollo Hospitals New Delhi, India

Email: drjayantapatwari@yahoo.co.in

Introduction

Head and neck cancer (HNC) is the sixth most common cancer worldwide with more than 550,000 cases reported annually [1]. The treatment of locally advanced HNC (LAHNC) usually involves a combination of surgery, chemotherapy and radiotherapy (RT). RT in addition to chemotherapy with concurrent cisplatin (CRT) is considered to be the most efficacious treatment option for SCCHN. However, it is often associated with acute and chronic toxicities [2].

Cetuximab, a chimeric monoclonal antibody of the immunoglobulin G1 class, an EGFR inhibitor is a critical target in the treatment of SCCHN that is overexpressed in >90% of patients with SCCHN. [3]. Cetuximab in combination with RT and chemotherapeutic drugs has demonstrated benefit for advanced as well as recurrent/metastatic SCCHN (R/M SCCHN) [4]. Cetuximab is efficacious as an add-on therapy and also as a monotherapy. When used as a single agent, it exhibits a cytostatic effect [3].

For patients with R/M SCCHN, international guidelines such as National Comprehensive Cancer Network Clinical (NCCN) Practice Guidelines and European Head and Neck Society (EHNS), European Society for Medical Oncology (ESMO) European Society for Radiotherapy and Oncology (ESTRO) recommend combination therapy with cetuximab as the first line treatment that results in a longer survival of the patients [5, 6].

Here, we report the case of a patient with SCCHN who initially had LASCCHN and later had R/M SCCHN. The patient was treated with cetuximab combination therapy.

Case Report

A 35-year-old male patient presented with complaints of swelling in left neck and induration of tongue since 5 days. Physical examination showed the presence of lateral border tongue lesion, indurated anteriorly with two large medial neck nodes and a node on the left side. He underwent Computer Tomography (CT), which showed a subtle increase in the bulk of left side of tongue with left sided cervical adenopathy. **Figure 1** shows the CT results of the patient at the time of admission.

The results from FNAC confirmed the presence of numerous mature squamous cells with heavy infiltration of polymorphonuclear leucocytes and few multinucleate giant cells. In view of strong clinical suspicion patient underwent a biopsy, which revealed SCC. He underwent hemiglossectomy and lymph node resection on the left side. The patient had a lesion of size 3.5 cm x 2.8 cm with thickness of 1.3 cm. Histopathology showed moderately differentiated carcinoma (WHO pT4a N2) with infiltrating margins and the presence of 6/28 lymph nodes from level I and II with necrosis pericapsular infiltration. After surgery, he was started with two cycles of chemotherapy with TPF, followed by concurrent local RT and cetuximab for 6 weeks. No evidence of tumor was found after cytoscopic examinations and MRI studies. Thus, no further therapy (including chemotherapy) was recommended.

The patient exhibited satisfactory recovery and remained asymptomatic for four years after which he developed an ulcer on the tongue and was readmitted (first recurrence). The patient was initially treated surgically and then he started the RT along with standard treatment with cetuximab for 6 weeks.

He was asymptomatic for two years. During follow up, his MRI (**Figure 2**) revealed recurrence on contralateral side of tongue. The patient underwent resection again and was treated with a single cycle of chemotherapy for 6 weeks along with cetuximab for 12 weeks.

In 10 months, the patient developed a mass in hypopharynx. The patient refused to undergo surgery after discussion with a multidisciplinary team of cancer specialists and was directly administered a treatment regimen comprising of docetaxel 40mg weekly for 12 doses, cetuximab weekly for 12 doses and an injection of cisplatin 50mg every alternate week for 6 doses. Of the 12 weekly chemotherapy cycles recommended, the patient completed 8 weekly doses of above treatment for 5 months. The patient was further kept on palliative care at home. Due to progression of disease leading to multi-organ dysfunction, the patient could not survive and died after 16 months of stopping treatment. Overall, the patient survived for 8 years since he began treatment in August 2007.

Discussion

Cancer like SCCHN may present with locally advanced (LA) stage III or IV disease and are usually treated with combined-modality therapies. Over the last 30 years, TPF as induction chemotherapy has been widely used for the management of patients with LA SCCHN. The results reported in the TAX 323 and TAX 324 trials indicate that the TPF regimen (docetaxel, cisplatin and 5-fluorouracil) improves overall survival (OS) as compared with the PF regimen (cisplatin and 5-fluorouracil) [7]. Cetuximab has shown beneficial results for the initial treatment of LA potentially curable disease. Studies by Bonner *et al.*; showed that the median duration of locoregional control was 24.4 months among patients treated with cetuximab plus RT and 14.9 months among those given RT alone. At 54 months of follow up, the median duration of OS was 49.0 months among patients treated with combined therapy and 29.3 months among those treated with RT alone. Survival rates at 2 years (62 % vs. 55 %) and at 3 years (55 % vs. 45 %) also favored the combination regimen ($p=0.05$ for the comparison at 3 years) [2, 8].

Data from several studies suggest that the combination of cetuximab with RT shows better survival and locoregional disease control associated in patients with SCCHN [3, 4, 8]. For R/M SCCHN, cetuximab along with chemotherapy followed by cetuximab maintenance monotherapy until progression is the gold standard first line treatment [9].

The EXTREME trial showed that the addition of cetuximab to platinum-5-fluorouracil improved the response rate and progression free survival (PFS) and OS. No evidence of recurrence was observed till 6 weeks, when the patient was first administered cetuximab in combination with chemotherapy and RT, and thus no further therapy was advised. This is primarily because cetuximab and RT have a significant benefit in locoregional control as compared with RT alone. The patient might have improved with the use of Cetuximab and RT [8].

For almost 4 years, the patient remained asymptomatic. The first recurrence was managed with cetuximab and RT after resection that showed satisfactory results. The second recurrence was managed by cetuximab and chemotherapy followed by resection. However, it has been observed in various recurrent cases of HNC, the duration of treatment is often not compatible with expected survival [10]. Overall, the patient could survive for around 8 years since the treatment began.

Conclusion

Cetuximab when given in combination with RT or used in combination with platins or with other chemotherapeutic drugs for management offers a survival advantage. In the advanced setting, treatment with cetuximab is recommended until disease progression or unacceptable toxicity.

Authorship

All authors have made substantial contributions to the conception and design of the study, drafting the article and final approval of the version to be submitted.

Acknowledgement

This publication was supported by a medical writing grant from Merck Specialties Pvt Ltd, India, an affiliate of Merck KGaA, Darmstadt, Germany. The authors also acknowledge Knowledge Isotopes Pvt. Ltd. (<http://www.knowledgeisotopes.com>) for the writing support.

Funding and Disclosure statement

It was funded by Merck Specialties Pvt Ltd, India, an affiliate of Merck KGaA, Darmstadt, Germany. Merck KGaA has reviewed the manuscript for checking the medical accuracy only before submitting it to the journal. The authors are fully responsible for the content of this manuscript, and the views and opinions described in the publication reflect solely those of the authors.

Conflict of interest

The author declares no conflict of interest.

Consent

The authors confirm that the patient has given their informed consent for the case report to be published.

References

1. Siegel RL, Miller KD, Jemal A. Cancer statistics, 2015. *CA: a cancer journal for clinicians*. 2015, 65:5-29
2. Bonner JA, Harari PM, Giralt J, Cohen RB, Jones CU, Sur RK, Raben D, Baselga J, Spencer SA, Zhu J, Youssoufian H, Rowinsky EK, Ang KK. Radiotherapy plus cetuximab for locoregionally advanced head and neck cancer: 5-year survival data from a phase 3 randomised trial, and relation between cetuximab-induced rash and survival. *The Lancet Oncology*. 2010, 11:8-21
3. Peddi P, Paryani B, Takalkar A, Bundrick P, Ponugupati J, Nair B, El-Osta H. Exceptional response to cetuximab monotherapy in a patient with metastatic oropharyngeal squamous cell carcinoma: a molecular insight. *OncoTargets and therapy*. 2016, 9:9-705
4. Pfister DG, Su YB, Kraus DH, Wolden SL, Lis E, Aliff TB, Zahalsky AJ, Lake S, Needle MN, Saha AR, Shah JP, Zelefsky MJ. Concurrent cetuximab, cisplatin, and concomitant boost radiotherapy for locoregionally advanced, squamous cell head and neck cancer: a pilot phase II study of a new combined-modality paradigm. *Journal of clinical oncology*. 2006, 24:8-1072

5. etal. VGg. Squamous cell carcinoma of the head and neck: EHNS–ESMO–ESTRO Clinical Practice Guidelines for diagnosis, treatment and follow-up. *Annals of Oncology*. 21 2010, 184-186
6. NCCN Clinical Practice Guidelines in Oncology: *Head and Neck Cancers VI*. 2015, 2015
7. Marshall R, Posner DMH, Cesar R, Blajman. Cisplatin and fluorouracil alone or with docetaxel in head and neck Cancer (THE TAX 324 trial). *New England Journal of Medicine*. 2007, 357:704-1697
8. Bonner JA HP, Giralt J, Azarnia N, Shin DM, Cohen RB, et al. Radiotherapy plus Cetuximab for SquamousCell Carcinoma of the Head and Neck. *N Engl J Med*. 2006, 354:78-567
9. Vermorken JB, Mesia R, Rivera F, Remenar E, Kawecki A, Rottey S, Erfan J, Zabolotnyy D, Kienzer HR, Cupissol D, Peyrade F, Benasso M, Vynnychenko I, De Raucourt D, Bokemeyer C, Schueler A, Amellal N, Hitt R. Platinum-based chemotherapy plus cetuximab in head and neck cancer. *N Engl J Med*. 2008, 359:27-1116
10. Lartigau EF TE, Thariat J, et al. Multi institutional phase II study of concomitant stereotactic reirradiation and cetuximab for recurrent head and neck cancer. *Radiother Oncol*. 2013, 109:5-281

Figures

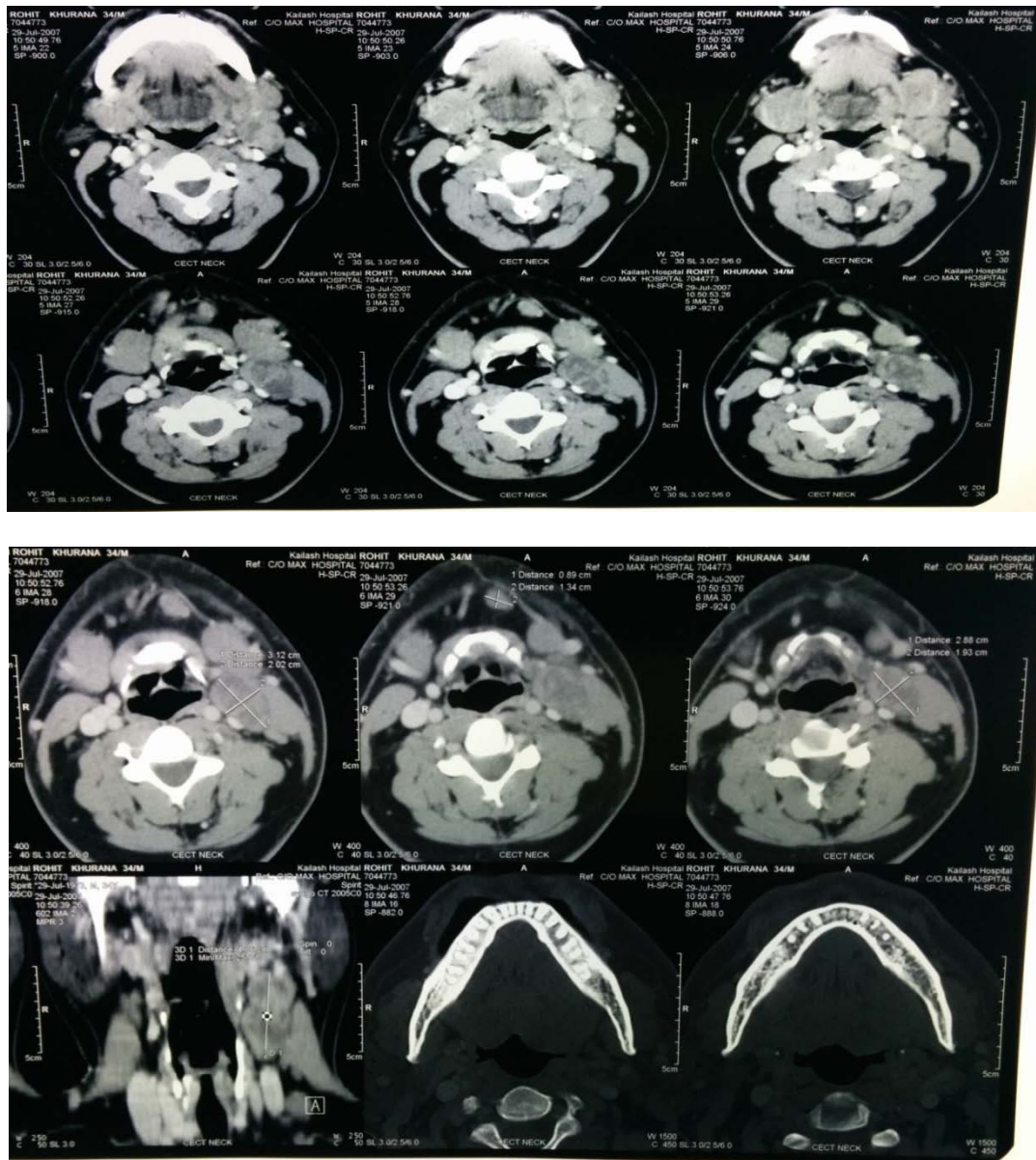


Figure 1 CT Report of Oropharynx: At the Time of Admission on 29th May 2007

Observations: Subtle increase in the bulk of left side of tongue with left sided cervical adenopathy. Few enlarged nodes in the submental and left supraclavicular region

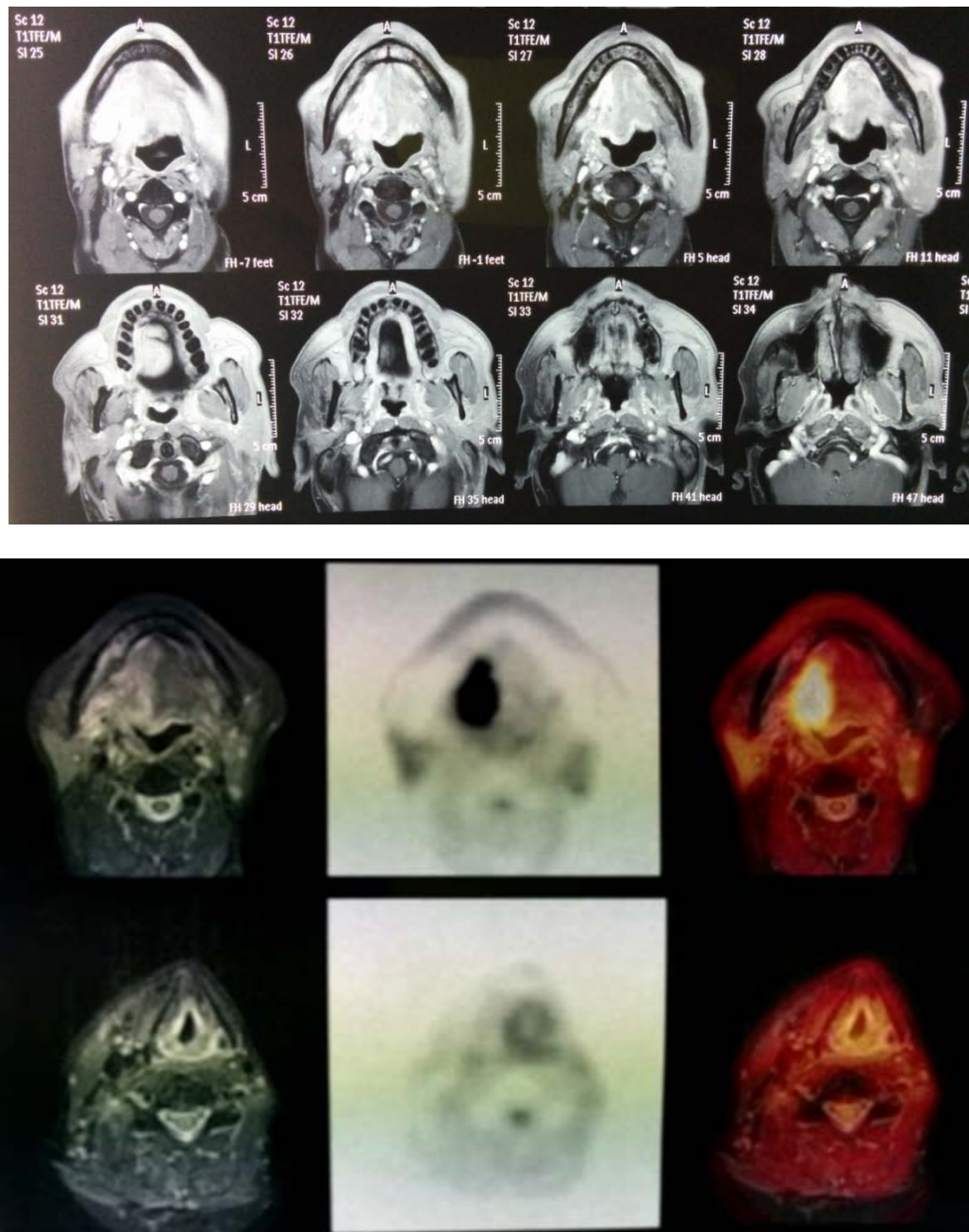


Figure 2 MRI Report Before Treatment:3rd May 2013
Observation: Recurrence was seen on contra lateral side of tongue.