



# The complementary role of histology and proteomics for diagnosis and typing of systemic amyloidosis

Tamer Rezk<sup>1,2†</sup> , Janet A Gilbertson<sup>1†</sup>, P Patrizia Mangione<sup>3,4</sup>, Dorota Rowczenio<sup>1</sup>, Nigel B Rendell<sup>3</sup>, Diana Canetti<sup>3</sup>, Helen J Lachmann<sup>1</sup>, Ashutosh D Wechalekar<sup>1</sup>, Paul Bass<sup>2</sup>, Philip N Hawkins<sup>1</sup>, Vittorio Bellotti<sup>3,4</sup>, Graham W Taylor<sup>3</sup> and Julian D Gillmore<sup>1\*</sup>

<sup>1</sup>National Amyloidosis Centre, University College London, London, UK

<sup>2</sup>Department of Renal Medicine, University College London, London, UK

<sup>3</sup>Wolfson Drug Discovery Unit, Centre for Amyloidosis and Acute Phase Proteins, Division of Medicine, Royal Free Campus, University College London, London, UK

<sup>4</sup>Department of Molecular Medicine, Institute of Biochemistry, University of Pavia, Pavia, Italy

\*Correspondence: Julian D Gillmore, National Amyloidosis Centre, Division of Medicine, Royal Free Campus, University College London, Rowland Hill Street, London NW3 2PF, UK. E-mail: j.gillmore@ucl.ac.uk

†Joint first authors.

## Abstract

The tissue diagnosis of amyloidosis and confirmation of fibril protein type, which are crucial for clinical management, have traditionally relied on Congo red (CR) staining followed by immunohistochemistry (IHC) using fibril protein specific antibodies. However, amyloid IHC is qualitative, non-standardised, requires operator expertise, and not infrequently fails to produce definitive results. More recently, laser dissection mass spectrometry (LDMS) has been developed as an alternative method to characterise amyloid in tissue sections. We sought to compare these techniques in a real world setting. During 2017, we performed LDMS on 640 formalin-fixed biopsies containing amyloid (CR+ve) comprising all 320 cases that could not be typed by IHC (IHC–ve) and 320 randomly selected CR+ve samples that had been typed (IHC+ve). In addition, we studied 60 biopsies from patients in whom there was a strong suspicion of amyloidosis, but in whom histology was non-diagnostic (CR–ve). Comprehensive clinical assessments were conducted in 532 (76%) of cases. Among the 640 CR+ve samples, 602 (94%) contained  $\geq 2$  of 3 amyloid signature proteins (ASPs) on LDMS (ASP+ve) supporting the presence of amyloid. A total of 49 of the 60 CR–ve samples were ASP–ve; 7 of 11 that were ASP+ve were glomerular. The amyloid fibril protein was identified by LDMS in 255 of 320 (80%) of the IHC–ve samples and in a total of 545 of 640 (85%) cases overall. The LDMS and IHC techniques yielded discordant results in only 7 of 320 (2%) cases. CR histology and LDMS are corroborative for diagnosis of amyloid, but LDMS is superior to IHC for confirming amyloid type.

**Keywords:** amyloid; mass spectrometry; proteomics; immunohistochemistry

Received 17 December 2018; Revised 28 January 2019; Accepted 4 February 2019

No conflicts of interest were declared.

## Introduction

The amyloidoses are a group of rare diseases caused by extracellular accumulation of amyloid, a fibrillar material derived from a variety of precursor proteins that can aggregate in a highly abnormal cross  $\beta$  sheet conformation [1,2]. Amyloid deposits progressively disrupt tissue structure and function [3], the various clinical syndromes being classified according to the respective fibril precursor protein, of which more than 30 are known [4]. Amyloid is identified by the

pathognomonic finding of apple-green dichroism when affected tissue sections are stained with Congo red (CR) dye and visualised under polarised light microscopy. Under electron microscopy, amyloid fibrils have a characteristic appearance of rigid non-branching fibrils with a diameter of  $\sim 10$  nm [5].

Systemic amyloidosis is highly heterogeneous not only with respect to amyloid fibril protein type but also to the range of organ involvement and broader clinical phenotype. Therapy is aimed at reducing the production of the respective amyloid fibril precursor

protein, and there is therefore a critical need to definitively determine the amyloid fibril protein type in every patient [6]. For example, chemotherapy, which can be very toxic, is potentially beneficial only in immunoglobulin light chain (AL) amyloidosis, which can be particularly challenging to confirm [7].

CR histology followed by immunohistochemical (IHC) staining of biopsy samples is the classical and widely available method for identifying amyloid and determining the fibril type. Whilst this is the historical gold standard for diagnosis and typing of amyloid, many different staining methods and antisera are used in different labs, and substantial operator experience is required for best results. The highly idiosyncratic nature of monoclonal AL amyloid, largely due the fact that the fibrils comprise the hypervariable region of the immunoglobulin light chains, presents particular challenges for IHC staining of AL deposits. Consequently, the sensitivity and specificity of IHC varies with type of amyloid, local methods and experience [8]. IHC studies of thousands of samples in our own centre have failed to confirm amyloid type beyond doubt in up to 30% of cases, mostly when AL amyloidosis is probable on clinical grounds. Immunofluorescence (IF) is a more reliable technique for the typing of AL amyloid deposits than IHC [9], although it requires frozen amyloidotic tissue. Immunoelectron microscopy (IEM) is a technique that combines IHC and electron microscopy and allows for the correct characterisation of the amyloid protein in virtually all cases but IEM is not widely available and is currently performed in only a select number of specialist centres [10]. Fibril extraction and direct protein sequencing is the gold standard method for typing of amyloid; however it is time consuming, expensive and requires substantial quantities of frozen tissue which are rarely available in clinical practice.

Laser dissection and tandem mass spectrometry (LDMS) is an alternative, reportedly accurate tool for identification and typing of amyloid deposits which has gained popularity. Importantly, it can be performed using tiny quantities of formalin fixed amyloidotic tissue. LDMS was first validated by the Mayo group in 2009, in 102 predominantly endomyocardial biopsy specimens; LDMS was 98–100% sensitive and specific in comparison to clinicopathological criteria for identification and typing of amyloid [11]. LDMS has also been reported in non-amyloid fibrillary monoclonal gammopathies of renal significance (MGRS), namely fibrillary glomerulonephritis (fibrillary GN) and light chain deposition disease (LCDD); hitherto, the diagnosis has been established by integrating morphological findings on light microscopy along with IF

and EM [12]. DNAJB9 is a recently reported novel and specific IHC marker [13], and its presence on LDMS of a glomerular sample, is pathognomonic of fibrillary GN [14].

We sought to compare and evaluate the roles of CR/IHC and LDMS for identifying and typing amyloid in a diverse population of suspected amyloidosis patients referred to our single national centre.

## Methods

### Samples

During the calendar year 2017, 1864 formalin-fixed paraffin wax-embedded (FFPE) biopsies from various tissues of patients suspected to have amyloid were studied in the UK National Amyloidosis Centre (NAC). They were received from many local hospitals across the UK and overseas. Tissue fixation and processing into paraffin blocks had been performed according to the referring hospitals' protocols and was therefore not standardised. Details on the duration of fixation and processing were unavailable.

Sections from all FFPE biopsy samples were cut and stained with CR and a panel of anti-fibril protein antibodies as described below. Amyloid, identified by pathognomonic green birefringence of CR stained tissue sections viewed under crossed polarised light, was present in 1109 of 1864 (59%) biopsy samples (CR +ve); 755 (41%) were negative for presence of amyloid (CR -ve). The amyloid fibril protein was determined by IHC in 789 of 1109 (71%) CR+ve samples, but could not be characterised definitively in the remaining 320 CR+ve samples.

For the purposes of this study, we processed a total of 700 samples for LDMS comprising all 320 CR+ve samples in which IHC was non-diagnostic of the amyloid fibril protein, 320 randomly selected CR+ve biopsy samples in which the amyloid type was definitively determined by IHC, and 60 randomly selected CR -ve biopsy samples.

All patients were managed in accordance with the declaration of Helsinki and institutional review board approval from the Royal Free Hospital Ethics committee was obtained for this study (REC/06/Q0501/42).

### CR and IHC staining at NAC

Twenty-two serial sections were cut from each FFPE block for CR and IHC staining. Sections of 2 µm thick were used for IHC and sections of 6 µm thick were used for CR staining and IHC/CR overlay [15]. CR

staining was by the method of Puchtler *et al* and amyloid was identified by the presence of apple green birefringence when viewed under crossed polarised light [16]. Immunohistochemical staining was with a panel of 11 antibodies against known amyloid fibril proteins using the Shandon Sequenza™ (Thermo Shandon Ltd, Runcorn, England), namely, kappa and lambda immunoglobulin light chains, transthyretin (ATTR), amyloid A protein, fibrinogen, LECT2, apolipoprotein A-I, and lysozyme, as previously described [17]. Antigen retrieval was not performed with the exception of ATTR staining, which uses oxidation steps 1% aqueous sodium periodate (10 min) and 0.1% sodium borohydride (10 min) followed by 6 M guanidine (4 h). Sections were blocked for endogenous peroxidases and also blocked with normal serum. Sections were incubated overnight at 4°C with the primary antibodies, rinsed in PBS. The antibodies were detected with the appropriate IMPRESS™ (Vector Laboratories, Accent Park, Peterborough, United Kingdom) polymer detection kit and labelled using metal enhanced 3,3'-diaminobenzidine (DAB) chromogen (Thermo Scientific).

The presence of amyloid by CR staining (CR+ve) was defined by the presence of pathognomonic apple green birefringence when viewed under crossed polarised light. The amyloid fibril protein was established on the basis of unique and specific staining of the amyloid with an antibody from the amyloid fibril protein panel. Interpretation was carried out without any clinical information by two independent experienced assessors using a Leica DM4000 with and without crossed polarising filters.

#### Laser capture microdissection and proteomic mass spectrometry analysis

For microdissection, stained CR sections were viewed under brightfield and fluorescence light using the Leica LMD7 laser capture microscope. Areas positive for amyloid when viewed using fluorescent light at excitation 497 nm and emission 614 nm wavelengths were laser microdissected into micro-centrifuge caps. In tissue samples where CR staining was equivocal or scanty, usually as a result of the presence of areas of amorphous eosinophilic material under brightfield light with seemingly white birefringence but bright fluorescence, such areas were captured by the same method. In renal tissues in which the differential diagnosis included amyloid or non-amyloid monoclonal gammopathy of renal significance (MGRS), and in which presence of amyloid was not confirmed by CR staining, glomeruli were captured by the same method. Proteins were extracted from each sample into 10 mM

Tris/1 mM EDTA/0.002% Zwittergent buffer solution (35 µl) by heating (99 °C, 1.5 h) followed by sonication (1 h) and then digested with trypsin (25 ng/sample) overnight (~18 h) at 37 °C. Each digested sample was reduced with dithiothreitol (50 µg) at 99 °C for 5 min, freeze dried, reconstituted in 0.1% (v/v) trifluoroacetic acid in HPLC grade water (20 µl) and analysed by HPLC-MSMS, using a Thermo Scientific Q-Exactive Plus mass spectrometer (Thermo Scientific, Bremen, Germany) coupled to a Dionex Ultimate 3000 RSLC nanoLC (Dionex Softron GmbH, Bavaria, Germany) using a Thermo Easy-spray Acclaim Pepmap (Fisher Scientific UK Ltd, Loughborough) column (75 µm × 15 cm, 3 µm/100 Å packing), as previously described [18,19].

MS raw data files were queried using Matrix Science's Mascot search engine (<http://www.matrixscience.com/>) and the SwissProt database to assign peptide and protein probability scores. Amyloid was established by LDMS on the basis of the presence of the 'amyloid signature proteins' (ASP) defined by the presence (≥1 unique specific peptide) of two or more of the following proteins; apolipoprotein E (APOE), apolipoprotein A-IV (AApoAIV) and serum amyloid P (SAP) component, as previously described [11]. The amyloid fibril protein was determined by a Mascot score of >80 coupled with at least two unique specific peptides of a known amyloid fibril protein together with absence (Mascot score < 80 or fewer than two unique specific peptides) of other known amyloid fibril proteins.

#### Analyses

The results of CR and IHC were compared with results of LDMS in a total of 700 samples (Figure 1). Specifically, they were compared with respect to identification of amyloid and identification of the amyloid fibril protein (amyloid type).

## Results

The 700 samples (640 CR+ve and 60 CR-ve) were from a total of 50 different tissue types with renal ( $n = 188$ ), cardiac ( $n = 126$ ) and bone marrow trephine ( $n = 44$ ) comprising over 50% of all samples processed.

#### Diagnosis of amyloid

A total of 602 of 640 (94%) CR+ve samples were ASP+ve by MS and 38 (6%) were ASP-ve. A total of 15 of 38 (39%) CR+ve/ASP-ve samples were classified by MS as 'insufficient for analysis' due to scanty tissue ( $n = 14$ ) or scanty amyloid ( $n = 1$ ) with a total

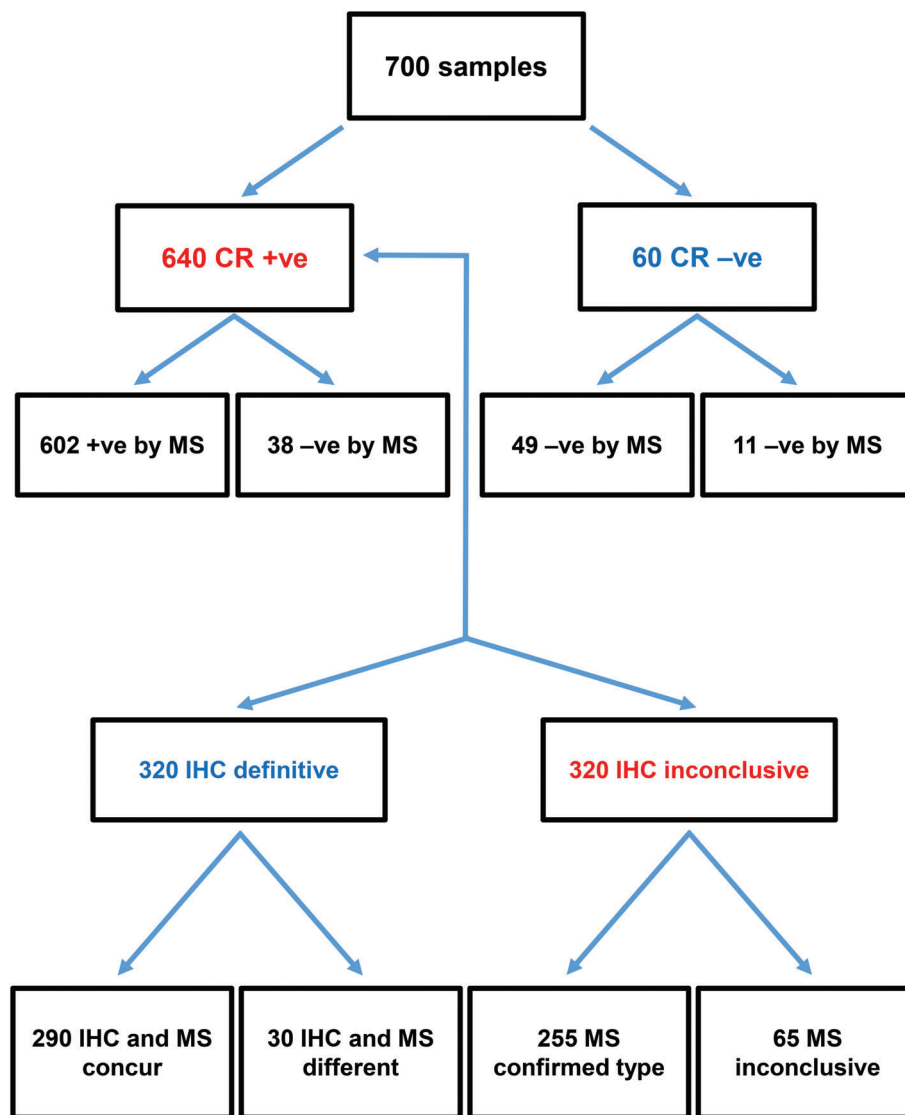


Figure 1. Flowchart of the results of 700 samples processed for CR with IHC and LDMS.

of <5 proteins identified within the sample. In the remaining 23/38 (61%) CR+ve/ASP-ve samples there was adequate tissue for analysis. The details of these 23 tissues samples (obtained from 20 patients) are listed in Table 1 which also includes the findings of a comprehensive clinical, biochemical and imaging review that was conducted in 15 of 20 individuals. In each of the 15 cases, an unequivocal diagnosis of amyloidosis was established on the basis of combined clinical, biochemical, echocardiographic, cardiac magnetic resonance (CMR) imaging, and scintigraphic analyses [20]. The final diagnosis was localised AL amyloidosis in four cases, ATTR amyloidosis in four cases, systemic AL amyloidosis in three cases, leukocyte chemoattractant factor 2 (ALECT2) amyloidosis in two cases,

beta 2 microglobulin ( $\beta$ 2M) amyloidosis in one case, and the final patient was a 59 year old male with carpal tunnel amyloid deposits in the absence of any critical amyloidotic organ involvement or dysfunction. The remaining 5 of 20 patients were not seen at our centre, and their biopsy sample had been sent to NAC solely for histological analysis.

A total of 49 of the 60 (82%) CR-ve samples were ASP-ve by MS and 11 of 60 (18%) were ASP+ve (Table 2). There were no CR-ve/ASP+ve cardiac, gastrointestinal, fat or bone marrow trephine biopsy samples (Table 3). However, there were seven renal biopsy specimens, all glomerular, from a total of 188 (4%) renal biopsies which were CR-ve/ASP+ve. In four of seven such cases, a diagnosis of fibrillary

Table 1. Samples diagnostic of amyloid by CR staining but with no amyloid by MS (CR+ve/ASP–ve)

Sample/ patient no	Age and sex	Tissue	Clinical/histology review	Final diagnosis*	Organ involvement	SAP scintigraphy	DPD scan (Perugini grade)
1/1	62 F	Lymph node	Clinical	Localised AL amyloidosis	No vital organ involvement	No visceral amyloid	Not done
2/2	87 M	Fat aspirate	Clinical	ATTR amyloidosis	Cardiac	No visceral amyloid	Grade 2
3/3	65 M	Prostate	Clinical	Localised AL amyloidosis	No vital organ involvement	No visceral amyloid	Not done
4/4	67 M	Renal	Clinical	Systemic AL amyloidosis	Renal	Isolated renal amyloid	Not done
5/5	84 M	Carpal tunnel	Clinical	β2M amyloidosis	No vital organ involvement	No visceral amyloid	Not done
6/6	68 F	Renal	Clinical	ALECT2 amyloidosis	Renal	Amyloid in spleen and kidneys	Not done
7/7	67 F	BMT	Histology	Uncertain	Not done	Not done	Not done
8/8	55 M	Muscle	Histology	Uncertain	Not done	Not done	Not done
9/9	84 M	Cardiac	Clinical	ATTR amyloidosis	Cardiac	No visceral amyloid	Grade 2
10/10	68 M	Tonsil	Clinical	Localised AL amyloidosis	No vital organ involvement	No visceral amyloid	Not done
11/11	82 M	Tongue	Clinical	ATTR amyloidosis	Cardiac	No visceral amyloid	Grade 2
12/12	54 M	Brain	Histology	Uncertain	Not done	Not done	Not done
13/13	72 M	BMT	Clinical	Systemic AL amyloidosis	Cardiac and soft tissue	No visceral amyloid	Not done
14/14	74 M	Renal (glomeruli)	Clinical	Renal amyloid – uncertain type	Renal	Isolated renal amyloid	Not done
15/14		Renal (medulla)	<i>As above</i>	<i>As above</i>	<i>As above</i>	<i>As above</i>	<i>As above</i>
16/15	34 F	Mucosa	Histology	Uncertain	Not done	Not done	Not done
17/16	63 M	Skin	Clinical	Localised AL amyloidosis	No vital organ involvement	No visceral amyloid	Not done
18/17	68 M	Renal (interstitium)	Histology	ALECT2 amyloidosis	Not done	Not done	Not done
19/18	59 M	Carpal tunnel	Clinical	Amyloid – uncertain type	No vital organ involvement	No visceral amyloid	Grade 0
20/19	92 M	Prostate	Clinical	ATTR amyloidosis	Cardiac	No visceral amyloid	Grade 2
21/19		Fat aspirate	<i>As above</i>	<i>As above</i>	<i>As above</i>	<i>As above</i>	<i>As above</i>
22/19		Fat aspirate #2	<i>As above</i>	<i>As above</i>	<i>As above</i>	<i>As above</i>	<i>As above</i>
23/20	61 F	BMT	Clinical	Systemic AL amyloidosis	Cardiac and soft tissue	Amyloid in liver and spleen	Not done

DPD, <sup>99m</sup>Tc-3,3-diphosphono-1, 2-propanodicarboxylic acid.

\*The final diagnosis in patients who underwent clinical review was established on the basis of a comprehensive clinical assessment, biochemical investigations including serum and urine immunofixation, serum free light chains and cardiac biomarkers and specialist imaging including SAP scintigraphy, DPD scintigraphy, echocardiography and CMR imaging.

GN was established on the basis of the clinical and electron microscopy findings coupled with the presence of DNAJB9 protein by MS [14]. One of the remaining three patients with a CR–ve/ASP+ve glomerular sample was eventually diagnosed with fibronectin glomerulopathy, and the diagnosis in the remaining two cases was not established at the time of writing (Table 2).

### Typing of amyloid

Of the 320 samples in which the amyloid fibril protein was determined by IHC, the amyloid type by MS concurred in 290 of 320 (91%), whereas in 30 samples there was a discrepancy between the amyloid type identified by IHC and the MS results. This discrepancy was due to the absence of ASP (i.e. CR+ve/ASP–ve) by

MS in 13 of 30 (43%) cases and, in the remaining 17 samples, the MS was either non-diagnostic of amyloid type ( $n = 10$ ) or discordant ( $n = 7$ ) (Table 4). Of those seven cases in which the amyloid fibril protein by IHC and MS were discordant, four were AL lambda sub-type by IHC but AL kappa sub-type by MS. Two of the four relevant patients had a circulating monoclonal protein, in both cases of lambda isotype. The amyloid fibril protein was discordant in a further three of seven samples; two were from the same patient (renal and testicular biopsy) in which IHC showed AA amyloid and MS showed AApoAI amyloid and in whom a novel *APOA1* mutation was discovered, and the remaining sample was a bladder biopsy in which AL (lambda sub-type) amyloid was identified by IHC and MS revealed ATTR amyloid. This last patient did not undergo clinical evaluation at our centre.

**Table 2.** Samples with no amyloid by CR staining but with the 'amyloid signature' by MS (CR–ve/ASP+ve)

Sample/ patient no	Age and sex	Tissue	Clinical/histology review	Final diagnosis*	Organ involvement	SAP scintigraphy
1/1	58 F	Soft tissue	Clinical	Localised AL amyloidosis	No vital organ involvement	No visceral amyloid
2/2	52 M	Soft tissue	Clinical	Systemic AA amyloidosis	Renal	Amyloid in spleen and kidneys
3/3	72 F	Skin	Clinical	Systemic AL amyloidosis	Cardiac and soft tissue	No visceral amyloid
4/4	66 M	Prostate	Clinical	Localised AL amyloidosis	No vital organ involvement	No visceral amyloid
5/5	66 F	Renal	Histology	Fibrillary GN	Not done	Not done
6/6	76 M	Renal	Histology	Fibronectin glomerulopathy	Not done	Not done
7/7	39 M	Renal	Clinical	Fibrillary GN	Renal	No visceral amyloid
8/8	52 M	Renal	Clinical	Fibrillary GN	Renal	No visceral amyloid
9/9	46 M	Renal	Histology	Uncertain	Not done	Not done
10/10	19 M	Renal	Histology	Uncertain	Not done	Not done
11/11	61 F	Renal	Clinical	Fibrillary GN	Renal	No visceral amyloid

\*The final diagnosis in patients who underwent clinical review was established on the basis of a comprehensive clinical assessment, biochemical investigations including serum and urine immunofixation, serum free light chains and cardiac biomarkers and specialist imaging including SAP scintigraphy, DPD scintigraphy, echocardiography, and CMR imaging.

**Table 3.** Comparison of CR histology and LDMS findings in commoner tissue types

Tissue type	Number of samples (n)	CR +ve (n)	CR– ve (n)	CR–ve/ASP +ve (n)	CR+ve/ASP –ve (n; %)*	Definitive typing of amyloid by MS (n; %)*	MS non-diagnostic of amyloid type (n, %)*	Inadequate sample (n; %)*
Cardiac	126	117	9	0	7 (6)	103 (88)	4 (3)	3 (3)
Renal	188	170	18	7	12 (7)	139 (82)	18 (11)	1 (1)
Gastrointestinal	40	40	0	0	0 (0)	38 (95)	2 (5)	0 (0)
Fat aspirate	25	23	2	0	4 (17)	18 (78)	1 (4)	0 (0)
Bone marrow trephine	44	40	4	0	4 (10)	30 (75)	4 (10)	2 (5)

\*Percentages are calculated as the percentage of all CR+ve samples (rather than percentage of all CR+ve/ASP +ve samples).

Of the 320 CR+ve samples in which the amyloid type was not diagnosed by IHC, amyloid was identified and typed by MS in 255 (80%) cases but was not definitively typed in the remaining 65 cases. In the 255 samples which were inconclusive by IHC but definitively typed by MS, the latter correlated with extensive clinical assessment in 252 of 255 (99%) cases. In the remaining three cases, tissue was received for a histology review alone such that limited clinical details were available. MS established a diagnosis of; AL kappa in 135 cases, AL lambda in 55 cases, ATTR in 26 cases, fibrinogen  $\alpha$  chain (AFib) in eight cases, localised semenogelin amyloid deposits in six cases, immunoglobulin heavy chain in six cases, hereditary apolipoprotein AI (AApoAI) in six cases, apolipoprotein C2 (AApoC2) in four cases, AApoAIV in four cases, galectin 7 (cutaneous) amyloid deposits in three cases, insulin derived (AIns) amyloid deposits in one case and isolated atrial amyloidosis in the final case.

Of the 65 cases in which the amyloid type could not be determined by MS, 12 samples were 'insufficient for analysis' by MS, 25 samples were ASP–ve, and 7 contained no known amyloid fibril protein. Twenty-one samples contained more than one known amyloid fibril protein each with a similar Mascot and specific peptide score including seven cases with both TTR

and a light chain (either kappa or lambda), and five cases with both kappa and lambda light chains.

## Discussion

CR staining and IHC remains the most commonly used method for the diagnosis and typing of amyloid worldwide, although some specialist centres have recently moved towards the use of LDMS alone [21]. Here we report for the first time a single centre direct comparison of the methods, supported where necessary by correlation with specialist clinical and imaging assessments, which highlights the advantages and limitations of each method and argues strongly in favour of their use as complementary techniques for diagnosis and typing of amyloid.

Our study showed a high concordance between CR staining and LDMS for the identification of amyloid with 94% of CR+ve samples showing amyloid by LDMS and 82% CR–ve samples not showing amyloid by LDMS. Nonetheless, LDMS in our hands failed to identify amyloid in a small proportion of cases, even when an adequate quantity of amyloidotic tissue was captured, and the reasons for this remain unclear. It is

Table 4. Samples in which MS was either non-diagnostic of amyloid type ( $n = 10$ ) or discordant ( $n = 7$ ) with the results of IHC

Sample/ patient no	Age/sex	Clinical/ histology review	Tissue	Final diagnosis*	Organ involvement	Systemic clone ( $n/\kappa/\lambda$ )	IHC	MS	SAP scintigraphy
1/1	78 M	Clinical	Laryngeal	Localised AL amyloidosis	No vital organ involvement	No	AL ( $\lambda$ )	AL ( $\kappa$ )	No visceral amyloid
2/2	65 F	Clinical	Lymph node	Localised AL amyloidosis	No vital organ involvement	Lambda	AL ( $\lambda$ )	AL ( $\kappa$ )	No visceral amyloid
3/3	84 F	Clinical	Renal	Systemic AL amyloidosis	Renal	Lambda	AL ( $\lambda$ )	Uncertain	Isolated renal amyloid
4/4	83 M	Histology	Cardiac	ATTR amyloidosis	Cardiac	Not known	ATTR	Uncertain	Not done
5/5	25 F	Clinical	Laryngeal	Localised AL amyloidosis	No vital organ involvement	No	AL ( $\lambda$ )	Uncertain	No visceral amyloid
6/6	58 M	Histology	Renal	Amyloid – uncertain type	Renal	Not known	AL ( $\lambda$ )	Uncertain	Not done
7/7	64 F	Clinical	Breast	Localised AL amyloidosis	No vital organ involvement	No	AL ( $\lambda$ )	AL ( $\kappa$ )	No visceral amyloid
8/8	79 M	Clinical	Renal	Systemic AL amyloidosis	Renal and Liver	Lambda	AL ( $\lambda$ )	Uncertain	Amyloid in liver and kidneys
9/9	78 M	Clinical	Cardiac	ATTR amyloidosis	Cardiac	Kappa	ATTR	Uncertain	No visceral amyloid
10/10	66 M	Clinical	Cardiac	Systemic AL amyloidosis	Renal and autonomic nerve	Lambda	AL ( $\lambda$ )	Uncertain	Amyloid in liver, spleen and kidneys
11/11	77 M	Histology	Bladder	Amyloid – uncertain type	Bladder	Not known	AL ( $\lambda$ )	TTR	Not done
12/12	67 F	Clinical	Lymph node	Insulin amyloid	No vital organ involvement	No	Alns	Uncertain	No visceral amyloid
13/13	46 M	Histology	Testes	Amyloid – uncertain type	Renal and testicular	Not known	AA	AApoAI	Not done
14/13		<i>As above</i>	Renal	<i>As above</i>	<i>As above</i>	<i>As above</i>	AA	AApoAI	<i>As above</i>
15/14	74 M	Clinical	Renal	Systemic AL amyloidosis	Renal	Lambda	AL ( $\lambda$ )	AL ( $\kappa$ )	Amyloid in spleen and kidneys
16/15	82 F	Histology	Soft tissue	Insulin amyloid	Soft tissue	Not known	Alns	Uncertain	Not done
17/16	47 F	Clinical	Laryngeal	Localised AL amyloidosis	No vital organ involvement	No	AL ( $\lambda$ )	Uncertain	No visceral amyloid

\*The final diagnosis in patients who underwent clinical review was established on the basis of a comprehensive clinical assessment, biochemical investigations including serum and urine immunofixation, serum free light chains and cardiac biomarkers and specialist imaging including SAP scintigraphy, DPD scintigraphy, echocardiography and CMR imaging.

also worth highlighting that 7 of 11 CR–ve/ASP+ve cases were glomerular and that the final diagnosis in 5 of these 7 glomerular samples was either fibrillary GN or fibronectin glomerulopathy. In 2015 the Mayo group reported LDMS in a small cohort of MGRS cases which included seven cases of renal amyloidosis and eight cases of fibrillary GN. LDMS revealed the presence of two or more ASP (SAP and APOE) in all amyloidotic samples and the presence of only APOE in fibrillary GN [22]. However, here we show that fibrillary GN and other very rare MGRS lesions can occasionally cause ‘false positives’ for amyloid by LDMS. In the case of fibrillary GN, however, the presence of glomerular DNAJB9 by MS should alert one to this potential risk [14]. Importantly, there were no CR–ve/ASP+ve cardiac, gastrointestinal, fat or bone marrow trephine samples such that the finding of ASP in the absence of CR staining in these tissues should be considered definitively diagnostic of amyloid.

With respect to typing of amyloid, MS was superior to IHC. The amyloid type was established by MS in 255 (80%) of the 320 cases that were not typed by IHC and in a total of 545 of 640 (85%) CR+ve samples. A sub-analysis according to tissue type showed that the amyloid type was definitively determined by MS in 95% of gastrointestinal, 88% of endomyocardial, 82% of renal, 78% of fat, and 75% of bone marrow trephine CR+ve samples (Table 3). However, despite a very high concordance between the amyloid type established by MS and that established by IHC, there were occasional discordant results ( $n = 7$ ; 2%) of which a proportion appeared to be more consistent with the IHC finding than that by MS, based on clinical and biochemical parameters. In addition, a number of CR+ve samples that were definitively typed by IHC did not contain ASP and the amyloid type could not therefore be determined by MS. Furthermore, a small number of cases were not typed by MS due to the

presence of more than one amyloid fibril protein, each with a similar Mascot and specific peptide score [23]. It is noteworthy that these cases frequently contained a combination of immunoglobulins and ATTR, both of which are abundant plasma proteins and may therefore be related to fixation and processing factors over which specialist referral centres, such as ours, have no control.

Whilst LDMS may successfully determine the amyloid fibril protein from tiny quantities of amyloidotic tissue, there are important factors to consider as to whether a sample is sufficient for analysis, including the distribution of amyloid deposits within the specimen. The challenges of dissecting ‘chicken-wire’ type amyloid deposits has been noted previously [24] and may result in abundance of other proteins within the microdissected sample. In addition, the limitations of amyloid typing by MS on fat samples containing ‘scanty’ amyloid deposits have previously been highlighted [25]. Further work is needed to avoid the small proportion of samples that cannot be typed by MS. To this end, recent work from our centre has looked at the role of tissue decellularisation in samples in which more than one potentially amyloidogenic protein is identified. In a small case series, pre-treatment of tissue with decellularisation enhanced the specificity of the identification of the correct amyloid fibril protein in samples in which more than one protein was detected [23].

In 2015, we undertook a smaller collaborative study of a similar nature in which 142 biopsy samples were stained with CR and IHC at the NAC and processed for LDMS at the Mayo Clinic, USA. The results of this earlier study were remarkably similar to our findings here; there was a very high degree of concordance between the two techniques and LDMS enabled typing of amyloid in 74% of 34 cases that could not be typed by IHC compared to 80% here. Furthermore, the reasons for the failure of MS to determine the amyloid type in the earlier study were listed as insufficient amyloid, insufficient tissue and technical failure [26], almost identical to our findings here.

Our study’s main limitation is that it is a retrospective analysis of biopsies from a single centre. There is, by definition, a selection bias based on the fact that all patients have been suspected of having amyloidosis or MGRS by the referring histopathologist or clinician in order to reach us in the first place. Second, due to the fact that fixation and processing of tissue occurred in the local referring centre, this was not controlled for and may have contributed to some of the failures of both IHC and LDMS [19]; as a consequence, however, our study does reflect ‘real-world’ clinical practice.

In conclusion we show here that the presence of ASP on MS is a sensitive and specific method for the identification of amyloid deposits but highlight the fact that, particularly in glomerular samples from patients with other deposition diseases such as fibrillary GN, the presence of ASP may not be due to amyloid. The addition of LDMS to CR histology and IHC markedly increased the proportion of amyloidotic samples in which the amyloid type was definitively determined to between 74 and 95%, depending on the biopsy tissue. Nonetheless, challenges remain; namely the occasional detection of more than one potential amyloid fibril protein by LDMS and the laser capture and identification of scanty material. Whilst LDMS remains a powerful tool for the diagnosis and typing of amyloid, our experience suggests that it should be used in conjunction with comprehensive clinical and histological assessment to ensure optimal patient care.

## Acknowledgements

We thank our many physician colleagues for referring and caring for the patients. Core support for the National Amyloidosis Centre and Wolfson Drug Discovery Unit is provided by NHS England, the UK National Institute for Health Research Biomedical Research Centre Biomedical Research Centre and Unit Funding Scheme *via* the UCLH/UCL Biomedical Research Centre. Funding for the proteomics platform was provided by the Wolfson Foundation and the Amyloidosis Research Fund.

## Author contributions statement

JDG, JAG, and TR were responsible for conceiving the study, interpreting the results and drafting the manuscript. DR, NR, PPM, TR, DC, HJL, ADW, PB, PNH, VB, and GWT were responsible for data collection and interpretation of results.

## References

1. Lachmann HJ, Hawkins PN. Systemic amyloidosis. *Curr Opin Pharmacol* 2006; **6**: 214–220.
2. Merlini G. Systemic amyloidosis: are we moving ahead? *Neth J Med* 2004; **62**: 104–105.
3. Pepys MB. Amyloidosis. In: *Samter’s Immunologic Diseases* (5th edn), Frank MM, Austen KF, Claman HN, et al. (Eds). Little, Brown and Company: Boston, 1994; 637–655.



4. Sipe JD, Benson MD, Buxbaum JN, *et al.* Amyloid fibril proteins and amyloidosis: chemical identification and clinical classification International Society of Amyloidosis 2016 Nomenclature Guidelines. *Amyloid* 2016; **23**: 209–213.
5. Pepys MB. Amyloidosis. *Annu Rev Med* 2006; **57**: 223–241.
6. Gillmore JD, Hawkins PN. Pathophysiology and treatment of systemic amyloidosis. *Nat Rev Nephrol* 2013; **9**: 574–586.
7. Lachmann HJ, Booth DR, Booth SE, *et al.* Misdiagnosis of hereditary amyloidosis as AL (primary) amyloidosis. *N Engl J Med* 2002; **346**: 1786–1791.
8. Owen-Casey MP, Sim R, Cook HT, *et al.* Value of antibodies to free light chains in immunoperoxidase studies of renal biopsies. *J Clin Pathol* 2014; **67**: 661–666.
9. Picken MM. New insights into systemic amyloidosis: the importance of diagnosis of specific type. *Curr Opin Nephrol Hypertens* 2007; **16**: 196–203.
10. Fernandez de Larrea C, Verga L, Morbini P, *et al.* A practical approach to the diagnosis of systemic amyloidoses. *Blood* 2015; **125**: 2239–2244.
11. Vrana JA, Gamez JD, Madden BJ, *et al.* Classification of amyloidosis by laser microdissection and mass spectrometry-based proteomic analysis in clinical biopsy specimens. *Blood* 2009; **114**: 4957–4959.
12. Bridoux F, Leung N, Hutchison CA, *et al.* Diagnosis of monoclonal gammopathy of renal significance. *Kidney Int* 2015; **87**: 698–711.
13. Nasr SH, Vrana JA, Dasari S, *et al.* DNAJB9 is a specific Immunohistochemical marker for fibrillary glomerulonephritis. *Kidney Int Rep* 2018; **3**: 56–64.
14. Dasari S, Alexander MP, Vrana JA, *et al.* DnaJ heat shock protein family B member 9 is a novel biomarker for fibrillary GN. *J Am Soc Nephrol* 2018; **29**: 51–56.
15. Tennent GA, Cafferty KD, Pepys MB, *et al.* Congo red overlay immunohistochemistry aids classification of amyloid deposits. In: *Amyloid and Amyloidosis 1998*, Kyle RA, Gertz MA (Eds). Parthenon Publishing: Pearl River, New York, 1999; 160–162.
16. Puchtler H, Sweat F, Levine M. On the binding of Congo red by amyloid. *J Histochem Cytochem* 1962; **10**: 355–364.
17. Gilbertson JA, Hunt T, Hawkins PN. Amyloid typing: experience from a Large Referral Centre. In: *Amyloid and Related Disorders*, Picken MM, Herrera GA, Dogan A (Eds). Humana Press: Totowa, NJ, 2012; 231–238.
18. Rodriguez FJ, Gamez JD, Vrana JA, *et al.* Immunoglobulin derived depositions in the nervous system: novel mass spectrometry application for protein characterization in formalin-fixed tissues. *Lab Invest* 2008; **88**: 1024–1037.
19. Canetti D, Rendell NB, Di Vagno L, *et al.* Misidentification of transthyretin and immunoglobulin variants by proteomics due to methyl lysine formation in formalin-fixed paraffin-embedded amyloid tissue. *Amyloid* 2017; **24**: 233–241.
20. Pinney JH, Lachmann HJ, Bansal L, *et al.* Outcome in renal AL amyloidosis following chemotherapy. *J Clin Oncol* 2011; **29**: 674–681.
21. Theis JD, Dasari S, Vrana JA, *et al.* Shotgun-proteomics-based clinical testing for diagnosis and classification of amyloidosis. *J Mass Spectrom* 2013; **48**: 1067–1077.
22. Sethi S, Theis JD, Vrana JA, *et al.* Laser microdissection and proteomic analysis of amyloidosis, cryoglobulinemic GN, fibrillary GN, and immunotactoid glomerulopathy. *Clin J Am Soc Nephrol* 2013; **8**: 915–921.
23. Mangione PP, Mazza G, Gilbertson JA, *et al.* Increasing the accuracy of proteomic typing by decellularisation of amyloid tissue biopsies. *J Proteomics* 2017; **165**: 113–118.
24. Picken MM. Proteomics and mass spectrometry in the diagnosis of renal amyloidosis. *Clin Kidney J* 2015; **8**: 665–672.
25. Brambilla F, Lavatelli F, Di Silvestre D, *et al.* Reliable typing of systemic amyloidoses through proteomic analysis of subcutaneous adipose tissue. *Blood* 2012; **119**: 1844–1847.
26. Gilbertson JA, Theis JD, Vrana JA, *et al.* A comparison of immunohistochemistry and mass spectrometry for determining the amyloid fibril protein from formalin-fixed biopsy tissue. *J Clin Pathol* 2015; **68**: 314–317.