

Gastrointestinal Stromal Tumor Associated with Hypertrophic Osteopathy in a Dog

Cintia Silva Correa da Veiga¹, Bruno Pessoa dos Santos Baetas², Flavia Bormann Vieira Nassif², Eduardo Ayres e Silva Pereira³, Danilo Gouveia Wasques⁴, Paula Elisa Brandão Guedes⁵ & Renata Santiago Alberto Carlos⁶

ABSTRACT

Background: Gastrointestinal stromal tumor (GIST) is a malignant mesenchymal neoplasm rarely described in the veterinary routine. The aim of this study was to report a case of GIST accompanied by a periosteal reaction, suggestive of hypertrophic osteopathy, in a dog.

Case: An 11-year-old male dog had a history of progressive weight loss, difficulty in locomotion, and dyspnea. During clinical care, increased bone volume was observed. Blood samples were collected for a complete blood count and biochemical analysis. The dog also underwent thoracic radiography and abdominal ultrasonography. The test results revealed anemia, leukocytosis, hypocalcemia, hypoalbuminemia, and hypocholesterolemia. The radiographic images of the limbs showed a generalized periosteal reaction, and thoracic radiography indicated changes compatible with mild chronic lung disease. Ultrasonographic findings indicated a neof ormation in the intestinal loop of the right mesogastric region and increased volume in the left testicle, both of which were indicative of neoplasia. Therefore, the dog was referred for surgery, wherein the intestinal mass and both testes were removed; the intestinal mass and left testicle were subjected to histopathological diagnosis. The results of the biopsies confirmed that the testicular neoplasm was a seminoma, whereas the intestinal nodule was compatible with GIST, and immunohistochemical analysis was necessary to confirm the diagnosis. On the basis of positive labeling for the antibodies vimentin, desmin, S100, and c-kit, the diagnosis of GIST was confirmed. Therefore, the animal underwent metronomic chemotherapy with 12 mg/m² cyclophosphamide every 24 h for 3 months, and thereafter every 48 h for 6 months. Moreover, the dog was periodically monitored via imaging (radiography of the anterior and posterior limbs, abdominal ultrasonography, and computed tomography). A few months after the surgical resection of the intestinal nodule, radiography revealed that the periosteal reactions had disappeared, but ultrasonography revealed nonspecific alterations of mild thickening and enlargement of the intestinal loops. Computed tomography revealed two nodular areas of soft-tissue attenuation in the right mesogastric region. Although the possibility of tumor recurrence was raised, the animal's owner chose only to perform palliative treatment. After 4 months, ultrasonography revealed a neof ormation in the right mesogastric region. On July 29, 2018 the animal had a worsening of its clinical condition, with tumor recurrence by ultrasound exam. The owners didn't accept returning to the oncologist and made an option for a conservative treatment with tramadol (3 mg/kg/TID), dipirone (25 mg/kg/TID), and vitaminic supplement based on docosahexaenoic acid plus eicosapentaenoic acid (30 mg/kg, once daily). On August, 28, 2018 he was euthanized. The dog's postsurgical survival time was 15 months.

Discussion: The dog described in the present report was large and elderly, both of which are predisposing factors for GIST development. Although non-specific, progressive weight loss may be associated with intestinal neoplasia, owing to the impairment of digestion and nutrient absorption, because a part of the duodenal mucosa was compromised by neoplasia. The difficulty in locomotion, which did not respond to treatment, was attributed to the periosteal reaction confirmed by radiographic exam. This, in turn, was associated with hypertrophic osteopathy secondary to neoplasia, because the condition regressed after the removal of the intestinal nodule. The histopathological findings related to intestinal neoplasia were suggestive of GIST; positive immunoblotting for c-kit, vimentin, S100, and desmin confirmed the diagnosis. Although the veterinarian alerted the owner to the suspicion of recurrence and suggested continuing treatment, the owner chose not to.

Keywords: *Canis familiaris*, hypertrophic osteopathy, immunohistochemical diagnosis, intestinal sarcoma, tomography.

DOI: 10.22456/1679-9216.97584

Received: 10 August 2019

Accepted: 19 November 2019

Published: 18 December 2019

¹M.V. Vet Bicharada & ²M.V. Itavet, Petrópolis, RJ, Brazil. ³M.V. Imagem.vet Telerradiologia & ⁴M.V. HistoPet, São Paulo, SP, Brazil. ⁵Curso de Pós-Graduação em Ciência Animal (PPGCA) & ⁶Curso de Medicina Veterinária, Universidade Estadual de Santa Cruz (UESC), Ilhéus, BA, Brazil. CORRESPONDENCE: R.S.A. Carlos [rsacarlos@uesc.com.br]. Campus Soane Nazaré de Andrade, Rodovia Jorge Amado, Km 16. CEP 45.652-900 Ilhéus, BA, Brazil.

INTRODUCTION

Neoplasms of the gastrointestinal tract are poorly reported in the veterinary routine, and account for only about 1% of malignancies described in dogs. Among these, smooth muscle mesenchymal neoplasms are the second most diagnosed type [1], with gastrointestinal stromal tumor (GIST) being the most common [8,15].

GIST is derived from the interstitial cells of Cajal, present in the gastrointestinal wall, and has histological characteristics of both smooth muscle tissue and neural tissue [1,7,9,14,16]. Its clinical signs are nonspecific and include weight loss, anorexia, and vomiting [2,14]. The diagnosis is based on the association of clinical signs and imaging techniques, such as endoscopy, ultrasonography, and computed tomography, which allow the visualization of neoplastic formation; however, confirmation requires histopathological and immunohistochemical analyses of the tumor [2,16,18]. The treatment of choice is the surgical removal of the mass with safe margins, but the efficacy of chemotherapy in dogs with this type of tumor remains unknown [1,2].

Some neoplasms may be accompanied by hypertrophic osteopathy, characterized by periosteal reaction, that occurs because of increased periosteal activity. It has been reported to accompany lung diseases in dogs, as well as secondary to thyroid carcinoma and renal sarcoma [7]. Nevertheless, bone alteration in cases of gastrointestinal tumors has not yet been reported. The aim of this study was to report a case of GIST in a dog with hypertrophic osteopathy.

CASE

An 11-year-old male Labrador dog, weighing 28.2 kg, with a history of difficulty in locomotion and weight loss for approximately 3 months, in addition to dyspnea, presented to a private clinic in Petrópolis - RJ, on May 16, 2017. The owner reported previous use of chondroitin and glucosamine at a dose of 100 mg/kg (Condroton 1000)¹ 6 months ago, but with no improvement in locomotion difficulty. A clinical examination revealed an increase in the volume of bones (Figure 1), mainly the radius/ulna, metacarpals, right and left metatarsals, as well as abdominal sensitivity. On auscultation, a holosystolic murmur grade II was identified in the mitral focus.

The following complementary tests were performed: complete blood count, biochemical analysis of

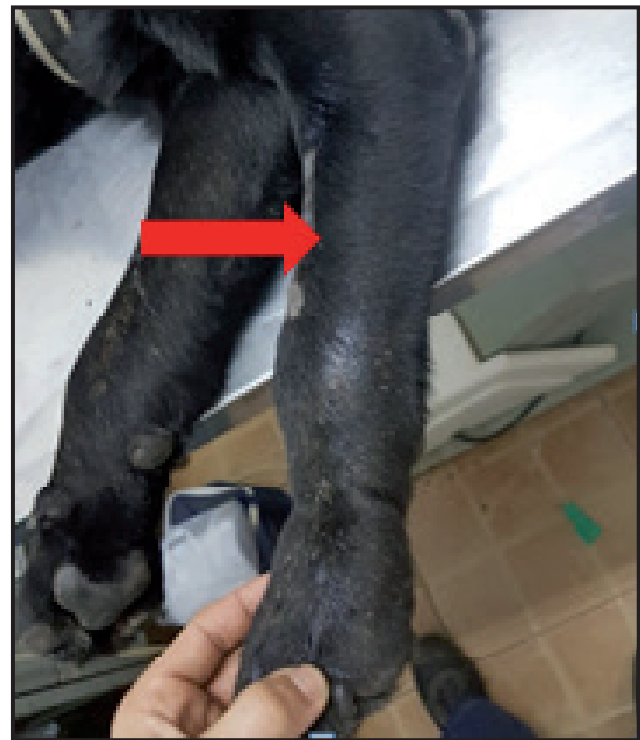

Figure 1. An 11-year-old male Labrador dog. Note the increased volume in the left radius/ulna bone (red arrow).

glucose, creatinine, phosphorus, calcium, prothrombin time, albumin, globulin, alanine aminotransferase, alkaline phosphatase, gamma glutamyl transferase, total bilirubin, and cholesterol (on May 16, 2017), as well as chest radiography and abdominal ultrasonography (on May 18, 2017). The results of the hematological tests revealed anemia (hematocrit of 21.8%), leukocytosis (24.4 K/ μ L), hypocalcemia (7.6 mg/dL), hypoalbuminemia (1.8 g/dL), and hypocholesterolemia (105 mg/dL), according to the reference values described by Kaneko *et al.* [12]. Radiographic images of the right and left limbs showed generalized periosteal reaction in distal diaphysis and metaphysis of humerus, and in radius, ulna, fibula, metacarpal and metatarsals bones (Figure 2A). Moreover, the images revealed incongruence of the humeral-radio-ulnar joints and loss of anatomical definition of the anomalous processes of the ulnar joints, presenting osteophytic formations in the medial and lateral umbilical condyles, radial heads, ulnar medial coronoid processes, and medial humeral epicondyles, suggesting a degenerative joint disease like osteoarthritis. The bone alterations were suggestive of hypertrophic osteopathy. In addition, soft-tissue volume increase, consistent with secondary inflammation, was observed. Thoracic radiographic exam indicated changes compatible with mild chronic lung disease. Ultrasonographic findings indicated a neof ormation in the right mesogastric re-

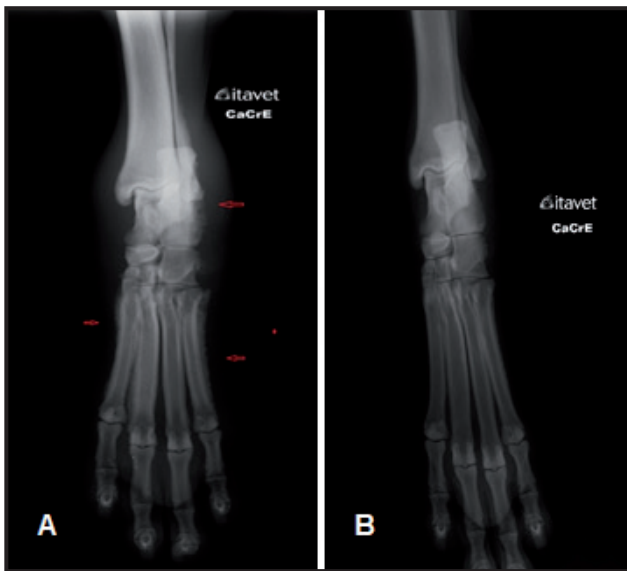


Figure 2. A- Radiographic image of the left tarsals and metatarsals of a dog before surgery for the removal of an intestinal nodule. Note the periosteal reaction (red arrow). B- Radiographic image of the left tarsals and metatarsals of a dog after surgery for the removal of an intestinal nodule. Note the absence of the periosteal reaction.

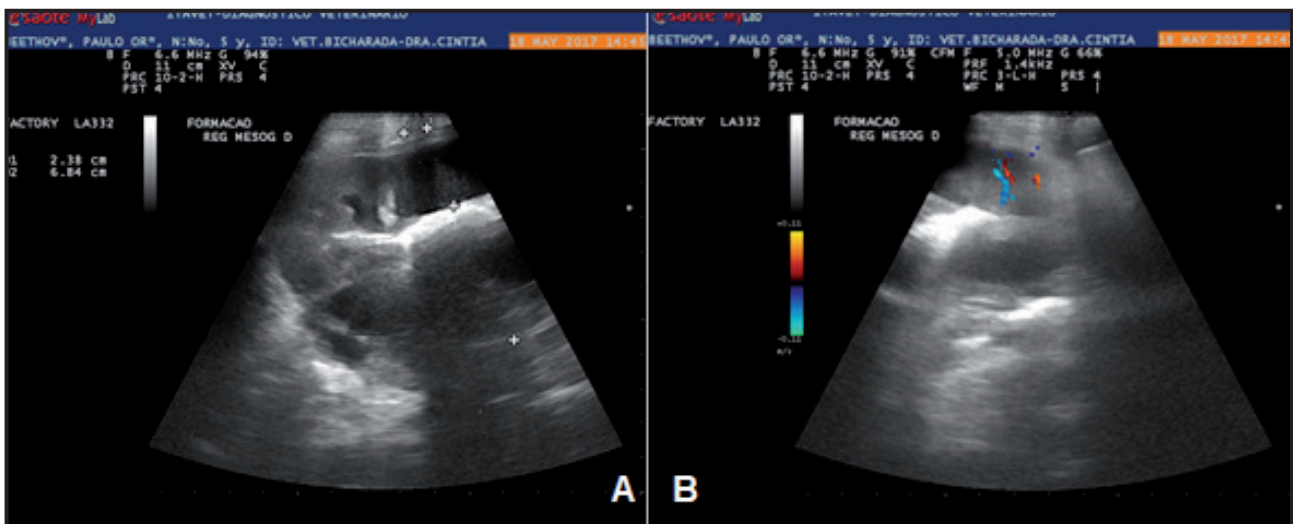


Figure 3. A- Ultrasonographic findings indicating an intestinal loop neof ormation, measuring approximately 10.04 × 6.84 cm; with thick hypoechoic walls, slightly heterogeneous and measuring 2.38 cm; and with some cystic structures measuring approximately 2.0 × 1.0 cm; these findings are compatible with neoplasia. B- Ultrasonographic findings of the same mass indicated in A, presenting vascularity on Doppler imaging; this finding is also compatible with neoplasia.

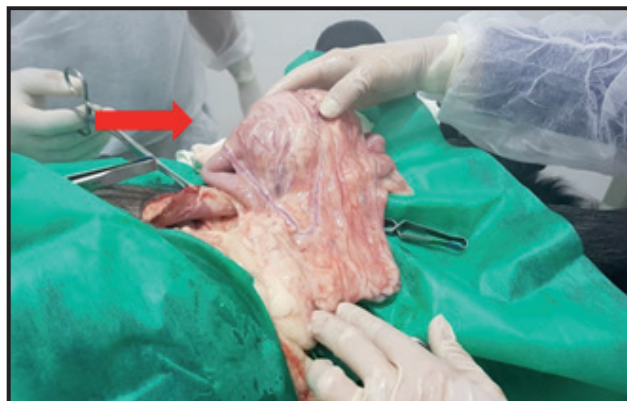

Figure 4. Removal of the intestinal tumor, measuring approximately 10 cm, located in the duodenum (red arrow).

gion, measuring approximately 10.04 × 6.84 cm; with thick hypoechoic walls that were slightly heterogeneous and measuring 2.38 cm; with some cystic structures measuring approximately 2.0 × 1.0 cm; and presenting vascularity on Doppler imaging; these findings were compatible with neoplasia (Figure 3). In addition, the left testicle presented a volume increase, globose aspect, heterogeneous surface, loss of definition of the mediastinal line, and discrete vascularization on Doppler imaging, thereby indicating neoplasia.

Thus, the animal was referred for exploratory laparotomy, performed on May 19, 2017, during which the intestinal tumor was resected (Figure 4), together with intestinal anastomosis and orchiectomy. Samples of the nodule located in the duodenum and left testicle were subjected to histopathological analysis.

Microscopic evaluation of the intestinal nodule revealed spindle-shaped neoplastic cells in bundles,

rarely with palisade formation and mild to moderate stromal myxoid matrix deposition. The neoplastic cells showed marked anisokaryosis, with prominent and multiple nucleoli of varying sizes and coarse aggregation of chromatin as well as a high mitotic index, with some atypical figures (Figure 5 A & B). The histopathological diagnosis was that it was a poorly differentiated neoplasm suggestive of GIST, but immunohistochemical evaluation was necessary to confirm the diagnosis. The immunohistochemical profile of the tumor cells was assessed using immunolabelling with c-kit, vimentin, S100, desmin, 1A4,

HHF35, and AE1/AE3. The reactions were positive for the first four antibodies (Figure 6A & B); therefore, in association with the histopathological findings, the diagnosis was confirmed as GIST. The left testicle showed a high cell density, composed of round germ cells arranged in mantles in the middle of a discrete fibrovascular stroma. Neoplastic cells had rounded, vesiculous nuclei with prominent nucleoli and moderate to marked anisokaryosis, with a moderate mitotic index. The diagnosis was seminoma.

review, which showed that the dog presented no clinical alterations. New radiographic and ultrasonographic exams were requested for control. After 38 days of surgical resection, the radiographic report revealed that the periosteal reactions had disappeared (Figure 2B). Abdominal ultrasonography showed no significant changes.

To monitor the evolution of the case, another abdominal ultrasonography was performed on August 8, 2017, which indicated that the duodenum presented

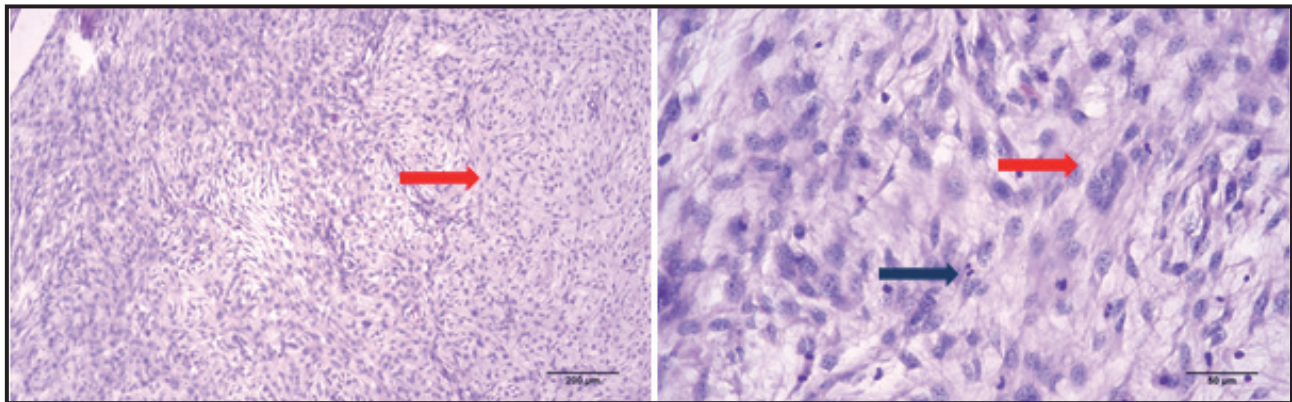


Figure 5. A- Gastrointestinal stromal tumor in a dog's duodenum. Note the spindle-shaped neoplastic cells arranged in bundles (red arrow), rarely with palisade formation and discrete to moderate stromal myxoid matrix deposition [HE; 10x]. B- Gastrointestinal stromal tumor in a dog's duodenum. Note the neoplastic cells with marked anisokaryosis (red arrow), prominent and multiple nucleoli of varying sizes, and coarse aggregation of chromatin. Frequent mitosis (blue arrow) [HE; 40x].

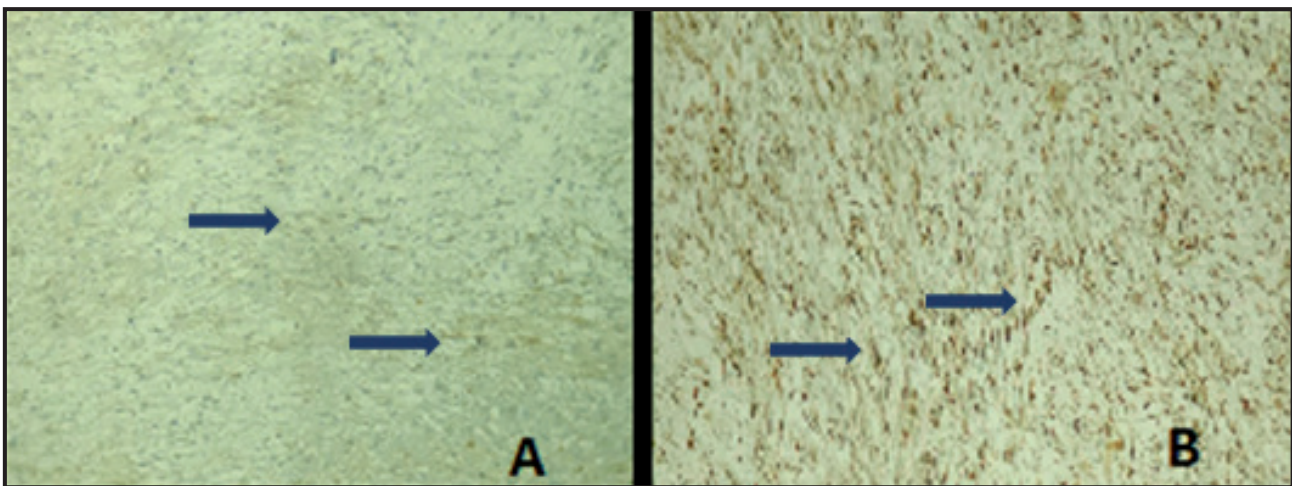


Figure 6. Immunohistochemical features of the nodule suggestive of gastrointestinal stromal tumor in a dog. A- Note the positive c-kit immunolabelling (arrows) [20x]. B- Notice the positive immunoblotting for vimentin (arrows) [20x].

On the basis of the histopathological and immunohistochemical test results of the gastrointestinal tumor, the animal was referred for metronomic chemotherapy, which started on June 23, 2017. Chemotherapy involved the administration of 12 mg/m² cyclophosphamide² every 24 h. This chemotherapy schedule was followed for 3 months; thereafter, it was administered every 48 hours, and was completed in March 2018.

In the first week of chemotherapy, the animal was again clinically evaluated to perform the clinical

a distension, measuring between 1.92 and 2.66 cm in diameter, with irregular walls, measuring between 0.55 and 0.98 cm; these findings were compatible with recurrent neoplasia. On the basis of these results, to monitor the evolution of this possible recurrence, the animal was submitted to new abdominal ultrasonography on October 26, 2017. The ultrasonographic findings indicated a segment of the duodenum presenting a decrease in the differentiation of the layers, measuring approximately 1.49 cm in diameter, suggestive of post-

surgical fibrosis; however, the possibility of recurrence of the previously removed neoplasia was not ruled out. Thus, periodic monitoring of the animal, through consultations with the veterinary doctor and completion of complementary tests, was suggested to the owner.

On March 5, 2018, the animal was reassessed and submitted to abdominal computed tomography (Figure 7). This exam revealed two nodular areas of soft-tissue attenuation with defined limits in the right mesogastric region of the mesentery. The first of these was located near the visceral wall of the duodenum, with a separation plane, measuring about 0.90 cm in diameter. The other was located ventrocaudal to the right branch of the pancreas, without contact between the structures, measuring about 1.0 cm in diameter. These findings were interpreted by the veterinarian as suggestive of new mesentery and lymph node enlargement. Since these findings were considered nonspecific, the animal was periodically monitored by the veterinarian.

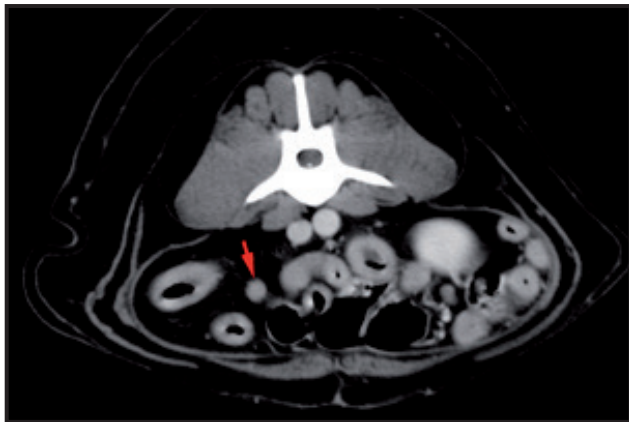


Figure 7. Abdominal computed tomography of a dog. A nodule measuring about 1.0 cm in diameter (red arrow), with defined and regular limits and homogeneous softening of parts is located ventrocaudally at the end of the right branch of the pancreas, through the mesentery.

On July 23, 2018, after performing new tests on the dog, ultrasonography revealed a heterogeneous formation in the right medial portion of the mesogastric region, measuring 5.47×3.36 cm and 4.87×4.15 cm, and presenting some cavitory areas. Discrete Doppler vascularization was observed, and this was more evident in the periphery of the formation. The sonographic image suggested a neoplastic process, compatible with relapse or metastatic focus of the previous formation. Thus, histopathological exam of this formation was recommended for a better interpretation of the findings.

The owner was informed about the suspicion of relapse; however, he chose not to perform any other procedure, and only approved of treatment to maintain

the quality of life of the animal. Thus, tramadol³ (3 mg/kg/TID), dipirone⁴ (25 mg/kg/TID), and vitaminic supplement based on docosahexaenoic acid plus eicosapentaenoic acid⁵ (30 mg/kg, once daily) were prescribed. Besides the prescription, the clinical condition went badly and the dog was euthanized on August 29, 2018. The dog's postsurgical survival time was 15 months, without any recurrence of hypertrophic osteopathy.

DISCUSSION

The male dog described in the present report was large and elderly, both of which are predisposing factors reported to lead to the development of GIST [2,8,9,14]. In addition, Labradors have been reported to be more affected by gastric neoplasias than are other breeds, but this association still lacks justification [2,14].

Progressive weight loss in an animal is a change, albeit a non-specific sign, that may be associated with GIST [2,8,14]. Weight loss is probably associated with impaired digestion and absorption of nutrients by the animal, since a part of the duodenal mucosa is compromised by neoplasia. In addition, it may be associated with cancer cachexia.

Another clinical sign presented by the animal was difficulty in locomotion that was not responsive to palliative treatment and was attributed to the periosteal reaction, which led to pain and was confirmed by radiographic exam. Although hypertrophic osteopathy has not yet been reported secondary to gastrointestinal neoplasms, it has been associated with other tumors in dogs [7]. In the veterinary literature, there are some reports of neoplastic upper gastrointestinal tract processes associated with hypertrophic osteopathy, such as esophageal embryonal rhabdomyosarcoma and esophageal sarcomas secondary to *Spirocerca lupi* infection [8]. However, no studies have described the association of neoplastic processes in the lower gastrointestinal tract with paraneoplastic syndrome in dogs. The association between GIST and hypertrophic osteopathy was based on the regression of bone alteration after the surgical removal of the intestinal mass. In addition, the fact that the periosteal reaction manifested bilaterally indicated that this would be secondary to a systemic process [19], as in the case presented, which helped rule out the possibility of a bone metastasis of GIST.

The periosteal reaction occurs because of a reaction of the bone cortex, characterized by an increase in the periosteum; however, its pathogenesis associated

with neoplasias remains unknown. According to the literature, this presentation has several alterations; in the present case, the radiographic characteristics of the lesion were suggestive of the periosteal palisade reaction. Nevertheless, because of the lack of reports in veterinary medicine about this association with GIST, it remains unclear if this pattern of periosteal reaction observed in the present dog is characteristic of this tumor [19]. The chest radiographic exam results also showed no relationship between the pulmonary alteration and neoplasia.

The present case is atypical because it is a possible case of hypertrophic paraneoplastic osteopathy in the absence of neoplastic lesions (primary or metastatic) in the thoracic cavity. In recent retrospective studies, the presence of neoplastic formations in the thoracic cavity (whether in the lung tissue or adjacent structures) has been a consistent finding in cases of hypertrophic paraneoplastic osteopathy [22,23]. However, the literature contains descriptions of some isolated cases of hypertrophic paraneoplastic osteopathy associated with extrathoracic tumors (in the absence of thoracic metastases), including hepatocellular carcinoma in a dog, ovarian granular cell tumor in a mare, and transitional renal pelvic carcinoma in a dog, among others [10,17,20]. The justification for the occurrence of the syndrome in these extrathoracic cases is unclear, but it is possible that the osteopathy occurs because of the stimulation of the extrathoracic portions of the vagus nerve.

Among the hematological changes observed in this dog, anemia and leukocytosis were also reported by Leandro & Sá [14] in dogs with GIST evaluated in their research. According to these authors, anemia may be secondary to blood loss from the intestinal mucosal injury caused by the mass as the disease progresses. Leukocytosis can be justified by bacterial infection secondary to ulceration of the intestinal mucosa as well as necrosis of neoplastic cells. In addition, inflammatory processes are usually accompanied by an increase in the number of circulating leukocytes.

Although biochemical changes were also found in the blood of this dog, these were considered nonspecific and, according to the literature, unrelated to GIST [14]. However, it is worth mentioning that hypoalbuminemia may be related to gastrointestinal protein loss owing to neoplasia involvement, and it is a finding that has also been described in cases of

hypertrophic paraneoplastic osteopathy, as observed in 11 of 19 animals in a previous study [23]. Nevertheless, the mechanism of hypoalbuminemia in the context of hypertrophic osteopathy remains unclear.

In the present case, ultrasonographic findings led to the suspicion of intestinal neoplasia once a vascularized mass was found in the duodenum; this prompted the veterinarian to opt for exploratory laparotomy for resection of the tumor. According to the literature, ultrasonography can aid the imaging diagnosis of gastrointestinal tumors [2], and in the present case, it was decisive to the referral of the animal to surgery. However, the most sensitive diagnostic technique for suspected cases of gastrointestinal neoplasms is computed tomography. This exam provides a presurgical evaluation with respect to tumor extension and invasion, thus aiding in surgical planning and the identification of possible metastases [10,18]. In the present case, computed tomography was only performed after the removal of the nodule, as an auxiliary tool to monitor the progression of the disease, a condition for which this test is also indicated [18]. Computed tomography was not initially performed for diagnosis owing to its high cost compared to that of ultrasonography; moreover, a computed tomography device for animals was as yet unavailable in the city at the time the dog first presented for treatment. However, considering the higher sensitivity of computed tomography for the diagnosis of gastrointestinal neoplasms, the dog was submitted to these exam during follow-up, when the device became available in the region.

In addition, because of the suspicion of testicular neoplasia, orchiectomy was performed, which enabled the performance of the biopsy and helped arrive at the seminoma diagnosis. Interestingly, the testicular neoplasm was an incidental finding, and there was no relationship between this and the other alterations reported in the animal.

The veterinary literature contains rare references to genital tract neoplasias in association with hypertrophic osteopathy, including a case of malignant Sertoli cell tumor in a dog, dysgerminoma in a mare, and ovarian tumor of granulosa cells in a mare [3,17]. With the exception of the granulosa cell tumor, the other two cases presented metastatic disease in the thoracic cavity (in the lung and mediastinal lymph nodes), and the trigger factor of hypertrophic osteopathy in these cases was probably the metastatic lesions in

the thoracic cavity, and not the primary formations. In the present case, although it is not possible to completely rule out the causal association of seminoma with hypertrophic osteopathy, this seems less likely because of the absence of evidence of metastasis in the thoracic cavity. Considering the proposed pathophysiology of hypertrophic osteopathy, it would be unreasonable to suggest that neoplasia located in a scrotal pocket could interfere with neurovagal stimulation.

The option for surgical resection of the intestinal mass was supported by the literature, which indicates this as the treatment of choice for cases of gastrointestinal tumors [1,2], even though only few reports have documented the treatment of GIST in dogs. In human medicine, patients with GISTs, after surgical resection, are usually submitted to adjuvant therapy with imatinib mesylate, a tyrosine kinase inhibitor. This drug interferes with the activity of tyrosine kinase (c-kit) receptors, which, as will be discussed later, are of utmost importance in the development of GIST [18]. This therapy has been reported in veterinary medicine in association with other forms of chemotherapy for mastocytoma, a neoplasm that also exhibits mutations in the c-kit receptor [13], but no reports have documented its use in cases of GIST in dogs. In the present case, chemotherapy with cyclophosphamide² was the recommended complementary therapy for soft-tissue sarcoma [2], since the owner did not agree to submit the animal to treatment with imatinib mesylate.

The neoplasm in the present case was approximately 10 cm in diameter, which is in agreement with the size described in the literature. According to Leandro & Sá [14], GISTs are neoplasias that can reach diameters of up to 30 cm, thus compromising the mucous and muscular layers of the intestine. This reiterates the hypothesis that the dog's weight loss was due to the reduction of the intestinal absorption surface. Although the size of gastric tumors has been related to their aggressiveness in human medicine, veterinary medicine still lacks studies on these neoplasms to confidently suggest such an association. In addition, the location of the mass corroborates with that reported in the veterinary routine, which indicates that the intestinal loops are the portion of the digestive system most affected by GIST in dogs, and that the duodenum is the second most described portion with this neoplasia [8,14,21].

The histopathological findings of the intestinal nodule were compatible with the literature description for GIST [8,9,14,16]. However, since soft-tissue sarcomas have high heterogeneity among the tumor cells that make up the tumor, immunohistochemical evaluation is often necessary to complete the diagnosis [2], as was used in the present report. The antibodies c-kit, vimentin, S100, and desmin used in the present case are the most commonly used in the veterinary routine to confirm cases suggestive of GIST [14,16]. Vimentin is a protein expressed by most mesenchymal cells; thus, immunopositivity to this antibody indicated the mesenchymal origin of the tumor cells from the intestinal nodule. According to Leandro & Sá [14], all intestinal stromal tumors are positive for vimentin. In addition, the cellular labeling for desmin, a protein expressed by smooth muscle cells, was consistent with that reported in the literature, which indicates that GIST has histologic features of smooth muscle tissue. In addition, S100 antibody labelling, which is characteristic of changes originating from the myenteric nerve plexus, corroborated with the literature, thereby indicating that this neoplasm also had histological features of neural tissue [1,7,9,14,16]. According to Frost *et al.* [8], more than 70% of GISTs may be positive for S100.

Regarding the immunostaining of c-kit, a transmembrane receptor tyrosine kinase, the positive result confirmed the diagnosis of GIST, since the interstitial Cajal cells (which give rise to this neoplasia) express the c-kit receptor, which makes it sensitive to such a diagnosis. c-kit is important for the proliferation, adhesion, apoptosis, and differentiation of Cajal cells. In cases of granulomatous stromal tumors, the abnormal and exacerbated proliferation of Cajal cells is due to mutations that trigger tyrosine kinase receptors, triggered by the proto-oncogene KIT, and these mutations are identified in more than 90% of GISTs [16]. Thus, by combining the immunostaining results for the above mentioned antibodies with the histopathological characteristics of the tumor, it was possible to confirm the origin of the neoplastic cells and, consequently, arrive at the diagnosis of intestinal neoplasia. It is worth mentioning that, more recently, the DOG1 antibody has been suggested as a more sensitive marker for the diagnosis of GIST (especially in c-kit-negative cases). DOG1 is a plasma membrane protein that is involved in the transport of chlorine [6].

GIST should be differentiated from other mesenchymal neoplasms, such as leiomyoma, leiomyosarcoma, schwannoma, neurofibroma, and neuroendocrine tumors, that may exhibit histopathological similarities to it, albeit with different immunohistochemical profiles [18,21]. More recently, an additional category of intestinal sarcomas has been proposed, classified as “non-GIST sarcoma and non-leiomyosarcoma,” which is negative for specific immunohistochemical markers of these neoplasms [11]. This information reinforces the importance of immunohistochemical profiling of suspected GIST neoplasias, as was done in the present case.

Data from the literature indicate that dogs with GIST submitted only to surgical treatment have an average survival time of 37.4 months [21]. There are no reports on the survival time of dogs with GIST submitted to postsurgical treatment with cyclophosphamide². However, Araújo *et al.* [2] reported an average survival time of 7.5 months in dogs with soft-tissue sarcomas that received chemotherapy, as in the present study. The dog reported herein presented a 15-month

survival period after surgical removal and received chemotherapy as adjuvant therapy, twice as long as that observed by Araújo *et al.* [2]. However, about 3 months after the surgical removal of the intestinal nodule, areas compatible with possible recurrence were noted. Although the veterinarian alerted the owner about continuing treatment, the owner chose not to. Thus, it was not possible to infer if the follow-up ultrasonographic images were actually suggestive of tumor recurrence, since surgical resection and subsequent microscopic analysis of the sample would have been necessary for confirmation.

Declaration of interest. The authors report no conflicts of interest. The authors alone are responsible for the content and writing of the paper.

MANUFACTURERS

¹Vetnil-Indústria e Comércio de Produtos Veterinários Ltda. Louveira, SP, Brazil.

²Baxter. Miami, FL, USA.

³Agener União - Saúde Animal. São Paulo, SP, Brazil.

⁴Biovet Vaxxinova. São Paulo, SP, Brazil.

⁵Avert. São Paulo, SP, Brazil.

REFERENCES

- 1 Américo P.M.A., Yoshitoshi F.N., Oliveira G.V., Noronha N.P. & Siqueira R.F. 2016. Sarcoma gástrico em cão: relato de caso. *Arquivo Brasileiro de Medicina Veterinária e Zootecnia*. 68 (5): 1183-1186.
- 2 Araújo D.C.C., Santos I.O V., Silva M.A., Pessoa C.C.V., Carvalho J.R.G., Lopes N.L. & Fernandes J.I. 2016. Sarcoma gastrointestinal em cão – Relato de Caso. *Revista Brasileira de Medicina Veterinária*. 38: 178-183.
- 3 Barrant K.R. & Scudamore C.L. 2001. Canine hypertrophic osteoarthropathy associated with a malignant Sertoli cell tumor. *Journal of Small Animal Practice*. 42(3): 143-145.
- 4 Cecarelli C.F., Silva F.F.S., Lorigados C.A.B., Cogliati B., Torres L.N. & Pinto A.C. B.C.F. 2014. Reação periosteal não metastática associada à neoplasia: relato de dois casos. *IV Simpósio Internacional de Diagnóstico por Imagem Veterinário* - (Belo Horizonte, Brazil). 1 CD ROM.
- 5 Devriendt N., Brantegem L.V., Willems A., Raes E. & Rooster H. 2017. Embryonal rhabdomyosarcoma of the oesophagus in a young dog. *Journal of Comparative Pathology*. 156(1): 21-24.
- 6 Dailey D.D., Ehrhart E.J., Duval D.L., Bass T. & Powers B.E. 2015. DOG1 is a sensitive and specific immunohistochemical marker for a diagnosis of canine gastrointestinal stromal tumors. *Journal of Veterinary Diagnosis and Investigation*. 27(3): 268-277.
- 7 Feng F., Feng B., Liu S., Liu Z., Xu G., Guo M., Lian X., Fan D. & Zhang H. 2017. Clinicopathological features and prognosis of mesenteric gastrointestinal stromal tumor: evaluation of a pooled case series. *Oncotarget*. 8(28): 46514-46522.
- 8 Frost D., Lasota J. & Miettinen M. 2003. Gastrointestinal Stromal Tumors and Leiomyomas in the Dog: A Histopathologic, Immunohistochemical, and Molecular Genetic Study of 50 Cases. *Veterinary Pathology*. 40: 42-54.
- 9 Gillespie V., Baer K., Farrelly J., Craft D. & Luong R. 2011. Canine Gastrointestinal Stromal Tumors: Immunohistochemical Expression of CD34 and Examination of Prognostic Indicators Including Proliferation Markers Ki67 and AgNOR. *Veterinary Pathology*. 48(1): 283-291.
- 10 Grillo T.P., Brandão C.V.S., Mamprim M.J., Jesus C.M.N., Santos T.C. & Minto B.W. 2007. Hypertrophic osteopathy associated with renal pelvis transitional cell carcinoma in a dog. *Canadian Veterinary Journal*. 48: 745-747.

- 11 Hayes S., Yuzbasiyan-Gurkan V., Gregory-Bryson E. & Kiupel M. 2013. Classification of canine nonangiogenic, nonlymphogenic, gastrointestinal sarcomas based on microscopic, immunohistochemical, and molecular characteristics. *Veterinary Pathology*. 50 (5): 779-788.
- 12 Kaneko J.J., Harvey J.W. & Russ M.L. 1997. *Clinical Biochemistry of Domestic Animals*. San Diego: Academic Press, 932p.
- 13 Kim J.H., Kim H.J., Kim D.H., Yim J.H., Lee S.J., Park K.H. & Yoon H.Y. 2016. Successful response to imatinib in two dogs with inoperable grade III infiltrating mast cell tumours: a case report. *Veterinary Medicina*. 61(8): 467-473.
- 14 Leandro R.M. & Sá L.R.M. 2016. Tumor estromal gastrointestinal em cães: estudo clínico-anatomopatológico. *Arquivo Brasileiro de Medicina Veterinária e Zootecnia*. 68(4): 938-944.
- 15 Macedo L.L., Torres L.R., Fauz R.A., Tornin O.S., Gonzalez F.M., Aquino I.M., Fonseca C.A.M., Pescioto A. & Souza R.P. 2007. Tumor do estroma gastrintestinal: achados clínicos, radiológicos e anatomopatológicos. *Radiologia Brasileira*. 40(3): 149-153.
- 16 Oliveira L.R.P., Pace F.H.L. & Souza A.F.M. 2011. Tumores estromais do trato gastrointestinal: revisão da literatura. *HU Revista*. 37(2): 247-255.
- 17 Packer M. & Mckane S. 2012. Granulosa thecal cell tumour in a mare causing hypertrophic osteopathy. *Equine Veterinary Education*. 24(7): 351-356.
- 18 Pelandré G.R., Djahjah M.C., Nobre L.F., Gasparetto E.L., Marchiori E., Pereira B.V., Valadão M. & Linhares E. 2008. Aspectos tomográficos do tumor estromal gastrintestinal de origem gástrica: estudo de 14 casos. *Radiologia Brasileira*. 41(5): 297-303.
- 19 Rana R.S., Wu J.S. & Eisenberg R.L. 2009. Periosteal Reaction. *American Journal of Roentgenology*. 193: 259-272.
- 20 Randall V.D., Souza C. & Vanderhart D. 2015. Hypertrophic osteopathy associated with hepatocellular carcinoma in a dog. *Canine Veterinary Journal*. 56(7): 741-744.
- 21 Russell K.N., Mehler S.J., Skorupski K.A., Baez J.L., Shofer F.S. & Goldschmidt M.H. 2007. Clinical and immunohistochemical differentiation of gastrointestinal stromal tumors from leiomyosarcomas in dogs: 42 cases (1990–2003). *Journal of the American Veterinary Medical Association*. 230(9): 1329-1333.
- 22 Salyusarenko M., Peeri D., Bibring U., Ranen E., Bdolah-Abram T. & Aroch I. 2013. Hypertrophic osteopathy: a retrospective case control study of 30 dogs. *Israel Journal of Veterinary Medicine*. 68(4): 209-217.
- 23 Withers S.S., Johnson E.G. & Culp W.T. 2015. Paraneoplastic hypertrophic osteopathy in 30 dogs. *Veterinary and Comparative Oncology*. 13(3): 157-165.