

## Metastatic Seminoma in a Male Alpine Goat: Clinical and Histopathological Approach

Isabel Oliveira Cosentino<sup>1</sup>, Mario Felipe Alvarez Balaro<sup>1</sup>, Ana Beatriz da Silva Carvalho<sup>1</sup>,  
Juliane Teramachi Trevizan<sup>2</sup>, Felipe Zandonadi Brandão<sup>1</sup> & Claudia Del Fava<sup>3</sup>

### ABSTRACT

**Background:** Seminomas are germ cell tumors mainly originating from spermatogonia in the seminiferous tubules and has been described in several domestic animal species, even though has rarely been described in goats. Moreover, seminomas tumors are not usually metastatic and rarely trigger paraneoplastic syndrome. In this sense, this is a case report of a 12-year-old male Alpine goat, suspected of testicular neoplasm based on clinical examination and ultrasound imaging, diagnosed as a seminoma with metastasis in liver by histopathology upon necropsy.

**Case:** A 12-year-old male Alpine goat presented a 10 month history of progressive weight loss, prostration, and scrotal sac enlargement. The major clinical findings were pale conjunctival mucus, bilateral nasal catarrhal secretion, obstructive dyspnea, an increased abdominal component, crackling at trachea auscultation, silence upon lung auscultation of the ventral area and wheezing upon auscultation of the dorsal area, and enlargement of the left testicle with contralateral atrophy. At the Ultrasonography scan, the enlarged left testicle presented architecture loss, as well as circumscribed masses differing in echogenicity and echotexture with scattered small hyperechoic nodules. The shrunken right testicle showed acoustic shading across the surface suggestive of calcification. Due to the poor prognosis and regard for animal welfare, the goat was euthanized. The main necropsy findings on testicles were: enlarged left testicle with white parenchyma on the dorsal side as well as diffuse yellow elliptical lesions of 0.5-2.5 cm on the surface in association with two circumscribed areas at the cranial and caudal poles, firm upon cutting. The right testicle was half the typical size, slightly pale, firm at cutting of the tunica albuginea, and presented dark parenchyma with abundant calcification dots suggestive of microlithiasis. The histological findings included diffuse tumoral stroma of the left testicle composed of large, polyhedral, discretely demarcated circular cells exhibiting a large nucleus varying in size with little cytoplasm and a high mitotic rate. The right testicle exhibited areas of necrosis and fibrosis of the testicular parenchyma, contiguous with the area of degeneration and normal parenchyma, caseous necrosis, and focal calcification. The liver presented some foci of the same cellular pattern of the seminoma, as described in the parenchyma. The findings summarized at necropsy and histopathological evaluation were seminoma in the left testicle, with metastasis to the liver; degeneration and necrosis of the right testicle with abscess and calcification.

**Discussion:** Seminoma has been described in several species, even though rarely in goats. This report was the second ever seminoma reported in caprine species, and particularly this case presented liver metastasis, showing the pathologic potential of this neoplasia for this species, and it differed from first reported which described ulcerative lesions in, and adhesion of the skin covering the testis. Regarding the US scan, even though this technique cannot be considered as a conclusive diagnostic, it may help to reach a prognosis by the tumor's characteristics. An US scan along with cytology or biopsy enables an earlier diagnosis of testicular lesions and prognosis. Orchidectomy, when unilateral, can be carried out to increase the animal's productive life.

**Keywords:** *Capra hircus*, neoplasia, testis, ultrasonography.

DOI: 10.22456/1679-9216.93422

Received: 3 April 2019

Accepted: 25 June 2019

Published: 24 July 2019

<sup>1</sup>Departamento de Patologia e Clínica Veterinária, Universidade Federal Fluminense (UFF), Niterói, RJ, Brazil. <sup>2</sup>Setor de Reprodução Animal, Universidade Estadual Paulista (UNESP), Campus Jaboticabal, Jaboticabal, SP, Brazil. <sup>3</sup>Laboratório de Anatomia Patológica, Instituto Biológico, São Paulo, SP. CORRESPONDENCE: M.F.A. Balaro [mariobalaro@hotmail.com - +55 (21) 2629-9510]. Departamento de Patologia e Clínica Veterinária, Faculdade de Veterinária, UFF. CEP 24320-340 Niterói, RJ, Brazil.

## INTRODUCTION

Seminomas are germ cell tumors mainly originating from spermatogonia in the seminiferous tubules and are characterized by spherical or polyhedral neoplastic cells [4,8]. Seminoma has been described in several domestic animal species [1,2,8] and in humans [5]. Nevertheless, in goats, only a single case was reported previously [6].

Seminomas tumors may be single or multiple, bilateral or unilateral, cystic or non-cystic, and diffuse or intratubular. They are not usually metastatic and rarely trigger paraneoplastic syndrome [2]. Cryptorchidism confers a predisposition to development of seminoma, and the neoplasia most often occurs in older animals [4].

In this sense, it was aimed to report a clinical case of a 12-year-old Alpine buck, suspected of testicular neoplasm based on clinical examination and ultrasound imaging, diagnosed as a seminoma with metastasis in liver by histopathology upon necropsy.

## CASE

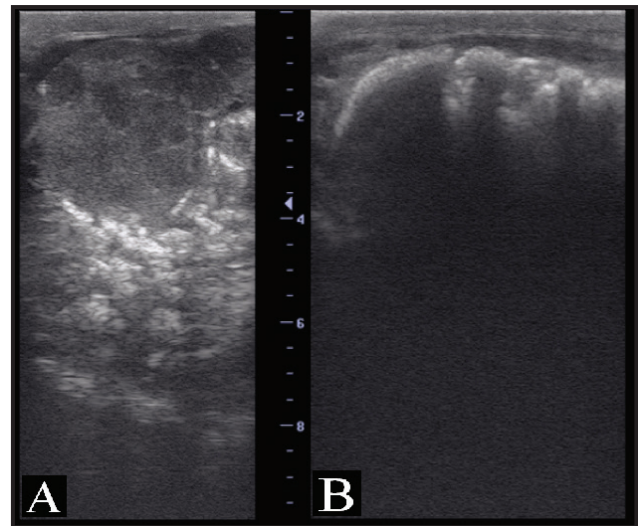
A 12-year-old male Alpine goat kept in an intensive dairy goat system in Minas Gerais State Brazil presented a 10 month history of progressive weight loss, prostration, and scrotal sac enlargement (Figure 1A). Its examination was proceeded according ethical approval (CEUA Protocol 855/16). The major clinical findings were pale conjunctival mucus, bilateral nasal catarrhal secretion, obstructive dyspnea, an increased abdominal component, crackling at trachea auscultation, silence upon lung auscultation of the ventral area and wheezing upon auscultation of the dorsal area, seborrheic dermatitis and alopecia over the back, 10% dehydration, body condition score of 2.0 out of 5.0 (thin), and enlargement of the left testicle with contralateral atrophy (Figure 1B).

Ultrasonography (US) was performed to obtain data regarding the internal viscera and contents of the scrotal sac. Liver and kidneys showed no abnormalities. The thorax image presented slight anechoic content, suggestive of hydrothorax. The enlarged left testicle presented architecture loss, as well as circumscribed masses differing in echogenicity and echotexture with scattered small hyperechoic nodules (Figure 2A). The shrunken right testicle showed acoustic shading across the surface suggestive of calcification (Figure 2B).

Due to the poor prognosis and regard for animal welfare, the goat was euthanized according to the



**Figure 1.** A- Male Alpine goat (12-year-old) presenting chronic cachexia. B- Asymmetric scrotum with enlarged left and contralateral right testicles.

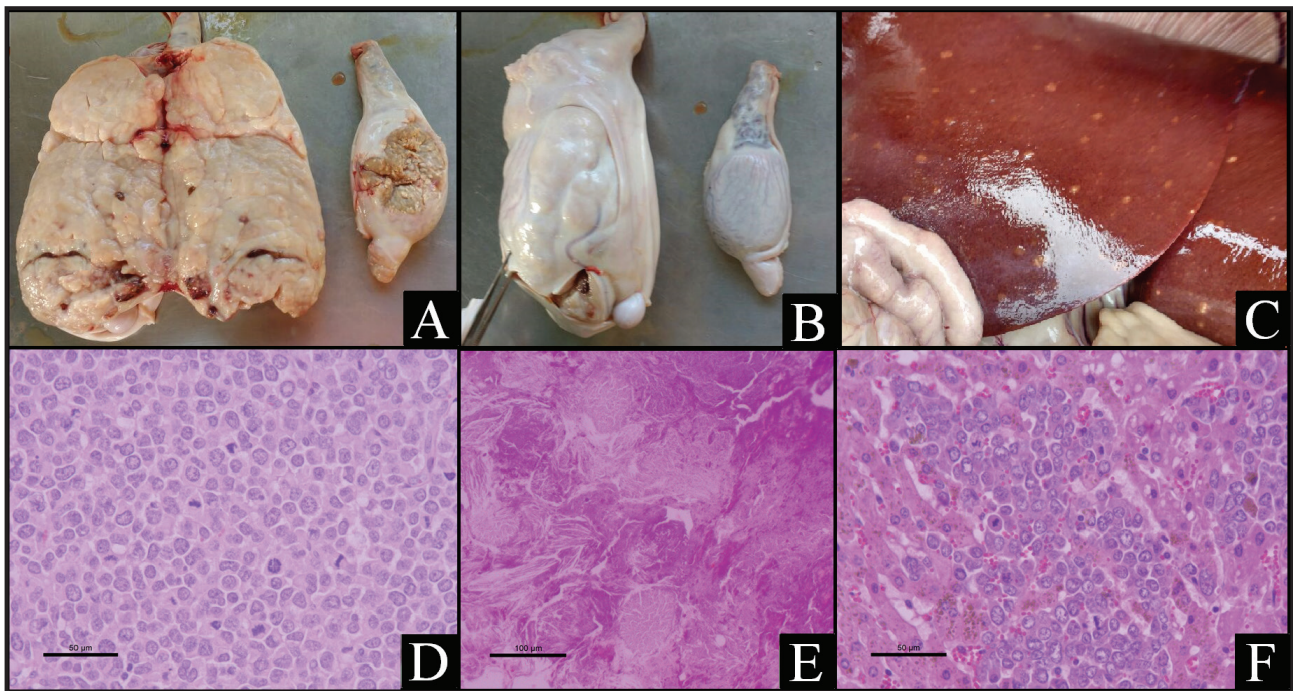


**Figure 2.** B-mode ultrasonographic image: A- Left testis with loss of architecture and presence of masses of differing dimensions, echotexture, and echogenicity. B- Right testicle with no visualization due to the presence of acoustic shadow on the surface (7.5 MHz probe, depth of 9.0 cm).

Federal Council of Veterinary Medicine [3] using 0.4 mg/kg of diazepam (Diazepam<sup>®</sup>)<sup>1</sup> as pre-anesthetic, 10 mg/kg of ketamine (Cetamin<sup>®</sup>)<sup>2</sup> as anesthetic, and saturated solution of potassium chloride<sup>3</sup> for induced cardiac arrest.

Necropsy was performed immediately, and the main findings were lack of subcutaneous and body cavity fat; straw-colored cloudy fluid in the abdominal cavity; bilateral pleural adhesion in the ventral region of the thoracic cavity (mainly on the right) near the pericardial sac and pericardial sternum ligament; left lung enlargement with diffuse congestion and edema; right lung presenting irregular surface of cranial and middle lobe due to pleuritis and pericardium adherence; mild emphysema in both lungs and moderate white foam in trachea and bronchi; mild hydropericardium (translucent content) and pericarditis; presence of fibrin adhering to the epicardium; left ventricle congestion and right ventricle pallor; mild congestion





**Figure 3.** Macroscopic images: A- Circumscribed areas at the poles, diffuse central mass in the testis with tumor, and foci of dystrophic calcification in the contralateral testis; B- Enlarged left testicle with diffuse elliptic lesions of varied sizes and degenerated right testicle; C- Liver with brownish lesions. Photomicrographs (H&E staining): D- Left testis - seminoma (400x); E- Right testicle - necrosis and dystrophic calcification (200 x); F- Liver - seminoma metastasis (400x).

and enteritis in some jejunum segments; little content in rumen and abomasum; bluish-white patches on the liver surface (Figure 3C); bilateral adhesion of renal capsule and bilateral white striping in the cortex; and right adrenal gland hypertrophy. The primary testicular findings were: enlarged left testicle (2.5x) with white parenchyma on the dorsal side as well as diffuse yellow elliptical lesions of 0.5-2.5 cm on the surface in association with two circumscribed areas at the cranial and caudal poles, firm upon cutting. The right testicle was half the typical size, slightly pale, firm at cutting of the tunica albuginea, and presented dark parenchyma with abundant calcification dots suggestive of microlithiasis (Figure 3A e B). Pieces of organ tissue were fixed in 10% formalin for histology and sent to the Laboratory of Pathological Anatomy of the Biological Institute in São Paulo State and processed by standard histopathological procedures using H&E staining [7].

The histological findings included diffuse tumoral stroma (seminoma) of the left testicle composed of large, polyhedral, discretely demarcated circular cells exhibiting a large nucleus varying in size with little cytoplasm and a high mitotic rate (Figure 3D). The right testicle exhibited areas of necrosis and fibrosis of the testicular parenchyma, contiguous with

the area of degeneration and normal parenchyma, caseous necrosis, and focal calcification (Figure 3E). The liver presented some foci of the same cellular pattern of the seminoma, as described in the parenchyma (Figure 3F); several mononuclear inflammatory foci in the parenchyma; intense periportal fibrosis with biliary hyperplasia and macrophage infiltrate; intense bile stasis; swelling and vacuolization of hepatocytes; atypia of hepatocytes; and hepatic capsule thickened by fibrosis with macrophage infiltrate and dilated lymphatic vessels. Lungs exhibited edema, congestion, and thromboembolism. The spleen showed a discrete white pulp and hemosiderosis. Lymph nodes presented moderate lymphoid infiltration and hemosiderosis. The small intestine presented adhesion of duodenal villi and discrete inflammatory infiltrate at the lamina propria. The adrenals showed intense cortical and medullar hemorrhage. The kidney capsule was thickened by fibrosis, glomerular hypercellularity, hyaline casts in the lumen of tubules and ducts, multiple foci of interstitial mononuclear inflammatory infiltrate, and nephrosis.

The primary findings were seminoma in the left testicle, with metastasis to the liver; degeneration and necrosis of the right testicle with abscess and calcification; cholangiohepatitis with replication of

biliary ducts; pulmonary edema; discrete non-purulent enteritis; non-purulent multifocal interstitial nephritis; nephrosis; and adrenal hemorrhage.

## DISCUSSION

Seminoma has been described in species including dogs, horses, humans and rams with a distinct macroscopic presentation in each case [1,2,5,8]. The present findings are the second ever seminoma reported in goats, and particularly this case presented liver metastasis, showing the pathologic potential of this neoplasia for this species, and it differed from those reported previously [6] who described ulcerative lesions in, and adhesion of the skin covering the testis. The surface of the testis was smooth and the cut section firm and lobulated showing necrotic and hemorrhagic foci. The epididymis was tumorous and enlarged in size. Shortridge and Cordes [8] described seminoma in two rams. The first exhibited normal testicular shape, color, and texture, the cut surface bulged and was a uniform glistening yellow-grey, with no involvement of epididymis or skin. The second presented an enlarged testicle more firm than is typical. The tail of the epididymis surface showed smooth, nodular prominences. A firm pale brown lesion with irregular red and yellow areas, numerous small mineralized areas, and fine stroma were observed in the center of the testicle. Testis degeneration can occur locally around a lesion such as a neoplasm that expands and causes compression of neighboring tissues [4] as found in the currently described case. It was not possible to find commercial antibodies for immunohistochemistry

for fenotyping this neoplasia in the caprine species. The microscopic diagnosis was based on the cellular morphology of the seminoma, when compared to the tumoral cells described previously [4], as well as the liver presented some foci of the same tumoral stroma, identifying hepatic metastasis of the seminoma.

Ultrasound assessment showed testicular enlargement, parenchyma loss, presence of masses, cysts, echogenicity, echotexture, and intra-testicular and extra-testicular lesions. According to Marko *et al.* [5], seminomas, under gray-scale US, are hypoechoic compared with the background testis, tend to be homogeneous, and may be lobulated or multinodular, as in our US findings. Even though US cannot be considered as a conclusive diagnostic, it may help to reach a prognosis by the tumor's characteristics. Color Doppler US evaluation can also differentiate between neoplastic and non-neoplastic testicular masses by blood flow assessment, as the neoplastic testicle normally presents increased blood flow within the tumoral mass [1].

An US scan along with cytology or biopsy enables an earlier diagnosis of testicular lesions and prognosis. Orchidectomy, when unilateral, can be carried out to increase the animal's productive life.

## MANUFACTURERS

<sup>1</sup>Santisa Laboratório Farmacêutico SA. Bauru, SP, Brazil.

<sup>2</sup>Syntec, Tecnologia Farmacêutica Aplicada à Medicina Veterinária. Santana de Parnaíba, SP, Brazil.

<sup>3</sup>Reagen, Ultrapure Chemicals do Brasil Ltda. Rio de Janeiro, RJ, Brazil.

**Declaration of interest.** None of the authors has any conflicts of interest to declare.

## REFERENCES

- 1 Bigliardi E., Denti L., De Cesaris V., Bertocchi M., Di Ianni F., Parmigiane E., Bresciani C. & Cantoni A.M. 2019. Colour Doppler ultrasound imaging of blood flows variations in neoplastic and non-neoplastic testicular lesions in dogs. *Reproduction of Domestic Animals*. 54: 63-71.
- 2 Farjanikish G., Sayari M., Raisi A. & Shirian S. 2016. Diffuse type testicular seminoma in a stallion. *Comparative Clinical Pathology*. 25: 1133-1136.
- 3 Federal Council of Veterinary Medicine (CFMV). 2012. Resolução n° 1000, de 11 de Maio de 2012. Dispõe sobre procedimentos e métodos de eutanásia em animais, e dá outras providências. *Diário Oficial [da] República Federativa do Brasil*. [Source: <<http://portal.cfmv.gov.br/lei/index/id/326>>]. [Accessed online in September 2018].
- 4 Foster R. 2007. Male Reproductive System. In: Stalker J.M. (Ed). *Pathologic Basis of Veterinary Disease*. 4th edn. St. Louis: Mosby Elsevier, pp.1336-1337.
- 5 Marko J., Wolfman D.J., Aubin A.L. & Sesterhenn I.A. 2017. Testicular Seminoma and Its Mimics: From the Radiologic Pathology Archives. *RadioGraphics*. 37: 1085-1098.
- 6 Pamukçu A.M. 1954. Seminoma of the testicles in an Ankara goat. *Kafkas Universitesi Veteriner Fakultesi Dergisi*. 1: 42-46.

- 7 Prophet E.B., Mills B., Arrington J.B. & Sobin L.H. 1995.** *Métodos Histotecnológicos*. Instituto de Patologia de las Fuerzas Armadas de los Estados Unidos de América (AFIP): Registro de Patología de los Estados Unidos de América (ARP), Washington, D.C., 280p.
- 8 Shortridge E.H. & Cordes D.O. 1969.** Seminomas in sheep. *Journal of Comparative Pathology*. 79: 229-232.