



## *Schistosomus reflexus* in a Dog and a Cat

Paulo Henrique Leal Bertolo<sup>1</sup>, Maria Eduarda Bastos Andrade Moutinho da Conceição<sup>1</sup>,  
Lucien Roberta Valente Miranda de Aguirra<sup>2</sup>, Danielli Martinelli Martins<sup>2</sup>, Breno Costa de Macedo<sup>2</sup>,  
Leandro Nassar Coutinho<sup>2</sup>, Adriana Maciel de Castro Cardoso<sup>2</sup> & Washington Luiz Assunção Pereira<sup>2</sup>

### ABSTRACT

**Background:** *Schistosomus reflexus* (SR) is a congenital anomaly, that the animal presents exposed abdominal and thoracic organs. The alterations includes limbs malformation, abnormal spinal column, liver and diaphragm hypoplasia, genitourinary and gastrointestinal changes, on this way, the fetus can not survive. The aim of this study was to report the first SR case in dog and cat in Brazil, and describe anatomical, pathological and radiographic changes.

**Case:** The puppy had ventral midline defect in the abdominal and thoracic wall extending from the sternum to the pubis with viscera exposition, including the heart, lung, liver, stomach, intestine, spleen, kidneys, moreover right arm was abnormal, however no spinal column was present. It was performed radiography to evaluate bone abnormalities, and was diagnosed agenesia of carpal, metacarpal and phalange bones. The kitten had ventral midline defect measuring 4 x 2 cm, in the abdominal wall and exposition of liver, stomach, intestine and spleen, as well as tibiotarsal joint arthrogyrosis on both lags. It was performed fetus radiography and no spinal column change was diagnosed.

**Discussion:** *Schistosomus reflexus* is a congenital abnormality common in ruminants. Although it was few reported in dogs and cats. The two cases in this study are the firsts reports in Brazil in these species. In our case, the dog had exposition of abdominal and thoracic organs and died one hour after born, similar to this, another author reported a case where the thoracic and abdominal evisceration and the puppy died ten minutes after born. However, in another case with abdominal evisceration only, the puppy survived for eight days. Probably it happened because respiratory function was not compromised. The kitten had abdominal opening only, in turn, other authors reported a case whose abdominal viscera exposition was by pelvic fissure, and another case, what presented thoracic and abdominal evisceration, like our dog case. Some authors affirm that this defect causes fetal dystocia on ruminants, because of the vertebral column abnormality, what promote passage difficult at born moment. On the other hand, dogs did not present these kind of changes and dystocia was not related to this pathology on cases in dogs and cats, however most of these authors performed cesarean because the female did not get normal born. As well as, on two cases in kitten were reported vertebral column abnormalities, what can be related to dystocia. Even no animal of our study present any vertebral column abnormality, other bone changes were found, like carpal, metacarpal and phalange agenesia on arm of the dog and tibiotarsal joint arthrogyrosis on both lags of the cat fetus. The others report in dogs did not found vertebral column or bone changes, but in cats it was observed vertebral column abnormalities and other changes, like arthrogyrosis on four limbs, skull flattening, mandibular brachignathism, reduced ossification of the cranial vault bones, palatoschisis and unfused eyelids. SR etiology is not clearly known, it may be related with genetic, mechanic, endocrine, metabolic, nutrition and infectious factors. The moment of embryonic development, where these factors influence the changes is related with abnormality grade. Although, Chromosomic abnormalities, like chromatid and chromosome breaks, non-homologous pairing of chromosomes was shown. In this study the bitch did not present any metabolic, endocrine or nutritional change, on other hand the queen was submitted to exogenous hormonal treatment to avoid pregnancy, what may be related to SR development. SR is a rare abnormality in dog and cat, fetus radiographic, anatomical and pathological findings confirmed to being this congenital defect, and this are the first reports in Brazil in these species.

**Keywords:** congenital defects, canine, feline, veterinary neonatology, congenital evisceration.

## INTRODUCTION

*Schistosomus reflexus* (SR) is a congenital anomaly, that the animal presents exposed abdominal and thoracic organs [8, 9]. In some cases it can causes foetal dystocia, because conformational defects, and obstetric help or fetotomy is necessary [11].

The alterations includes limbs malformation, abnormal spinal column, liver and diaphragm hypoplasia, genitourinary and gastrointestinal changes [10,11], on this way, the fetus can not survive [8,9].

Etiology is not even known, although genetic, environment and infections are related, or more than one of them [9]. Chromosomic abnormalities, like chromatid and chromosome breaks, non-homologous pairing of chromosomes was shown in cats [10].

SR is more common in bovine [5,6,11], however it was reported in buffalo [13], ewe [2], goat [1,14], horse [12], rhinoceros [4], and few cases in cats [7,10] and dogs [8,9]. The aim of this study was to report the first SR case in dog and cat in Brazil, and describe anatomical, pathological and radiographic changes.

## CASES

**Case 1.** A 2-year-old, female, Pinscher, primigravida was admitted at Veterinary Hospital. She was being in labor for 12 h. First puppy was born after obstetric help. After 2 h it was observed fatigue, then she was submitted to a cesarean and ovarohysterectomy. There were 2 fetus, both alive, one of them was normal, and another had ventral midline defect measuring 7 x 2 cm, in the abdominal and thoracic wall extending from the sternum to the pubis with viscera exposition, including the heart, lung, liver, stomach, intestine, spleen, kidneys, moreover right army was abnormal, however no spinal column deformity was present (Figure 1A).

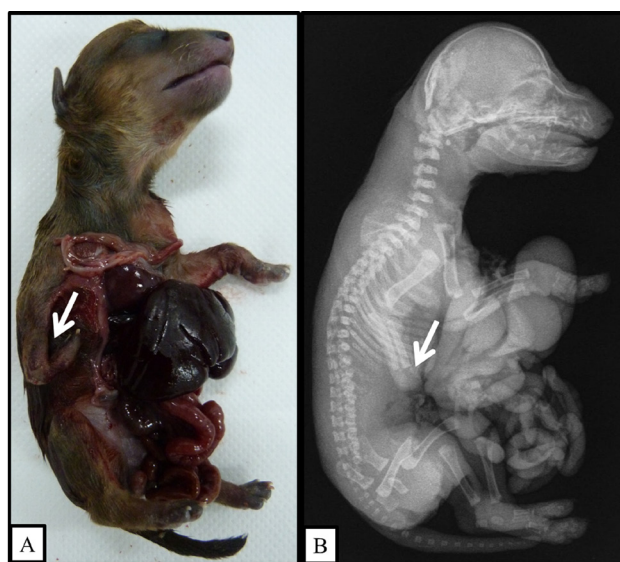
The puppy dead one hour after surgery. It was performed radiography to evaluate bone abnormalities, and was diagnosed agenesia of carpal, metacarpal and phalange bones, but no column abnormality was observed (Figure 1B).

**Case 2.** At same Veterinary Hospital of the first case was admitted a female feline, 3-year-old, cross breed, she had been in estrus 75 days before, after copulate it was administrated exogenous progesterone to avoid pregnancy.

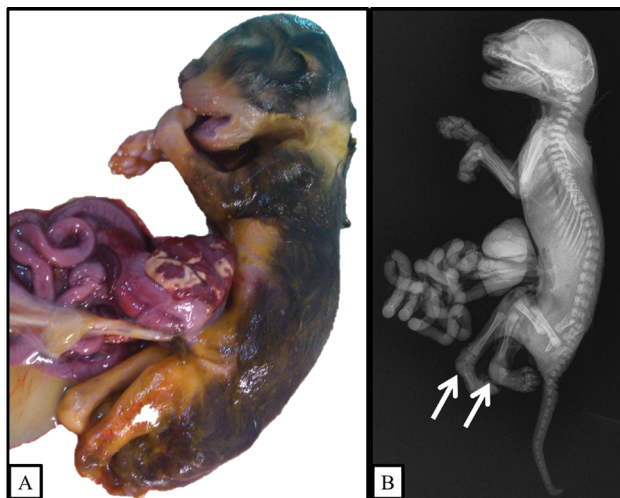
Four days before clinical attendance the cat was being in labor, but had born no kitten. She presented anorexia, adipsia, apathy, abdomen was firm and big,

on ultrasound evaluation it was diagnosed pregnancy with dead fetus.

It was performed cesarean and ovarohysterectomy, after that the fetus were evaluated and all of them was dead, although one presented abnormalities, as ventral midline defect measuring 4 x 2 cm in the abdominal wall and exposition of liver, stomach, intestine and spleen, as well as tibiotarsal joint arthrogyposis on both lags (Figure 2A). It was performed fetus radiography and no spinal column change was diagnosed (Figure 2B).



**Figure 1.** Puppy dog specimen, what presents *Schistosomus reflexus*. A- Macroscopy evaluation shown ventral midline defect with 7x2 cm in the abdominal and thoracic wall extending from the sternum to the pubis with viscera exposition, and abnormal formation of right army (arrow). B- Radiography shown agenesia of carpal, metacarpal and phalange bones (arrow).



**Figure 2.** Kitten specimen, what presents *Schistosomus reflexus*. A- Macroscopy evaluation shown ventral midline defect with 4x2 cm in the abdominal wall with viscera exposition. Tibiotarsal joint arthrogyposis on both limbs. B- Radiography diagnosed the same arthrogyposis seen in macroscopy (arrows).

## DISCUSSION

SR is a congenital abnormality common in ruminants [1,2,5,6,11,13,14]. Although it was few reported in dogs [8,9] and cats [7,10]. The two cases in this study are the firsts reports in Brazil in these species.

In our case, the dog had exposition of abdominal and thoracic organs and died one hour after born, similar to this, another author reported a case where the thoracic and abdominal evisceration and the puppy died ten minutes after born [9]. However, in another case with abdominal evisceration only, the puppy survived for eight days. Probably it happened because respiratory function was not compromised [8].

The kitten had abdominal opening only, in turn, other authors reported a case whose abdominal viscera exposition was by pelvic fissure [10], and another case, what presented thoracic and abdominal evisceration, like our dog case [7].

Some authors affirm that this defect causes fetal dystocia on ruminants, because of the vertebral column abnormality, what promote passage difficult at born moment [1,2,5,11,14]. On the other hand, dogs did not present these kind of changes and dystocia was not related to this pathology on cases in dogs and cats [7-10], however most of these authors performed cesarean because the female did not get normal born. As well as, on two cases in kitten were reported vertebral column abnormalities, what can be related to dystocia.

Even no animal of our study present any vertebral column abnormality, other bone changes were found, like carpal, metacarpal and phalange agenesis on any of the dog and tibiotarsal joint arthrogyposis on both lags of the cat fetus. The others report in dogs did not found vertebral column or bone changes [8,9], but in cats it was observed vertebral column abnormalities [10] and other changes, like arthrogyposis on four limbs, skull flattening, mandibular brachygnathism, reduced ossification of the cranial vault bones, palatoschisis and unfused eyelids.

SR etiology is not clearly known, it may be related with genetic, mechanic, endocrine, metabolic, nutrition and infectious factors. The moment of embryonic development, where these factors influence the changes is related with abnormality grade [3]. Although, Chromosomic abnormalities, like chromatid and chromosome breaks, non-homologous pairing of chromosomes was shown [10]. In this study the bitch did not present any metabolic, endocrine or nutritional change, on other hand the queen was submitted to exogenous hormonal treatment to avoid pregnancy, what may be related to SR development.

SR is a rare abnormality in dog and cat, fetus radiographic, anatomical and pathological findings confirmed to being this congenital defect, and this are the first report in Brazil in these species.

**Declaration of interest.** The authors report no conflicts of interest. The authors alone are responsible for the content and writing of the paper.

## REFERENCES

- 1 Bello A., Sonfada M.L., Umar A.A., Ja'afar A.I., Abubakar M.S., Umaru M.A., Umar A., Raji A.A., Baraya Y.S. & Abubakar A.A. 2012. *Schistosomus reflexus* in a red Sokoto doe. *Scientific Journal of Zoology*. 1(4): 79-81.
- 2 Ferreira D.O.L., Santarosa B.P., Monteiro-Toma C.D., Belotta A.F., Chiacchio S.B., Machado V.M.V., Gonçalves R.C. & Prestes N.C. 2013. Estudo anatomorfológico, radiográfico e tomográfico de *Schistosomus reflexus* em ovino da raça Dorper: relato de caso. *Arquivo Brasileiro de Medicina Veterinária e Zootecnia*. 65(4): 1096-1102.
- 3 Jubb K.V.F., Kennedy P.C. & Palmer N. 2007. *Pathology of Domestic Animals*. 5th edn. Oxford: M. Grant Maxie, 2340p.
- 4 Lankton J.S., Vanderhart D.J. & Terrel S.P. 2014. *Schistosomus reflexus*-like malformation in a southern white rhinoceros (*Ceratotherium simum simum*). *Journal of Zoo and Wildlife Medicine*. 45(3): 708-711.
- 5 Loughton K.W., Fisher K.R.S., Halina W.G. & Partlow G.D. 2005. *Schistosomus reflexus* syndrome: a heritable defect in ruminants. *Anatomia Histologia Embryologia*. 34(5): 312-318.
- 6 Macêdo J.T.S.A., Lucena R.B., Giaretta P.R., Kommers G.D., Figuera R.A., Irigoyen L.F. & Barros C.S.L. 2011. Defeitos congênitos em bovinos da Região Central do Rio Grande do Sul. *Pesquisa Veterinária Brasileira*. 31(4): 297-306.
- 7 Mateo I. & Camón J. 2008. *Schistosoma reflexum* in a cat: insights into aetiopathogenesis. *Journal of Feline Medicine and Surgery*. 10(4): 376-379.
- 8 Molina V.M., Oviedo C.A., Casado A. & Arias M.P. 2012. *Schistosomus reflexus* en un canino: reporte caso. *Revista de la Facultad de Medicina Veterinaria y de Zootecnia*. 59(1): 49-55.
- 9 Öszozy S.Y., Oto C. & Haziroglu R. 2009. *Schistosoma reflexum* in a dog. *Ankara Üniversitesi Veteriner Fakültesi Dergisi*. 56: 225-226.

- 10 Ozalp G.R., Celikler S., Simsek G., Ozyigit M.O. & Inan S. 2011.** A case of *Schistosoma reflexum* in a cat with chromosomal aberrations. *Reproduction in Domestic Animal*. 46(2): 373-376.
- 11 Prestes N.C. & Megid J. 2010.** Uma forma rara de ocorrência do *Schistosomus reflexus* em bovino - relato de caso. *Veterinária e Zootecnia*. 17(2): 214-218.
- 12 Prestes N.C., Santos R.C. & Leal L.S. 2011.** Ocorrência do *Schistosomus reflexus* em equino (relato de caso). *Brazilian Journal of Equine Medicine*. 35: 12-14.
- 13 Purohit G.N., Kumar P., Solanki K., Shekher C. & Yadav S.P. 2012.** Perspectives of fetal dystocia in cattle and buffalo. *Veterinary Science Development*. 2(8): 31-42.
- 14 Suthar D.N., Sharma V.K., Dabas V.S. & Bhoi D.B. 2011.** Per-vaginal handling of *Schistosomus reflexus* as a cause of dystocia in a Goat. *Veterinary World*. 4(7): 330-331.