



## Effects of Autohemotherapy on Hematologic Parameters and Morphology of Canine Oral Papillomatosis

Olivia Maria Moreira Borges<sup>1</sup>, Cynthia Larissa Medeiros Araújo<sup>2</sup>, Gisele Cândida Ramalho<sup>2</sup>, Rosângela Maria Nunes da Silva<sup>3</sup>, Atticus Tanikawa<sup>1</sup> & Almir Pereira de Souza<sup>3</sup>

### ABSTRACT

**Background:** Several treatments for oral papillomatosis in dogs, with satisfactory results, have already been described in the literature. However, there is need for further studies regarding remission time, association and exposure to drugs, side effects, cost-effectiveness and reproducibility of results. Autohemotherapy (AHT) is a therapeutic technique increasingly used in veterinary medicine that has been providing satisfactory clinical results to treat several pathologies. The procedure consists of removing blood by intravenous puncture that is immediately re-administered via intramuscular, subcutaneous, intravenous or intradermal. Although the empirical isolated use via intramuscular reached excellent results in routine medical treatment of dogs and since few studies and protocols have been described for this species, many times the treatment is based on the experience with the bovine papillomatosis. To this end, this report describes a case of canine oral papillomatosis treated with autohemotherapy (AHT), emphasizing the dosage and clinical evolution of the case.

**Case:** A one-year-old mongrel dog rescued from the street eight months earlier was treated. The animal was thin resulting from the small food amount ingested due to feeding difficulty, infested with ticks, had bad breath and few small warts on the lips, which, after five months, grew and multiplied, and were distributed throughout the oral cavity. The animal clinical history led to papillomatosis diagnosis, which was confirmed by cytological and histopathological exams. The AHT treatment consisted of taking 5 mL of whole blood without EDTA and immediately injecting this volume intramuscularly, every four days until the total remission of the clinical symptoms. Every four days, the papilloma fall off, and involution processes were recorded through a detailed macroscopic analysis of the warts (quantity, consistency, color and size), as well as hematological evaluations (blood count, hemoparasite screening and total plasm protein), which were performed before each AHT treatment until the complete clinical resolution of the disease (24 days).

**Discussion:** The dose adopted in this autohemotherapy study was clinically effective since the papillomas started to fall off after four days of therapy, with total resolution in 24 days. Therefore, it can be concluded that the 5 mL AHT injected intramuscularly every four days reduced treatment time and decreased therapeutic costs. There are few studies evaluating more accurately the hematological aspects related to the therapeutic use of autohemotherapy to treat canine oral papillomatosis, the existing reports are restricted to the initial measurement as an evaluation of the general condition of the patient and/or diagnosis of possible basal diseases. In this study, no changes were observed in the blood count during the entire therapeutic process, demonstrating that the AHT did not interfere in the red series dynamics of the treated animal. Additionally, thrombocytosis followed by thrombocytopenia exhibited a correlation with the macroscopic appearance of warts [enlargement and modified color, texture, shape and consistency]. This observation is possibly related to a platelet mobilization toward the site of action [warts], so that there was a modulation in the immune response, amplifying the inflammatory process and tissue repair, which resulted in the fall off and involution of the papillomas.

**Keywords:** blood, warts, neoplasia, dog.

## INTRODUCTION

Papillomatosis is a benign and opportunistic tumor, mediated by a virus of the Papillomavirus genus, which affects dogs, especially puppies. More often it is characterized by oral verrucous lesions that begin on the lips and, in the presence of immunosuppression, organic weakness or mechanical abrasion, can potentially develop and spread in the oral mucosa, tongue, palate, pharynx and epiglottis, possibly requiring an immediate clinical-surgical procedure and/or therapy, depending on the lesion extension [1,2].

Autohemotherapy (AHT) is a widely used therapeutic technique in veterinary that presents satisfactory clinical results to treat several pathologies [8]. The procedure consists of collecting a whole blood sample from the sick animal, which is administered immediately intramuscular, subcutaneous, intravenous or intradermal [8,20]. Some action mechanisms have already been suggested, emphasizing activation and subsequent potentiation of the Mononuclear Phagocytic System (SMF) [20] and immunomodulatory action [8].

The few studies describing the use of this therapy to treat oral papillomatosis in dogs are restricted to intralesional application [4] or associated with other drugs [7]. Although its isolated empirical use, intramuscularly, has shown excellent results in the medical clinic routine of canines, it is based mostly on the experience with bovine papillomatosis since there are few works and protocols described for treating dogs. Thus, this case report describes the AHT to treat a dog with oral papillomatosis, emphasizing the dosage, remission of the lesions and hematological aspects.

## CASE

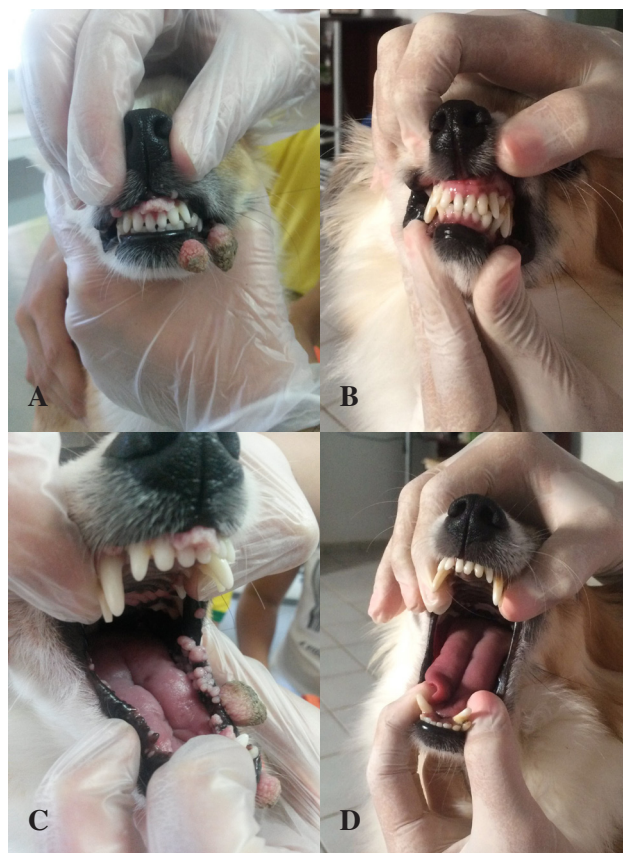A one-year-old mongrel dog, weighing 3 kg, which was not vaccinated and had been dewormed on the day before surgery, was treated in the Small Animal Clinic of the Universidade Federal de Campina Grande, Campus de Patos, PB, Brazil. The animal, which had been rescued from the street eight months earlier, was infested with ticks, thin and eating only small amounts of food with difficulty, had bad breath and few small warts on the lips, which after five months multiplied and spread throughout the oral cavity.

Physical examination revealed discreet apathy, regular body score, ocular mucous and oral mucosa slightly pale, halitosis, multiple increases of smooth to verrucous volumes. The cauliflower-like warts ranged

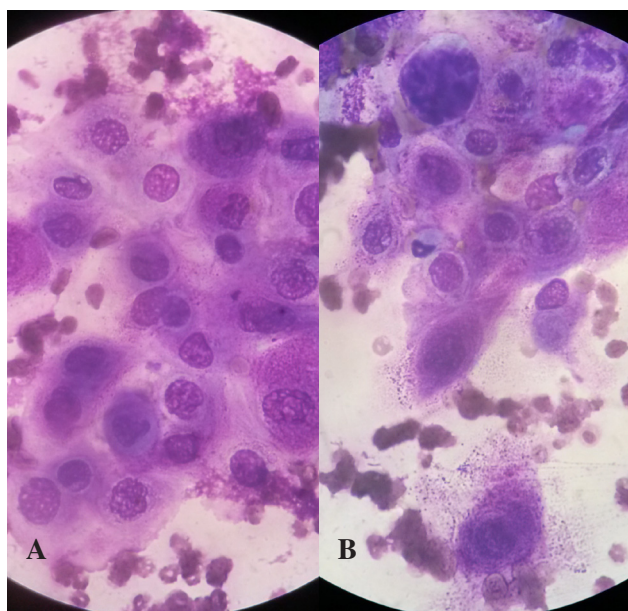
from 0.2 to 3.5 cm in size, were rosy colored, firm, located in the gingiva, oral cavity and lower and upper lips (Figure 1 A and C). The blood count results showed unchanged physiological parameters.

The history and clinical evaluation indicated a moderate-grade oral papillomatosis diagnosis [9]. Therefore, a hematological evaluation was requested [hemogram with hemoparasite (Hg + PHem) and total plasma protein (ppt), as well as cytology and biopsy of the warts. The cytological examination showed moderate cellularity composed of squamous epithelial cells in all development stages, but predominantly mature forms, which had benign-looking nuclei (Figure 2 A and B). These characteristics suggested papillomatosis diagnosis, which was confirmed in the histopathological evaluation [1,6].

The owner after being given an explanation on the therapeutic technique to be adopted authorized the treatment. The autohemotherapy consisted of aseptically collecting a 5 mL whole blood sample without anticoagulant from the jugular vein, which following trichotomy and asepsis was immediately injected



**Figure 1.** A & C- Macroscopic appearance of a dog with oral papillomatosis before AHT treatment; B & D- Absence of papillomas after 24 days of AHT treatment.



**Figure 2.** A & B- Cytological aspect of a dog with oral papillomatosis characterized by squamous epithelial cells [Panótico rápido; x1000].

intramuscularly into the semitendinosus or semimembranosus muscles. The treatment was repeated every four days, totaling 24 days of therapy (six applications).

Before each application and after completing the six applications, 1.5 mL blood samples were collected to perform new hematological evaluations [Hg + PHem and ppt], totaling seven hematological analyses (M0, M4, M8, M12, M16, M20 and M24) [Table 1]. Also, the involution process of the papillomas was followed by macroscopic analysis [size, color, texture, shape, consistency and quantity] throughout the treatment period. The regression process started

immediately, with 14 papillomas falling off, after the first application (4 days), and total disease remission after six applications (24 days) [Table 1].

After the second application, the papillomas changed color while size increased significantly. However, from the third application, the warts started to progressively reduce, change color and shape, and disappeared after 20 days of treatment (Chart 1).

The results of the blood counts showed eosinophilia in M0, a tendency to thrombocytosis (M8) at other time intervals compared to M0 and M4, followed by thrombocytopenia (M12, M16 and M20). Anemia was not observed throughout the evaluation process. No side effects were observed during the treatment, and there was no recurrence after one year.

#### DISCUSSION

Papillomatosis has been described as self-limiting while the verrucous processes in dogs regress within a period of 4 to 8 weeks after the onset of the lesions, but may occasionally remain and multiply [11]. In this case, spontaneous regression of the papillomas was not observed since the disease evolved and the warts multiplied over a period of more than five months, therefore, excluding the self-limiting hypothesis and justifying a therapeutic intervention.

Factors such as immunological immaturity, immunosuppression, and organic weakness are involved in the manifestation and development of papillomas [12]. The dog of this case report was a street animal with no history of deworming with intense eosinophilia as indicated by the initial hematological examination

**Chart 1.** Macroscopic evaluation of the involution process of oral papillomas in a dog treated with AHT.

M	Nº	Size (cm)	Layout	Texture	Color	Shape	Consistence
M0	92	0.2-3.0	individual	rough to spiculate	rosy/albescent/enegrecido	rounded/oval	firm
M4	78	0.3-1.2	individual/coalescent	rough to spiculate	rosy/albescent/enegrecido	rounded/oval	firm
M8	59	0.4-3.5	individual/coalescent	smooth	rosy to reddish	rounded	elastic
M12	21	0.2-0.4	individual/coalescent	smooth	light pink	rounded	elastic
M16	5	0.1-0.2	individual	smooth	light pink	rounded	elastic
M20	aus	aus	aus	aus	aus	aus	aus
M24	aus	aus	aus	aus	aus	aus	aus

M: moments; Nº: number of papillomas; aus: absent.



**Table 1.** Hematologic findings of a dog with oral papillomatosis treated with autohemotherapy intramuscularly every four days for 24 days.

Variable	Period of evaluation and treatment (days)							Reference Values*
	M0	M4	M8	M12	M16	M20	M24	
Red blood cells	7.15	6.87	7.08	6.78	6.33	8.01	5.96	5.5-8.5 milh/mm <sup>3</sup>
Hemoglobin	15	14	14	14	13	16	12	12-18 g/dL
Hematocrit	45	42	44	42	41	49	38	37-55 %
VCM	63.3	61.7	62.8	70	65	61.2	63.6	60-77.0 fl
CHCM	33.3	33.3	31.8	33.3	31.7	32.6	32.2	30-36 %
Leucocytes	13.700	11.650	14.700	15.650	9.900	11.400	7.800	6.000-17.000/mm <sup>3</sup>
Myelocytes	0	0	0	0	0	0	0	0-0/mm <sup>3</sup>
Metamyelocytes	0	0	0	0	0	0	0	0-0/mm <sup>3</sup>
Rods	0	0	0	0	0	0	0	0-510/mm <sup>3</sup>
Segmented	7.398	7.722	10.437	10.205	7.128	6.826	3.350	3.600-13.090/mm <sup>3</sup>
Lymphocytes	2.192	3.042	3.528	4.396	1.287	2.290	3.900	720-5100/mm <sup>3</sup>
Monocytes	411	234	294	314	396	684	400	180-1700/mm <sup>3</sup>
Eosinophils	3.699	702	441	785	998	1600	150	120-1700/mm <sup>3</sup>
Basophils	0	0	0	0	0	0	0	0-170/mm <sup>3</sup>
Platelets	208.000	202.000	410.000	91.000	180.000	136.000	215.000	200-500x10 <sup>3</sup> /mm <sup>3</sup>
ppt	6.8	7.0	7.0	7.0	6.7	7.9	7.6	5.5-8 g/dL
Hemoparasites	neg	neg	neg	neg	neg	neg	neg	negative
<i>E. canis</i> **	nr	nr	nr	neg	neg	neg	neg	negative

\*Kaneko *et al.* [10]; ppt: total plasma protein \*\*Imunocromatography for *Ehrlichia canis*; neg: negative; nr: not performed.

[M0], thus suggesting verminosis [13] as a debilitating underlying organic cause as reported by Lane & Tübbing [23]. Also, the dog was young and, therefore, immunologically immature, and the lack of vaccine protocol [9,12] may have also contributed to the worsening and evolution of the clinical symptoms.

The macroscopic characteristics observed during the initial clinical care agreed with the symptoms already described in the literature for oral papillomatosis [3,4,7,15], but a detailed macroscopic description of the involution process such as in this study (Table 1) has not been addressed to our knowledge [3]. Such characterization is necessary so that the clinician has a better perception and can correlate the evolution of the clinical symptoms with the therapeutic efficacy, especially when using AHT.

The diagnosis of canine papillomatosis is routinely supported by clinical-epidemiological findings [15]. However, due to similar macroscopic characteristics, it should be differentiated from fibromatous epulides, transmissible venereal tumor and squamous

cell carcinoma [16]. Therefore, to determine the therapeutic procedure to be adopted, other complementary diagnostic methods should be performed, especially the histopathological and immunohistochemical analyses [1,6]. In this report, although the histopathological findings confirmed the clinical suspicion, the cytological findings allowed an early diagnosis [17], speeding up the beginning of the clinical-therapeutic conduct.

The dosage adopted for the AHT in this study was clinically effective since the papillomas started to fall off after four days of therapy and had total resolution in 24 days, evidencing the stimulating immunological potential of the therapy [8,18,19]. This finding may be better elucidated compared to other studies involving AHT, in which the remission onset was observed after seven days and total resolution between 24-30 days [4,7]. Thus, the 5 mL intramuscular application every four days reduced treatment time and decreased therapeutic costs.

Few studies evaluate more accurately the hematological aspects related to the use of autohemotherapy

to treat canine oral papillomatosis, being restricted to the initial measurement as an evaluation of the general state of the patient and/or diagnosis of possible basal diseases [4,6,7]. In this study, the blood counts remained unchanged during the entire therapy process, demonstrating that the protocol adopted did not interfere in the dynamics of the red cells of this animal.

The increased platelets observed at M8 followed by thrombocytopenia from M12 to M20 was correlated with the evolution of the macroscopic appearance of warts, with an increase in size and modification in color, texture, shape and consistency. This dynamics is possibly related to a platelet mobilization to the action site (warts), so that these modulate the immune response, aiding in the amplification of the inflammatory process and tissue repair [22], mediating the fall and involution of the papillomas.

This report shows the importance of performing more dosage studies involving intramuscular autohemotherapy in dogs with oral papillomatosis, emphasizing and correlating the relationship between the period of application intervals and the precocity of remission of the clinical symptoms.

#### CONCLUSION

Autohemotherapy applied at four-day intervals proved to be effective to treat a dog with moderate oral papillomatosis, with no clinical and laboratory side effects, and complete remission after 24 days of treatment. The role of platelets in immune modulation and tissue repair should be further investigated, especially in the therapeutic involvement with AHT.

**Declaration of interest.** The authors state that there is no conflict of interest. Only the authors are responsible for the content and writing of this manuscript.

#### REFERENCES

- 1 Bredal W.P., Thoresen S.I., Rimstad E., Aleksandersen M. & Nafstad P.H. 1996.** Diagnosis and clinical course of canine oral papillomavirus infection. *Journal of Small Animal Practice*. (37): 138-142.
- 2 Fenner F., Gibbs E.P.J., Murphy F.A., Rott R., Studdert M.J. & White D.O. 1993.** *Veterinary Virology*. 2nd edn. London: Academic Press, 666p.
- 3 Fantini O., Videmont E. & Pin D. 2015.** Successful treatment of florid papillomatosis in a dog using subcutaneous feline recombinant interferon- $\omega$ . *Revue de Médecine Vétérinaire*. 166(1-2): 25-29.
- 4 Bambo O., Cardoso J.M.M., Dimande A. & Santos I.F.C. 2012.** Auto-hemoterapia no tratamento da papilomatose oral canina - Relato de caso. *Revista de Educação Continuada em Dermatologia e Alergologia Veterinária*. 2(2): 39-43.
- 5 Lira R.N., Lempek M.R., Marinho P.V.T., Neves C.C.N. & Trombini H.R. 2012.** Uso de *Thuya occidentalis* no tratamento da Papilomatose oral canina. *PUBVET*, Londrina. 6(16): 1360.
- 6 Fernandes M.C., Ribeiro M.G., Fedato F.P., Paes A.C. & Megid J. 2009.** Papilomatose oral em cães: revisão da literatura e estudo de doze casos. *Semina: Ciências Agrárias*, Londrina. 30(1): 215-224.
- 7 Cesarino M., Ávila D.F., Fernandes C.C., Silva C.B., Scherer D.L., Dias T.A., Mendonça C.S. & Castro J.R. 2008.** Efeito da autohemoterapia associada com clorobutanol no tratamento da papilomatose oral em cão (*Canis familiaris*). *Arquivo Brasileiro de Medicina Veterinária e Zootecnia*. (46): 145-148.
- 8 Borges O.M.M., Silva R.M.N., Mendes R.S. & Souza A.P. 2014.** Auto-hemoterapia, uma nova ou antiga alternativa terapêutica? Revisão de literatura. *Medvop - Revista Científica de Medicina Veterinária - Pequenos Animais e Animais de Estimação*. 12(39): 32-40.
- 9 Yaci B.B., Ural K., Öcal N. & Haydardedeolu A.E. 2008.** Azithromycin therapy of papillomatosis in dogs: a prospective, randomized, double-blinded, placebo-controlled clinical Trial. *The Authors. Journal compilation*. (19): 194-198.
- 10 Kaneko J.J., Harvey J.W. & Bruss M.L. 2008.** *Clinical Biochemistry of Domestic Animals*. 6.ed. Rio de Janeiro: Elsevier, 905p.
- 11 Calvert C.A. 2003.** Canine viral papillomatosis. In: Greene E.C. (Ed). *Infectious diseases of the dog and cat*. 3rd edn. Philadelphia: W.B. Saunders Company, pp.288-290.
- 12 Wall M. & Calvert C.A. 2006.** Canine viral papillomatosis. In: Greene C.E. (Ed). *Infectious disease in the dog and cat*. 3rd edn. Philadelphia: W.B. Saunders, pp.73-78.
- 13 Silva B.J.A., Freire I.M.A., Silva W.B. & Amarante E.E.V.G. 2010.** Avaliação das alterações hematológicas nas infecções por helmintos e protozoários em cães [*Canis lupus familiaris*, Linnaeus, 1758]. *Neotropical Helminthology*. 4(1): 37-48.

- 14 Santos F, Coppede J.S. Pereira A.L., Oliveira L.P., Roberto P.G., Benedetti R.B., Zucoloto L.B., Lucas F., Sobreira L. & Marins M. 2009.** Molecular evaluation of the incidence of *Ehrlichia canis*, *Anaplasma platys* and *Babesia* spp. in dogs from Ribeirão Preto, Brazil. *The Veterinary Journal*. 179(1): 145-148.
- 15 Oliveira N.F., Melo M.M. & Lago L.A. 2002.** Papilomatose. *Arquivo Brasileiro de Medicina Veterinária e Zootecnia*. (74): 14-15.
- 16 Tilley L.P. & Francis W.K. 2015.** *Consulta Veterinária em 5 min*. 5.ed. São Paulo: Manole, 1560p.
- 17 Raskin R.E. & Meyer D.J. 2011.** *Citologia clínica de cães e gatos*. 2.ed. Rio de Janeiro: Elsevier, 472p.
- 18 Moura L. 2006.** *Auto-hemoterapia: conversa com o Dr. Luiz Moura*. Disponível em: <[http:// www.rnsites.com.br/auto-hemoterapia-dvd.htm](http://www.rnsites.com.br/auto-hemoterapia-dvd.htm)>. [Accessed online in December 2016].
- 19 Klemparskaya N.N., Shalnova G.A., Ulanova A.M., Kuzmina T.D. & Chuhorv A.V. 1986.** Immunomodulating effect of autohaemotherapy [a literature review]. *Journal Hygiene, Epidemiology, Microbiology and Immunology*. 30(3): 331-336.
- 20 Mettenleiter M.W. 1936.** Autohemotransfusion in preventing postoperative lung complications. *American Journal of Surgery*. 32(2): 321-323.
- 21 Teixeira J. 1940.** Complicações Pulmonares Pós-Operatórias Autohemotransusão. *Revista Brasileira de cirurgia*. 2(3): 213-230.
- 22 Semple J.W., Italiano J.E.J. & Freedman J. 2011.** Platelets and the immune continuum. *Nature Reviews Immunology*. 11(4): 264-74.
- 23 Lane E.P. & Tübbesing U. 2007.** Multiple cutaneous inverted papillomas in a dog. *Journal of the South African Veterinary Association*. 78(4): 221-223.