



## Eyelid Apocrine Hidrocystomas in a Cat

João Antonio Tadeu Pigatto, Luciane de Albuquerque, Michelle Petersen Becker,  
Tanise Carboni da Silva & David Driemeier

### ABSTRACT

**Background:** Eyelid apocrine hidrocystoma (AH) is a benign cystic lesion originating from the glands of Moll. These eyelid lesions are rare in cats and there are few cases reported in the literature. The aetiopathogenesis of AH is unknown and the lesion has been interpreted either as proliferative adenomatous tumour or as retention cyst. Definitive diagnosis requires biopsy with microscopic examination. Treatment options for eyelid AH include surgical excision, drainage through aspiration, cryosurgery with liquid nitrogen and chemical ablation. The aim is to report a case of bilateral multiple AH of the eyelids in a cat that was successfully treated with surgical excision.

**Case:** A 5-year-old male Himalayan cat was referred to the Ophthalmology Section in the Veterinary Clinics Hospital of the Federal University of Rio Grande do Sul (UFRGS), Porto Alegre, RS, Brazil with a history of pigmented masses in both eyes that had been progressively enlarging over a 1-year period. Ophthalmic examination revealed two cysts on the medial canthus at the eyelid margin in both eyes. In the left eye was observed mild blepharospasm and lacrimation. Cysts were soft, smooth, round and filled with a dark brownish pigment. The remainder of the ophthalmic examination was unremarkable. Surgical excision of the cysts was indicated with a safety margin. The surgical procedure was performed under inhalation anaesthesia using an operating microscope. A V-shaped, full-thickness excision of the eyelid containing the cyst was performed. The eyelids were closed with two layers of sutures. No complications were noted during surgery. Microscopic examination revealed cystic dilatation of the sweat glands with a large amount of eosinophilic secretion. Eyelid AH was diagnosed based on the results to confirm the diagnosis. The cat recovered and was discharged the following day. The postoperative treatment involved the administration of tramadol (2 mg/kg, PO, q 12 h) daily for 3 days. After surgery, the cat had no signs of ocular discomfort. After three years, no recurrence has been observed.

**Discussion:** AH is a benign tumour derived from Moll's glands. The exact aetiology of AH is unknown. A breed-specific predisposition among Persian cats has been suggested. In the present case, the ophthalmic examination revealed periocular masses brownish to black, round, soft, and fluid-filled. Multiple pigmented nodules involving the skin of the lower eyelids were observed. In the current case, the cat was of the Himalayan breed and was 5 years old with multiple AH in both eyelids. In terms of clinical features, this case was similar to previous ones reporting eyelid AH in cats. Normally, a definitive diagnosis is confirmed through histopathology after excisional biopsy. In the current case, diagnosis was made on the basis of the clinical findings, history, and results of histological examination. Treatment options for eyelid AH include surgical excision, aspiration, cryosurgery and chemical ablation with trichloroacetic acid. Surgical removal of the cysts was performed in the current case. Histopathologic examination revealed cystic dilatation of the sweat gland with large amount of eosinophilic secretion. The sutures were removed one week after surgery. Periodic evaluations were conducted and there were no signs of recurrence after three years. In the present case, surgical excision was effective in the treatment of eyelid AH in a cat.

**Keywords:** lid, cystic adenomas, feline.

## INTRODUCTION

The majority of eyelid tumours in cats are malignant, with squamous cell carcinoma being the most prevalent [5,8]. Benign cystic lesions of the eyelid have been reported mainly in humans and cats [1-4]. The aetiopathogenesis of eyelid AH is unknown and lesions have been interpreted as retention cysts caused by excretory duct obstruction [2,9]. Eyelid AH have been reported, mostly in Persian cats, although they have been described in domestic shorthairs and a Himalayan [3,6,10]. Grossly, they were described as raised and darkly pigmented masses [8]. Normally, signs of pain were not evident. Although clinical signs and cytology may be suggestive of AH, its definitive diagnosis requires biopsy with microscopic examination. Treatment options for eyelid AH include surgical excision, drainage through aspiration, cryosurgery with liquid nitrogen and chemical ablation [2,6,11]. Only few cases of eyelid AH have been reported in cats [2-4,6,10,11]. Based on information available in the literature, this is the first case of eyelid AH in a cat to be documented in South America.

## CASE

A 5-year-old male Himalayan cat was referred to the Ophthalmology Section in the Veterinary Clinics Hospital of the Federal University of Rio Grande do Sul (UFRGS), Porto Alegre, RS, Brazil with a history of pigmented masses in both eyes that had been progressively enlarging over a 1-year period. The cat was well-nourished and presented good clinical condition. The cat was visually unimpaired with pupillary normal light reflexes in its both eyes (OU). Ophthalmic examination revealed two cysts on the medial canthus at the eyelid margin in both eyes (Figure 1). In the left eye was observed blepharospasm and lacrimation. In that eye,



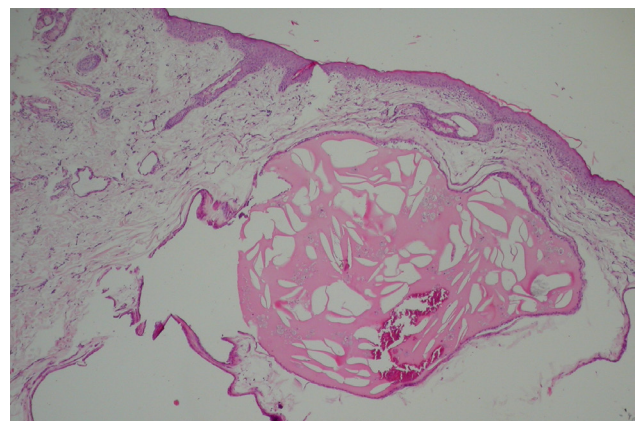
**Figure 1.** Cat on presentation. Cysts on the medial canthus at the eyelid margin in both eyes.

two dark-brown lesions of variable size (2 to 6 mm in diameter) were observed on the medial canthus. In the right eye, there were two black rounded cysts (2 to 5 mm in diameter) near the medial canthus. In this eye, the cat did not show any signs of discomfort. Cysts were soft, smooth, round and filled with a dark brownish pigment.

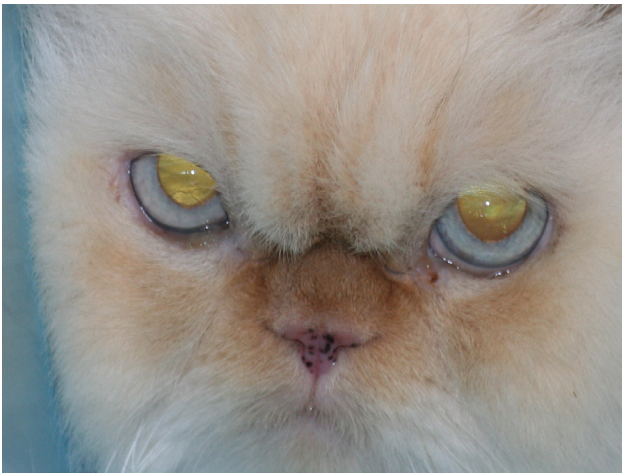The remainder of the ophthalmic examination was unremarkable. Physical examination was normal. Complete blood cell count and serum chemical profiles were unremarkable. Surgical excision of the cysts was indicated with a safety margin. The surgical procedure was performed under inhalation anaesthesia, using an operating microscope. A V-shaped, full-thickness excision of the eyelid containing the cyst was performed. The eyelid was closed with 2 layers of sutures. The tarsoconjunctival layer was sutured with 5-0 polyglactin 910 (Vicryl)<sup>1</sup>, and the skin with 5-0 mononylon (Mononylon)<sup>1</sup>. A similar surgical procedure was performed on the left eyelid.

The resected tissues were placed in 10% buffered formalin and submitted for histological examination in the Sector of Veterinary Pathology (SVP), Faculdade de Veterinária (FaVet), Universidade Federal do Rio Grande do Sul (UFRGS), Porto Alegre, RS, Brazil. Histopathological examination revealed cystic dilatation of the sweat glands with a large amount of eosinophilic secretion (Figure 2). Moreover had negative images of cholesterol clefts in the rosy liquid proteinaceous cyst. Eyelid AH was diagnosed based on the results to confirm the diagnosis.

After surgery, the cat was treated with tramadol (Dorless V)<sup>2</sup> [2 mg/kg], PO, q 12 h for three days. The cat recovered and was discharged the following day. Following surgery, the cat was comfortable, and the skin suture was removed in 10 days. Three years after surgery, the cat was clinically normal without evidence of recurrence (Figure 3).



**Figure 2.** Histological appearance of the AH. Cystic dilatation of the sweat glands with a large amount of eosinophilic secretion. [H&E ×40].



**Figure 3.** Macroscopic view of the cat three years after surgical procedure.

### DISCUSSION

In humans, AH may occur over multiple parts of the body, including the scalp, chest, shoulders, feet, face and eyelids [1,9]. AH in cats occur most commonly on the head, neck and limbs [7]. Hidrocystomas originate from apocrine sweat glands of Moll and those involving the eyelid margin are a rare condition in cats [5,8]. The aetiopathogenesis of AH is unknown, but two main theories can be found in the literature. Epithelial flattening and dermal fibrosis around cystic structures apparently support the hypothesis of a retention cyst [2]. High proliferative indices and papillary projections have been considered features of neoplastic transformation [2].

Most cases of feline eyelid AH reported so far have been in Persians cats, suggesting a breed-specific predisposition [2,4]. Cases have been reported in domestic shorthairs and one in a Himalayan [3,10]. Eyelid AH have been reported in cats between 3 and 15 years old [6]. They occur as single or multiple lesions on the lid margin involving one or both eyelids [4]. In the current case, the cat was of the Himalayan breed and was 5 years old with multiple AH in both eyelids. In terms of clinical features, this case was similar to previous ones reporting eyelid AH in cats.

Clinical signs of palpebral AH will depend on the size and location of the cysts, and may include blepharospasm, lacrimation, conjunctival hyperemia, and ocular discharge [2,11]. In this case, some of these clinical signs were observed. Fine-needle aspiration has been performed for the diagnosis of lid AH in cats [6]. Aspirated fluid from AH contains mostly reactive macrophages with phagocytized pigment, arranged in dark intracellular granules [6]. Fine-needle aspiration is a technique that may be

useful in the differential diagnosis of AH and malignant eyelid lesion [2,6].

In this described case, fine needle aspiration cytology was considered, but not performed. Because the cyst was causing discomfort, excisional biopsy was performed. Although cytology may be suggestive of AH, a definitive diagnosis requires biopsy and histopathological examination [4,6,11]. In the present case, the diagnosis of AH was confirmed by histopathology. The histological appearance was similar to that previously described. Because these cysts were described clinically as darkly pigmented, it has been suggested that melanomas should be considered as a differential diagnoses [2].

Treatment options for eyelid AH mainly include surgical excision, cryosurgery using liquid nitrogen and chemical ablation [2-4,11]. Depending on the tumour growth rate and age of the patient, it may be appropriate to observe the tumour. At present, knowledge of the success rate in the treatment of eyelid AH in cats is limited [10]. In a recent study, cyst aspiration was performed. This procedure was accompanied by a reduction in the size of the cyst and a temporary therapeutic effect [6]. In a case where AH was treated by drainage, the cysts recurred seven months after drainage [3]. A case report described the treatment of eyelid AH in a cat by debridement and topical treatment with 20% trichloroacetic acid [11]. In the present report, surgical removal of lid AH was indicated due to discomfort observed in the cat's left eye. Considering that the cyst in the right eye may have enlarged and caused discomfort, these were also surgically removed. Besides reducing patient discomfort, with the surgical excision of AH it was possible to perform a histopathological assessment and confirm the diagnosis. In a report where treatment consisted of surgical removal of the cysts, the cat developed additional cysts five years after the initial surgery [3]. In the present case, the cat was followed for three years and we have not yet seen signs of recurrence or the development of new cysts.

Surgical excision was effective for the treatment of AH in the eyelid of a cat. AH must be considered in the differential diagnosis of neoplasm that affects the eyelid in cats.

### MANUFACTURERS

<sup>1</sup>Ethicon - Johnson & Johnson do Brasil. SP, Brazil.

<sup>2</sup>Agener União Saúde Animal. Brasília, DF, Brazil.

**Declaration of interest.** The authors report no conflicts of interest. The authors alone are responsible for the content and writing of the paper.

REFERENCES

- 1 Alessi E., Gianotti R. & Coggi A. 1997. Multiple apocrine hidrocystomas of the eyelids. *British Journal of Ophthalmology*. 137: 642-645.
- 2 Cantaloube B., Raymond-Letron I. & Regnier A. 2004. Multiple eyelid apocrine hidrocystomas in two Persian cats. *Veterinary Ophthalmology*. 7(2): 121-125.
- 3 Chaitman J., Van Der Woert A. & Bartick T.E. 1999. Multiple eyelid cysts resembling apocrine hidrocystomas in three Persian cats and one Himalayan cat. *Veterinary Pathology*. 36(5): 474-476.
- 4 Giudice C., Muscolo M.C., Rondena M., Crotti A. & Grieco V. 2009. Eyelid multiple cysts of the apocrine gland of Moll in Persian cats. *Journal of Feline Medicine & Surgery*. 11: 487-491.
- 5 Hesse K.L., Fredo G., Guimarães L.L.B., Reis M.O., Pigatto J.A.T., Pavarini S.P., Driemeier D. & Sonne L. 2015. Neoplasmas oculares e de anexos em cães e gatos no Rio Grande do Sul: 265 casos (2009 -2014). *Pesquisa Veterinária Brasileira* 35(1): 49-54.
- 6 Kahane N., Ofri R., Prager O., Louka M. & Aroch I. 2014. Apocrine hidrocystoma in four Persian cats. *Israel Journal of Veterinary Medicine*. 69(1): 29-34.
- 7 Scott D.W. 2001. Neoplastic and non-neoplastic tumors. In: Muller and Kirk's *Small Animal Dermatology*. 6th edn. Philadelphia: WB Saunders, pp.1379-1381.
- 8 Newkirk K.M. & Rohrbach B.W. 2009. A retrospective study of eyelid tumors from 43 cats. *Veterinary Pathology*. 46: 916-927.
- 9 Shields J.A., Eagle R.C., Shields C.L. De Potter P. & Markowitz G. 1993. Apocrine hidrocystoma of the eyelid. *Archives of Ophthalmology*. 111: 866-867.
- 10 Sivagurunathan A., Goodhead A.D. & Du Plessis E.C. 2010. Multiple eyelid apocrine hidrocystoma in a domestic short-haired cat. *Journal of the South African Veterinary Association*. 81(1): 65-68.
- 11 Yang S.H., Liu C.H., Hsu C.D., Yeh L.S. & Lin C.T. 2007. Use of chemical ablation with trichloroacetic acid to treat eyelid apocrine hidrocystomas in a cat. *Journal of the American Veterinary Medical Association*. 230(8): 1170-1173.

