



Tenorrhaphy of the Common Calcaneal Tendon in Dogs and Cats

Ísis dos Santos Dal-Bó, Cássio Ricardo Auada Ferrigno, Aline Schafrum Macedo, Fernanda Paes, Jaqueline França dos Santos, Paulo Vinícius Tertuliano Marinho, Thales Bregadioli & Viviane Sanchez Galeazzi

ABSTRACT

Background: Common calcaneal tendon (CCT) is usually affected by injuries in dogs and less frequently in cats. The Achilles mechanism consists of the convergence of three distinct structures: the tendons of the gastrocnemius muscle, superficial digital flexor muscle and the common tendons of the biceps femoris, gracilis, and semitendinosus muscles. Classification of lesions is based upon their location, severity and chronicity. Clinical signs include lameness, plantigrade stance and various degrees of tarsal hyperflexion according to the injury's severity. The purpose of this study is to report four cases of reconstruction of the common calcaneus in three dogs and a cat.

Cases: *Case 1.* A 10-year-old male canine, Brazilian Terrier, 7.7 kg of body weight, with a 6-month history of nonweight-bearing lameness of the right hind limb attended consultation. Orthopedic examination showed plantigrade stance, hyperflexion of the right tibial-tarsal joint (TTJ) and swelling with fibrous thickening of the distal portion of the CCT. Surgical tendon repair was achieved through insertion of a locking screw on the calcaneo-tibial, tenorrhaphy and suture of a titanium plate on the caudal aspect of the CCT. *Case 2.* A 2-year-old female mongrel canine, with 13.3 kg of body weight was presented with the complaint of chronic left hind leg lameness. The owner described trauma at the area of the hock six months prior to consultation. On orthopedic exam, severe lameness was noted, swelling with fibrous thickening of the distal portion of the common calcaneal tendon and hyperflexion of the left TTJ (plantigrade position) were visible. Tendon repair was performed in the same manner as in case 1, except that in this case a bovine pericardium graft preserved in glycerin 98% was sutured over the tendon/plate junction. *Case 3.* A 6-year-old female mongrel canine, with 18.6 kg of body weight was attended with a 22-day history of right hind limb lameness. On physical exam intermittent lameness during gait performance and non-weight-bearing position in stance were noted. The distal portion of the limb was internally rotated with plantigrade stance and discontinuity of the CCT was palpable. Tenorrhaphy was performed similarly to case 2. *Case 4.* A 6 kg, 3-year-old, mixed breed male feline was admitted with a wound on the CCT region for 7 days. The wound was originated after animal interaction with a stray feline. On clinical examination the animal was non-weight bearing on the right hind limb, with plantigrade posture and with a 1 cm wound on the caudal portion of the CCT with tendon exposure. Surgical repair was performed by tenorrhaphy with placement of a surgical steel plate on the caudal aspect of the CCT. A bovine pericardium graft preserved in glycerin 98% was sutured on top of the plate. The TTJ was immobilized with a type II transarticular external fixator.

Discussion: Ultrasonography is the test of choice to monitor tendon healing after tenorrhaphy. At this report, this exam was crucial to determine when the calcaneo-tibial screw could be removed. Two dogs and the cat from this report received an association of plate and bovine pericardium preserved in glycerin 98%. The purpose of this association was to increase the strength of the tenorrhaphy, and the pericardium graft had also the function of reducing the formation of peritendinous adhesions. Immobilization of the TTJ has the purpose of opposing muscle forces to avoid stress at tenorrhaphy suture increasing the strength of the healed tendon allowing early weight bear while minimizing the recurrence risk and avoiding limb contracture. We chose to perform the procedure with hyperextension of the TTJ in order to promote greater relaxation of the tendon since there was need to remove large portions of calcaneal fibrous tissues of the dogs and devitalized tissue in the cat from this report. Surgical treatment of injuries of the Achilles mechanism has good prognosis in complete closed lesions treated by tenorrhaphy associated with suture of a plate, suture of bovine pericardial graft preserved in 98% glycerin, calcaneo-tibial locking screw and splint for six weeks.

Keywords: Achilles tendon, rupture, calcaneo-tibial screw, locking-loop suture pattern.

Received: 4 March 2016

Accepted: 12 July 2016

Published: 4 August 2016

Laboratório de Ortopedia e Traumatologia Veterinária (LOTVC), Departamento de Cirurgia (VCI), Faculdade de Medicina Veterinária e Zootecnia (FMVZ), Universidade de São Paulo (USP), São Paulo, SP, Brazil. CORRESPONDENCE: Í.S. Dal-Bó [idb_vet@yahoo.com.br - Tel.: +55 (11) 30911229]. Faculdade de Medicina Veterinária e Zootecnia - USP. Av. Prof. Dr. Orlando Marques de Paiva n. 87. Bairro Cidade Universitária. CEP 05508 270 São Paulo, SP, Brazil.

INTRODUCTION

The common calcaneal tendon (CCT), or Achilles mechanism, is one of the most affected tendon by injuries in dogs [8], however, in cats is less common [1]. The etiology of most injuries are related to sharp object trauma, motor vehicle accidents and pet fights or aggressive interaction [8]. There is description of degenerative lesions in large breed dogs [2].

The CCT consists of the convergence of three distinct structures: the tendons of the gastrocnemius muscle (GT), superficial digital flexor muscle (SDFT) and the common tendons (CT) of the biceps femoris, gracilis, and semitendinosus muscles [5,7]. The major component the GT [11]. The anatomy of this mechanism in cats is nearly identical to that of the dogs [1].

Grading of lesions is based upon their location and severity. They are classified in three types. Type I: complete tendon disruption. Type II: subdivided into three subtypes, type IIa - muscle-tendon disruption; type IIb - CCT rupture with preservation of the paratenon and type IIc - partial GT avulsions with the SDFT intact. Type III: partial disruption or peritendinitis [4]. Acute injuries are those that occur within 48 hours, subacute between two and 21 days and chronic injuries are those with more than 21 days [1].

Clinical signs include lameness, plantigrade stance with concurrent stifle extension in complete ruptures whereas partial ruptures lead to various degrees of tarsal hyperflexion, according to the injury's severity. It is also possible to observe digital bending with a claw-like appearance in isolated lesions of the GT or common tendon if the SDFT is spared [1,7].

Surgical repair by tenorrhaphy in conjunction with internal immobilization of the tibiotarsal joint (TTJ) or splint has been advocated for satisfying results with appropriate return to function. In chronic cases or in severe tissue loss, tissue grafts may be useful [8].

The purpose of this study is to report three cases of reconstruction of the common calcaneus tendon in dogs and one in a cat.

CASES

Case 1. A 10-year-old male canine, Brazilian Terrier, 7.7 kg of body weight was attended with a 6-month history of nonweight-bearing lameness of the right hind limb (RHL). Orthopedic examination showed plantigrade stance, hyperflexion of the right TTJ and swelling with fibrous thickening of

the distal portion of the calcaneal tendon with a scar on the tendon's lateral aspect suggesting old trauma. Ultrasonography (US) of the CCT region displayed heterogeneous increased volume and signs of fibrous thickening in the distal portion of the Achilles mechanism and hypoechoic areas with discrete irregularities on its insertion. Radiographic findings of the TTJ displayed altered CCT silhouette. Tendon repair was surgically performed by caudolateral skin incision and immobilization of the right TTJ was achieved through insertion of a 2.7 mm locking screw from the calcaneus towards the distal portion of the right tibia. All the grossly abnormal fibrous tissue was removed from the calcaneal tendon and tenorrhaphy was performed with Bunnell pattern with nylon monofilament (NM) size 0 followed by placement of a 5-hole 2.0 mm titanium plate on the caudal aspect of the CCT by use of 4-0 NM with isolated simple pattern. All tissues were apposed in regular fashion with 3-0 NM. A modified Robert Jones bandage was used with a stiff component (thermoplastic material Scotchcast®)¹, and was maintained for six weeks. Cephalexin, metamizole, tramadol, carprofen and omeprazole were prescribed. After nine postoperative (PO) days, skin suture dehiscence occurred. After 15 days PO, exposure of the calcaneo-tibial screw occurred. Antimicrobial agent was changed to enrofloxacin and the patient was discharged without splint, but with rest recommendations. Weight bearing on the affected limb was observed at 30 days PO. Removal of the calcaneal screw occurred at 90 days PO, with no need for plate removal. Every three months after surgery the dog was evaluated and after 1 year postoperatively it was active and grade I intermittent lame and was discharged without any postural changes or pain on palpation.

Case 2. A two-year-old female mongrel canine, with 13.3 kg of body weight was presented with the complaint of a 6-month left hind limb (LHL) lameness after collision with the garage door. On orthopedic exam, grade V/V lameness was noted, swelling with fibrous thickening of the distal portion of the CCT and hyperflexion of the left tibial-tarsal joint (TTJ) - plantigrade position - were visible. At US exam it was possible to identify CCT's enlarged heterogeneous branches with misalignment of fibers, partial healing and stump formation with peripheral tissue reaction; insertion region was unaltered. Radiographic exam displayed CCT's silhouette augmentation on the distal

portion compared to contralateral side. Tendon repair was performed similar to case 1. A caudolateral skin incision was made and immobilization of the left TTJ was achieved through insertion of a 3.5 mm locking screw from the calcaneus towards the distal portion of the left tibia. All the grossly abnormal fibrous tissue was removed from the calcaneal tendon and tenorrhaphy was performed with no 2 polypropylene suture in locking loop pattern, followed by placement of a 7-hole 2.0 mm titanium plate on the caudal aspect of the CCT by use of 3-0 NM with isolated simple pattern. Also a bovine pericardium graft preserved in 98% glycerin was sutured over the tendon/plate conjunction by use of 4-0 NM in isolated simple pattern. All tissues were apposed in regular fashion with 3-0 NM. Postoperative care and treatment was the same as case 1, except that the patient was kept with splint for 6 weeks. After 15 days PO the patient was bearing weight on the affected limb. US exam performed at 50 days PO displayed healed CCT although there was a wound over the screw and distal portion of the plate. Both implants were removed at the 70th day PO. Patient was discharged at the 90th day PO with satisfactory limb usage.

Case 3. A six-year-old female mongrel canine, with 18.6 kg of body weight was attended with a 22-day history of RHL lameness. On physical exam intermittent lameness during gait performance and non-weight-bearing position in stance were noted. The distal portion of the limb was internally rotated with plantigrade stance and discontinuity of the CCT was palpable. Radiographs of the right TTJ showed an increased silhouette of the distal portion of the CCT (about 1.2 cm in diameter compared to 0.6 cm on the contralateral side). Tenorrhaphy was performed similarly to case 2, except that about 0.5 cm of the grossly abnormal fibrous tissue was removed from each extremity of the right CCT and tenorrhaphy was performed with no 0 NM followed by placement of a 6-hole 2.0 mm titanium plate on the caudal aspect of the CCT and also a bovine pericardium graft preserved in 98% glycerin was sutured over the tendon/plate conjunction. Postoperative care and treatment was the same as case 2. After 8 days PO the patient was bearing weight on the affected limb. US exam performed at 30 days PO displayed healing of the CCT. Transarticular screw was removed at 45 days PO and patient discharge occurred after 120 days PO, with a slight restriction on range of motion of the TTJ.

Case 4. A 6 kg, 3-year-old, mixed breed male feline was admitted with a wound on the CCT region for 7 days treated with sulfamethoxazole and trimethoprim, metamizole and daily wound dressings. The wound was originated after animal interaction with a stray feline. On clinical examination the animal was non-weight bearing on the right hind limb, with plantigrade posture and had a 1 cm wound on the caudal portion of the CCT with tendon exposure. Complete CCT rupture was observed at US exam. Tenorrhaphy was performed similarly to case 3, all the grossly abnormal fibrous tissue was removed from each extremity of the right CCT and tenorrhaphy was performed with no 3-0 NM with locking loop pattern with placement of a 6-hole 2 mm steel plate. Bovine pericardium graft preserved in 98% glycerin was also sutured over the tendon/plate conjunction. TTJ was immobilized with a type II transarticular external skeletal fixator (TESF). After wound debridement was performed all tissues layers were sutured and a bandage to cover the TESF was made with two Steinmann pins and two Schanz pins on the tibia, one Schanz pin located at the calcaneus and two Steinmann pins in the metatarsals. Tissue samples were sent to culture exam and antimicrobial susceptibility testing, meanwhile amoxicillin with clavulanate acid, metronidazole, meloxicam, tramadol, metamizole and ranitidine were prescribed. Early weight bearing was observed on the day after surgery, however, at six days PO suture dehiscence occurred. After results from culture, antimicrobial therapy was changed to cefovecin (two injections with a 14-day interval) and metronidazole was maintained for another seven days. US exam at 30 days PO identified hyperechoic insertion of the CCT stump in the calcaneus, but without any pattern of tendon structure. Radiographs revealed displacement of the sutured plate over the CCT. At 40 days PO surgical revision was performed by incision on the caudal aspect of the CCT, wound debridement and removal of all devitalized tissue along with the sutures and plate from the first intervention. Arthrotomy of the TTJ was performed to burr the joint cartilage and perform arthrodesis with insertion of two cortical screws, one lateral to medial from the tarsus to the tibia and another caudal to cranial, from the calcaneus to the tibia. The type II TESF was maintained for another 50 days (removed after 90 days of PO placement). 120 days after the arthrodesis was performed, the tibiotarsal screw was removed. All throughout treatment (210 days), the patient displayed

good limb usage (weight bearing) and there was no need for removal of the calcaneal-tibial screw since satisfactory arthrodesis was obtained.

Figures and general information concerning all cases are shown in Figures 1 and 2 and Table 1, respectively.

Table 1. Patient's general information.

| Patient | Species | Breed | Gender | Age (years) | Body weight (kg) | Type of lesion of the common calcaneal tendon | Limb | Techniques used for tendon repair | Complications | Implant removal | Return to function |
|---------|---------|-------------------|--------|-------------|------------------|---|------|--|---|--|--|
| 1 | Canine | Brazilian terrier | M | 10 | 7.7 | Type I chronic (6 m) | RHL | Tenorrhaphy Plate sutured over the tendon Tibiotarsal joint immobilized with locking screw | Yes, suture dehiscence and screw exposure | Screw removal at 30 days PO. There was no need for plate removal | Yes, 30 days PO Discharged at 1 year PO |
| | | | | | | | | Splint | | | |
| 2 | Canine | Mixed breed | F | 2 | 13.3 | Type I chronic (6 m) | LHL | Tenorrhaphy Plate sutured over the tendon Bovine pericardium graft preserved in 98% glycerin coating Tibiotarsal joint immobilized with locking screw | No | Screw and plate removal at 70 days PO | Yes, 15 days PO Discharged at 90 days PO |
| | | | | | | | | Splint | | | |
| 3 | Canine | Mixed breed | F | 6 | 18.6 | Type I chronic (22 days) | RHL | Tenorrhaphy Plate sutured over the tendon Bovine pericardium graft preserved in 98% glycerin coating Tibiotarsal joint immobilized with locking screw | No | Screw removal at 45 days PO There was no need for plate removal | Yes, 8 days PO Discharged at 120 days PO |
| | | | | | | | | Splint | | | |
| 4 | Feline | Mixed breed | M | 3 | 6.0 | Type I open subacute (7 days) | RHL | Tenorrhaphy Plate sutured over the tendon Bovine pericardium graft preserved in 98% glycerin coating Tibiotarsal joint immobilized with type II TESF | Yes, suture dehiscence and infection | Plate, sutures and pericardium graft removal. Debridement Arthrodesis with 2 screws. TESF kept in place. | Yes, considered satisfactory due to tibiotarsal arthrodesis Discharged at 210 days PO |

M: male; F: female; TESH: transarticular external skeletal fixator; PO: postoperative; m: months; RHL: right hind limb; LHL: left hind limb.

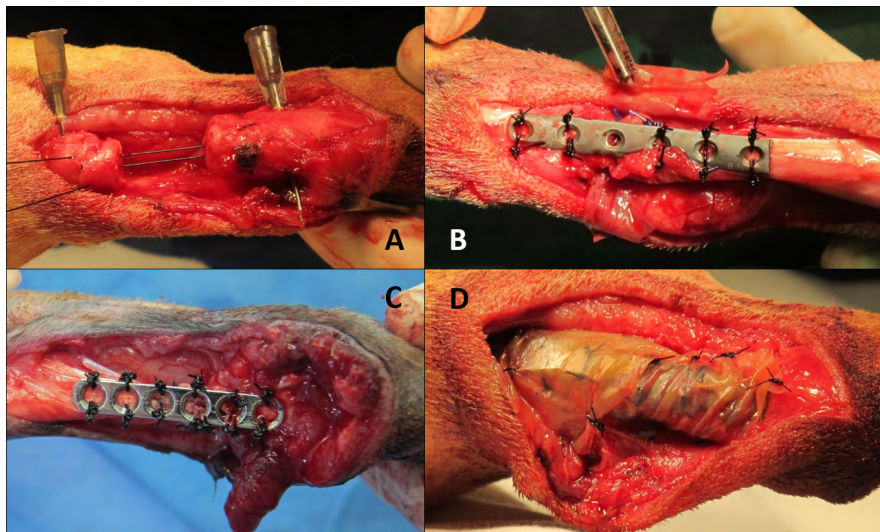


Figure 1. Transoperative images. A- Delicate handling of the CCT with aid of hypodermic needles and locking loop suture being applied (case 3). B- Titanium plate sutured over the CCT, in detail bovine pericardium graft on the forceps positioned behind the tendon (case 2). C- Surgical steel plate sutured over the CCT (case 4). D- Bovine pericardium graft preserved in 98% glycerin 98 % sutured around the conjunction tendon/plate (case 3).

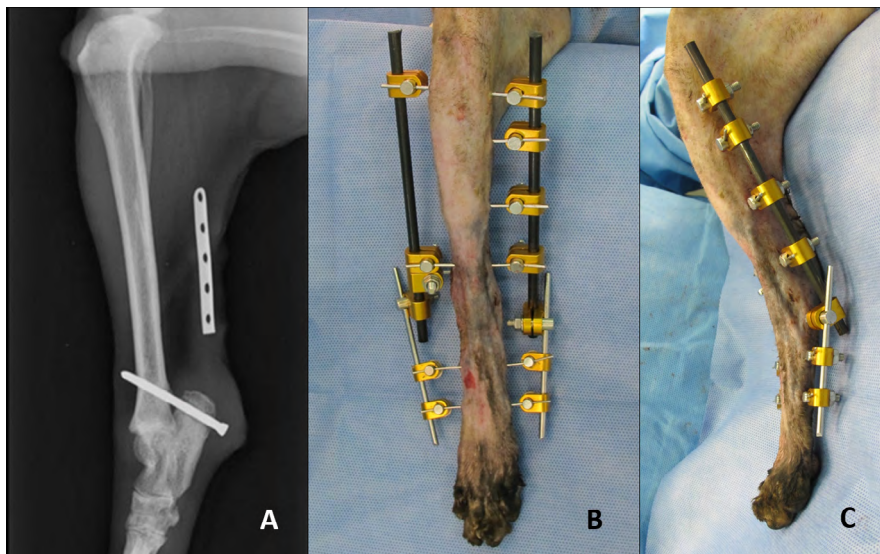


Figure 2. A- Immediate postoperative radiographic image of the right tibia and TTJ on medial-lateral view with hyperextension of the TTJ, presence of a calcaneal-tibial locking screw and plate located on the CCT's region (case 1). B & C- TESS from case 4, in the immediate postoperative period with hyperextension of the TTJ, cranial and medial views, respectively.

DISCUSSION

Clinical signs of CCT rupture are similar in dogs and cats [1,8] and the same occurred in our findings, in accordance to a 2010 retrospective study of 21 cats in which plantigrade posture and soft tissue swelling were observed in 19 animals [1].

Ultrasound exam is the test of choice to monitor tendon healing after tenorrhaphy [11]. In our study it was crucial to determine when the calcaneo-tibial screw could be removed, as well as to highlight the

deficiency on tendon repair on case 4, leading to revision surgery.

Association of plate and bovine pericardium preserved in 98% glycerin was used in two dogs and the cat from this study. The aim was to increase the tenorrhaphy's stiffness [10] and the pericardium graft had also the function of reducing the formation of peritendinous adhesions, fact confirmed in case 2 at implant removal. There is a report of use of ipsilateral fascia lata autograft associated with polypropylene

mesh for degenerative CCT injury repair for the same purposes [12].

There was no rejection of bovine pericardium preserved in 98% glycerin, corroborating with a previous study with calcaneal tendon homologous implant also preserved in 98% glycerin in 24 dogs [9]. Complications encountered with the cat are due probably to previous wound contamination since glycerin is a powerful antiseptic with broad-spectrum of activity, except for bacterial spores. Furthermore, it dehydrates tissue by replacing most of the intracellular water without changing the ionic cell concentration [8].

The calcaneal-tibial screw is a proper fixation method, however susceptible to premature failure or breakage and needs complimentary immobilization such as a splint. But splint usage may lead to complications including skin lesions, muscle atrophy and osteoporosis due to stress protection [11]. Mild muscle atrophy and skin wounds like pressure sores were observed on patients treated with splint. Owners also reported trouble with splint management and with the necessity of frequent appointments for bandage check.

Tibiotalar joint was immobilized to oppose muscle forces and avoid stress concentration at tenorrhaphy suture, increase the strength of the healed tendon and allow early weight bearing in order to minimize the risk of recurrence and prevent limb contracture [3]. Although it is recommended to maintain the TTJ with a 135°-145° angle (anatomical position) [3,6,8,12], we chose to immobilize it in hyperextension to promote tendon relaxation to compensate large portions of fibrous and devitalized tissues that were removed from the dogs and cat respectively. Our findings are in accordance with those from other studies kept TTJ in hyperextension after tenorrhaphy in 10

labor dogs, without any complications [13]. We did not encounter complications as well.

TTJ immobilization may be achieved by use of transarticular external skeletal fixator (TESF), calcaneal-tibial screw with external bandages or several types of splints [5]. In a retrospective study, there was no significant difference between use of TESF and splints after CCT tenorrhaphy in 28 dogs [5]. We opted for use of splints made of thermoplastic component base to protect the calcaneal-tibial screws of the dogs. TESF was used for the cat's treatment in the first place and facilitated revision surgery that resulted in arthrodesis by combined use of TESF and screws. Moreover, cats tolerate TESF better than splints. A previous study evaluated 21 cats on the short and long term after CCT repair, 16 of them received TESF and complications were reported only in six patients [1]. At this study there was not any complication related to TESF use, however, we believe that all complications that occurred with the cat were due to previous infection.

After removal of the calcaneal tibial screws all dogs did not display any pain on the TTJ or restricted range of motion. However, joint immobilization leads to degeneration of the articular cartilage caused by loss of water and damage to the extracellular matrix, usually irreversible after six weeks [7].

Surgical treatment of CCT injuries have good prognosis for closed complete injuries treated by tenorrhaphy associated with suture of titanium plate, 98% glycerin preserved bovine pericardial, calcaneal tibial locking screw and splint for six weeks.

MANUFACTURER

13M do Brasil. Sumaré, SP, Brazil.

Declaration of interest. The authors report no conflicts of interest. The authors alone are responsible for the content and writing of the paper.

REFERENCES

- 1 **Cervi M., Brebner N. & Liptak J. 2010.** Short- and long-term outcomes of primary Achilles tendo repair in cats: 21 cases. *Veterinary and Comparative Orthopaedics and Traumatology*. 23(5): 348-353.
- 2 **Gilbert P.J., Shmon C.L., Linn K.A. & Singh B. 2010.** Macroscopic and microvascular blood supply of the canine common calcaneal tendon. *Veterinary and Comparative Orthopaedics and Traumatology*. 23(2): 81-86.
- 3 **Guerin S., Burbidge H., Firth E. & Fox S. 1998.** Achilles tenorrhaphy in five dogs: a modified surgical technique and evaluation of a cranial half cast. *Veterinary and Comparative Orthopaedics and Traumatology*. 11(4): 47-52.
- 4 **Meutstege F.J. 1993.** The classification of the canine Achille's tendo lesions. *Veterinary and Comparative Orthopaedics and Traumatology*. 6(1): 53-55.

- 5 **Nielsen C. & Pluhar G.E. 2006.** Outcome following surgical repair of achilles tendo rupture and comparison between post-operative tiobiotarsal immobilization methods in dogs. *Comparative Orthopaedics and Traumatology*. 19(4): 246-249.
- 6 **Norton J.C., DeCamp C.E., Yu J. & Rooks R.L. 2009.** Use of a single-ring transarticular fixator construct for immobilisation of the talocrural joint following common calcaneal tenorrhaphy. *Comparative Orthopaedics and Traumatology*. 22(5): 430-435.
- 7 **Pratesi A., Grierson J. & Moores A.P. 2012.** The use of a stifle flexion device to manage avulsion of the lateral head of the gastrocnemius muscle in a cat. *Veterinary and Comparative Orthopaedics and Traumatology*. 25(3): 246-249.
- 8 **Raiser A.G. 2001.** Reparação do tendão calcâneo em cães. *Ciência Rural*. 31(2): 351-359.
- 9 **Raiser A.G., Graça, D.L., Pippi, N.L., Zinn L.L., Silveira D.S., Bordin A.I., Baiotto G.C., Rios M.V. & Silveira A.F. 2001.** Homoimplante ortotópico de tendão calcâneo em cães. Conservação, assepsia e implantação. *Ciência Rural*. 31(1): 89-94.
- 10 **Schulz K. 2008.** Abordagens das lesões ou doenças dos músculos e tendões. In: Fossum T.W. (Ed). *Cirurgia de Pequenos Animais*. 3.ed. Rio de Janeiro: Elsevier, pp.1316-1332.
- 11 **Sivacolundhu R.K., Marchevsky A.M., Read R.A. & Eger C. 2001.** Achilles mechanism reconstruction in four dogs. *Veterinary and Comparative Orthopaedics and Traumatology*. 14(1): 25-31.
- 12 **Swiderski J., Fitch R.B., Staatz A. & Lowery J. 2005.** Sonographic assisted diagnosis and treatment of bilateral gastrocnemius tendon rupture in a labrador retriever repaired with fascia lata and polypropylene mesh. *Veterinary and Comparative Orthopaedics and Traumatology*. 18(4): 258-263.
- 13 **Worth A.J., Danielsson F., Bray J.P., Burbidge H.M. & Bruce W.J. 2004.** Ability to work and owner satisfaction following surgical repair of common calcanean tendon injuries in working dogs in New Zealand. *New Zealand Veterinary Journal*. 52(3): 109-116.