



Histopathological and Immunohistochemical Diagnostic of Carcinosarcoma of Mandible in a Rainbowtrout (*Onchorhynchus mykiss*)

Luis Alberto Romano¹, Yara Aiko Tabata² & Agar Alexandrino²

ABSTRACT

Background: The most common health problems described in fishes are noninfectious, infectious, and metabolic disorders. Fishes have neoplasias that are similar to those observed in mammals. Though these neoplasias do not cause economic losses to aquaculture, they have aroused a crescent interest from the comparative pathology's point of view. Neoplasias of the oral cavity in fishes are usually reported as individual cases, but mandible tumors are not common, and most of them are squamous cells carcinomas. The aim of this study is to report a case of carcinosarcoma of the mandible in a rainbow trout (*Oncorhynchus mykiss*), obtained from a trout farm in Campos do Jordão, São Paulo, Brazil.

Case: The fish underwent necropsy and tissue samples were collected and fixed with a buffer-neutralized formalin solution, which were then embedded in paraffin, sectioned in 5 µm sections and stained with hematoxylin-eosin. The histological sections were stained for immunohistochemical procedures, according to a modified avidin-biotin-peroxidase complex technique. Slides containing tissue were deparaffinized with xylol and rehydrated with alcohol of different grades. The endogenous peroxidase activity was blocked by incubating the slides for 20 min at 0.3% H₂O₂ in a solution of 5% methanol. After rinsing the slides in water and in a PBS/0.05%-Tween 20 solution, they were incubated in normal serum diluted 1:100 containing 10% bovine albumin in PBS (BSA), at room temperature for 30 min in humid chamber. After incubation, the primary anti-cytokeratin and anti-vimentin antibody was added to a 1:200 dilution in 10% PBS-BSA, and the slides were incubated until the next day at 41°C in humid chamber. The slides were then rinsed in PBS and incubated for 7 min in a 50 mL 30.3-diaminobenzidine solution containing 1% PBS-BSA in 50 mL H₂O₂. Hematoxylin was used for counterstaining. The immunohistochemical analysis showed a tumor with epithelial and mesenchymatous neoplastic components. The epithelial component presented an epidermoid carcinoma with well differentiated and keratinizing areas, in addition to other little differentiated, non-keratinizing areas. The mesenchymatous component presented a fibrosarcoma. The immunohistochemical analysis demonstrated signs of cytokeratin in carcinomatous elements and of vimentin in sarcomatous elements.

Discussion: Fishes are valuable resources in human nutrition, medicine, science and leisure. Similarly to other poikilothermic vertebrates, fishes also develop benign and malign neoplasias. However, it is their infectious diseases that are more known and studied. Teleost fishes constitute the widest and most diverse class of vertebrates, with over 20,000 known species. The diversity and placement in the phylogenetic tree make teleost fishes the ideal objects for comparative carcinogenesis studies, which could allow a broader knowledge about basic neoplastic development mechanisms, in comparison to studies limited to mammal models only. According to our knowledge and considering the literature available on fish tumors, this is the first description of a carcinosarcoma of the mandible affecting a rainbow trout.

Keywords: carcinosarcoma, neoplasia, tumor, fish, rainbowtrout, mandible.

INTRODUCTION

Fishes are valuable resources in human nutrition, medicine, science, leisure and companionship. The most common health problems described in fish are non-infectious, infectious, and metabolic disorders.

Teleost fishes constitute the largest and most diverse class of vertebrates, with over 20,000 known species. Their diversity and placement in the phylogenetic tree make them ideal subjects for comparative carcinogenesis studies, which could allow a broader knowledge about basic mechanisms, in comparison to studies limited to mammal models only [1,10]. The study of fish tumors is very important in cancer research, but the classification of fish neoplasms is largely based on mammalian criteria.

Reports of neoplasias in fish are uncommon. Neoplasias of the oral cavity in fish are usually reported as individual cases, but tumors of the mandibles are not common and carcinosarcoma of the mandible is a very uncommon neoplasm.

The aim of this study is to report a case of carcinosarcoma of the mandible in a rainbow trout, with histopathological and immunohistochemical studies obtained from a trout farm in Campos do Jordão, São Paulo, Brazil.

CASE REPORT

A rainbow trout weighting 750g, obtained from a trout farm in Campos do Jordão, São Paulo, Brazil, presented a hard, non-mobile mass in the upper and lower mandible (Figure 1). The fish was subjected to necropsy and tissue samples were

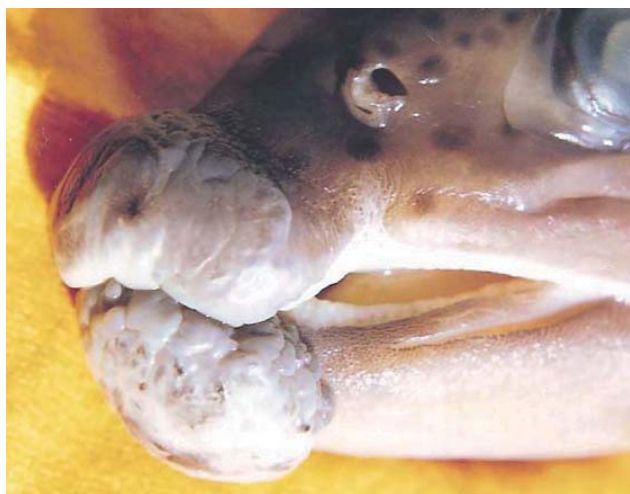

Figure 1. Rainbowtrout with mass of the upper and lower mandible.

collected and fixed in a 10% neutral buffer formalin solution, embedded in paraffin, sectioned at 5 μ m and stained routinely with hematoxylin and eosin.

Histological sections were stained with immunohistochemical procedures, according to a modified avidin-biotin-peroxidase complex technique [4]. 17 Tissue slides were deparaffinized rinsing them with xylol and then rehydrated with alcohols of different grades (absolute ethanol, 90, 80, 70, 50%). The endogenous peroxidase activity was blocked by incubating the slides for 20 min in 0.3% H₂O₂ in a 5% methanol solution. After washing the slides in water and PBS/0.05%-Tween 20 solution, they were incubated in normal 1/100 serum¹, in a 10% PBS-bovine serum albumin (BSA) solution at normal temperature for 30 min in a humid chamber. After incubation, the primary anti-cytokeratin and anti-vimentin² antibody was added at a dilution of 1:200 in PBS-BSA 10%, and the slides were incubated overnight at 41°C in humid chamber. The slides were then rinsed in PBS and incubated for 7 min in a 50 mL 30.3-diaminobenzidine³ solution containing 1% PBS-BSA in 50 mL H₂O₂. Counterstaining was then performed with hematoxylin⁴.

Microscopic examination showed neoplasia presenting both epithelial and mesenchymal neoplastic components. The epithelial component showed a typical squamous cells carcinoma proliferation. It presented a well differentiated and keratinizing area, with the formation of epithelial pearls, but also presented poorly differentiated and non-keratinizing squamous cells carcinoma areas, with cells forming sheets, cords, and bundles separated by varying amounts of vascular connective

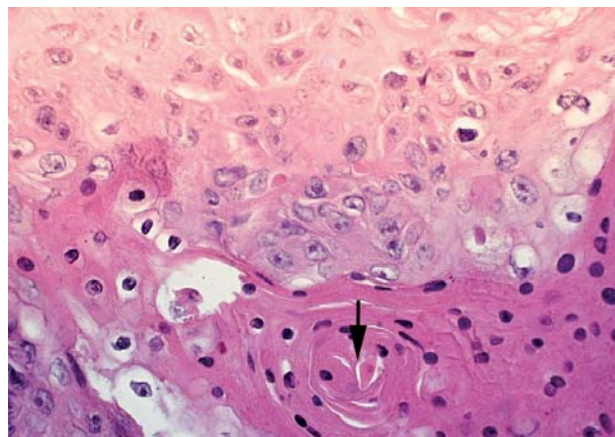


Figure 2. Squamous cells carcinoma well - differentiated keratinizing with epithelial pearl formation (arrow) [HE, 200x].

tissue (Figure 2). The mesenchymal component also showed fibrosarcoma-like, malignant features, including hypercellularity, marked pleomorphism, and enlarged nuclei (Figure 3). The most populated immunoreactive areas, which stained with anti-cytokeratin, were found in epithelial components (Figure 4). In mesenchymal components, the immunoreactive area was only stained with anti-vimentin (Figure 5).

DISCUSSION

Dawe [2], when discussing the problems of oncogeny associated with phylogeny, raised many interesting questions, including the problems associated with “the phylogenetic point of the neoplasm”. The study of neoplasias is a branch of both human and animal medicine, which receives a considerable financial support worldwide for the execution of different types of research [5]. Neoplasia may ultimately be considered a property of life, and

the study of tumors in fishes is a very important tool in cancer research [6]. As already stated, the classification of fish neoplasms are largely based on mammalian criteria [7,8]. Therefore, the study of pathologies in fishes, such as neoplasms, developmental anomalies and infectious disease deserve the same attention given the other poikilothermic vertebrates [3].

Carcinosarcoma of the mandible is a very uncommon neoplasm in fish. To the best of our knowledge, and considering the available literature on fish tumors [9,11], this appears to be the first description of a carcinosarcoma of the mandible affecting a rainbow trout.

SOURCES AND MANUFACTURERS

- ¹Vectastain Universal Elite, BC Kit, Vector Laboratories, Burlingame, CA, USA.
- ²Dako, São Paulo, SP, Brazil.
- ³DAB, Sigma- Aldrich, Steinheim, Germany.
- ⁴Harris Modified Hematoxylin Stain, Fisher Scientific, Fair Lawn, NJ, USA.

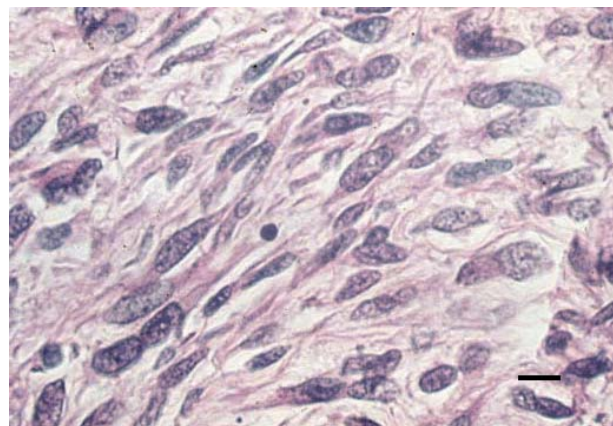


Figure 3. Fibrosarcoma-like composed of elongated spindle cell [HE, 200x].

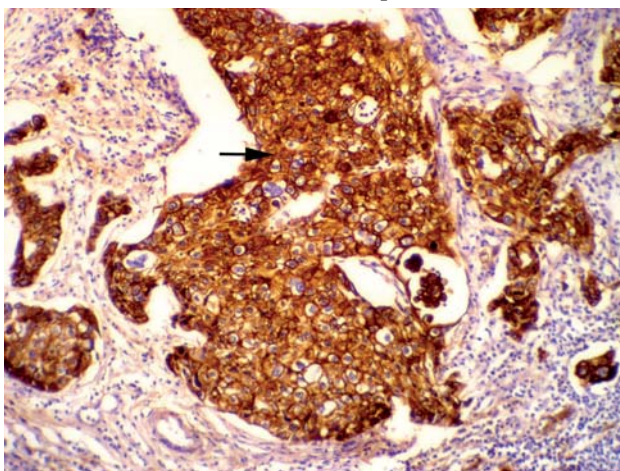


Figure 4. Immunoreactive areas, stained for anti-cytokeratin in epithelia components (arrow) [HE, 200x].

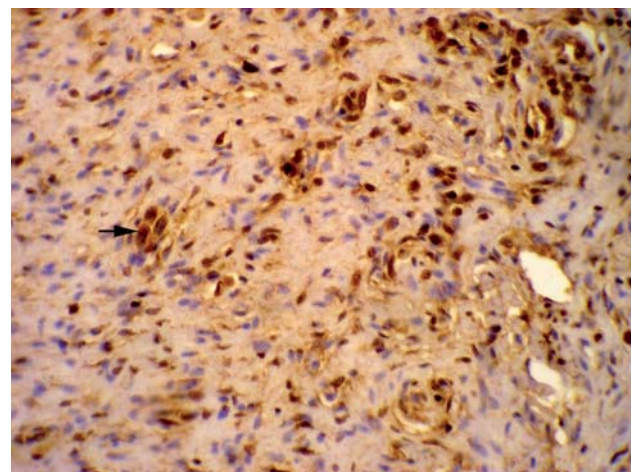


Figure 5. Mesenchymal components: the immunoreactive area was only stained with anti-vimentine (arrow) [HE, 200x].

REFERENCES

- 1 Anders F., Scharl M., Barnekow A. & Anders A. 1984. *Xiphophorus* as an *in vivo* model for studies on normal and defective control of oncogenes. *Advances Cancer Researcher*. 42(1): 191-275.
- 2 Dawe C.J. 1969. Neoplasms of blood cell origin in poikilothermic animals: A review. *National Cancer Institute Monographs*. 32(1): 7-28.
- 3 Harshbarger J.C. 2004. Chronology of oncology in fish, amphibians and invertebrates. *Bulletin European Association of Fish Pathologists*. 24(1): 62-84
- 4 Hsu S.M., Raine L. & Fanger H. 1981. Use of avidin-biotin-peroxidase complex (ABC) in immunoperoxidase techniques: a comparison between ABC and unlabeled antibody (PAP) procedures. *Journal of Histochemistry and Cytochemistry*. 29(5): 577-585.
- 5 Maccubbin A.E. & Ersing N. 1991. Tumors in fish from the Detroit River. *Hydrobiologia*. 219(2): 301-306.
- 6 Masahito P., Ishikawa T. & Sugano H. 1998. Fish tumors and their importance in cancer research. *Japanese Journal of Cancer Research*. 79(3): 545-555.
- 7 Mawdesley-Thomas L.E. 1971. Neoplasia in fish: a review. *Current Topics in Comparative Pathobiology*. 1(2): 87-170.
- 8 Mawdesley-Thomas L.E. 1972. Some tumours of fish. In: Mawdesley-Thomas L.E (Ed). *Diseases of Fish*. London: Academic Press, pp.380-392.
- 9 Mawdesley-Thomas L.E. 1975. Neoplasia in fish. In: Ribelin W.E. & Migaki G. (Eds). *Pathology of fishes*. Madison: The University of Wisconsin Press, pp.1250-1327.
- 10 Schmale M.C., Hensley G.T. & Udey L.R. 1986. Neurofibromatosis in the bicolor damselfish (*Poacetrus partitus*) as a model for von Recklinghausen neurofibromatosis. *Annals of the New York Academy of Sciences*. 486(4): 386-402.
- 11 Wellings S.R. 1969. Neoplasia and primitive vertebrate phylogeny: echinoderms, prevertebrates, and fishes-a review. *National Cancer Institute Monographs*. 31(1): 59-128.