



Use of polyamide tie-rape for ovariectomy in standing mares

Uso de abraçadeira de poliamida para ovariectomia em éguas em posição quadrupedal

Rogério Elias Rabelo¹, Luiz Antônio Franco da Silva², Fabiano José Ferreira de Sant'Ana³, Marco Augusto Machado Silva², Maria Ivete Moura², Leandro Guimarães Franco² & Caroline Rocha de Oliveira Lima²

ABSTRACT

Ovariectomy is a common surgical spaying method in mares, which it leads to short/medium-term masculinization and improves especially their stamina. This study aimed to assess the economic, clinical and histological aspects of the polyamide tie-rape for haemostasis in surgical sterilization of twelve seven-year-old mares, with or without ovary excision. The equines were spayed with polyamide tie-rape for pedicle preventive haemostasis. The left ovary was excised after mesovarium clamping. The polyamide device was also used in the opposite pedicle, though the ovary was not excised. The mean operating cost was determined, the wound healing was assessed and macroscopic and histological evaluation of the pedicles and ovaries were achieved in the post-op. The mean operating cost of the surgical procedure was US\$ 69,44. The ovaries were atrophied and with multifocal necrosis areas, firm irregular nodules and follicles. These nodules were histologically recognized as granulomas. The polyamide tie-rape was efficient in controlling hemorrhage and safe for surgical purpose in the experimental model studied. However, it did not interrupt ovarian activity in the non-excised gland.

Keywords: Mares, Mesovarium, Nylon Clamp, Preventive Haemostasis.

RESUMO

Ovariectomia é um método de esterilização cirúrgica de éguas que promove masculinização a curto/médio prazo e melhora, sobretudo, a capacidade de trabalho. Este estudo objetivou avaliar os aspectos econômicos, clínicos e histológicos do emprego da abraçadeira de poliamida para hemostasia pedicular na esterilização de doze éguas de sete anos, com ou sem exérese ovariana. Empregou-se abraçadeiras de poliamida para hemostasia pedicular preventiva. O ovário esquerdo foi excisado após ligadura do mesovário. A abraçadeira de poliamida foi igualmente empregada no pedículo ovariano direito, contudo não excisou-se o ovário. Avaliou-se o custo operacional médio do procedimento e a cicatrização da ferida cirúrgica, além das alterações macroscópicas e histológicas dos ovários e pedículos ovarianos no pós-operatório. O custo operacional médio do procedimento cirúrgico foi de US\$ 69,44. Os ovários apresentaram atrofia, áreas de necrose multifocal, nódulos irregulares e folículos. Esses nódulos possuíam constituição histológica característica de granulomas. A abraçadeira de poliamida foi eficaz na prevenção da hemorragia e demonstrou segurança para fins cirúrgicos no presente modelo experimental. Contudo, não interrompeu a atividade ovariana nos ovários não excisados.

Descritores: Éguas, Hemostasia Preventiva, Lacre de Náilon, Mesovário.

INTRODUCTION

Several factors affect the performance of equines in different activities, particularly the age, health status, breed of the animal and gender. Pregnancy, lactation and behavioral changes in mares during estrus impair their workforce, which make male equines the best choice for farm and/or sports activities. Ovariectomy is the main spaying method for mares [1] and in Brazil, this surgical procedure is especially employed to avoid undesirable pregnancy in animals with low genetic contribution to the troop or without specific breed patterns, or even to increase their economic value [2]. Moreover, ovariectomized mares presented masculinization tendencies, which improved their appearance, stamina and performance [3].

Trans-vaginal or colpotomy [2,4], unilateral or bilateral flank laparotomy [5,6] and bilateral flank laparoscopy [3,7,8] are the main surgical approaches for ovariectomy in standing mares, which can be chosen based on the animal's age and body condition. In spite of the large amount of surgical technique available, particular caution must be taken concerning the effective haemostasis of the mesovarium, which may be accomplished through monopolar or bipolar electrocoagulation [9], ultrasonic scalpel [7,10] and ovarian pedicle ligation with absorbable [11] or non-absorbable threads [2] or stapling device [12]. High implementation cost, lack of infrastructure and equipment, as well as the possibility of development of trans or postoperative complications, are known limitations of some of these haemostatic methods, which may lead from increase of the cost-effectiveness of the surgical procedure to impaired recovery or even death [6].

Besides those facts, this study aimed to assess the economic, clinical and histological aspects of the polyamide tie-rape for mesovarium preventive haemostasis during surgical spaying of mares, with or without ovary excision.

MATERIAL AND METHODS

This study was carried out under experimental conditions in accordance to the guidelines of the Brazilian College of Animal Experimentation (COBEA). Twelve healthy non-pregnant seven year-old mares, weight ranging from 320 to 415 kg, were used. The animals were admitted for the study after clinical exam, blood serum analysis for infectious

equine anemia (IEA) and complete hemogram, which ranged within the normal patterns for the equine specie.

The 2.5 mm wide and 100 mm long polyamide tie-raps (Fig. 1A) were autoclaved¹ before the beginning of the surgical procedures for 30 minutes at 121° C, followed by a 10-minute-sterile-drying at 38° C in slow warming oven.

The animals were fastened for 12 hours, administered pre-operatively 5.000 I.U. of antitetanic serum², 1.0 mg/kg 10% xylazine chloride³ and restrained in stocks in standing position. The left and right flanks were clipped, surgically prepared and regional anesthesia was carried out in an inverted L block pattern using 2% lidocaine in maximum dose of 7 mg/kg⁴.

A 15 cm skin incision was achieved in the left flank. The abdominal wall musculature was individually separated by finger blunt dissection and the peritoneum was incised with blunt scissors. The left ovary was wrapped for about two minutes in 2% lidocaine chloride soaked gauze before its exteriorization, in order to minimize pain and discomfort during the mesovarium traction. Following this step, the ovary was gently exteriorized, the mesovarium was clamped with a Kocher haemostatic forceps (Fig. 1B) and the nylon tie-rape⁵ was immediately placed right distal to the forceps. While the forceps was slowly softened, the tie-rape was progressively tightened to its maximum capacity. After this step, the left ovary was excised two centimeters distal to the ligature and the exceeding tie-rape tail was cut off. As no bleeding was observed after the ovarian excision, the ovarian pedicle was gently replaced into the abdominal cavity and the Kocher forceps was completely removed.

The left flank musculature was sutured individually with number 1 chromic catgut⁶ in simple interrupted pattern. The same thread was used to close subcutaneous space in simple continuous suture. For skin closure, number 0 monofilamentous nylon thread⁷ was used in simple interrupted pattern. The same surgical technique was used to approach and ligate the right ovary. However, the right ovarian pedicle was only clamped with the polyamide tie-rape and the ovary was not excised, which was gently replaced into the abdominal cavity. The purpose of this procedure was to evaluate macro and microscopically the ischemic effect of the tie-rape clamp on the remaining ovary.

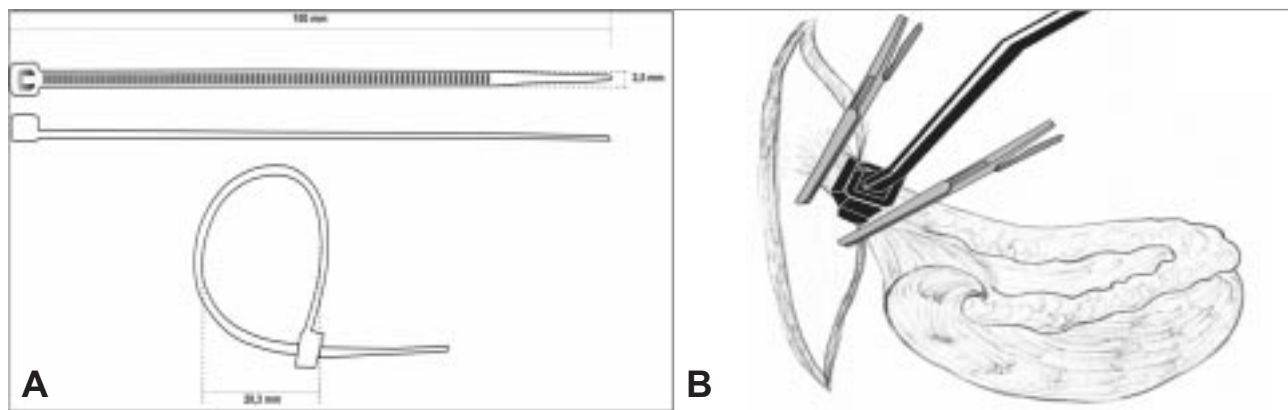


Figure 1: Polyamide tie-rap used for clamping the mesovarium (A); positioning and adjustment of the polyamide tie-rap in the ovarian pedicle as haemostatic method in ovariectomy in standing mares (B).

After the surgical procedures, the mares were kept on an opened grazing area. The post-op management included daily disinfection of the surgical wound with 0.1% polyvinylpyrrolidone-iodine⁸ and the application of topic skin healing/repellant spray⁹. Immediately after the surgical procedure and for the following 48 hours post-op, butorphanol¹⁰ was administered intravenously (0.1 mg/kg, four times a day) for analgesia. For the prophylactic antibiotic therapy, an association of penicillin G benzathine, potassium and procaine, with streptomycin and diclophenac sodium¹¹ was given intramuscularly (20,000 IU/kg penicillin G benzathine; 48-hour intervals; four applications). Skin suture was removed within 12 days after the surgical intervention and total wound cicatrization and postoperative complications were assessed clinically.

Among the possible post-op surgical wound complications, edema, abscess, subcutaneous emphysema and dehiscence were evaluated. Edema was classified as mild (accumulation of seroma in less than five centimeters of diameter, concentrated at the ventral extremity of the wound), moderate (accumulation of seroma in than five centimeters of diameter, extended along the entire wound) and severe (edema extended along the entire flank). Abscess and subcutaneous emphysema were classified as present or absent and wound dehiscence as partial or total.

Sequentially, macroscopic and histological exams in the left ovarian pedicle and in the right ovary were carried out, which were accessed by new flank incision parallel and caudal to the first intervention's scar, under the same pre and post-op protocols for tranquilization, local anesthesia, analgesia and prophylactic antibiotic therapy previously adopted. At

the macroscopic evaluations, possible intraperitoneal adhesions, granulomas and abscesses were assessed and classified as present or absent. The biopsies were achieved in groups of four mares, on the 15th, 30th and 45th days after surgery. Tissue sampling from de left ovarian pedicle for histological exam was collected with biopsy forceps. Right ovariectomy was accomplished for microscopic evaluation of the implications of ischemia on the right ovary following mesovarium ligation with the polyamide tie-rap. Both tissue samples were fixed in 10%-buffered-formaldehyde, stained in hematoxilin-eosine [13,14], and analyzed under optic microscopy.

The estimated operating cost¹² of bilateral flank ovariectomy was carried out regarding the mean price of the consumption materials, such as antiseptics, tranquilizers, local anesthetic, polyamide tie-rap, suture threads, analgesics and antibiotics, and assessed descriptively. The main complications inherent to the bilateral flank laparotomy and to the use of the polyamide band for ovarian pedicle haemostasis were evaluated clinical and microscopically and analyzed descriptively [15].

RESULTS

The estimated operating cost of bilateral flank ovariectomy in a single animal reached the mean price of US 69,50 (\pm US\$ 16,11).

Restraining the mares in standing position in stocks following sedation/analgesia allowed safe and secure surgical interventions for both surgeon and animals. However, two (16.66%) of the mares presented incoordination and suddenly dropped into the stocks few minutes after intravenous xylazine chloride injection.

Regarding the surgical procedure, wrapping the left ovarian pedicle or the right ovary with lidocaine-soaked gauze before clamping, ligation and/or excision of the ovary resulted in no signs of acute pain or intolerance to the surgical approach. Besides that, the polyamide tie-clip provided satisfactory preventive haemostasis on the left ovarian pedicle. No ligature slippage or bleeding after ovarian excision was observed. Moreover, it provided easy handling and accurate adjust to the ovarian pedicle, which made the surgical procedure safe and dynamic.

Even though this study was carried out under farm/field conditions, the therapeutic protocol adopted in post-op resulted in satisfactory healing of the surgical wounds and convalescence of the animals. Only mild edema was observed in the flank incision in all equines (100%), which disappeared one week after the surgical procedure. However, subcutaneous emphysema was present in both surgical wounds of the two mares (16%) that fell down into the stocks, which probably happened due to environmental contamination after dropping. This complication was absent in one of these equines after two additional intramuscular administration of the same antibiotic association used in the post-op. In the other mare (8.4%), partial dehiscence of the left surgical wound and total dehiscence on the opposite side occurred, which lasted respectively 21 and 35 days to complete healing following daily disinfection with 0,5% sodium hypochlorite solution.

The excision of the left ovary resulted in the retraction of the ovarian pedicle, which impaired its exteriorization and visualization for biopsy sampling. This process was not observed on the right side, during the surgical exposure and excision/sampling of the remaining ovary.

There were no adhesions or abscesses involving the ovarian pedicles in any of the examined mares, independently of the sampling day for histological exams, though small macroscopic granuloma-like nodules were noticed. The right ovary of all animals presented apparent atrophy during macroscopic evaluation, white/yellow multifocal areas and irregular necrotic spots on the cut surface. Firm irregular white nodules ranging from 0.5 to 1.0 cm in diameter and primary/secondary follicles were also observed on the right ovaries of all animals.

The histological assessment of the nodules

observed in the ovaries revealed multifocal granulomas, characterized by mononuclear inflammatory infiltrate with great amount of macrophages, lymphocytes and plasmocytes per field, surrounded by fibrous conjunctive tissue. Hemosiderosis and mild neutrophilic and eosinophilic infiltrate were also noted. On the left ovarian pedicles of five (41.66%) animals, granulomas similar to those on the right ovaries were observed.

DISCUSSION

Although the present study concerned only the operating cost of the intervention, the results showed that this surgical procedure was economically viable and allowed its use in low genetic value female equines. This fact makes ovariectomy in standing mares attractive and permitted them to perform different work activities, thus benefiting equine owners that need their workforce for subsistence but they can't afford genetically improved/high-value animals. On the other hand, the use of laparoscopic approach, or bilateral ovariectomy under general anesthesia and dorsal/lateral recumbency would be more expensive than the intrinsic value of the animal [3,9,16]. Moreover, Silva et al. [2] also reported the surgical spaying in standing mares as an elective surgery to increase its commercial and genetic value.

Despite the fact that central miorelaxants such as xylazine rarely lead equines to recumbency [17], the dropping of two (16.66%) mares during contention was attributed to the side effects of this α_2 -agonist. Intense depression and loss of proprioception were observed in these animals following 10% xylazine administration. The need for tranquilization depends on the temperament/behavior of the mares submitted to ovariectomy, as previously mentioned [6]. Hanson & Galuppo [18] administered intravenous 0.01-0.02 mg/kg detomidine to reach analgesia/sedation for bilateral laparoscopic ovariectomy in standing equines and affirmed that this active principle resulted in satisfactory sedation. Nonetheless, the authors did not mention the possibility of loss of proprioception or dropping during the surgical procedure following intravenous administration.

Satisfactory trans-surgical analgesia was reached by surrounding the ovaries with gauze soaked in 2% lidocaine chloride, as observed in other study [6], which emphasized that the mesovarium has several sensitive neuronal fibers and makes useful

the use of local anesthetic before the accomplishment of pedicle ligation and ovarian excision. Farstvedt & Hendrickson [8] also achieved ovarian analgesia for ovariectomy in mares by injecting 20 mg 2% lidocaine chloride in mesovarium or by intraovarian route. However, the authors reported that mesovarian block was more efficient than intraovarian injection.

Although the present study showed that bilateral ovariectomy is a relatively simple spaying surgical procedure in standing mares, other studies recommended the ventral midline or paramedian approach under general anesthesia and dorsal recumbency [19]. Many authors performed laparoscopic ovariectomy through ventral abdominal or paramedian access in mares with ovarian tumors and mentioned that easy exteriorization and effective haemostasis of the mesovarium were the main advantages of this surgical approach [1,3,9,16,20,21]. There is no doubt that laparoscopic ovariectomy is an effective, minimally invasive and safe access. Nonetheless, it was not assessed in the present study due to its high implementation/maintenance cost, which would not be economically viable in low-commercial-value animals. Other related advantages of the surgical protocol employed in the present study, such as decreased transoperative time, greater comfort for the surgeon and reduced need for assistants and equipment, were also observed in other studies [2,22].

The easy handling, great resistance to traction and effectiveness in the haemostasis of the ovarian pedicle regarding the use of the polyamide tie-rape were also noticed by França [6]. The author compared the use of the same polyamide device employed in the present study to chromic catgut and emasculator for preventive mesovarium haemostasis for ovariectomy in standing mares and found out that lower operating cost and reduced operative time were achieved following the use of the nylon tie-rape. Silva et al. [23] also used successfully the polyamide tie-rape for ovariohysterectomy in bitches and affirmed that it was an economically viable and an effective alternative method to ligate the ovarian pedicles and uterine stump. Other authors used this device as cerclage to reduce long bone fractures and stated that less injury to adjacent soft tissues and greater resistance to traction were achieved when compared to traditional wire cerclage [24,25].

The edema observed in all operated equines regressed on average a week post-op, which was

similar to previous reports [26]. Although subcutaneous emphysema is a relatively normal complication following field/farm surgeries in equines, the occurrence of this lesion in two animals probably was due to their drop and consequent wound contamination during the surgical procedure. We believe that strict pre and trans-op antiseptic management associated to the prophylactic use of antibiotics and, particularly, the decreased surgical time minimized the occurrence of post-op complications, even though the interventions were not carried out in low-contaminating environment, such as surgical center's. Other author also described small number of postoperative complications after flank ovariectomy in standing mares, such as edema and wound dehiscence [6]. In contradiction to these results, ovariectomy was considered for other authors as responsible for higher occurrence of complications compared to other elective surgical procedures in mares [18,19,27,28]. The main complications highlighted in these studies were peritonitis, incisional hernias, eviscerations, persistence of heat behavior, hemorrhage of the ovarian pedicle due to ligature loosening, fever and wound infection.

In the present study, the wound dehiscence in two mares cicatrized by second intention following wound disinfection with 0.5% sodium hypochlorite solution (BID). The protocol adopted was based on previous study [29], where the same active principle and concentration were used successfully in the treatment of postoperative complications of in young bovines underwent surgical lateral penile deviation.

The lack of adhesions and abscesses on the ovarian pedicles was considered favorable to the surgical protocol adopted in the present study, since these findings may be related to tissue ischemia, infection or organic intolerance to foreign materials [30]. The nylon tie-rape was also used for laparoscopic ovariectomy in standing mares in other study [16], where adhesions between the left ovarian pedicle and the mesentery of the descending colon during convalescence were noticed. Hand et al. [3] also examined the ovarian pedicle of ovariectomized mares, though by laparoscopy, and revealed the presence of discrete granular tissue on the tenth day after the surgical intervention.

The growth of primary and secondary follicles in the right ovary even after clamping was an indication that the ischemia inherent to the tie-rape

clamping did not impair the reestablishment of collateral ovarian blood supply/drainage, which partially maintained the ovarian activity. The histological findings were within the normal patterns for tissue submitted to ischemia due to ligation and did not reveal any menace inherent to the use of the polyamide tie-rap [31].

CONCLUSION

The polyamide tie-rap was economically viable, efficient and secure for bilateral ovariectomy in low-economic-value standing mares after macroscopic and histological evaluation. However, it did not interrupt ovarian activity in the non-excised

ovaries.

INFORMATIVE NOTES

¹Prosmatic T model 215 Autoclave®, Primatec Ltda., Itu, SP, Brazil.

²Vencosat®, Vencofarma Ltda., Curitiba, PR, Brazil.

³Sedomin®, König Ltda., Santana do Parnaíba, SP, Brazil.

⁴Dorfin® - Hertape Ltda., Juatuba, MG, Brazil.

⁵Fixtil®, Comercial Ltda., São Paulo, SP, Brazil.

⁶Catgut®, Medline, Goiânia, GO, Brazil.

⁷Nylon®, Medline, Goiânia, GO, Brazil.

⁸Farmogral Ltda., Brasília, DF, Brazil.

⁹Bertac®, Allvet Quim. Ltda., Londrina, PR, Brazil.

¹⁰Torbugesic®, Fort Dodge Animal Health Ltda., SP, Brazil.

¹¹Septipen Plus®, Vallée, MG, Brazil.

¹²Dollar (US\$) currency trading in Reais (R\$) in April, the 1st, 2008: R\$ 1,71

REFERENCES

- 1 Alldredge J.G. & Hendrickson D.A. 2004.** Use of high-power ultrasonic shears for laparoscopic ovariectomy in mares. *Journal of the American Veterinary Medical Association*, 225(10): 1578-1580.
- 2 Beard W. 1991.** Standing urogenital surgery. *The Veterinary Clinics of North America. Equine Practice*, Philadelphia: W.B. Saunders, 7(3): 669-684.
- 3 Chaves S.M., Silva L.A.F., Eurides D., Atayde I.B., Martins M.E.P. & Figueredo E.J. 2003.** Complicações pós-operatórias e viabilidade econômica na obtenção de rufiões bovinos pelos métodos de desvio lateral modificado e da aderência do pênis à parede abdominal. *Veterinária Notícias*, 9: 45-52.
- 4 Cokelaere S.M., Martens M.J.G. & Wiemer P. 2005.** Laparoscopic ovariectomy in mares using a polyamide tie-rap. *Veterinary Surgery*, 34: 651-656.
- 5 Colbern G.T. & Reagan W.J. 1987.** Ovariectomy by colpotomy in mares. *Compendium Equine Edition*, 9(10): 1035-1039.
- 6 Curi P.R. 1997.** *Metodologia e análise de pesquisa em ciências biológicas*. Botucatu: Téponic Gráfica e Editora, 263p.
- 7 Doran R., Allen D. & Gordon B. 1988.** Use of stapling instruments to aid in the removal of ovarian tumours in mares. *Equine Veterinary Journal*, 20(1): 37-40.
- 8 Dusterdieck K.F., Pleasant R., Lanz O.I., Saunders G. & Howard R.D. 2003.** Evaluation of the harmonic scalpel for laparoscopic bilateral ovariectomy in standing horses. *Veterinary Surgery*, 32: 242-250.
- 9 Farstvedt E.G., Hendrickson D.A. 2005.** Intraoperative pain responses following intraovarian versus mesovarian injection of lidocaine in mares undergoing laparoscopic ovariectomy. *Journal of the American Veterinary Medical Association*, 227(4): 593-596.
- 10 França R.O. 2005.** Ovariectomia e orquiectomia em eqüinos: uso da abraçadeira de náilon na hemostasia preventiva em comparação ao categute e emasculador. 54f. Goiânia, GO. Dissertação (Mestrado em Ciência Animal) – Programa de Pós-Graduação em Ciência Animal, Escola de Veterinária, Universidade Federal de Goiás.
- 11 Hand R., Rakestraw P. & Taylor T. 2002.** Evaluation of a vessel-sealing device for use in laparoscopic ovariectomy in mares. *Veterinary Surgery*, 31: 240-244.
- 12 Hanson C.A. & Galuppo L.D. 1999.** Bilateral laparoscopic ovariectomy in standing mares: 22 cases. *Veterinary Surgery*, 28:106-112.
- 13 Hooper R.N., Taylor T.S., Varner D.D. & Blanchard T.L. 1993.** Effects of bilateral ovariectomy via colpotomy in mares: 23 cases (1984-1990). *Journal of the American Veterinary Medical Association*, 203(7): 1043-1046.
- 14 Jones T.C., Hunt R.D. & King N.W. 1997.** *Veterinary pathology*. New York: W.B. Saunders, 1415p.
- 15 Lazzeri L. 1994.** *Técnica operatória veterinária*. Belo Horizonte: Manole, 415p.
- 16 Luna L.G. 1968.** *Manual of histologic staining methods of the armed forces institute of pathology*. 3.ed. New York: McGraw-Hill, 258p.

- 17 **Massone F. 2003.** *Anestesiologia veterinária – farmacologia e técnicas*, 4. Ed. Rio de Janeiro: Guanabara Koogan, 2003. 326p.
- 18 **Miranda A.F. 2006.** Uso da abraçadeira de náilon na redução aberta de fratura femoral em cães. 82f. Goiânia, GO. Tese (Doutorado em Ciência Animal) – Programa de Pós-Graduação em Ciência Animal, Escola de Veterinária, Universidade Federal de Goiás.
- 19 **Moll H.D., Slone D.E., Juzwiak J.S. & Garrett P.D. 1987.** Diagonal paramedian approach for removal of ovarian tumors in the mare. *Veterinary Surgery*, 16(6): 456-458.
- 20 **Nickels F.A. 1988.** Complications of castration and ovariectomy. *The Veterinary Clinics of North America. Equine Practice*, Philadelphia: W.B. Saunders, 4(3): 515-523.
- 21 **Palmer S.E. 1993.** Standing laparoscopic laser technique for ovariectomy in five mares. *Journal of the American Veterinary Medical Association*, 203(2): 279-283.
- 22 **Prophet E.B., Mills B., Arrigton J.B. & Sobin L.H. 1992.** *Laboratory methods in histotechnology*. Washington: Armed Forces Institute of Pathology, 275p.
- 23 **Rabelo R.E., Viu M.A.O., Leão H.F., Oliveira S.L., Sant'ana J.F., Lima C.R.O. & Prado J. 2006.** Avaliação clínica e histológica do uso da abraçadeira de náilon como material alternativo na castração de éguas. In: *Proceedings of the 33th Congresso Brasileiro de Medicina Veterinária* (Cuiabá, Brazil). pp.106-107.
- 24 **Ragle C.A. & Schneider R.K. 1995.** Ventral abdominal approach for laparoscopic ovariectomy in horses. *Veterinary Surgery*, 24: 492-497.
- 25 **Rodgers D.H., Belknap J.M. & Wilson D.A. 2001.** Laparoscopic ovariectomy using sequential electrocoagulation and sharp transection of the equine mesovarium. *Veterinary Surgery*, 30: 572-579.
- 26 **Schmidt T.L. & Davis W.M. 1978.** Intraoperative use of nylon bands in fracture fixation. *Clinical Orthopaedics*, 154(341): 341-343.
- 27 **Slone Jr. D.E. 1988.** Ovariectomy, ovariectomy, and cesarean section in mares. *Veterinary Clinics of North America. Equine Practice*, Philadelphia: W.B. Saunders, 4(3): 451-459.
- 28 **Silva L.A.F., Araújo G.R.S., Miranda A.H., Rabelo R.E., Garcia A.M., Silva O.C., Araújo I.F.L., Macedo S.P., Sousa J.N., Fioravanti M.C.S., Oliveira K.S., Amaral A.V.C. & Silva E.B. 2004.** Ovariohisterectomia em cadelas: uso da abraçadeira de náilon na hemostasia preventiva. In: *Proceedings of the 1st Congresso do Centro Oeste de Veterinários de Pequenos Animais* (Goiânia, Brazil). pp.100-102.
- 29 **Silva L.A.F., Silva C.A., Fioravanti M.C.S., Atayde I.B., Silva M.A.M.; Matos E.S. & Castro G.R. 2001.** Ovariectomia em éguas: comparação da viabilidade de três técnicas cirúrgicas e avaliação do pós-operatório. *Ciências Veterinária dos Trópicos*, 4(2): 256-267.
- 30 **Trew G. 2006.** Postoperative adhesions and their prevention. *Reviews in Gynecological and Perinatal Practice*, 6: 47-56.
- 31 **Trotter S.S. & Embertson R.M. 1999.** The uterus and ovaries. In: Auer J.A. & Stick J.A. (Eds.). *Equine Surgery*. 2. ed. Philadelphia: W.B. Saunders, pp.575-583.