

NEUROLYMPHOMATOSIS: UNUSUAL EXTRANODAL INVOLVEMENT PATTERN ON 18F-FDG PET/CT IN A NON-HODGKIN LYMPHOMA RECURRENCE

NEUROLINFOMATOSE: PADRÃO NÃO USUAL DE ENVOLVIMENTO EXTRANODAL NO 18F-FDG PET/CT EM RECORRÊNCIA DE LINFOMA NÃO-HODGKIN.

Marcos Pretto Mosmann¹, Clarice Sprinz², Ana Amélia Raupp², Thiago Krieger Bento da Silva³, Henrique Rodrigues de Abreu³

A 37-year-old woman was diagnosed with Stage IVB diffuse large-B cell lymphoma, presenting with bulky mediastinal and bone marrow involvement. She was treated with 8 cycles of R-CHOP and radiotherapy, achieving complete remission on CT. Two months latter, she presented with pain and weakness in the lower limbs. The ENM, MR and the CSF analysis had shown evidence of lymphoma recurrence with initiation of intrathecal chemotherapy. Her disease continued to progress despite treatment. The following PET/CT shows multiple hypermetabolic areas, compatible with extranodal disease and poor response to therapy, allowing change to R-ICE and autologous stem cell treatment.

Rev HCPA 2011;31(1):113

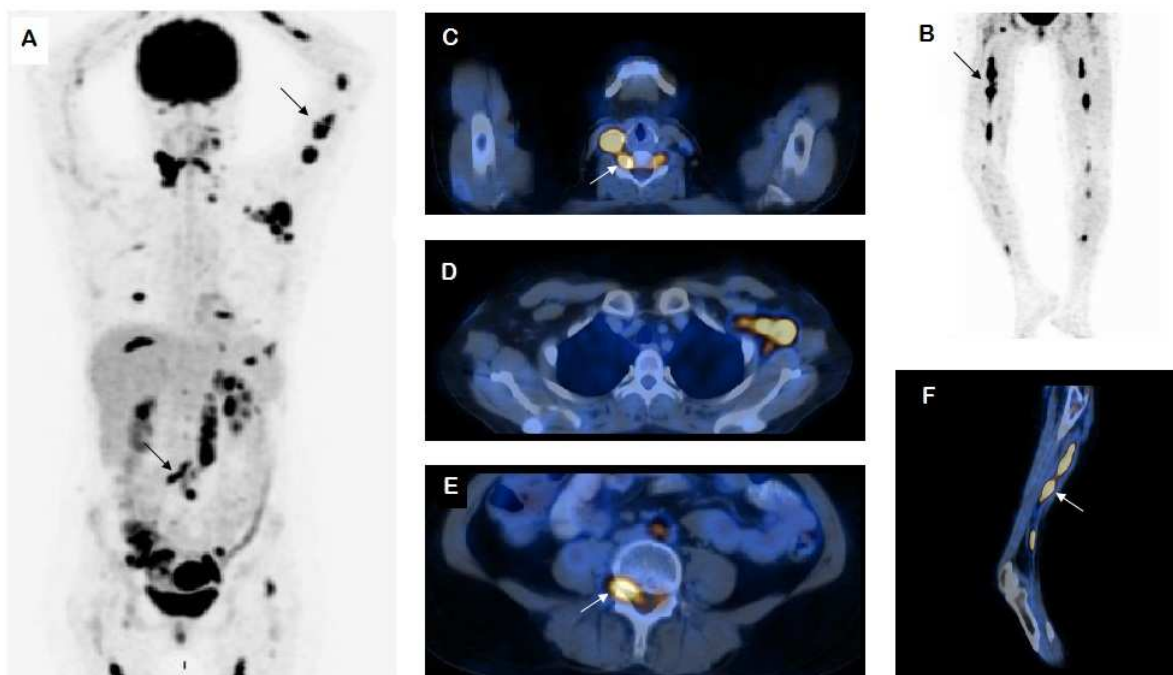


Figure 1 - 18F-FDG PET/CT scan in a non-Hodgkin's lymphoma after intrathecal chemotherapy showing poor response to treatment. Maximum intensity projection (A,B) and fused images demonstrates multiple hypermetabolic areas especially in cervical (C), left axillary (D), abdominal and pelvic lymph nodes. Moreover, there is involvement of the spinal canal and nerve roots (C,E), as well as bilateral sciatic nerve (B,F) and left arm peripheral nerve, findings compatible with neurolymphomatosis (arrows).

1. Serviço de Medicina Nuclear, Hospital de Clínicas de Porto Alegre (HCPA).
 2. Serviço de Medicina Nuclear, Unidade PET/CT, Hospital Mãe de Deus (HMD).
 3. Serviço de Radiologia, Hospital Mãe de Deus.
Contato: Clarice Sprinz. E-mail: clasprinz@gmail.com (Porto Alegre, RS, Brasil).