

MIGRATION OF A LEVONORGESTREL- RELEASING INTRAUTERINE DEVICE (LNG-IUD): CAN WE TRUST ON ULTRASOUND IMAGE?

Migração de um dispositivo intrauterino com levonorgestrel: é possível acreditar na ecografia?

Helena von Eye Corleta^{1,2,3}, Ana Luiza Berwanger da Silva², Suzana Cardona Lago², Edison Capp^{2,3}

We report the case of a nulliparous 33-year-old woman who had a uneventful insertion of levonorgestrel-releasing intrauterine device (LNG-IUD; Mirena, Schering, Brazil) inserted on august/2005. She was amenorrheic from august 2005 to may 2006, when she referred the beginning of an intermittent spotting. On september/2006, she had a normal transvaginal ultrasound, showing a well-placed device. One year later, she informed the occurrence of regular menstrual cycles, but with menorrhagia. At that time, during the physical examination, the retrieval thread was not visible at the cervix. Another ultrasound was then performed, showing a device outside the uterine cavity, probably in the uterine serosa (Figure).

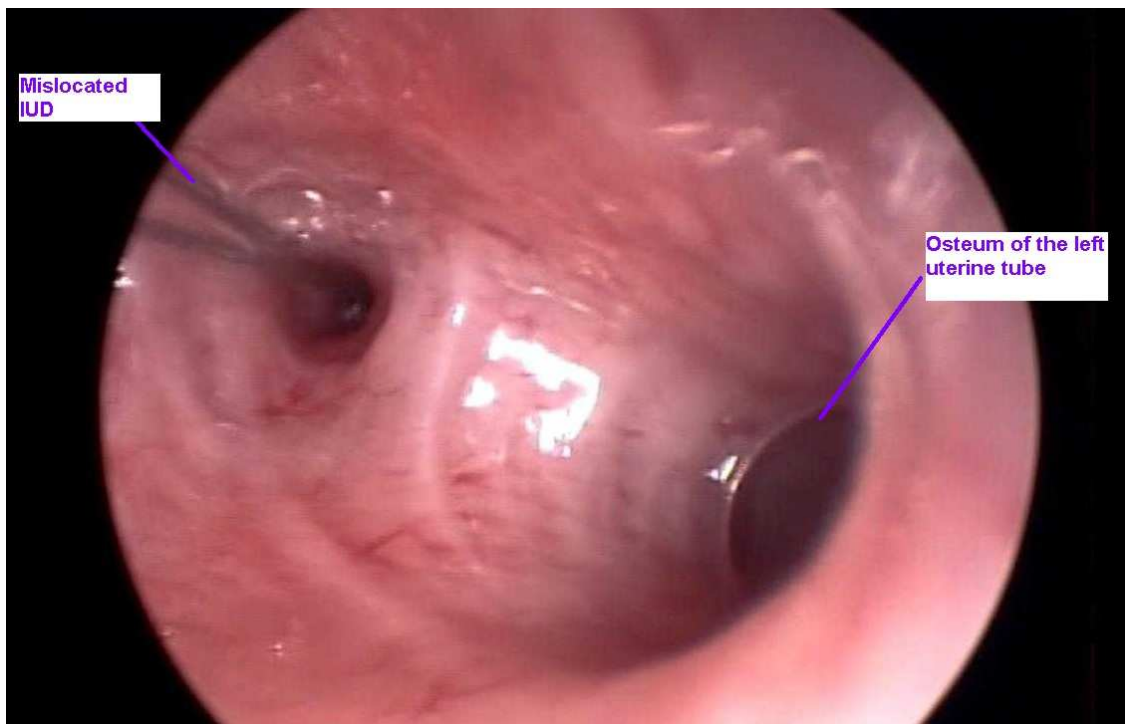
Laparoscopy and hysteroscopy were scheduled. The hysteroscopy identified apparently two osteum related to the left uterine tube, one being the pathway created by the migrating device. It had not perforated the serosa of the uterus yet, being easily removed through hysteroscopy. Laparoscopy was cancelled.

One of the major, although infrequent, complications of intrauterine contraception is perforation, with reported rates of 0.8 per 1000 insertions for copper devices and approximately 2.0 per 1000 for LNG-IUD. This event can happen in the moment of insertion, but most of dislocated devices are detected until one year after in 80% of cases.

Uterine perforation should always be ruled out whenever an intrauterine device is not identified, and this case report remind us that the ultrasound image alone is not enough to determine the type of procedure appropriated for each patient. Ultrasound or pelvic X-ray are exams that usually confirm the diagnosis. The LNG-IUD has a typical sonographic appearance; however, correct fundal positioning of the IUD appears not to be always easy to recognize. Unlike the copper IUD, the levonorgestrel-releasing IUD has acoustic shadows only at its proximal and distal ends, rendering its intrauterine and extrauterine detection more difficult. Another possible way of identifying the place of a mislocated LNG-IUD is through the patient complaints, as this kind of device, when located intra-abdominally, can lead to high levels of levonorgestrel, usually causing amenorrhea and supression of ovulation.

The described higher frequency of uterine perforation with the LNG-IUD remains to be elucidated. We suggest studies of uterine peristalsis in women with LNG-IUD to rule out an increase of a cervix-fundal pressure gradient secondary to the very high tissue concentrations of levonorgestrel.

Rev HCPA 2010;30(1):87



1. Núcleo de Reprodução Humana, Hospital Moinhos de Vento.
2. Programa de Pós-Graduação em Ciências Médicas, Universidade Federal do Rio Grande do Sul.
3. Serviço de Ginecologia e Obstetrícia, Hospital de Clínicas de Porto Alegre.
Contato: Helena von Eye Corleta. E-mail: hcorleta@portoweb.com.br (Porto Alegre, RS, Brasil)