

## Introduction

According to the AADSM published paper on management of side effects(1), Tooth mobility is a top five concern during the treatment of Obstructive Sleep Apnea using an oral appliance. Recently, Norrhem(2) reported a significant difference in anterior crowding using a flexible oral appliance(OA) versus a rigid OA, the results showed less tooth movement with the rigid OA. This poster will report on the changes in tooth movement for a hard acrylic rigid OA, the ProSomnus® Sleep appliance, over a two year period. This work was conducted under IRB through HREBA.

## ProSomnus® Sleep Appliance

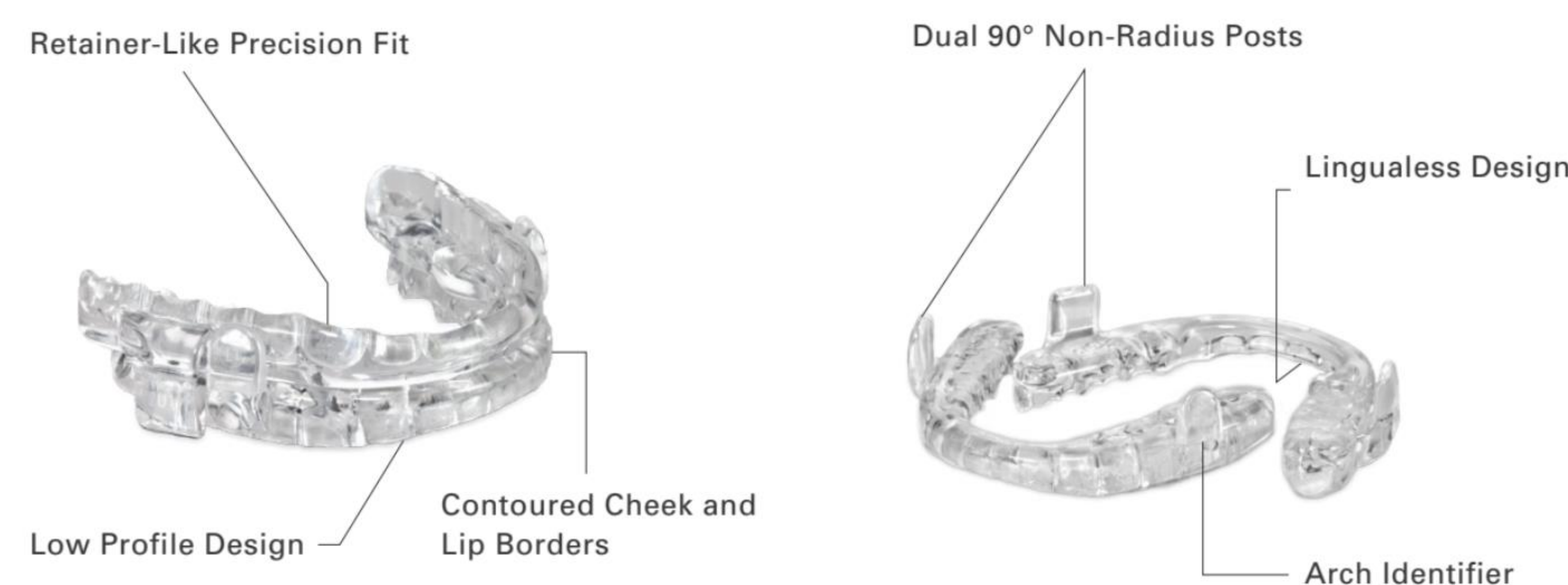


Figure 1

## Objectives

- ❖ Test the hypothesis that a rigid CAD/CAM oral appliance with “Retainer-Like fit” does not result in tooth movement upon regular wear over the period of 2 years or more, having a lingualess design and without the need for ball clasps.
- ❖ Determine the amount of tooth movement related to use of a rigid OAT using the Little’s irregularity index
- ❖ Determine bite change relative to MIP using inter-canine width, overjet and overbite
- ❖ Determine patient acceptance of the device considering any reported side effects

## Method

Eighteen patients (14M/4F) with sleep apnea were recruited for this study. Subjects were fitted with a ProSomnus® MicrO<sub>2</sub>, Sleep Appliance(Fig. 1) at the Snore Centre in Calgary. Subjects were NOT fitted with a morning aligner. Impressions were taken at baseline, after approximately one year (mean = 1.2 years) and two years (mean = 2.3 years) of use with the oral appliance. Subjects were surveyed on compliance and quality of life using Sleep Apnea Quality of Life Index SAQLI. Models were marked per the IRB to scrub the patient data. Models (Fig. 2)were scanned on a TRIOS lab scanner and scored using 3Shape Ortho Analyzer software (3Shape, Copenhagen, Denmark). The upper and lower anterior teeth crowding was calculated using the Little’s index method(2) (Fig 3). The models were placed in MIP and scanned, the Overjet and Overbite were measured in software (Fig. 4). Scanning and measurements were completed by the University of Pacific Orthodontics Department.

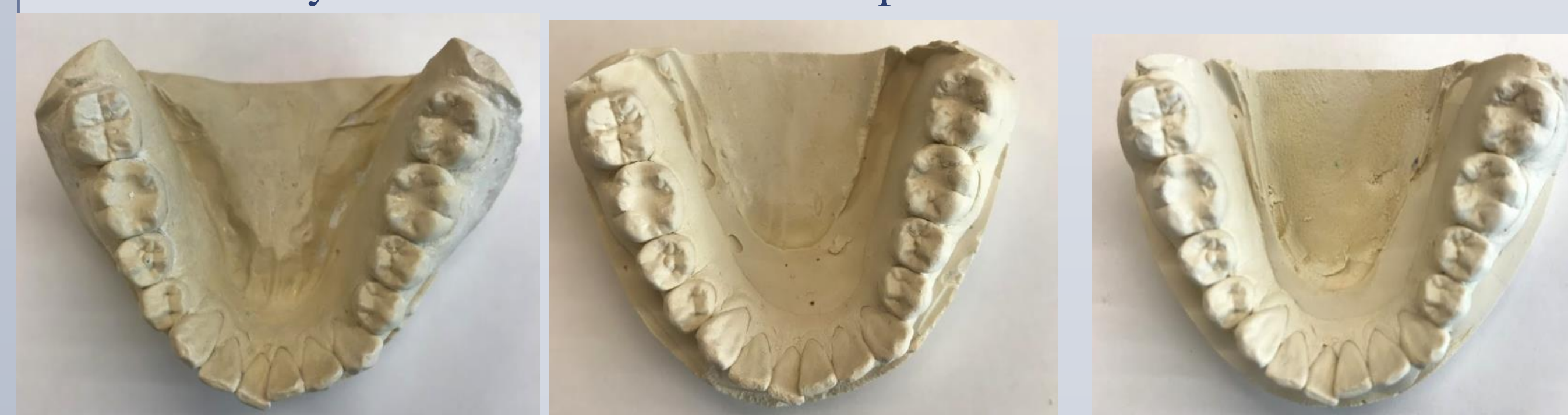

Figure 2

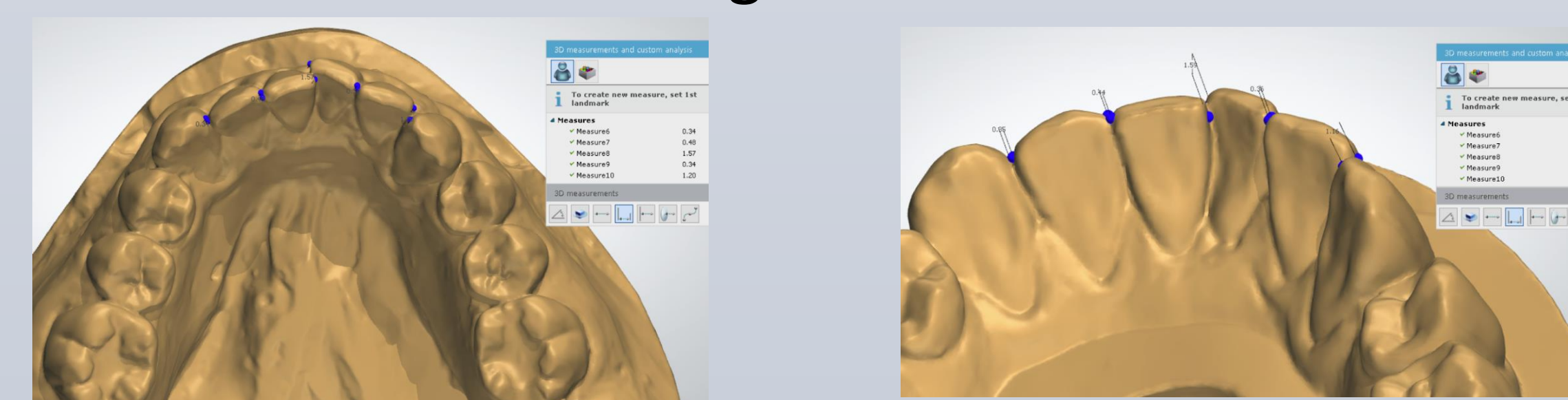


Figure 3

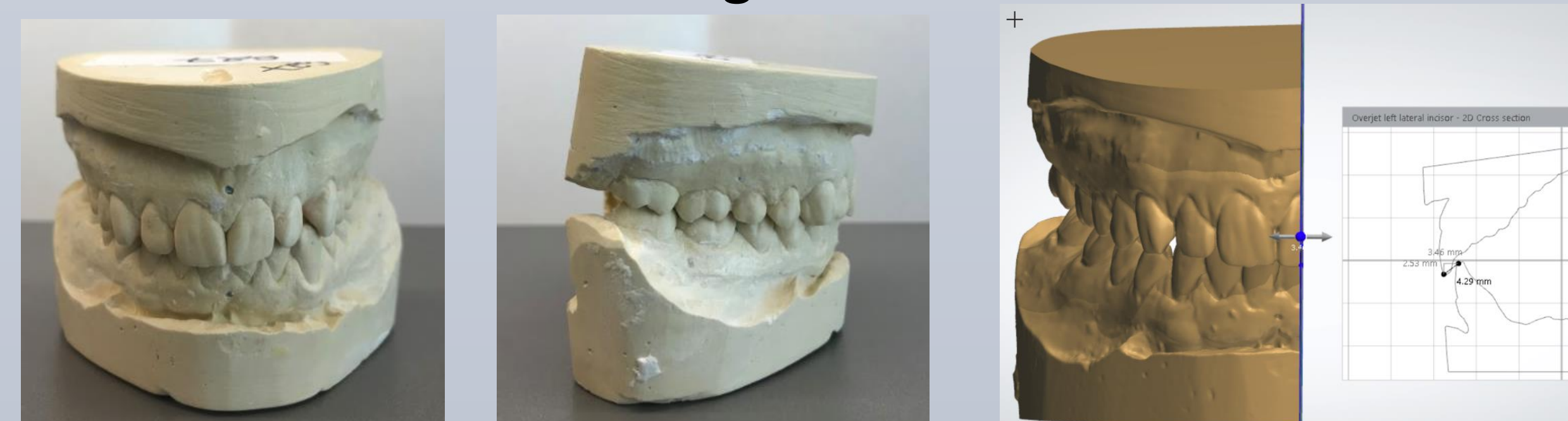

Figure 4

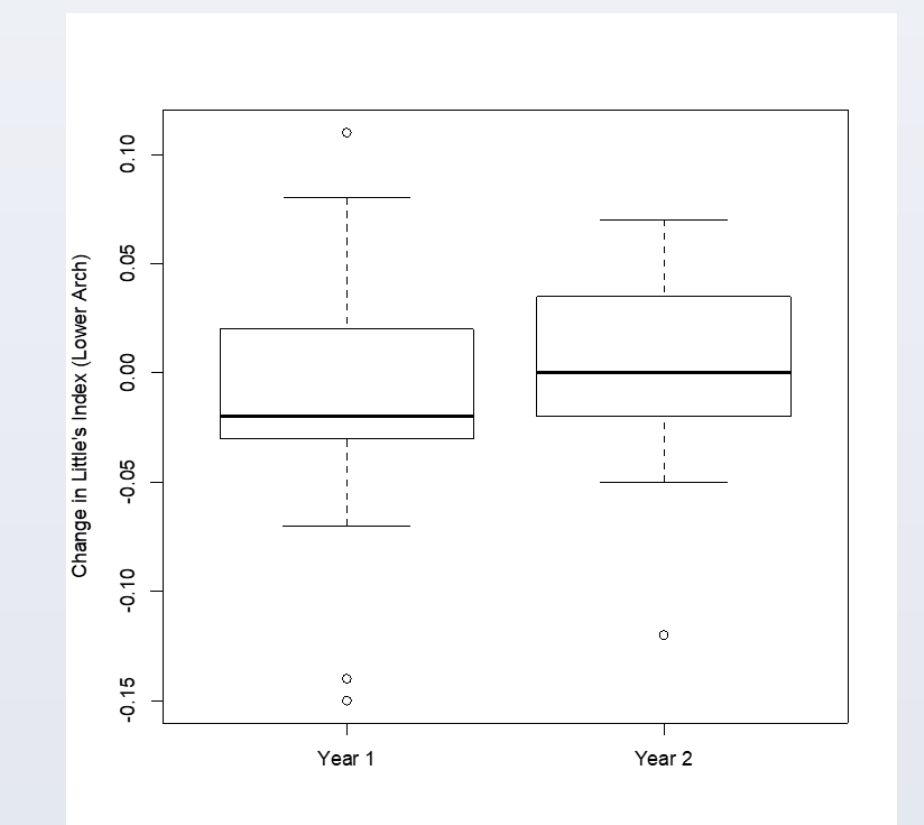
## Patient Acceptance (Survey Results)

- ❖ Patient’s reported 94% subjective compliance (4hr/5day)
- ❖ Patient’s reported an average 9/10 favorable rating to having a better sleep experience and 8.9/10 favorable rating to wearing the ProSomnus device for the rest of their life
- ❖ Patient’s reported on average, a “small amount” of concern related To side effects based on the SAQLI (Scale of 1-7, 7 = “not at all” and is most favorable; “small amount” =6)

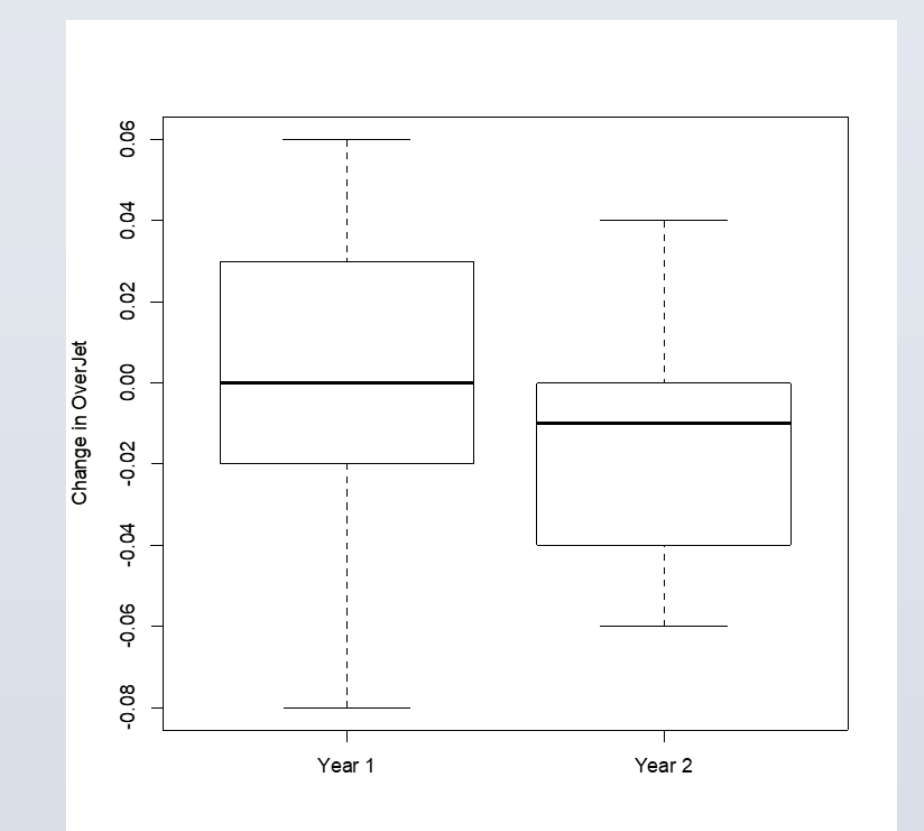
## Results

### No Significant Tooth Movement or Change in Overjet or Overbite

MEAN change Little’s index Lower Arch:  
At 2.3 YRS = 0.003 mm  
*Statistically no change*  
From T=0 to T=2.3YRS



MEAN change Overjet:  
At 2.3 YRS = -0.015 mm  
*Statistically no change*  
From T=0 to T=2.3YRS



	1.2 YRS		2.3 YRS	
	MEAN Change	IQR	MEAN Change	IQR
Little's Index upper (mm)	-0.018	-0.07-0.04	-0.007	-0.075-0.09
Little's Index lower (mm)	-0.013	-0.03-0.02	0.003	-0.02-0.04
Overjet (mm)	-0.0015	-0.02-0.03	-0.015	-0.04-0.00
Overbite (mm)	0.0035	-0.02-0.03	0.0045	-0.02-0.02
Inter canine distance upper (mm)	0.001	-0.01-0.010	-0.008	-0.015-0.005
Inter canine distance lower (mm)	-0.002	-0.010-0.01	0.003	0.00-0.00

## Conclusion

- ❖ A CAD/CAM rigid OA, ProSomnus Sleep Device, demonstrated no significant change in tooth position during the 2.3 YR test period
- ❖ There was no significant change in the bite per the MIP as measured by overjet and overbite
- ❖ It is inconclusive if there was change or no change in the patient’s functional bite
- ❖ Patients reported no issues concerning the ProSomnus Sleep Device

## References

- 1) Sheats RD, Schell TG, Blanton AO, Braga PM, Demko BG, Dort LC, Farquhar D, Katz SG, Masse JF, Rogers RR, Scherr SC, Schwartz DB, Spencer J. Management of side effects of oral appliance therapy for sleep-disordered breathing. Journal of Dental Sleep Medicine. 2017;4(4):111–125
- 2) Changes in lower incisor irregularity during treatment with oral sleep apnea appliances Niclas Norrhem & Hans Nemeček & Marie Marklund; Sleep Breath; Published On-line JAN 23 2017 DOI 10.1007/s11325-016-1456-3

## Acknowledgements

The Authors would like to thank and acknowledge support from University of Pacific Orthodontics Department (San Francisco CA), ProSomnus Sleep Technologies (Pleasanton CA) for financial support, Technical support for 3Shape Software by Joshua Seefeldt at Argen (San Diego CA), Colleen Kelly at Kelly Statistical Consulting (San Diego CA), and the staff at Snore Centre Quarry Park (Calgary AB).