



9-1-2014

# A multidisciplinary treatment of congenitally missing maxillary lateral incisors: a 14-year follow-up case report

Renato Rodrigues de Almeida  
*University of São Paulo*

Ana Carolina Morandini  
*Catholic University of Brasília, amorandini@pacific.edu*

Renata Rodrigues de Almeida-Pedrin  
*Sagrado Coração University*

Marcio Rodrigues de Almeida  
*University North of Paraná*

Renata Cristina Faria Ribeiro Castro  
*Sagrado Coração University*

*See next page for additional authors*

Follow this and additional works at: <https://scholarlycommons.pacific.edu/dugoni-facarticles>

 Part of the [Dentistry Commons](#)

## Recommended Citation

Rodrigues de Almeida, R., Morandini, A. C., Rodrigues de Almeida-Pedrin, R., Rodrigues de Almeida, M., Castro, R. C., & Insabralde, N. M. (2014). A multidisciplinary treatment of congenitally missing maxillary lateral incisors: a 14-year follow-up case report. *Journal of Applied Oral Science*, 22(5), 465–471. DOI: [10.1590/1678-775720140061](https://doi.org/10.1590/1678-775720140061)  
<https://scholarlycommons.pacific.edu/dugoni-facarticles/256>

This Article is brought to you for free and open access by the Arthur A. Dugoni School of Dentistry at Scholarly Commons. It has been accepted for inclusion in Dugoni School of Dentistry Faculty Articles by an authorized administrator of Scholarly Commons. For more information, please contact [mgibney@pacific.edu](mailto:mgibney@pacific.edu).

---

**Authors**

Renato Rodrigues de Almeida, Ana Carolina Morandini, Renata Rodrigues de Almeida-Pedrin, Marcio Rodrigues de Almeida, Renata Cristina Faria Ribeiro Castro, and Natalia Martins Insabralde

# A multidisciplinary treatment of congenitally missing maxillary lateral incisors: a 14-year follow-up case report

Renato Rodrigues de ALMEIDA<sup>1</sup>, Ana Carolina Faria MORANDINI<sup>2</sup>, Renata Rodrigues de ALMEIDA-PEDRIN<sup>3</sup>, Marcio Rodrigues de ALMEIDA<sup>4</sup>, Renata Cristina Faria Ribeiro CASTRO<sup>3</sup>, Natalia Martins INSABRALDE<sup>5</sup>

1- Department of Orthodontics, Bauru School of Dentistry, University of São Paulo, Bauru, SP, Brazil; Discipline of Orthodontics, University North of Paraná, Londrina, PR, Brazil.

2- Discipline of Periodontics, Catholic University of Brasília, Brasília, DF, Brazil.

3- Department of Orthodontics, School of Dentistry, Sagrado Coração University, Bauru, SP, Brazil.

4- Discipline of Orthodontics, University North of Paraná, Londrina, PR, Brazil.

5- Department of Dentistry, University North of Paraná, Londrina, PR, Brazil.

**Corresponding address:** Renato Rodrigues de Almeida - Departamento de Ortodontia - Faculdade de Odontologia de Bauru - Alameda Octávio Pinheiro Brizolla, 9-75 - 17012101 - Bauru-SP - e-mail: renatinhaalmeida@uol.com.br

**Submitted: February 17, 2014 - Modification: May 15, 2014 - Accepted: May 22, 2014**

## ABSTRACT

Absence of the maxillary lateral incisor creates an aesthetic problem which can be managed in various ways. The condition requires careful treatment planning and consideration of the options and outcomes following either space closure or prosthetic replacement. Recent developments in restorative dentistry have warranted a re-evaluation of the approach to this clinical situation. Factors relating both to the patient and the teeth, including the presentation of malocclusion and the effect on the occlusion must be considered. The objective of this study was to describe the etiology, prevalence and alternative treatment modalities for dental agenesis and to present a clinical case of agenesis of the maxillary lateral incisors treated by the closure of excessive spaces and canine re-anatomization. A clinical case is presented to illustrate the interdisciplinary approach between orthodontics and restorative dentistry for improved esthetic results. In this report, the treatment of a girl with a Class II malocclusion of molars and canines with missing maxillary lateral incisors and convex facial profile is shown. Treatment was successfully achieved and included the space closure of the areas corresponding to the missing upper lateral incisors, through movement of the canines and the posterior teeth to mesial by fixed appliances as well as the canines transformation in the maxillary lateral incisors. This is a 14-year follow-up case report involving orthodontics and restorative dentistry in which pretreatment, posttreatment, and long-term follow-up records for the patient are presented.

**Keywords:** Agenesis. Etiology. Orthodontics. Dental esthetics.

## INTRODUCTION

Congenital absence of one or both of the maxillary incisors in humans has been observed since the Paleolithic period. With the evolution of species, the face and jaws tend to decrease in the anteroposterior direction. This trend can limit the space needed to accommodate all of the teeth and, consequently, the last tooth of each series tends to disappear (third molars, second premolars and lateral incisors). This is a hereditary process: a generation that has an anomalous tooth (small-

sized maxillary lateral incisors/peg-shaped lateral incisors) will have descendants that no longer possess this tooth<sup>12</sup>.

Despite presenting this aspect of heredity, agenesis can also be associated with other factors such as: congenital deformities (including ectodermal dysplasia), radiation and nutritional disorders. However, genetics probably represents the primary etiological factor of tooth agenesis<sup>16</sup>. The prevalence of agenesis is enhanced in the families of affected patients<sup>17</sup>. In a previous study, congenital absence of the permanent lateral incisor

with a frequency of 2.2% and absence of the second premolar with a frequency of 3.4% were reported<sup>24</sup>.

An interesting study performed in twins showed a high percentage of agreement for agenesis between homozygous twins, while all heterozygous pairs of twins showed discordance for such dental anomaly<sup>11</sup>. In the 1960s, Garn and Lewis<sup>8</sup> observed that patients with agenesis of third molars had a higher prevalence of agenesis of other permanent teeth. The prevalence of agenesis of permanent teeth in patients with agenesis of third molars was found to be 13 times higher than the prevalence of agenesis in patients with third molar teeth<sup>8</sup>. Recently, a pair of monozygotic twins with second premolar and third molar agenesis was described to show differential expression of PAX9 and MSX1 genes<sup>10</sup>.

Tooth agenesis is the most common developmental anomaly of human dentition, occurring in approximately 25% of the population<sup>1,5,7,9,12</sup>. The third molar is the most affected tooth, showing a prevalence of 20.7%<sup>7</sup>. The prevalence of agenesis is approximately 4.3% to 7.8%, excluding third molars<sup>5,12</sup>. The second lower premolars represent the most commonly missing teeth, followed by maxillary lateral incisors and the upper second premolars<sup>6</sup>. In Caucasians, the occurrence of tooth agenesis could be classified as: common, if it affects the mandibular second premolars, maxillary lateral incisors and upper second premolars; less common, which includes, in decreasing order of occurrence, lower central incisors, lower lateral incisors and upper first premolars, upper canines and lower second molars; and rare, comprising, in descending order of frequency, agenesis of the first and second maxillary molars, lower canines, lower first molars and upper central incisors<sup>19</sup>.

It is important to notice that there is an ethnic difference in the prevalence of tooth agenesis. Epidemiological studies show a lower prevalence of agenesis in black patients compared to whites, while Asians tend to show an increased frequency of agenesis<sup>19</sup>. Even among Caucasian individuals from different continents, the prevalence of agenesis may oscillate<sup>19</sup>. For example, Caucasian Europeans and Australians have a higher prevalence of agenesis compared to Caucasian North Americans. Regarding gender, this anomaly is more frequent in females<sup>5</sup>.

The majority of the patients with agenesis (76-83%) have the absence of one or two permanent teeth<sup>6,19</sup>. The tooth agenesis is usually bilateral and of symmetrical occurrence. There is an exception in relation to the upper lateral incisors, which often are absent unilaterally, and the left side is more affected than the right side<sup>1,26</sup>. It is important to note that when only one lateral incisor is absent, its counterpart usually presents anomaly of form (conoid) or size (microdontia)<sup>1,5,14-16,25</sup>. Some changes in the size of

mesiodistal crown of the other permanent teeth are also observed<sup>6,7,19,24</sup>. The diagnosis of this condition consists of clinical examination associated with radiographic examination and, more recently, cone beam computed tomography (CT) scan. Treatment of patients with unilateral or bilateral lateral incisors agenesis must be multidisciplinary, involving Orthodontics, Restorative Dentistry, Implantology and Prosthodontics.

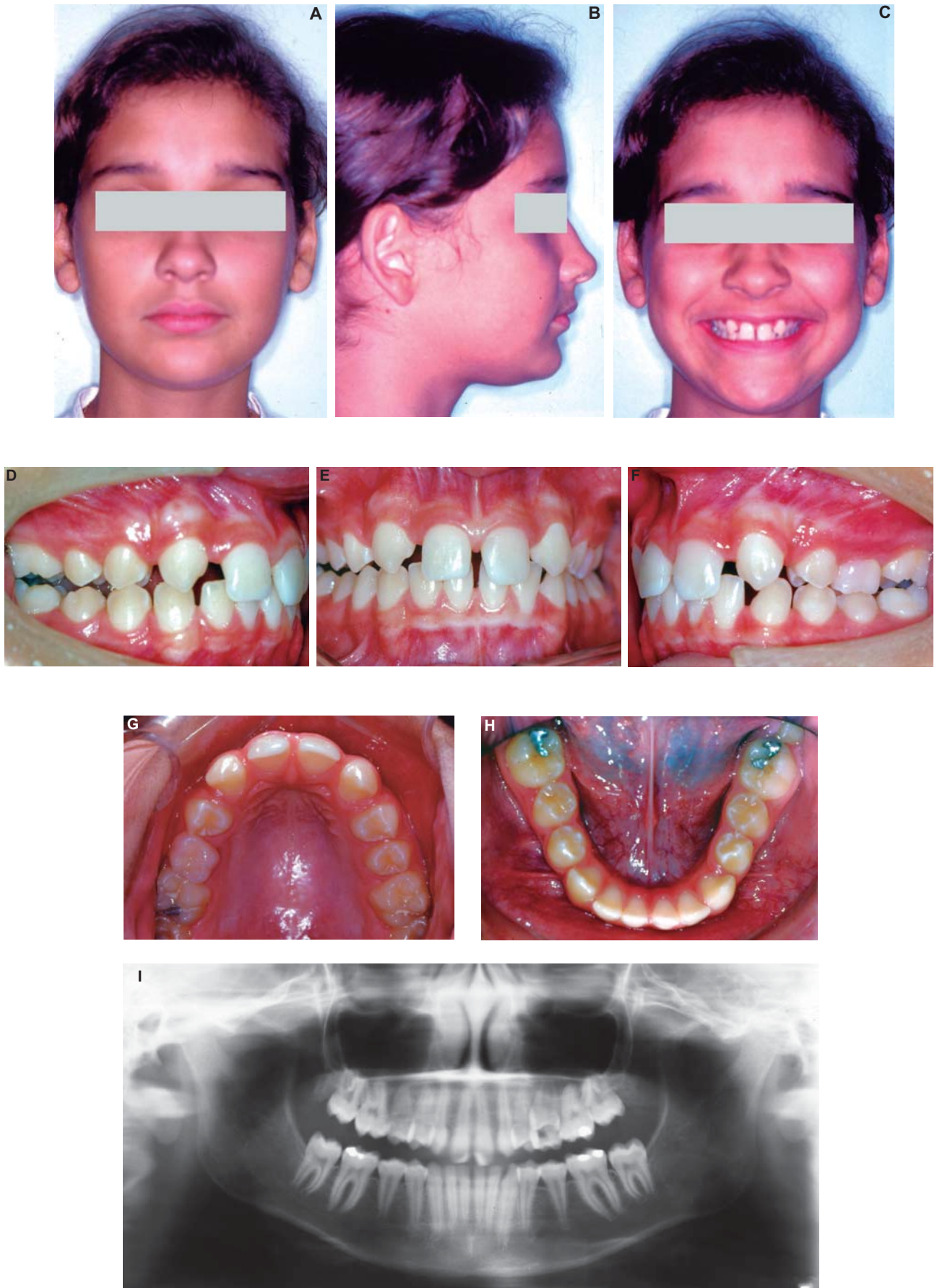There are many treatment options like spaces closure, using orthodontic mechanics, or the maintenance of these spaces for future prosthetic/implants rehabilitation<sup>2,3</sup>, and this should be discussed with the patient and/or parents. It is always important for the professional to explain the advantages and disadvantages of each option of treatment, as total treatment time and biological implications. Therefore, the most important treatment decisions must be linked to the long-term outcome, since change over time is normal in biologic systems. Obviously, issues such as molar and inter-arcs relationship, margin and gingival contour and aesthetics of the smile must be considered in order to define the best strategy for each patient. Conventional space closure for missing maxillary lateral incisors is a viable and safe procedure that provides satisfactory esthetic and functional long-term results<sup>4,13,18,20-23,27</sup>. Further improvements by orthodontists in tooth reshaping and positioning, and progress in restorative treatment with individual tooth bleaching and hybrid composite resin buildups demonstrate that quality treatment can be obtained when space closure is combined with esthetic dentistry<sup>10,20-22,27</sup>.

In this scenario, the aim of this study is to present a clinical case of bilateral maxillary lateral incisors agenesis, with a 14-year follow-up, treated satisfactorily with space closure involving orthodontics and esthetic dentistry procedures.

## CASE REPORT

### Diagnosis

A 12-year-old female patient in the late mixed dentition stage (second transitional period) was referred for treatment at CORA – Centro Odontológico Rodrigues de Almeida with a chief complaint of spacing between the upper anterior teeth (Figures 1A-H). Facial evaluation showed a mesofacial growth pattern, symmetrical and proportional face without upper central incisor exposure at rest and interlabial space of 0 mm (Figures 1A, B). Analysis of the smile showed 100% exposure of the upper incisors, generalized diastema, and midline sagittal plane coincident with the medium line of smile (Figure 1C). The patient had a convex facial profile and thin retruded lips (Figure 1B). Intraoral examination



**Figure 1-** Pretreatment facial (A-C) and intraoral (D-H) photographs. Initial panoramic radiograph (I)

revealed an Angle Class II relationship of molars and canines, 1 mm overjet, normal overbite, upper and lower coincident midline in relation to the facial plane (Figures 1D, E, F). Maxillary arch showed generalized spaces in the anterior region and missing lateral incisors (Figure 1G). In the lower arch, complete permanent dentition was observed, as well as the parabolic shape of the arch and diastema between the incisors (Figure 1H). The panoramic radiograph confirmed the bilateral agenesis of maxillary incisors (Figure 1I).

### Treatment objectives

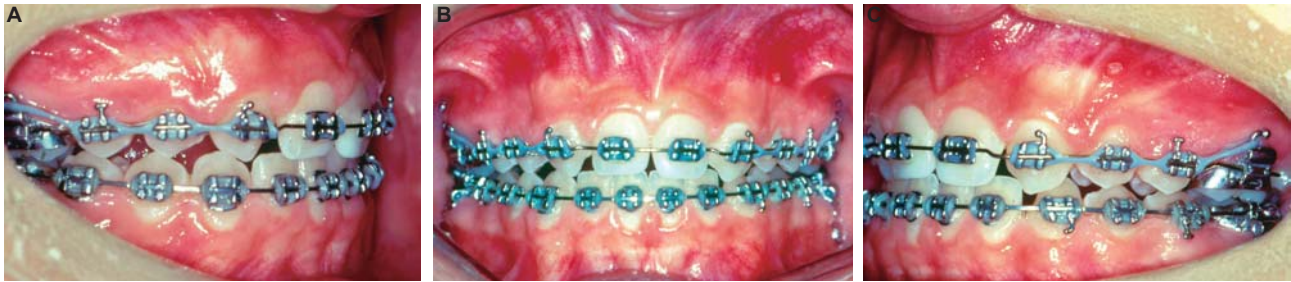According to the diagnosis, the aims of treatment of this clinical case included: space closure (the patient's chief complaint), smile's line and gingival level improvement, canines transformation/re-anatomization, lower arch midline, overjet and overbite maintenance.

### Treatment plan

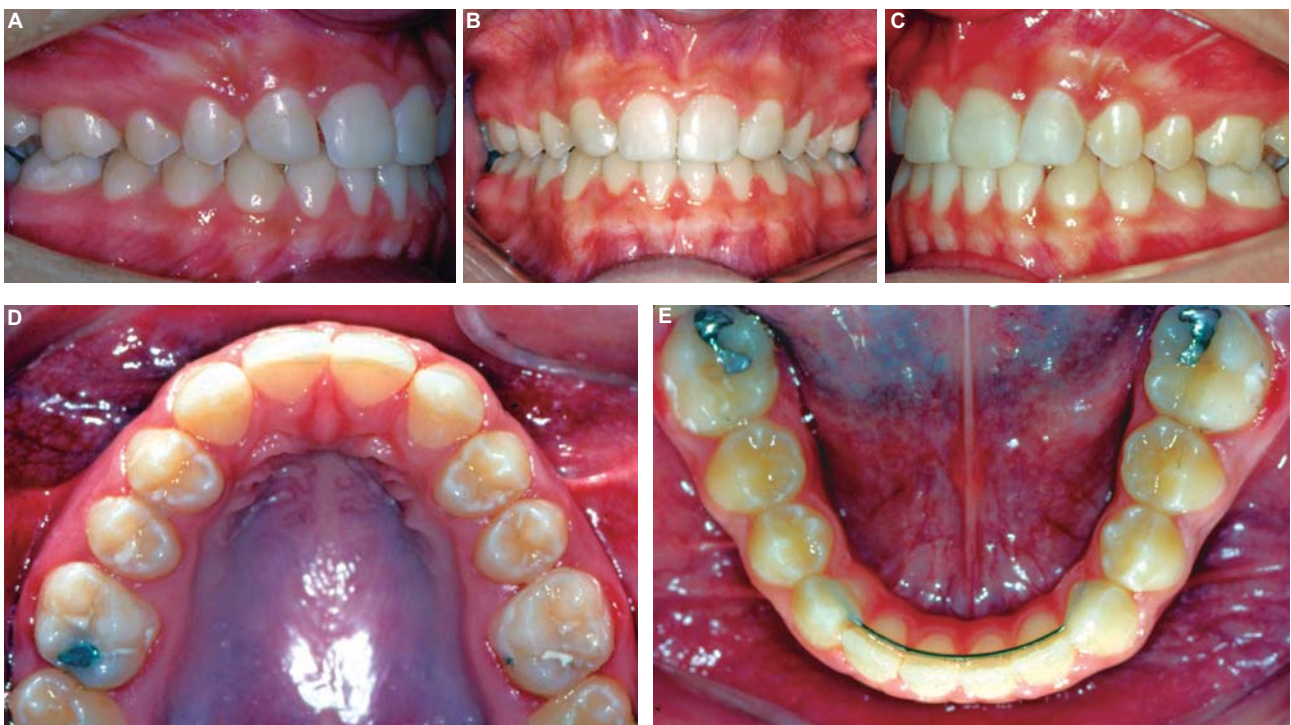The proposed treatment plan was the space closure of the areas corresponding to the missing upper lateral incisors, through movement of the canines and the posterior teeth to mesial. Upper and lower fixed appliance was installed with an Andrews 0.022-inch slot (3M-UNITEK, Monrovia, California, USA), Andrews prescription (Figure 2). After orthodontic correction, canines transformation/re-anatomization was performed.

### Orthodontic treatment progress

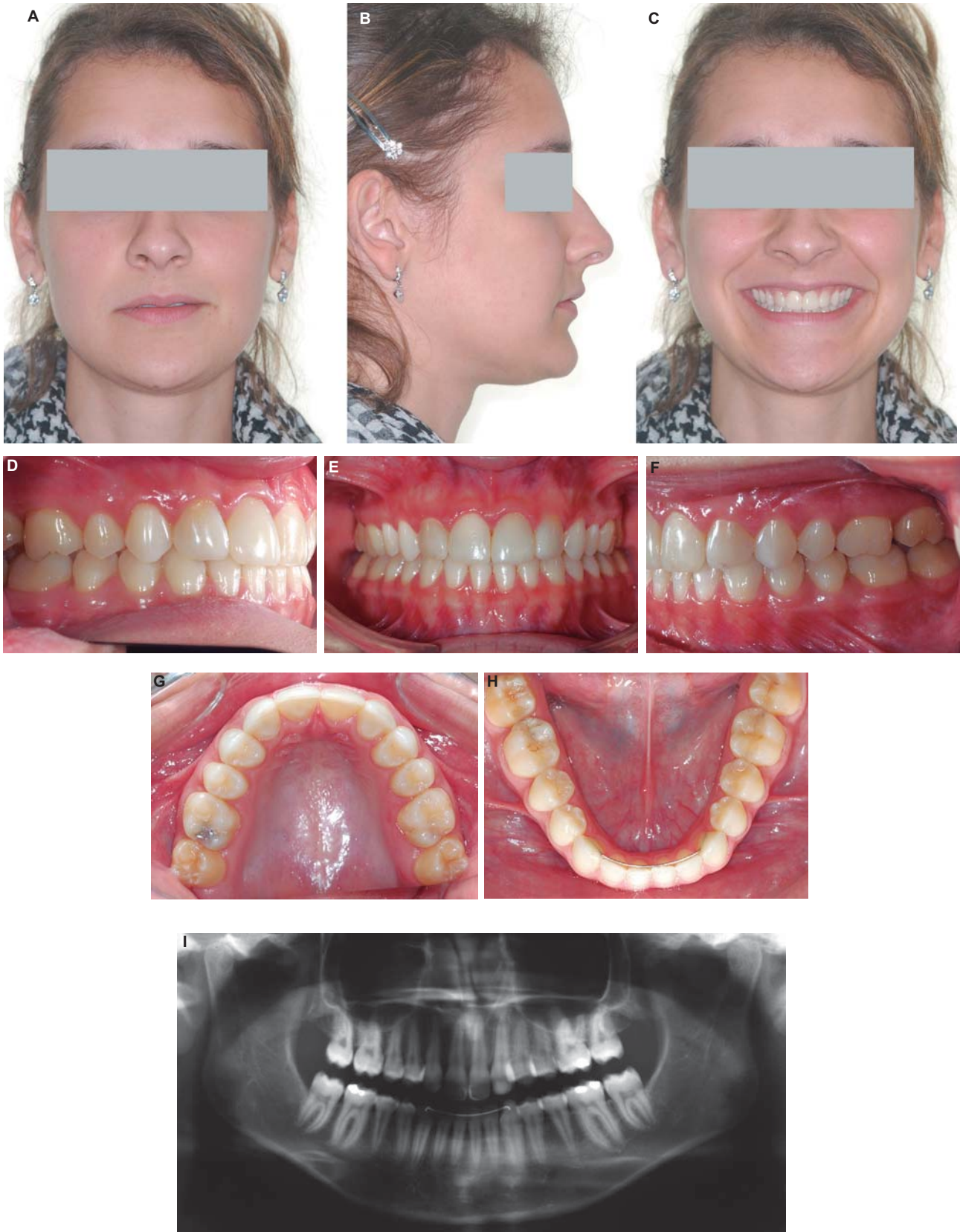
Upper arch was aligning and leveling with continuous arches using Nitinol and also stainless steel arches to perform bending and torque. Individualized canine extrusion and first premolar intrusion during the mesial movement of these teeth were used. Finishing phase was accomplished with an stainless steel braided 0.019x0.025-inch



**Figure 2-** Treatment Progress: Intraoral (A-C) photographs showing full fixed appliances. Upper stainless steel arch performing bends (individualized canine extrusion) to adequate placement of gingival margins



**Figure 3-** Post treatment intraoral (A-E) photographs showing proper crown torque of mesially relocated canines and premolars and an optimum level for the marginal gingival contours of the anterior teeth



**Figure 4-** 14-year follow-up involving orthodontics and restorative dentistry: Facial photographs showed a good facial profile (B) and proportional esthetic face (A). The analysis of the smile showed 100% exposure of the upper incisors with midline sagittal plane coincident with the medium line of smile (C). Intraoral photographs revealed optimal and stable occlusion with normal overbite and overjet (D-F) and maintenance of upper and lower arch shapes (G-H). Panoramic X-ray (I) showing ideal dental axial inclinations, confirming the stability of the closed spaces

archwire to provide intercuspation. Hawley plate was used for retention after appliance removal (Figure 3D).

Lower arch was aligning and leveling with 0.014-inch, 0.016-inch, 0.016x0.022-inch and 0.019x0.025-inch Nickel titanium (NiTi). Intercuspation/finishing was achieved with stainless steel braided archwire 0.019x0.025-inch. Fixed canine-to-canine retainer was bonded immediately after appliance removal (Figure 3E).

### Treatment results

Orthodontic treatment was conservative in this case, without extractions in the mandibular arch, also due to the good facial profile of the patient (Figure 1C). After upper and lower fixed appliances were placed (Figure 2A-C), the conventional mechanical technique for spaces closure was performed. This case's completion has kept the upper molars in an Angle Class II and canines were masked cosmetically as lateral incisors with restorative dentistry procedures (Figure 3A-C). Our decision to use the space closure treatment considered the improvement of orthodontic results by combining properly detailed orthodontic treatment with techniques from esthetic dentistry. The detailed orthodontic mechanics included: careful correction of the crown torque of mesially relocated canines to mirror the optimal lateral incisor crown torque, along with providing optimal torque and rotation for the mesially moved premolars; individualized extrusion and intrusion during the mesial movement of the canine and the first premolar, respectively, to obtain an optimum level for the marginal gingival contours of the anterior teeth. Some small esthetic repairs were performed after 10 years of initial re-anatomization in order to improve esthetic appearance (Figure 4A-H). The panoramic radiograph confirmed the stability of the closed spaces (Figure 4I).

### DISCUSSION

In the present report, the case was treated successfully with orthodontic space closure and transformation of the canines in lateral incisors. Thus, in agreement with some authors<sup>4,7,26</sup>, the treatment of these patients represents a challenge for orthodontists and specialists in esthetic dentistry. However, we think that the best treatment option for patients with agenesis of maxillary lateral incisor is, whenever possible, the orthodontical closing of spaces. Based on literature<sup>20-22,27</sup> and clinical evidence, we can highlight some advantages of this treatment option, such as better periodontal conditions of patients treated with space closure compared to patients treated with spaces maintenance and prosthetic rehabilitation,

obtaining excellent cosmetic and functional results after transforming the canine in the lateral incisor. Robertsson and Mohlin<sup>20</sup> (2000) pointed three advantages of space closure orthodontic treatment. They found that (1) the space-closure patients were more satisfied with the treatment results than the patients that had space opening for prosthetics rehabilitation, (2) there was no difference between the 2 groups in prevalence of signs and symptoms of temporomandibular joint dysfunction, and (3) patients with prosthetic replacements had impaired periodontal health with accumulation of plaque and gingivitis. So, they concluded that orthodontic space closure produces results that are well accepted by patients, does not impair temporomandibular joint function, and encourages periodontal health in comparison with the prosthetic replacements.

In cases of closure of spaces the following should be considered: (1) careful correction of the crown torque of mesially relocated canines to mirror the optimal lateral incisor crown torque, along with providing optimal torque and rotation for the mesially moved premolars, (2) canines bleaching, as these teeth are normally more yellowish than the incisors, (3) the relationship between space closure x treatment time, which generally can be increased, (4) the difficulty in mechanical posterior tooth rotation during the subsequent mesial movement, uncontrolled root of the first pre-molars that have two roots, and differential bracket bonding, where the canines receive the lateral incisor brackets. Usually there is the need for adjustments off set for the canines and first premolars, besides the need for canines extrusion and premolars intrusion to adjust the gingival level. Regarding canines mechanics, special attention should be given to the torque that the canines should receive, namely lingual root torque. The first premolars, in turn, will receive brackets for canines occupying an appropriate buccolingual and mesiodistal position, as they can be intruded and torqued to increase the gingival margin, similar to the canines. Later they must be transformed into canines with esthetic dentistry procedures.

Clinical experience has shown us that a good clinical outcome depends on various factors such as knowledge and professional skills involved in the treatment as well as the combination of orthodontic and esthetic dentistry techniques, patient's cooperation and age. The orthodontist should move the teeth mesially, characterizing the canine in the lateral incisor, considering torque and extrusion. Similarly, the premolar characteristics should be transformed in a canine, increasing intrusion and torque, to raise the gingiva, as previously mentioned. The dentist who performs the re-anatomization of the canines must pay attention to the teeth's shape and color. The



possible involvement of a periodontist may be necessary to obtain an adequate level and gingival contour (Figure 3).

The occlusion of a patient with lateral incisors agenesis orthodontically treated with posterior teeth's mesialization is satisfactory from the aesthetic and functional point of view. Long-term studies evaluated the periodontal status and occlusal function from 2 to 25 years post-treatment<sup>18,21</sup>, concluding that there is no functional overload in the premolar. However, in some patients, due to the discrepancy in teeth's size (Bolton), the case may be ended with a little overjet and overbite. Regarding retention, Hawley is usually utilized for the upper arch and a 3x3 in the lower arch, for continuous use.

## CONCLUSION

The treatment of patients with missing lateral incisors must be multidisciplinary. It can involve orthodontics, esthetic dentistry, implantology and prosthodontics. The interdisciplinary approach can achieve not only an optimal occlusion, but also a well-balanced, natural smile that will be stable over the long-term.

Treatment options to close spaces orthodontically or maintain these spaces for future prosthodontics rehabilitation should be discussed with the patient and/or parents. The orthodontist should explain all of the advantages and disadvantages of each treatment option. Some factors such as the need for extractions, the sagittal relationship of dental arches, the occlusal relationship of the posterior teeth, the position, shape and color of the canines, the amount of remaining space, patient age and analysis of the standard profile as well as the patient's face must be considered in treatment planning.

For all that was reported in this clinical case with a successful long-term follow-up, it is concluded that bilateral maxillary lateral incisors agenesis can be treated satisfactorily with space closure involving orthodontics and esthetic dentistry procedures.

## REFERENCES

- 1- Bailit HL. Dental variation among populations: an anthropologic view. *Dent Clin North Am*. 1975;19:125-39.
- 2- Borzabadi-Farahani A. Orthodontic considerations in restorative management of hypodontia patients with endosseous implants. *J Oral Implantol*. 2012;38(6):779-91.
- 3- Borzabadi-Farahani A, Zadeh HH. Adjunctive orthodontic applications in dental implantology. *J Oral Implantol*. 2013. Epub ahead of print.
- 4- Carlson H. Suggested treatment for missing lateral incisor cases. *Angle Orthod*. 1952;22:205-16.
- 5- Dermaut LR, Goeffers KR, De Smit AA. Prevalence of tooth agenesis correlated with jaw relationship and dental crowding. *Am J Orthodont Dentofac Orthop*. 1986;90:204-10.
- 6- Garib DG, Alencar, BM, Lauris JR, Baccetti T. Agnesis of maxillary lateral incisors and associated dental anomalies. *Am J Orthod Dentofacial Orthop*. 2010;137:732e1-6.
- 7- Garib DG, Peck S, Gomes SC. Increased occurrence of dental anomalies in patients with second premolar agenesis. *Angle Orthod*. 2009;79(3):436-41.
- 8- Garn SM, Lewis AB. The relationship between third molar agenesis and reduction in tooth number. *Angle Orthod*. 1962;32(1):14-8.
- 9- Graber LW. Congenital absence of teeth: a review with emphasis on inheritance patterns. *J Am Dent Assoc*. 1978;96:266-75.
- 10- Lopez SI, Mundstock KS, Paixão-Côrtes VR, Schüler-Faccini L, Mundstock CA, Bortolini MC, et al. MSX1 and PAX9 investigation in monozygotic twins with variable expression of tooth agenesis. *Twin Res Hum Genet*. 2013;16(6):1112-6.
- 11- Markovic M. Hypodontia in twins. *Swed Dent J Suppl*. 1982;15:153-62.
- 12- Mattheeuws N, Dermaut L, Martens G. Has hypodontia increased in Caucasians during the 20<sup>th</sup> century? A meta-analysis. *Eur J Orthodon*. 2004;26(1):99-103.
- 13- McNeill RW, Joondeph DR. Congenitally absent maxillary lateral incisors: treatment planning considerations. *Angle Orthod*. 1973;43:24-9.
- 14- Meskin LH, Gorlin RJ. Agnesis and peg-shaped permanent maxillary lateral incisors. *J Dent Res*. 1963;42:1476-9.
- 15- Montagu MF. The significance of the variability of the upper lateral incisor teeth in man. *Hum Biol*. 1940;12:323-50.
- 16- Mossey PA. The heritability of malocclusion: part 2. The influence of genetics in malocclusion. *Br J Orthod*. 1999;26(3):195-203.
- 17- Muller TP, Hill IN, Peterson AC, Bayney JR. A survey of congenitally missing permanent teeth. *J Am Dent Assoc*. 1970;81:101-7.
- 18- Nordquist, GG, McNeill, RW. Orthodontic vs restorative treatment of congenitally absent lateral incisors - long term periodontal and occlusal evaluation. *J Periodontol*. 1975;46:139-43.
- 19- Polder BJ, Van't Hof MA, Van der Linden FP, Kuijpers-Jagtman AM. A meta-analysis of the prevalence of dental agenesis of permanent teeth. *Community Dent Oral Epidemiol*. 2004;32(3):217-26.
- 20- Robertsson S, Mohlin B. The congenitally missing upper lateral incisor. A retrospective study of orthodontic space closure versus restorative treatment. *Eur J Orthod*. 2000;22:697-710.
- 21- Rosa M, Zachrisson BU. Integrating esthetic dentistry and space closure in patients with missing maxillary lateral incisors. *J Clin Orthod*. 2007;41:563-73.
- 22- Rosa M, Zachrisson BU. The space-closure alternative for missing maxillary lateral incisors: an update. *J Clin Orthod*. 2010;44:540-9.
- 23- Senty EL. The maxillary cuspid and missing lateral incisors: esthetics and occlusion. *Angle Orthod*. 1976;46:365-71.
- 24- Symons AL, Stritzel F, Stamation J. Anomalies associated with hypodontia of the permanent lateral incisor and second premolar. *J Clin Pediatr Dent*. 1993;17:109-11.
- 25- Vastardis H. The genetics of human tooth agenesis: new discoveries for understanding dental anomalies. *Am J Orthod Dentofacial Orthop*. 2000;117(6):650-6.
- 26- Woodworth DA, Sinclair PM, Alexander RG. Bilateral congenital absence of maxillary lateral incisors: a craniofacial and dental cast analysis. *Am J Orthod Dentofac Orthop*. 1985;87(4):280-93.
- 27- Zachrisson BU, Rosa M, Toreskog S. Congenitally missing maxillary lateral incisors: canine substitution. *Point*. *Am J Orthod Dentofacial Orthop*. 2011;139:434-45.