

Journal of Mind and Medical Sciences

Volume 7 | Issue 1

Article 17

2020

Therapeutic approach for Amyand's hernia; a case report

Sorin Berbece

DUNĂREA DE JOS UNIVERSITY OF GALAȚI, FACULTY OF MEDICINE AND PHARMACY, DEPARTMENT OF MORPHOLOGICAL SCIENCES, GALAȚI, ROMANIA

Valeriu Ardeleanu

VIDIUS UNIVERSITY, FACULTY OF MEDICINE AND PHARMACY, CONSTANȚA, ROMANIA

Vlad Denis Constantin

CAROL DAVILA UNIVERSITY OF MEDICINE AND PHARMACY, BUCHAREST, ROMANIA

Ioana Paunica

NATIONAL INSTITUTE OF DIABETES, NUTRITION AND METABOLIC DISEASES, BUCUREȘTI, ROMÂNIA

Alexandra Toma

DUNĂREA DE JOS UNIVERSITY OF GALAȚI, FACULTY OF MEDICINE AND PHARMACY, DEPARTMENT OF MORPHOLOGICAL SCIENCES, GALAȚI, ROMANIA

Follow this and additional works at: <https://scholar.valpo.edu/jmms>

 Part of the [Mental and Social Health Commons](#), [Nursing Commons](#), and the [Surgery Commons](#)

Recommended Citation

Berbece, Sorin; Ardeleanu, Valeriu; Constantin, Vlad Denis; Paunica, Ioana; and Toma, Alexandra (2020) "Therapeutic approach for Amyand's hernia; a case report," *Journal of Mind and Medical Sciences*: Vol. 7 : Iss. 1 , Article 17.

DOI: 10.22543/7674.71.P105109

Available at: <https://scholar.valpo.edu/jmms/vol7/iss1/17>

This Case Presentation is brought to you for free and open access by ValpoScholar. It has been accepted for inclusion in *Journal of Mind and Medical Sciences* by an authorized administrator of ValpoScholar. For more information, please contact a ValpoScholar staff member at scholar@valpo.edu.

Therapeutic approach for Amyand's hernia; a case report

Sorin Berbece¹, Valeriu Ardeleanu²⁻⁵, Vlad Denis Constantin⁶, Ioana Paunica⁷,
Alexandra Toma^{1,2}

¹DUNĂREA DE JOS UNIVERSITY OF GALAȚI, FACULTY OF MEDICINE AND PHARMACY, DEPARTMENT OF MORPHOLOGICAL SCIENCES, GALAȚI, ROMANIA

²C.F.R. HOSPITAL OF GALAȚI, DEPARTMENT OF SURGERY, GALAȚI, ROMANIA

³DUNĂREA DE JOS UNIVERSITY OF GALAȚI, DEPARTMENT OF KINETOTHERAPY, GALAȚI, ROMANIA

⁴OVIDIUS UNIVERSITY, FACULTY OF MEDICINE AND PHARMACY, CONSTANȚA, ROMANIA

⁵ARESTETIC CLINIC OF GALAȚI, GALAȚI, ROMANIA

⁶CAROL DAVILA UNIVERSITY OF MEDICINE AND PHARMACY, BUCHAREST, ROMANIA

⁷NATIONAL INSTITUTE OF DIABETES, NUTRITION AND METABOLIC DISEASES, BUCUREȘTI, ROMANIA

ABSTRACT



In very few cases stated in the literature, the vermiform appendix might be contained in a hernial sac. This distinctive pathology is described as Amyand's hernia and has the very small occurrence of about 1%. We report the case of a 62-year-old man that presented for a reducible tumoral mass located in the right inguinal region. Amyand's hernia was the intraoperative diagnostic. We performed hernioplasty (using the Lichtenstein tension-free mesh repair with a composite polypropylene mesh) without appendectomy. This case matches the type 1 Lossanoff and Basson's classification and has no facile management. Due to the clinical specificities of each case that presents with defining features of an Amyand's hernia, surgical management depends on the recommendations stated in the literature, as well as the surgeon's judgment based on experience.

Category: Case Report

Received: August 10, 2019

Accepted: October 02, 2019

Keywords:

Amyand's hernia, inguinal hernia, hernia sac, hernia surgery, hernioplasty, tension-free mesh

*Corresponding author:

Alexandra Toma, Dunărea de Jos University of Galați,
Faculty of Medicine and Pharmacy, Department of
Morphological Sciences, Galați, Romania
E-mail: dr.alexandratoma@gmail.com

Introduction

In 1735 Claudius Amyand - a noted surgeon of that period - practiced appendectomy on an 11-year-old male patient, diagnosed preoperatively with a right inguinal hernia [1]. The patient survived, but the hernia pathology reoccurred. The eponym Amyand's hernia refers to a condition characterized by the protrusion of the cecal appendix in the inguinal hernia sac. In such cases, the appendix may be normal, inflamed, or even perforated.

While the physiopathology remains imprecise, the literature notes that the vermiform appendix herniates through the processus vaginalis [2]. It is one of the rarest forms of inguinal hernias with an incidence varying between 0.19 – 1.7%, most often encountered in male patients [3, 4].

Patients usually present to the hospital with signs and symptoms that are no different from those encountered in a patient diagnosed with an inguinal hernia. Amyand's hernia can be diagnosed preoperatively using simple

imaging tests like ultrasonography and computed tomography. Sometimes, the clinical findings or even abdominal ultrasonography can lead to a misdiagnosis, as there are similarities between symptoms for Amyand's hernia and other conditions, including a cecum/ ascendant colon cancer, lymph metastasis from liver, or other abdominal cancer [5-12]. The intraoperative diagnosis is the most frequent way of carrying out a differential diagnosis.

Case presentation

A 62-year-old male presented to our surgery department complaining of an enlarging inguinal mass located in the right groin, accompanied by pain in the right inguinal area.

Based on anamnesis, he stated that the mass appeared for the first time in a very small area of the right inguinal region, about three years ago. The groin mass increased in size over time, with prolonged standing or even walking,

and finally, when the patient was doing the most normal and low demanding house chores. The patient had no history of chronic diseases or any associated comorbidities. In the last few days, he had been self-medicating with ibuprofen.

Upon physical examination, in the right inguinal area, we discovered that the region was deformed by a non-erythematous, non-fluctuant, slightly reluctant to fell, and mobile mass, with a diameter of about 4 cm x 5 cm. There were no signs of intestinal obstruction. We could also palpate the right inguinal foramen that was much weakened.

Laboratory test values showed normal limits; no additional imaging tests were performed due to patient history of uncomplicated inguinal hernia. We scheduled the patient for inguinal hernia surgery within a few days after admission.

On the day of surgery, the patient was transferred to the operating room, and the anesthesiology team opted for spinal anesthesia. Preoperative disinfection used a povidone-iodine solution. After careful draping of the patient, an incision was performed in the right inguinal region; within the inguinal canal, an oblique hernial sac was revealed. After dissection of the spermatic cord (slightly difficult due to a chronic process that resulted in multiple adhesions), we completed isolation of the hernial sac.

After opening the sac, we encountered a lipoma (an usual finding) and caecum and vermiform appendix that represent rare findings in an inguinal hernia sac (Figure 1, 2).

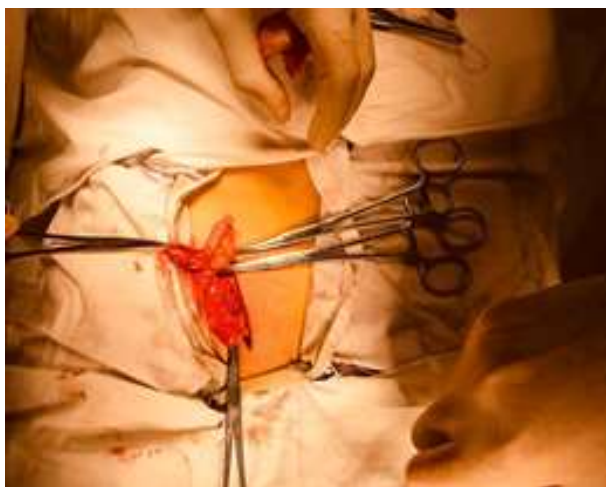


Figure 1. The content of the hernia sac

The intraoperative diagnosis was established based on the findings within the content of the hernial sac. Based on the international diagnostic criteria for this pathology, we classified it as a type 1 Amyand's hernia [13]. We did not perform an appendectomy because the appendix was

neither inflamed nor showed other signs of pathology. The intervention continued with herniorrhaphy (using the retro funicular procedure), followed by hernioplasty using the Lichtenstein tension-free mesh repair. The repair mesh was a composite polypropylene mesh.

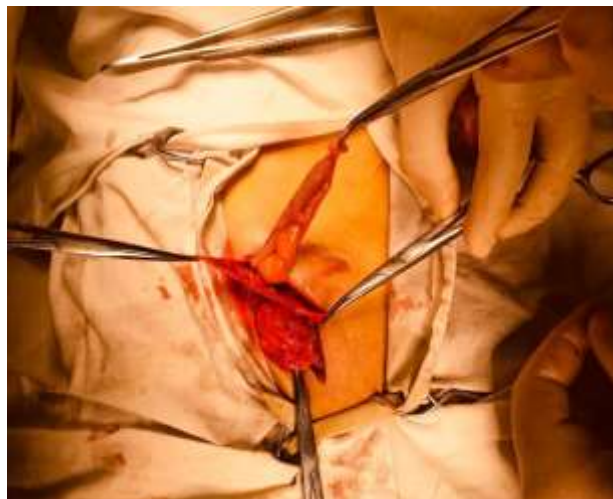

Figure 2. Vermiform appendix in the hernial sac

The postoperative period followed with no particular events or complications. The patient showed no sign of infection or inflammation and was able to move independently. The patient also quickly regained normal intestinal transit (i.e., he was able to feed normally). The surgical site evolved favorably so that he was discharged on the third postoperative day. At discharge, we advised the patient to avoid even small and insignificant movements or household tasks for about three months, so that hernia pathology would not recur.

Discussions

Amyand's hernia is a rare form of inguinal hernia, with low incidence and often difficulty to diagnosis. It is defined as the presence of the cecal appendix in a groin hernia, with or without appendicitis [3].

Garegeot, in 1731 [14], was the first to describe the occurrence of a non-inflamed vermiform appendix in a direct inguinal hernia sac. The name of the particular type of inguinal hernia described in this case study is derived from the French surgeon, Claudius Amyand, who was the first to perform an appendectomy on an 11-year-old patient with a perforated appendix within the inguinal hernial sac. Later, the Garegeot name was used to describe the type of femoral hernia that contains appendix in the hernial sac, while Amyand's hernia defines the inguinal hernia with vermiform appendix present in the sac.

Garegeot and Amyand are specific types of low incidence hernias. The presence of a cecal appendix in the

hernia sac is reported in about 1% (0.19 - 1.7%) of all cases of inguinal hernias [3,4]. The incidence of such types of hernias containing a perforated appendix is even lower (0.13%), but the prognosis for this pathology is quite severe, with severe abdominal sepsis and even high mortality (10-30%) [15]. The incidence of the disease is greater in men than women, with the prevalence of locating the hernia on the right side, a consequence of the normal anatomical position of the cecal appendix on the right side. Cases of Amyand's hernia have also been reported on the left side of the abdomen, resulting from situs inversus, intestinal malrotation, or mobile caecum [16-18].

The development of any type of hernia (common or rare) in the groin region does not usually produce a significant change in the quality of the patients' life during the initial stages, which could explain the late presentation for medical investigation. In initial and sometimes even complicated forms, inguinal hernias that include the vermiform appendix in the sac are often asymptomatic, with symptoms appearing only once the appendix is inflamed or perforated. Even in such cases, the symptoms for which the patient presents to the hospital are similar to incarcerated hernias: local erythema, swelling determined by an immobile mass, pain in the lower right abdominal quadrant, accompanied by nausea and vomiting.

Clinical manifestations, sometimes non-specific and insidious, often lead to difficulties in setting up a positive differential diagnosis, which may lead to the late establishment of the disease-specific therapeutic option. Children present more obvious symptoms and can mimic even acute scrotum [19]. In adults, the evolution of the disease usually has a gradual history, with patients often presenting to the hospital after years from the onset of the pathology and reporting episodes of expansion followed by reduction of the pseudo tumoral inguinal mass until incarceration of the hernia sac occurs.

From the perspective of associated pathology, Amyand's hernia can present as various clinical forms, from the presence in the hernia sac of the normal vermiform appendix to an inflamed appendix, leading finally to a necrotic or even perforated appendix [20, 21]. Some cases of associated tumors have also been described in the literature [22-24].

Imaging tests that include ultrasonography and computer tomography might show a tubular form structure originating at the caecum and extending into the hernial sac. A normal appendix cannot be easily visualized while performing ultrasonography, and this may lead to a misdiagnosis of Amyand's hernia. On the other hand, computer tomography can identify not only the structure but also the length and appearance of the vermiform

appendix by using multi-level reconstruction of the examined structures.

Surgical treatment must take into account two important aspects: the contents of the hernia sac (and the condition of the contained vermiform appendix), the necessity of restoring the abdominal content in its natural place, followed by a specific hernia surgical procedure tailored to the patient's needs.

The first classification of Amyand hernias, taking into account the type of hernia pathology, the associated manifestations, and the most advised surgical management, was generated by Lossanoff and Basson in 2008. They identified and defined four types: one with a normal appendix, and three types with inflamed appendix, and the last with associated conditions (Table 1).

Table 1. Lossanoff – Basson classification after Morales – Cardenas		
Classification	Description	Management
Type I	Normal appendix enclosed within the sac of an inguinal hernia	Hernioraphy, followed by mesh hernioplasty (free of choice: appendectomy in young patients)
Type II	Symptoms of acute appendicitis, no evidence of abdominal sepsis	Perform an appendectomy followed by a hernioplasty without a mesh
Type III	Symptoms of acute appendicitis, with evidence of abdominal sepsis	Perform an appendectomy followed by a hernioplasty without a mesh
Type IV	Symptoms of acute appendicitis, with affiliated abdominal pathology outside the hernial sac	Perform an appendectomy followed by a hernioplasty without a mesh. Subsequent - managing the affiliated pathology, after the initial procedure

There is general agreement regarding the surgical procedure for types III and IV, which consists of appendectomy and primary hernia repair, avoiding use of the mesh [4]. However, controversy surrounds surgical treatment for types I and II. There are case reports of a non-inflamed appendix present in the herniated sac, but with fibrous adhesions to it, which makes it impossible to release safely and thus required appendectomy [4, 13].

Several case reports of Amyand's hernia have taken a laparoscopic approach, with normal vermiform appendix contained in the hernia sac, or even Amyand's hernia

presented with acute appendicitis [14,25]. Some cases of Amyand's hernia have been resolved by using robotic surgery [26-28], which may involve a minimally invasive approach.

Highlights

- ✓ Amyand's hernia is a rare form of vermiform appendix hernia.
- ✓ Surgical treatment of Amyand's hernia depends on the contents of the hernia sac

Conclusions

Amyand's hernia is a very rare hernia pathology represented by the protrusion of the vermiform appendix in the hernia sac.

Studies suggest the need for adequate management of Amyand's hernia, in close connection with intraoperative observations. Most surgeons choose not to remove the appendix if they conclude that it is within normal characteristics. Some surgeons prefer appendectomy for all Amyand's hernias situated in the left inguinal region, while others suggest that appendectomy must be conducted only when the appendix is inflamed. The most encountered classification of the Amyand's hernia is the Lossanoff and Basson system that can assist in staging the pathology and also provides details on the management / surgical results. The final management decision must be made by the surgeon who relies on both the specialized literature for this field and surgical expertise.

Conflict of interest disclosure

There are no known conflicts of interest in the publication of this article. The manuscript was read and approved by all authors.

Compliance with ethical standards

Any aspect of the work covered in this manuscript has been conducted with the ethical approval of all relevant bodies and that such approvals are acknowledged within the manuscript.

References

1. Amyand C. Of an inguinal rupture, with a pin in the appendix caeci, incrusted with stone; and some observations on wounds in the guts. *Philosophical transactions*. 1736; 39(436-444): 329-42. doi: 10.1098/rstl.1735.0071
2. Ivanschuk G, Cesmebasi A, Sorenson EP, Blaak C, Loukas M, Tubbs SR. Amyand's hernia: a review. *Med Sci Monit*. 2014; 20: 140-146. doi: 10.12659/MSM.889873.
3. Patoulias D, Kalogirou M, Patoulias I. Amyand's Hernia: an Up-to-Date Review of the Literature. *Acta Medica (Hradec Kralove)*. 2017; 60(3):131-134. doi:10.14712/18059694.2018.7.
4. Shaban Y, Elkbuli A, McKenney M, Boneva D. Amyand's hernia: A case report and review of the literature. *Int J Surg Case Rep*. 2018; 47:92-96. doi: 10.1016/j.ijscr.2018.04.034.
5. Suceveanu AI, Pantea Stoian A, Parepa IR, Voinea C, Hainarosie R, Manuc D, Nitipir C, Mazilu L, Suceveanu AP. Gut Microbiota Patterns in Obese and Type 2 Diabetes (T2D) Patients from Romanian Black Sea Coast Region. *Rev Chim (Bucharest)*. 2018; 69(8): 2260-67.
6. Suceveanu AI, Mazilu L, Nitipir C, Pantea Stoian A, Parepa I, Voinea C, Suceveanu AP. Diabetes Mellitus raise the risk for Interval Colorectal Cancer and Advanced Adenomas. *Rev Chim (Bucharest)*. 2019; 70(5):1808-11.
7. Tuta LA, Iorga I, Azis O, Voinea F. End-of-life Care in Elderly Patients with End-Stage Renal Disease – Ethical and Clinical Issues. *SGEM 2015, Book 1: Psychology and Psychiatry, Sociology and Healthcare, Education Conference Proceedings, 1, 2015; pp. 487-493.*
8. Suceveanu AI, Pantea Stoian A, Mazilu L, Voinea F, Hainarosie R, Diaconu CC, Pituru S, Nitipir C, Badiu DC, Ceausu I, Suceveanu AP. Interferon-free therapy is not a trigger for hepatocellular carcinoma in patients with chronic infection with hepatitis C virus. *Farmacia*. 2018;66(5):904-908.
9. Mazilu L, Ciufu N, Galan M, Suceveanu AI, Suceveanu AP, Parepa IR, Tofolean DE. Posttherapeutic Follow-up of Colorectal Cancer Patients Treated with Curative Intent. *Chirurgia*. 2012;107(1):55-8.
10. Suceveanu AI, Suceveanu A, Voinea F, Mazilu L, Mixici F, Adam T. Introduction of cytogenetic tests in colorectal cancer screening. *J Gastrointest Liver Dis*. 2009;18(1):33-38.
11. Mazilu L, Parepa IR, Suceveanu AI, Suceveanu AP, Baz R, Catrinioiu D. Venous Thrombembolisms: secondary prevention with dabigatran vs. acenocumarol in patients with paraneoplastic deep vein thrombosis. Results from a small prospective study in Romania. *Cardiovascular Research*.2014;103(1):221.
12. Bolocan A, Paduraru DN, Nitipir C, Hainarosie R, Pituru SM, Diaconu C, Suceveanu AI, Pantea Stoian A. Mixed adenoneuroendocrine carcinoma of the gastrointestinal tract-features, diagnosis, management and prognostics. *Rom Biotech Lett*. 2018;23(6):14193-202.
13. Ardeleanu V, Chiccos S, Tutunaru D. et al. A rare case of acute abdomen: Garengot Hernia. *Chirurgia*. 2013;108(6):896-99.

14. Sahu D, Swain S, Wani M, Reddy PK. Amyand's hernia: Our experience in the laparoscopic era. *Journal of minimal access surgery*. 2015;11(2):151–53.
15. Rudiman R, Winata AA. Giant Left-Sided Amyand's Hernia: A Challenging Procedure in a Rural Hospital. *Case Rep Gastroenterol*. 2018;12(3):646-52.
16. Mongardini M, Maturo A, De Anna L, Livadoti G, D'Orazi V, Urciuoli P, Custureri F. Appendiceal abscess in a giant left-sided inguinoscrotal hernia: a rare case of Amyand hernia. *Springerplus*. 2015;26(4):378.
17. Kromka W, Rau AS, Fox CJ. Amyand's hernia with acute gangrenous appendicitis and cecal perforation: A case report and review of the literature. *Int J Surg Case Rep*. 2018;44:8-10.
18. Shaknovsky TJ, Sabido F, Shaikh D, Rosen PL. Robotic repair of Amyand's hernia: A case report. *J Case Rep Images Surg*. 2016;2:92–96.
19. Ardeleanu V, Chebac GR, Georgescu C, et al. The modifications suffered by the peri-esophageal anatomical structures in the hiatal hernia disease: a qualitative and quantitative microanatomic study. *Rom J Morphol Embryol*. 2010;51(4):765–770.
20. Maekawa T. Amyand's Hernia Diagnosed by Computed Tomography. *Intern Med*. 2017; 56(19): 2679-80.
21. Ardeleanu V, Francu L, Georgescu C. Neoangiogenesis. Assessment in Esophageal Adenocarcinomas. *Indian J Surg*. 2015; 77(Suppl 3): 971–976. doi:10.1007/s12262-014-1091-9.
22. Morales-Cárdenas A, Ploneda-Valencia CF, Sainz-Escárrega VH, et al. Amyand hernia: Case report and review of the literature. *Ann Med Surg (Lond)*. 2015;4(2):113–115. doi:10.1016/j.amsu.2015.03.007.
23. Ardeleanu V, Chebac GR, Francu L, et al. Neoangiogenesis. The quantitative microscopical modifications of the diaphragm and the periesophageal anatomical structures in hiatal hernias. Clinical correlations. *Chirurgia*. 2015;106:77-82.
24. Motofei IG, Rowland DL, Baconi DL, et al. Androgenetic alopecia; drug safety and therapeutic strategies. *Expert Opin Drug Saf*. 2018;17(4):407–412. doi:10.1080/14740338.2018.1430765
25. Bhatti SI, Hashmi MU, Tariq U, Bhatti HI, Parkash J, Fatima Z. Amyand's Hernia: A Rare Surgical Pathology of the Appendix. *Cureus*. 2018;10(6):e2827.
26. Socea B, Carap A, Bratu OG, Diaconu CC, Dimitriu M, Socea LI, Bobic S, Constantin VD. The role of the composite and biologic meshes in the trocar site hernia repair following laparoscopic surgery. *Revista de Materiale Plastice*. 2018;55(2):146-48.
27. KORKUT E, PEKSÖZ R, AKSUNGUR N. Iatrogenic diaphragmatic hernia and intestinal obstruction following laparoscopic hepatectomy: A case report. *J Clin Invest Surg*. 2019; 4(2): 127-131. doi: 10.25083/2559.5555/4.2/127.131
28. Socea B, Smaranda A, Nica AA, Bratu O, Diaconu C, Socea L, Dumitrescu D, Dimitriu M, Carâp A, Constantin V. Spiegel hernia – case presentation. *Arch Balk Med Union* 2018;53(1):152-154.