

# Journal of Mind and Medical Sciences

---

Volume 6 | Issue 2

Article 22

---

2019

## Conservative surgical treatment in cervical dysplastic lesions associated with cystoectocoele

Bogdan Marian Puca

Anca D. Braila

Cosmin V. Obleaga

Mihai Braila

Hany Saad

*See next page for additional authors*

Follow this and additional works at: <https://scholar.valpo.edu/jmms>

 Part of the [Obstetrics and Gynecology Commons](#), [Surgery Commons](#), and the [Urology Commons](#)

---

### Recommended Citation

Puca, Bogdan Marian; Braila, Anca D.; Obleaga, Cosmin V.; Braila, Mihai; Saad, Hany; Lungulescu, Cristian; and Deca, Mihai (2019) "Conservative surgical treatment in cervical dysplastic lesions associated with cystoectocoele," *Journal of Mind and Medical Sciences*: Vol. 6 : Iss. 2 , Article 22.  
DOI: 10.22543/7674.62.P340345  
Available at: <https://scholar.valpo.edu/jmms/vol6/iss2/22>

This Research Article is brought to you for free and open access by ValpoScholar. It has been accepted for inclusion in Journal of Mind and Medical Sciences by an authorized administrator of ValpoScholar. For more information, please contact a ValpoScholar staff member at [scholar@valpo.edu](mailto:scholar@valpo.edu).

---

# Conservative surgical treatment in cervical dysplastic lesions associated with cystoectocoele

## **Authors**

Bogdan Marian Puca, Anca D. Braila, Cosmin V. Obleaga, Mihai Braila, Hany Saad, Cristian Lungulescu, and Mihai Deca



Received for publication: March 18, 2019  
Accepted: July 11, 2019

## Research article

# Conservative surgical treatment in cervical dysplastic lesions associated with cystocele

Bogdan Marian Puca<sup>1</sup>, Anca Daniela Braila<sup>2</sup>, Cosmin Vasile Obleaga<sup>1</sup>, Mihai Braila<sup>2\*</sup>, Hany Saad<sup>3</sup>, Cristian Lungulescu<sup>4</sup>, Mihai Deca<sup>5</sup>

Craiova University of Medicine and Pharmacy, <sup>1</sup>Department of General Surgery, <sup>2</sup>Department of Obstetrics and Gynecology, <sup>3</sup>Craiova University of Medicine and Pharmacy, <sup>4</sup>Department of Oncology, <sup>5</sup>Department of Urology, Craiova, Romania

### Abstract

The treatment of cervical intraepithelial neoplasia aims at removing the squamocolumnar junction area, including abnormal tissues, up to the healthy tissue. Old postpartum perineal tears associated with cystocele, hypertrophic cervical elongation, and first and second degree uterine prolapse are pelvic static disorders. Particular aspects of pelvic-genital static disorder are related to the vulnerability of the pelvic-perineal floor during birth. On the occasion of birth, especially when there are different forms of dystocia during labor, the degradation of soft pelvic, genital, and vaginal-perineal tissues can occur.

The objective of this study was to re-evaluate the conservative treatment of cervical dysplasia, depending on the degree of cervical lesions, the surface extension, the age of the patients, and the pathology associated with cervical lesions – colpocele, cystocele, and urinary incontinence in the old postpartum perineal tears.

In order to solve the three types of concomitant lesions, we used the Manchester operation: the anterior colporrhaphy with the recalibration of the urethra and the suspension of the cystocele, the minimal colpectomy, the lesional cervical amputation with the anterior fixation of the parameters, and the posterior colpoperineorrhaphy with high myorrhaphy of the levator ani muscles. The decision on the management of cervical dysplasia has taken into account the degree of cervical lesions, the extension on the surface, the patients' age and the pregnancy planning, and the pathology associated with cervical lesions. The Manchester operation is a conservative surgical procedure, effective in women under 45 years old, multiparous, with present genital activity, with dysplastic cervical lesions and cystocele. It also solves cystocele, cervical dysplasia, hypertrophic cervical elongation, and first and second degree uterine prolapse.

### Keywords

: cervical dysplasia, cystocele, rectocele, conservative surgical treatment

### Highlights

- ✓ Triple surgery in Manchester is a surgical procedure indicated in patients under 45 years old, multiparous, with cervical and cystocele dysplasia.
- ✓ The management of cervical dysplasia depends on the degree and extent of the cervical lesions, the age of patients, the reproductive, menstrual and sexual functions, and the associated pathology.

**To cite this article:** Puca BM, Braila AD, Obleaga CV, Braila M, Saad H, Lungulescu C, Deca M. Conservative surgical treatment in cervical dysplastic lesions associated with cystocele. *J Mind Med Sci.* 2019; 6(2): 340-345. DOI: 10.22543/7674.62.P340345

✉ \*Corresponding author: Mihai Brăila, Craiova University of Medicine and Pharmacy, Department of Obstetrics and Gynecology, 2-4 Petru Rareș Street, 200349, Craiova, Romania  
E-mail: [ancabraila@yahoo.com](mailto:ancabraila@yahoo.com)

## Introduction

The treatment of cervical intraepithelial neoplasia aims at removing the squamocolumnar junction area, including abnormal tissues, up to healthy tissue. Cervical and vaginal cytological screening resulted in a significant reduction of the incidence and mortality rate by invasive cervical cancer (1). The notion of cervical dysplasia involves lesion of the squamous epithelium of the cervix, the precursor lesion of the invasive cancer, diagnosed through biopsy and histopathological examination. The severity of the intraepithelial lesion is classified as: mild dysplasia or CIN 1, moderate dysplasia or CIN 2, severe dysplasia or CIN 3, and carcinoma in situ (CIS). The neoplastic potential increases with the CIN (2) degree. Most cases of cervical neoplasia develop in the transformation area (TZ), adjacent to the squamocolumnar junction (SCJ) (3). Reserve cervical cells and immature metaplastic cells are vulnerable to the oncogenic effects of HPV and carcinogens (4).

Old postpartum perineal tears associated with cystoectocele, hypertrophic cervical elongation, and first and second degree uterine prolapse are pelvic static disorders. These disorders are a consequence of a complex pathology of anatomical-functional and topographic modification of the position of the normal genital organs in the pelvis, bladder and rectal ampulla, vaginal walls, their tendency to descend outside the pelvic-abdominal compartment and to be expelled in the external environment as in total genital prolapse, with the rise of static pressure intra-abdominal effort, coughing, sneezing, grunting, respiratory dysfunction, and constipation.

The substrate of these pelvic-genital disorders is dependent on several factors: the conformation of the pelvic-abdominal compartment in the human species related to the bipedal station, the intra-abdominal static pressure, the direction of the expulsion force in correlation with the bipedal station and the gravity, the counterpressure of the lower limbs, the musculo-conjunctive structure of the pelvic-perineal layer, rich in collagen, hyaluronic acid, elastin, orientation, fixation means, function of the internal genital organs, and urinary and low digestive organs in different biological periods of the woman's life (pregnancy, parturition, menopause). Particular aspects of pelvic-genital static disorders are related to the vulnerability of the pelvic-perineal floor during birth.

Normally, the uterus is in anteversion and antelexion. Deviations may occur from its normal position, either in the sagittal or frontal plane. In the sagittal plane, there are forward deviations (the inclination of the uterus towards

the axis of the excavation – hypertension or the inclination of the uterine body towards the cervix – hyperantelexion) and the backward deviations (the inclination of the uterus towards the excavation axis – the retroversion or inclination of the body towards the cervix – retroflexion).

The objective of this study was to re-evaluate the conservative treatment of cervical dysplasia, depending on the degree of cervical lesion, surface extension, patients' age, and the pathology associated with cervical lesions – colpocele, cystoectocele, and urinary incontinence in the old postpartum perineal tear.

## Materials and Methods

The study included 47 young women under 45 years old with present genital activity, 2/3 of the cases aged 41 to 45 years old. The analysis of the cases was carried out for 2 years, 2017-2018, in the surgical, urologic, and obstetric-gynecological clinics of Craiova County Emergency Clinical Hospital. The patients studied were those that had old perineal tears, cystoectocele, and cervical lesions. We have not included cases of effort urinary incontinence associated with the old perineal tears with cystoectocele at which the subcutaneous sling was imposed. We have also not included patients under 45 years in the study, nulliparous without cervical lesions and cystoectocele. Excluded from the study were those patients who did not show up at the planned schedules, and those with cervical, endometrial, or vulvo-vaginal cancer.

The obstetric history was recorded – the number of births (45% of the patients included in the study were multiparous), a history of general pathology – cardiopathy, nephropathy, pulmonary disease, obesity, diabetes, and varicose disease.

Symptoms for which patients were checked were: persistent and sometimes bloody leucorrhoea due to cervical lesions seen in 68% of the cases, vaginal pressure, dyspareunia, sexual dysfunction, pelvic pain, dysuria, increased urinary frequency, and urinary incontinence when making effort (present in over 30% of the cases). The valve examination revealed the anterior and posterior colpocele with cystoectocele, hypertrophic cervical elongation, and cervical dysplastic lesions.

The preoperative investigations were the usual ones – hematological, urinary, cervico-vaginal, and specific investigations – exfoliative cytology Babes-Papanicolau and Bethesda (most of the cases presented HSIL-38%), simple colposcopy (43% colposcopic coded lesions), with acetic acid, Lugol reagent, cervical, endocervical, endometrial biopsy, pelvic-genital, renal echography, EKG, pulmonary radiography, interdisciplinary

consultations – internal diseases, cardiology, nephrology, nutritional disorders and metabolism.

The diagnoses of admission in all cases were: old postpartum perineal tear, cystoectocele, cervical dysplasia, and cervical hypertrophic elongation. The essential condition of the diagnosis was the absence of cervical cancer, endometrium, neoplastic vulvovaginal lesions in young women under 45 years old with present genital activity.

The preoperative training consisted of psychological counselling and physical training: the evacuation of emunctories and local cleaning. Locoregional spinal anesthesia was provided.

The surgical techniques applied were: the anterior colporrhaphy with recalibration of the urethra – clogging in the cystocele, colpectomy depending on the excess of the vaginal mucosa. We performed the Kelly-Marion procedure. As a technical artifice, we tried to strengthen the clogging of the cystocele, passing a slowly absorbable Z-shaped thread over the already tight clogging (Aburel-Rebedea technique).

The cervical amputation consisted of performing a pericardial circular incision, high mucosal take-off to allow for wider collections of normal exocervical mucosa, and placing two Sturmdorff wires solid enough to cover the entire cervical blunt after amputation. We also preferred the placement of two slowly absorbable threads at the back of the cervix redone with normal mucosa. Depending on the degree of uterine prolapse, we fixed the parameters by bending to the anterior part of the cervix blunt before suturing the mucosa.

The posterior colpoperineorrhaphy with high myorrhaphy of the levator ani muscles – cutaneous-mucosal incision, vaginal mucosal detachment with progressive penetration into the levator ani muscles (“tunneling” was performed digitally to avoid breakage of hemorrhoid varicose packs at this level), high myorrhaphy with slowly resorbable threads, hemostasis control, vaginal and perineal repair with separate threads, endovaginal mesh and a 24-hour vesicle probe, and sterile dressing.

The postoperative treatment consisted of antibiotic therapy with urogenital spectrum, and anti-inflammatory and anticoagulant therapy for thromboprophylaxis in all cases. The periodic postoperative surveillance of patients followed the resting and recurrent cervical blunt or worsening of uro-genital symptomatology.

## Results

The 47 cases were divided into 3 groups according to the age of the patients: 8 cases (17%) of 30-35-year-old

patients, 10 cases (21%) of 36-40-year-old patients, and 29 cases (62%) of 41-45-year-old patients (Table 1).

**Table 1.** The distribution of patients by age group.

Age group	30-35 years	36-40 years	41-45 years	Total
No. cases	8	10	29	47
%	17%	21%	62%	100%

According to parity, we found 10 cases with one and two births (21%), 16 cases with three births (34%) and 21 with four and more births (45%) (Table 2).

**Table 2.** The distribution of patients by parity group.

Parity group	I P + II P	III P	>= IV P	Total
No. cases	10	16	21	47
%	21%	34%	45%	100%

According to their background, 35 cases were from rural areas (74%) and 12 from urban areas (26%).

The results of the cervical-vaginal cytology test were positive for epithelial cell abnormalities in the Bethesda classification as follows: atypia of undetermined squamous cells ASC-US in 10 cases (21%), atypia of squamous cells with a high-grade lesion ASC-H in 7 cases (15%), low-grade squamous intraepithelial L-SIL lesions in 12 cases (26%), and high-grade squamous intraepithelial H-SIL lesions in 18 cases (38%) (Table 3).

**Table 3.** The distribution of patients according to the results of the cervical-vaginal cytology test

Cytology	ASCUS	ASC-H	L-SIL	H-SIL	Total
No. cases	10	7	12	18	47
%	21%	15%	26%	38%	100%

The results of the histopathological examinations of the resected parts were: 12 cases (26%) of CIN 1 including HPV infection lesions, 15 cases (32%) CIN 2, and 15 cases (32%) CIN 3 and 5 cases CIS (11%) (Table 4).

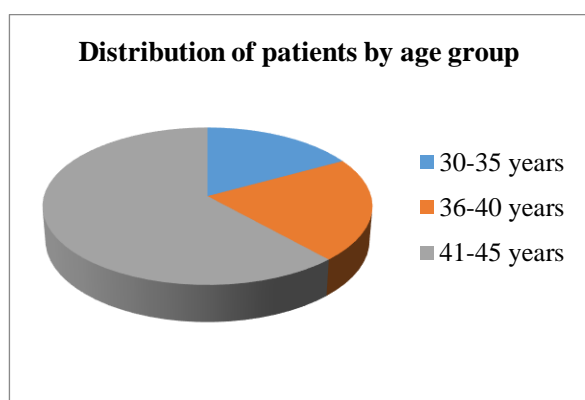
**Table 4.** The distribution of patients according to the results of the histopathological examinations.

HP results	CIN 1	CIN 2	CIN 3	CIS	Total
No. cases	12	15	15	5	47
%	26%	32%	32%	11%	100%

The postoperative evolution was favorable; the symptom that the patients had complained about disappeared and their general condition improved. Perineal gymnastics were recommended, i.e., Kegel exercises, rational physical effort, and treating conditions that increase intra-abdominal pressure were recommended.

## Discussions

The Manchester operation is beneficial to first and second degree uterine prolapse patients with cystocele who wish to maintain sexual function and preserve reproductive functions, thus conserving the uterus. We performed this surgery in younger patients under the age of 45, who wanted to keep their maternity, menstrual and sexual function, most of them in the 40-45 age group (29 patients, 62%) (Figure 1).

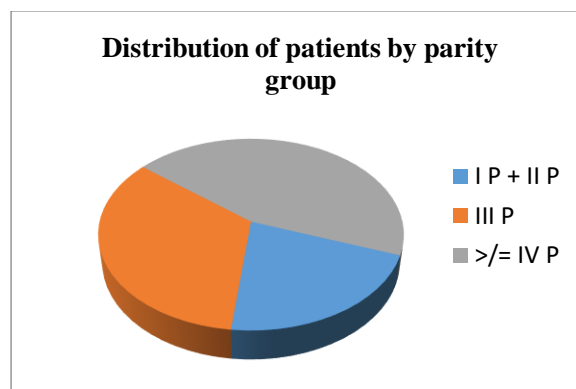


**Figure 1.** The distribution of patients by age group.

The advantages of this operation are that it does not penetrate into the peritoneal cavity, it does not cause postoperative morbidity, and the operating time is reduced. The cervical amputation performed in this operation allows the removal of dysplastic cervical lesions. Fractioned uterine curettage performed prior to surgery allows endometrial lesions such as endometrial hyperplasia or endometrial lesions (5, 6) to be excluded. Cervical-vaginal cytology, colposcopy, and cervical biopsy exclude invasive cervical cancer (7). Pelvic-genital echography, hormonal dosing, and tumor markers exclude appendage, uterine, and vulva-vaginal tumors (8, 9, 10, 11). The gestational factor determines the imbibition, relaxation and stretching of uterine suspension ligaments (uterosacral ligaments and cardinal ligaments), paracolpos, uro-genital diaphragm, and bladder-vaginal and recto-vaginal fascia. Parturition favors the prolapse of the vaginal and uterine walls by: mechanical trauma caused by the fetal skull during the passage through the pelvic-vaginal stage, ischemia caused by prolonged stinging of the fetal skull, iatrogenic precipitate expulsion, compression, stretching

and dilacerations of the suspension and muscular connective support of genital organs, and incorrect restoration of postpartum perineal tears.

The risk of prolapse increases significantly in women with vaginal birth (probability rate 2.8), two vaginal births (probability rate 4.1), three or more vaginal births (probability rate 5.3), compared to nulliparous women (12). In our study, the number of patients increased proportionally with the number of births, so patients with four or more births were the most numerous (21 cases, 45%) (Figure 2).

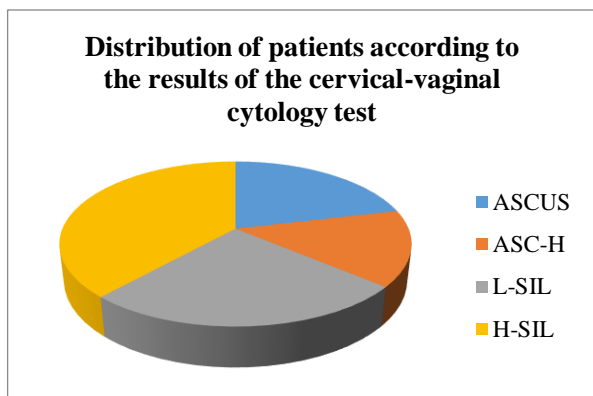


**Figure 2.** The distribution of patients by parity group.

On the occasion of births, especially when there are different forms of dystocia during labor, the degradation of the soft pelvic, genital, and vaginal tissues can occur. These changes, the occurrence of the old perineal tears with cystocele and effort urinary incontinence can be corrected surgically through the Manchester operation. All problems are solved except for the effort urinary incontinence, which requires at the same time an operator or later on, the installation of a transopturator tape (TOT) polyurethane sub-urethral bandage. The Manchester operation solves the anterior and posterior colpocele, with or without colpolectomy, which the medial-urethral sling does not solve.

We have not included in the study the cases of effort urinary incontinence associated with the postpartum perineal tears related to cystocele rupture for which a suburethral sling was imposed, the aim of the study being to solve cervical dysplasia, anterior and posterior colpocele, first and second degree uterine prolapse, and hypertrophic elongation of the cervix.

Vaginal surgery is preferred by most specialists to resolve cervical intraepithelial neoplasia by removing the cervical lesion and prolapse (13, 14, 15, 16). The amputation of the lesion of the cervix was performed after a preliminary investigation. In our group, cervical cytology was of the type: ASC-US, ASC-H, L-SIL, H-SIL, most patients presenting H-SIL type cervical-vaginal cytology (Table 3; Figure 3).

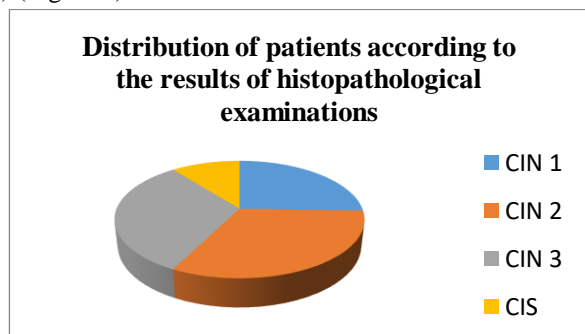


**Figure 3.** The distribution of patients according to the results of the cervical-vaginal cytology test

In order to solve the three types of concomitant lesions, we used the Manchester operation: the anterior colporrhaphy with the recalibration of the urethra and the cessation of the cystocele, minimal colpectomy, cervical amputation with the anterior fixation of the parameters, the posterior colpoperineorrhaphy with the high myorrhaphy of the levator ani muscles. The vital and functional prognosis was favorable.

Randomized studies suggest that the anatomical solution of cystocele by anterior colporrhaphy is obtained in no more than 50% of the cases (17). In other randomized studies, mesh consolidation compared to the traditional previous colporrhaphy offered only a modest improvement rate of 15-23% (17, 18, 19). Other authors have not reported any improvement in the rate of surgical success when using synthetic mesh prosthesis (20). Consideration should also be given to the risks of erosion and over-infestation caused by the mesh (21).

The Manchester operation solves the discomfort created by the postpartum perineal tears associated with cystoectocele and first and second degree uterine prolapse along with cervical dysplasia in women under 45 years old. In the cases studied in our group, the histopathological examination of the resected parts revealed CIN 1, CIN 2, CIN 3, and CIS, most cases being CIN 2 and CIN 3 (Table 4) (Figure 4).



**Figure 4.** The distribution of patients according to the results of histopathological examinations

Regarding previous colpectomy in younger patients, we consider necessary minimal colpectomy to provide an efficient bladder-suburethral support base, while large colpectomy provides more disservice than benefits, causing sexual discomfort, dyspareunia and dysuria.

Post-therapeutic cervical stump monitoring is required (22), cytological screening should be performed for at least 20 years because there is an increased risk of cervical neoplasia after a high-grade CIN diagnosis (23).

## Conclusions

The decision on the management of cervical dysplasia has taken into account the degree of cervical lesions, the extension on the surface, the age of the patients and the pregnancy planning, and also the pathology associated with cervical lesions.

The Manchester operation is a conservative surgical procedure, effective in women under 45 years old, multiparous, with present genital activity, and with dysplastic cervical lesions and cystoectocele.

At the same time, the procedure solves cystoectocele, cervical dysplasia, hypertrophic cervical elongation, and first and second degree uterine prolapse. The vital and immediately functional and far-reaching prognosis is favorable.

## Acknowledgements

All authors have contributed equally to this paper.

## Conflict of interest disclosure

There are no known conflicts of interest in the publication of this article. The manuscript was read and approved by all authors.

## Compliance with ethical standards

Any aspect of the work covered in this manuscript has been conducted with the ethical approval of all relevant bodies and that such approvals are acknowledged within the manuscript.

## References

1. Saslow D, Runowicz CD, Solomon D, Moscicki AB, Smith RA, Eyre HJ, Cohen C; American Cancer Society. American Cancer Society guideline for the early detection of cervical neoplasia and cancer. *CA Cancer J Clin.* 2002; 52(6): 342-62.
2. Hall JE, Walton L. Dysplasia of the cervix: a prospective study of 206 cases. *Am J Obstet Gynecol.* 1968; 100(5): 662-71.

3. Anderson MC. The cervix, excluding cancer. In Anderson MC (Eds): Systematic Pathology-Female Reproductive System. Churchill Livingstone. 1991. New York. 47.
4. Stanley M. Pathology and epidemiology of HPV infection in females. *Gynecol Oncol.* 2010; 117: S5-10.
5. Brăila AD, Vaniova Klimentova D, Damian CM, Brăila M. Endometrial proliferative lesions associated with uterine fibromatosis. *RJME.* 2012; 53(3), Supp: 743 – 747.
6. Neacșu A, Marcu ML, Stănică CD, Brăila AD, Pacu I, Ioan RG, Grigorescu CC, Ionescu CA. Clinical and morphological correlations in early diagnosis of endometrial cancer. *RJME.* 2018; 59(2): 527-531.
7. Braila AD, Marinov Krastev B, Mihai-Zamfir E, Caraveteanu DC, Nawaf Al Krayem, Braila M, Velea R, Neacsu A. Uteroplacental apoplexy associated with invasive cervical neoplasm. *RJME.* 2017; 58(4): 1465-1470.
8. Vaniova Klimentova D, Brăila AD, Simionescu C, Ilie I, Brăila M. Clinical and paraclinical study regarding the macro and microscopic diagnosis of various anatomo-clinical forms of operated uterine fibromyoma. *RJME.* 2012; 53(2): 369–373.
9. Braila AD, Ionescu CA, Calin A, Musetescu AE, Lungulescu C, Braila M, Navolan D, Neacsu A. Hormonal Biochemical Markers In Ectopic Pregnancy Monitoring. *Rev. Chim.* 2018; 69(6): 1558-1561.
10. Herghelegiu CG, Neacsu A, Oprescu ND, Carbutaru AE, Braila AD, Curea FG, Marcu ML, Ioan RG, Bohiltea RE. Difficulties of clinical and histopathological diagnosis in advanced vulvar clear cell carcinoma. *RJME.* 2018; 59 (4): 1233-1238.
11. Brăila AD, Brăila M, Cornițescu F. Benign ovarian tumors. Anatomo-clinical, diagnosis, and therapeutical aspects. *Gineco.eu.* 2008; 4(3): 178–185.
12. Rotveit G, Brown JS, Thom DH. Symptomatic pelvic organ prolapse: prevalence and risk factors in a population-based, racially diverse cohort. *Obstet Gynecol.* 2007; 109(6): 1396-403.
13. Olsen AL, Smith VJ, Bergstrom JO. Epidemiology of surgically managed pelvic organ prolapsed and urinary incontinence. *Obstet Gynecol.* 1997; 89(4): 501-6.
14. Brown JS, Waetjien LE, Subak LL. Pelvic organ prolapsed surgery in the United States, 1997. *Am J Obstet Gynecol.* 2002; 186(4): 712-6.
15. Boyles SH, Weber AM, Meyn L. Procedures for pelvic organ prolapsed in the United States, 1979-1997. *Am J Obstet Gynecol.* 2003; 188(1): 108-15.
16. Brubaker L, Bump R, Fynes M. Surgery for pelvic organ prolapsed. In Abrams P, Cardozo L, Khoury W (Eds): 3rd International Consultation on Incontinence. Paris: Health Publication, 2005b, pp. 1371.
17. Weber AM, Walters MD, Piedmonte MR: Anterior colporrhaphy: a randomized trial of three surgical techniques. *Am J Obstet Gynecol.* 2001; 185(6): 1299-304.
18. Sand PK, Koduri S, Lobel RW. Prospective randomized trial of polyglactin 910 mesh to prevent recurrence of cystoceles and rectoceles. *Am J Obstet Gynecol.* 2001; 184(7): 1357-62.
19. Altman D, Vayrynen T, Engh ME. Anterior colporrhaphy versus transvaginal mesh for pelvic-organ prolapsed. *N Engl J Med.* 2011; 364(19): 1826-36.
20. Gandhi S, Goldberg RP, Kwon C. A prospective, randomized trial using solvent dehydrated fascia lata for the prevention of recurrent anterior vaginal wall prolapsed. *Am J Obstet Gynecol.* 2005; 192(5): 1649-54.
21. Ciuhu AN, Pantea-Stoian AM, Nitipir C. et al. Assessment of cachexia in cancer patients with advanced disease. Interdiab 2017: Diabetes mellitus in internal medicine Book Series: International Conference on Interdisciplinary Management of Diabetes Mellitus and its Complications Pages: 139-147. Published: 2017
22. Wright TC Jr, Massad S, Dunton CJ, Spitzer M, Wilkinson EJ, Solomon D; 2006 American Society for Colposcopy and Cervical Pathology-sponsored Consensus Conference. 2006 consensus guidelines for the management of women with abnormal cervical cancer screening tests. *Am J Obstet Gynecol.* 2007b; 197(4): 346-55.
23. American College of Obstetricians and Gynecologists. Cervical cytology screening. Practice Bulletin No, 109, december 2009.