

# Journal of Mind and Medical Sciences

Volume 5 | Issue 1

Article 6

## Mandatory multidisciplinary approach for the evaluation of the lymph node status in rectal cancer

Marian Diaconescu

*Craiova University of Medicine and Pharmacy, Department of General Surgery*

Cosmin V. Obleaga

*Craiova University of Medicine and Pharmacy, Department of General Surgery*

Cecil S. Mirea

*Craiova University of Medicine and Pharmacy, Department of General Surgery, cecil\_mirea@yahoo.com*

Mihai C. Ciorbagiu

*Craiova University of Medicine and Pharmacy, Department of General Surgery*

Emil Moraru

*Craiova University of Medicine and Pharmacy, Department of General Surgery*

*See next page for additional authors*

Follow this and additional works at: <https://scholar.valpo.edu/jmms>

 Part of the [Digestive System Commons](#), [Gastroenterology Commons](#), [Oncology Commons](#), and the [Surgery Commons](#)

### Recommended Citation

Diaconescu, Marian; Obleaga, Cosmin V.; Mirea, Cecil S.; Ciorbagiu, Mihai C.; Moraru, Emil; and Vilcea, Ionica D. () "Mandatory multidisciplinary approach for the evaluation of the lymph node status in rectal cancer," *Journal of Mind and Medical Sciences*: Vol. 5 : Iss. 1 , Article 6.

DOI: 10.22543/7674.51.P2938

Available at: <https://scholar.valpo.edu/jmms/vol5/iss1/6>

This Review Article is brought to you for free and open access by ValpoScholar. It has been accepted for inclusion in Journal of Mind and Medical Sciences by an authorized administrator of ValpoScholar. For more information, please contact a ValpoScholar staff member at [scholar@valpo.edu](mailto:scholar@valpo.edu).

---

# Mandatory multidisciplinary approach for the evaluation of the lymph node status in rectal cancer

## **Cover Page Footnote**

All authors contributed equally to the manuscript.

## **Authors**

Marian Diaconescu, Cosmin V. Obleaga, Cecil S. Mirea, Mihai C. Ciorbagiu, Emil Moraru, and Ionica D. Vilcea



## Review

# Mandatory multidisciplinary approach for the evaluation of the lymph node status in rectal cancer

Marian Diaconescu<sup>1</sup>, Cosmin V. Obleaga<sup>1</sup>, Cecil S. Mirea<sup>1</sup>, Mihai C. Ciorbagiu<sup>1</sup>, Emil Moraru<sup>1</sup>, Ionica D. Vilcea<sup>1</sup>

<sup>1</sup>Craiova University of Medicine and Pharmacy, Department of General Surgery, Craiova, Romania

### Abstract

Colorectal cancer is the third most frequently reported malignancy and also the third leading cancer-related cause of death worldwide. Lymph node evaluation, both preoperatively and postoperatively, represents an important aspect of the diagnosis and therapeutic strategy in colorectal cancer, such that an accurate preoperative staging is required for a correct therapeutic strategy. Treatment of rectal cancer with positive lymph nodes, a very important predictive prognostic parameter, is currently based on neoadjuvant chemoradiotherapy followed by total/surgical mesorectal excision and adjuvant regimen.

Preoperative evaluation of the lymph node status in rectal cancer is based on endoscopic ultrasound and magnetic resonance imaging, but their accuracy, specificity, and sensitivity still require improvement. Postoperative evaluation also presents points of debate, especially related to the role of sentinel lymph node mapping and their final implication, represented by detection of micrometastases and isolated tumor cells. The pathologic interpretation of tumor deposits represents other points in discussion. From a surgical perspective, extended lateral lymph node dissection vs. abstinence and (neo)adjuvant therapeutic approach represent another unresolved issue.

This review presents the major controversies existing today in the treatment and pathologic interpretation of the lymph nodes in rectal cancer, the role/ indication and value of the lateral pelvic lymph node dissection, and the postoperative interpretation of the value of the micrometastatic disease and tumor deposits.

**Keywords** : rectal cancer, lymph node evaluation, lateral lymph node dissection, sentinel lymph node mapping, micrometastases

**Highlights**

- ✓ Despite important progress made in the evaluation and prognostic interpretation of lymph nodes in rectal cancer, many controversial and unresolved aspects remain, requiring future clarification.
- ✓ An accurate interpretation requires better standardization than is now offered by current staging systems, as suggested in this review.

**To cite this article:** Diaconescu M, Obleaga CV, Mirea CS, Ciorbagiu MC, Moraru E, Vilcea ID. Mandatory multidisciplinary approach for the evaluation of the lymph node status in rectal cancer. J Mind Med Sci. 2018; 5(1): 29-38. DOI: 10.22543/7674.51.P2938

## Introduction

Colorectal cancer is the third most common malignancy reported at all sites, for both sexes, and also the third leading cancer-related cause of death (1-3). The incidence of rectal cancer in USA is about 12.3% per 100,000 people, with an estimated 39,610 new cases in 2015 (1, 4). Rectal topography represents between 17-41% of the colorectal cancer cases, depending on the patient's age and sex (the proportion is higher in younger patients and in men). Almost 33% of the rectal cancers will have regional spread at the time of the diagnosis, associated with a 5-year relative survival rate of 69.5% (4). The T stage and high-grade pathology represent the most important independent predictive factors for the risk of lymph node involvement (5).

Lymph node involvement represents one of the most important predictive parameters for survival: the 5-year overall survival rates varies significantly from 74% if nodal spread is absent (N0), to 64% if only 1-3 lymph nodes are invaded (N1), and drops to 48% if more than 4 lymph nodes are invaded (N2); at the same time the local recurrence rates will significantly increase from 9% if N0, to 11% if N1, and 13% if N2 (6).

The treatment of rectal cancer with positive lymph nodes is based in most centers on neoadjuvant chemoradiotherapy, followed by rectal resection with total mesorectal excision and adjuvant regimen. Some centers apply extended lateral lymph nodes dissection. Adequate treatment is based on the correct preoperative evaluation of the lymph nodes basin which can be influenced by many factors. The significance of an adequate evaluation of the lymph node status in rectal cancer is emphasized by the SEER analysis results that show important declines in the 5-year relative survival rates in cases with incorrect evaluation of the lymph nodes (Nx): 23.8-89.4%, almost similar with N2 stage, depending on the T stage of the tumor (7). The evaluation of the lymph node involvement begins preoperatively, but continues intraoperatively and with postoperative histologic examination.

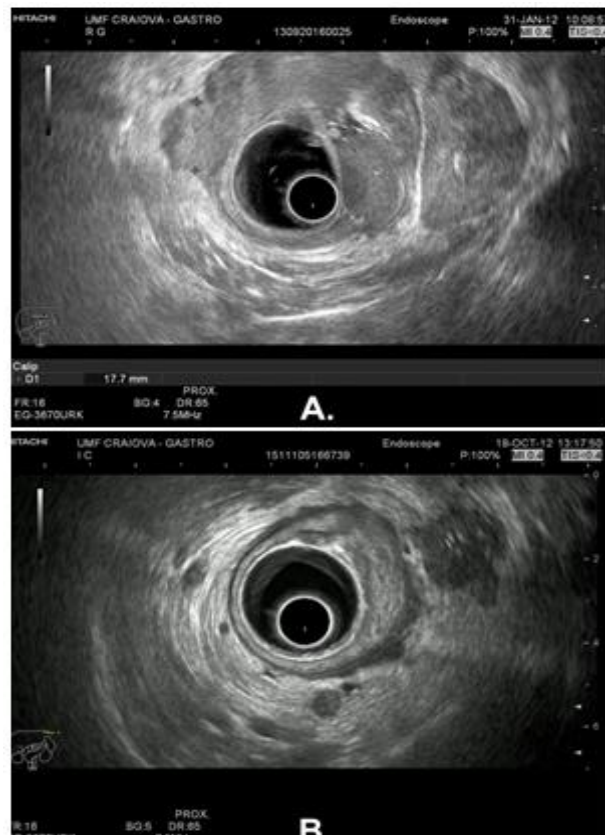
## Discussion

### *Pretherapeutic evaluation of the lymph node status in rectal cancer*

Preoperative evaluation of lymph node status in rectal cancer is based on imaging modalities, clinical examination having limited value. The main imaging modalities used for TNM staging in rectal cancer are endoscopic rectal ultrasound (ERUS), magnetic resonance imaging (MRI), computed tomography (CT), and Positron emission tomography-computed tomography (PET-CT). The accuracy of the abdominal

CT in predicting the N stage is low, between 53%-73%, with an important percentage of cases overstaged (16%) or understaged (10%) and a sensitivity of 17%-33% and specificity of 81% (8, 9). In a randomized trial FoxTROT, 83% of the pN+ were radiologically classified as cN+, but with the same tendency of overstaging the N stage (10). Nevertheless, the abdominal CT appears to be the most frequently used staging modality in rectal cancer centers (55% of centers use abdominal CT in all cases of rectal cancer for staging purposes) (11).

PET/CT manifests also a lower accuracy (60-66%), specificity (81-90%), and sensitivity (33%) in detecting lymph node invasion in colorectal cancer (8) and represents the least common imaging method used for preoperative staging of rectal cancer: only 1% of centers use PET/CT for preoperative staging of all rectal cancer cases (11). ERUS probably represents the best preoperative staging modality for small rectal tumors (T1 and T2); the incidence of lymph node metastases in these cases varies from 14.3% to 18.4% (12). However, the usage of ERUS as a staging method in all rectal cancer cases varies from 21% to 43% in colorectal cancer centers (11).



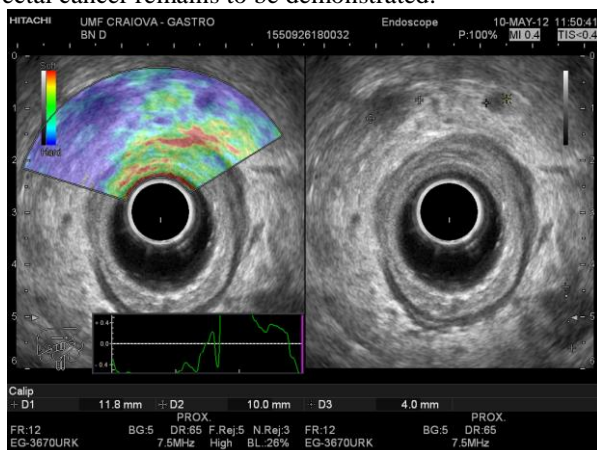
**Figure 1.** Endoscopic ultrasound in rectal cancer.

**A.** A rectal adenocarcinoma invading all layers of the rectal wall (T3) with cleavage plane with the prostate and peritumoral lymphadenopathy  
**B.** Multiple suspected (round, hypoechoic) lymph nodes in a patient with a rectal adenocarcinoma.

ERUS has a 73%-76.47% accuracy in detecting lymph node metastases in rectal cancer, with a sensitivity of 52.94%-77% and a specificity of 70%-84.31% (13, 14). The value of ERUS in the N staging of rectal cancer is influenced by the experience of the examiner and the tumor morphology (i.e., it is lower in large-stenosing tumors that do not allow the probe to pass through the lumen). Also, it may be difficult to differentiate malignant lymph nodes from benign ones, the malignant appearance being suggested by the lymph node morphology and size: round, hypoechoic lymph nodes, larger than 3-5 mm present a higher probability of malignant colonization.

In order to improve the N staging, other modalities may be used in association, such as fine-needle aspiration cytology of the detected lymph nodes which may increase the accuracy of the ERUS in detecting colonized lymph nodes by up to 90%, with a sensitivity of 87%, and a specificity of 100% (15). Also, using 3-D endoscopic ultrasound, the accuracy of the nodal detection may increase up to 87.3%, specificity up to 91.4%, and sensitivity up to 79.1% (16).

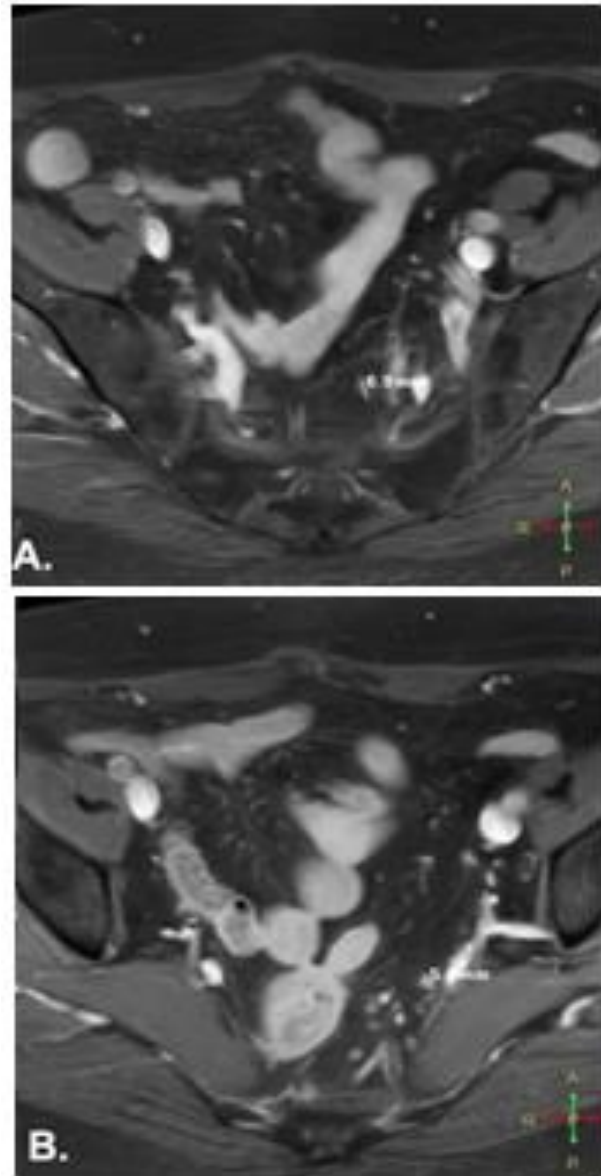
Endoscopic Ultrasound Elastography (EUS elastography) has proven to be a reliable method for differentiating rectal adenomas from adenocarcinomas (17), with an accuracy of 0.94, a sensitivity of 0.96, and a specificity of 0.86. Furthermore, in differentiating benign from malignant lymph nodes, elastography presented a sensitivity of 70.2-85% and a specificity of 91-100%, depending on the elastography score, with the lowest sensitivity (60%) and specificity (31.5%) for a score 2 (18, 19). However, the role of ERUS elastography in the evaluation of the lymph nodes in rectal cancer remains to be demonstrated.



**Figure 2.** ERUS elastography: perirectal enlarged lymph nodes with elastography hard aspect (blue) in a patient with a rectal adenocarcinoma.

MRI is used for all cases of rectal cancer staging by 20-42% of the colorectal cancer centers (11). The accuracy of MRI in detecting lymph node metastases in rectal cancer varies from 68.49%-74.5% to 92%, with

61.76%-85.71% sensitivity and 57.78%-80.88% specificity, similar to the ERUS (13, 20, 21). However, the MRI presents the same problems of differentiating between benign enlarged lymph nodes and malignant lymph nodes, the diagnosis being based on the same criteria as for ERUS (lymph nodes morphology and size) (21).



**Figure 3.** MRI in rectal cancer: multiple suspected lymph nodes in the presacral region (A) and on the left pelvic sidewall region (B).

Pre and post-neoadjuvant treatment evaluation of the lymph nodes represents an important objective and may be realized using ERUS, MRI, or both as complementary methods. Neoadjuvant chemoradiotherapy decreases the tumoral volume and may also determine a downstaging, thus becoming very important in evaluating the treatment response; the lymph nodes post-neoadjuvant treatment downstaging may be as high as 72.2% (22). The pre-neoadjuvant treatment accuracy of the lymph node detection using ERUS was 56% but increases in the post-neoadjuvant setting to 74%, while the MRI accuracy was



the same in pre and post-neoadjuvant settings (74%), as reported by Swartling et al. These authors concluded that the staging accuracy was improved using the combination of the ERUS and MRI (23).

*Intraoperative evaluation of the lymph nodes; extended lymphadenectomy in rectal cancer*

Intraoperative evaluation of the lymph nodes in rectal cancer raises two major points of contention: the attitude over the potentially involved lymph nodes located at a distance from the rectum, and the importance of the lateral lymph nodes dissection.

Regarding the potential involvement of lymph nodes located outside the regular area of drainage of a rectal cancer, the recommendation is to follow the oncologic principle of biopsy and, if possible, removal of all the enlarged lymph nodes in order to reduce the tumoral volume and correctly stage the case.

A special consideration must be accorded to lymph nodes located at the origin of the inferior mesenteric vascular package: ligation and section of the inferior mesenteric artery and vein at their origin is not mandatory, many surgeons performing it below the left colic artery origin without any negative influence on the distant survival or recurrence rate. Obviously, the presence of an enlarged lymph node at this level requires ligation of the inferior mesenteric artery at its origin and removal of the lymph nodes.

Regarding perirectal (intra-mesorectal) lymph nodes, these may be palpated in some cases but intraoperative biopsy is not recommended, requiring sectioning of the mesorectal fascia which may compromise the oncologic results. Quirke et al. have demonstrated that the plane of surgery achieved during rectal resection for cancer has an important influence on the local recurrence rate and distant survival: a 3-year 4% local recurrence rate if the mesorectal plane was achieved, compared to 13% if the muscularis propria plane was entered during surgery, respectively a 79% 3-year disease-free survival rate, if the mesorectal plane was achieved, compared to 70%-75% if the mesorectal plane was compromised during surgery (24).

Probably the most debatable point relates to the extended lateral (pelvic) lymph node dissection. Western surgeons do not perform and do not routinely recommend lateral lymph node dissection in rectal cancer, considering metastases in these lymph nodes as systemic spread of the disease; consequently, they are treated with chemoradiotherapy. Moreover, the MERCURY study group has found through MRI an incidence of 11.7% suspicious lateral lymph nodes, but the 5-year disease free survival was influenced only in

the cases receiving primary surgery (42% 5-year DFS) and not in the group receiving neoadjuvant treatment, which supports the above opinion (25).

Extended lateral lymph node dissection is more common among Eastern surgeons, especially in Japan. The incidence of lateral lymph node metastases varies from 10% to 25% of the cases (26-28) (11% in the study of Dong et al., 14.6% in Wu et al., and 17% in the series of reports by Ueno et al.) (26, 27, 29), but the presence of micrometastases was demonstrated in another 4% of the cases where the positivity of the lymph node was not suspected after initial histologic evaluation (30).

The risk of lateral lymph node involvement increases in low rectal cancers (below peritoneal reflection) with the T stage, circumferential rectal wall involvement, tumor size >5 cm, advanced tumor infiltration and poor differentiation (26, 27), and also with the presence of the positive mesorectal lymph nodes (28), but this is not mandatory since Ueno et al. have found that 24% of the cases (10 out of 41 cases) with invasion in the lateral pelvic lymph nodes had no invasion in the mesorectal lymph nodes (29).

Extended lymph nodes resection, including the origin of the inferior mesenteric artery and pelvic sidewall dissection, has been associated with an improved 5-year survival for all stages (overall 68% 5-year survival rate for extended lymphadenectomy vs 42.9% for conventional resection) as reported in Dong et al. (26). In a retrospective study, Shirouzu et al. found that TME associated with lateral lymph node dissection produced better results than conventional surgery, but only in Dukes C stage: 13.3%-16.7% local recurrence rate vs 25% for conventional surgery (31). Wu et al. have also demonstrated that the presence of lateral lymph node metastasis is associated with a significantly increased risk of local recurrence (64.3%) compared with patients without lateral lymph node metastases (11%), and a significantly lower median survival rate ( $38 \pm 6.7$  months vs  $80.9 \pm 2.1$  months) (27). Ueno et al. have also found a lower 5-year survival rate in cases with lateral lymph node involvement, only 32%-42%, and an increased risk of local recurrence (56.8%), in cases without distant metastases (28, 29).

The main selection criteria for lateral pelvic dissection in rectal cancer are: advanced rectal cancers (T3 and resectable T4 and some advanced T2 cancers, stage III on the TME specimen), located below the peritoneal reflection, on a suitable patient, without distant or peritoneal metastases (26, 32). Wu et al. recommend lateral lymphadenectomy for tumors larger than 5 cm in diameter (27, 32), although Ueno et al. found no significant correlation between tumor diameter

and lateral lymph nodes invasion (29). Ueno et al. also found that the increased number of invaded lymph nodes is associated with an increased risk of lateral lymph node metastases (2/3 of the cases with lateral lymph node involvement had 4 or more positive lymph nodes), and a lower long-distance survival (4% for 4 or more positive lymph nodes compared with 75% for less than 3 involved lymph nodes) (28, 29).

In spite of the apparently better results of the extended lymph node dissection, the higher morbidity, especially in terms of genitourinary dysfunction, requires supplementary criteria for case-selection for lateral lymph nodes dissection.

However, with the lateral lymph node dissection and autonomic nerve preservation, better results were obtained in terms of perioperative results (31), but results appear to be better in terms of urinary function and not so good in terms of genital impairment (33).

The size of the pelvic lymph nodes appears to be an important criterion; on histopathologic analysis on a cut-off of 8.4 mm for the long axis and 5.4 mm for the short axis, Ishida et al. obtained an accuracy of 71.9% (for the long axis) and 72.8% (for the short axis, respectively) in predicting the risk of lateral lymph nodes metastases (34). However, a more recent study demonstrated a lower positive predictive value of the lymph node size for lateral lymph nodes compared to perirectal (mesorectal) lymph nodes (35).

Using the same criteria, Matsuoka et al. consider that an ovoid shape with transverse axis larger than 5 mm of the lymph nodes identified on MRI represents an optimal criterion for lateral dissection in rectal cancer (36). Ueno et al. have also found that in cases with lateral lymph node invasion, the diameter of the lymph nodes was statistically larger than the diameter of the non-invaded lateral lymph nodes ( $8.5 \pm 4.1$  vs  $6.0 \pm 2.8$  mm); the incidence of lateral lymph nodes invasion increased progressively with the size of the lymph nodes from 3.6% in cases with lymph nodes  $< 5$  mm, up to 34% in cases with lymph nodes larger than 10 mm (29). Quadros et al. have used intraoperatively a radiotracer and a blue dye stain which allowed them to find with 100% accuracy and sensitivity in 37.1% of the cases metastatic lymph nodes in the retroperitoneal and lateral pelvic area, with an upstaging rate of 11.1% (out of which 5.5% were due to micrometastases identification) (32).

In conclusion, the debate over the necessity of lateral pelvic lymph node dissection remains open, even if the meta-analysis performed by Cheng et al. found no significant difference in terms of 5-year survival and recurrence rate, but the postoperative morbidity was higher in cases with lateral dissection performed (37).

Establishing clear preoperative criteria for indication of the lateral lymph nodes dissection remains, also, an open discussion.

*Pathologic evaluation: sentinel lymph node mapping and micrometastases significance in rectal cancer*

It is now well recognized that the number of the pathologically examined lymph nodes has a great influence on colorectal cancer staging, and ultimately on distant survival of the patients (38-40). Starting with the sixth edition of the AJCC staging system it was established that a minimum of 12 lymph nodes must be histologically evaluated in order to ensure an adequate N staging, a recommendation that was maintained in the subsequent seventh edition and in the current guidelines for rectal cancer (39, 41, 42). At this point, the histological examination of fewer than 12 lymph nodes is considered a risk for residual disease and incorrect downstaging and an adjuvant chemotherapy protocol must be employed (38-41). In spite of the recommendations there are many situations in which the minimum number of 12 lymph nodes is not reached, even in the most developed care systems (38, 43, 44, 45), negatively influencing the quality of the staging. Many factors influence the number of the lymph nodes examined on a resection specimen for rectal cancer (41, 43, 46), out of which the neoadjuvant therapy appears to be a specific one (47). There are many modalities trying to improve the staging, including the injection of a blue dye in the inferior mesenteric artery (48) in order to identify more stained lymph nodes; NCCN guidelines for rectal cancer recommend, in case of fewer than 12 lymph nodes identified, for the pathologist to review the specimen in an attempt to identify more lymph nodes (41). Probably the most debatable method trying to improve the pN staging in rectal cancer remains the sentinel lymph node mapping; however, current guidelines recommend caution in interpretation of the results (41).

Several methods have been used for identification of the SLN in rectal cancer: in vivo or ex vivo techniques, different staining dyes or radiotracers, even different techniques of pathologic evaluation (seriate sections, usual hematoxylin-eosine staining method, immunohistochemistry or polymerase-chain reaction) (49-55), all leading to a lack of uniformity and making finding a common and reproducible path difficult.

The detection rate of the SLN varies from 61.9% to 97.8%-100%, the sensitivity 50%-58.3% to 80%-93.7%, with a false negative rate of 3.84%-10.7% to 18.18%-20%, and an upstaging rate varying from 4.76%-12.5% to 29%-37.5%. The results were better when the study included the colon and the rectum cases together (49-55).

As a consequence, the different detection rate, sensitivity, and specificity of these methods represent other reasons for which SLN mapping is not a method sufficiently good to be recommended as a guideline, even though most studies have demonstrated some degree of upstaging. The main advantage, present in most of these studies, is represented by the identification of a higher number of lymph nodes submitted to pathologic evaluation than conventional, non-staining methods (49-55). Making the decision even more difficult, the significance of the micrometastases and isolated tumor cells identified on the examined lymph nodes only by IHC or RT-PCR is still up for debate.

The incidence of micrometastases varies, depending on the examination technique, from 25.5-30% to 54-60% if IHC or RT-PCR technique, respectively, is used for detection (56-58).

Wang et al., have found a significant drop in the 5-year survival rate in patients diagnosed with micrometastases (lymph node metastases smaller than 2 mm, but larger than 0.2 mm) (50%-50.3% vs 92.3%), and the decrease of the survival rate was higher for micrometastases identified only by IHC; the same trend was noticed for the 5-year disease-free survival rate (47.5%-50% in the presence of micrometastases vs 92.4% if micrometastases were not present) (56). On the other hand, Liefers et al., and Koyanagi et al., have found a large decrease in the observed 5-year survival rate from 75% in cases without micrometastases to 36% in cases with RT-PCR detected micrometastases, respectively in the mean disease-free survival rate (61 vs 37 month) (57, 58). On the other hand, Oh et al., have found no significant influence of the micrometastases or isolated tumor cells on disease-free survival rate and prognosis (59).

As a consequence, the importance of the micrometastases, IHC or RT-PCR detected, remains controversial. On the other hand, the 7th edition of the AJCC staging system included as prognostic factor, at least for the T1-T2 tumors, the peritumoral (mesorectal) satellite nodules (tumor deposits), which were included as N1c stage if they respect the contour and form of a lymph node (42, 60). Tumor deposits were found in 31.9-36.4% of the studied cases and led to an important stage migration between the AJCC staging systems since their introduction (60), with 40.2-44.2% of the cases becoming stage III with the TNM 7th edition. Thus, the role and especially the definition according to size, form and contour of these tumor deposits remain in debate, in spite of the proven negative prognostic value (60-62).

## Conclusions

Despite important progress made in the evaluation and prognostic interpretation of lymph nodes in rectal cancer, many controversial and unresolved aspects remain, requiring future clarification. However, accurate interpretation requires better standardization than is now offered by current staging systems, as demonstrated by the present studies.

## Acknowledgment

All authors contributed equally to the manuscript.

## References

1. Siegel R, Miller KD, Jemal A. Cancer Statistics, 2015. *CA Cancer J Clin.* 2015; 65(1): 5–29. PMID: 25559415, DOI: 10.3322/caac.21254
2. Torre L, Bray F, Siegel R, Ferlay J, Lortet-Tieulent J, Jemal A. Global cancer statistics, 2012. *CA Cancer J Clin.* 2015; 65(2): 87-108. PMID: 25651787, DOI: 10.3322/caac.21262
3. Ferlay J, Soerjomataram I, Ervik M, Dikshit R, Eser S, Mathers C, Rebelo M, Parkin DM, Forman D, Bray F. Cancer incidence and mortality worldwide: sources, methods and major patterns in GLOBOCAN 2012. *Int J Cancer.* 2015; 136(5): 359-86. PMID: 25220842, DOI: 10.1002/ijc.29210
4. Siegel R, DeSantis C, Jemal A. Colorectal Cancer Statistics, 2014. *CA Cancer J Clin.* 2014; 64(2): 104–17. PMID: 24639052, DOI: 10.3322/caac.21220
5. Takano S, Kato J, Yamamoto H, Shiode J, Nasu J, Kawamoto H, Okada H, Shiratori Y. Identification of risk factors for lymph node metastasis of colorectal cancer. *Hepatogastroenterology.* 2007; 54(75): 746-50. PMID: 17591053
6. Gunderson L, Sargent D, Tepper JE, Wolmark N, O'Connell MJ, Begovic M, Allmer C, Colangelo L, Smalley SR, Haller DG, Martenson JA, Mayer RJ, Rich TA, Ajani JA, MacDonald JS, Willett CG, Goldberg RM. Impact of T and N stage and treatment on survival and relapse in adjuvant rectal cancer: a pooled analysis. *J Clin Oncol.* 2004; 22(10): 1785-96. PMID: 15067027, DOI: 10.1200/JCO.2004.08.173
7. Gunderson L, Jessup JM, Sargent D, Greene F, Stewart A. Revised tumor and node categorization for rectal cancer based on surveillance, epidemiology, and end results and rectal pooled analysis outcomes. *J Clin Oncol.* 2010; 28(2): 256-63. PMID: 19949015, DOI: 10.1200/JCO.2009.23.9194



8. Engelmann BD, Loft A, Kjær A, Nielsen HJ, Berthelsen AK, Binderup T, Brinch K, Brünner N, Gerds TA, Høyer-Hansen G, Kristensen MH, Kurt EY, Latocha JE, Lindblom G, Sloth C, Højgaard L. Positron emission tomography/ computed tomography for optimized colon cancer staging and follow up. *Scand J Gastroenterol.* 2014; 49(2): 191–201. PMID: 24286594, DOI: 10.3109/00365521.2013.863967
9. Huh JW, Jeong YY, Kim HR, Kim YJ. Prognostic value of preoperative radiological staging assessed by computed tomography in patients with nonmetastatic colon cancer. *Ann Oncol.* 2012; 23(5):1198-206. PMID: 21948813, DOI: 10.1093/annonc/mdr404
10. Foxtrot Collaborative Group. Feasibility of preoperative chemotherapy for locally advanced, operable colon cancer: the pilot phase of a randomised controlled trial. *Lancet Oncol.* 2012; 13(11): 1152–60. PMID: 23017669, DOI: 10.1016/S1470-2045(12)70348-0
11. Augestad K, Lindsetmo RO, Stulberg J, Reynolds H, Senagore A, Champagne B, Heriot A, Leblanc F, Delaney C, International Rectal Cancer Study Group (IRCSG). International preoperative rectal cancer management: staging, neoadjuvant treatment, and impact of multidisciplinary teams. *World J Surg.* 2010; 34(11): 2689–700. PMID: 20703471, DOI: 10.1007/s00268-010-0738-3
12. Fang WL, Chang SC, Lin JK, Wang HS, Yang SH, Jiang JK, Chen WC, Lin TC. Metastatic potential in T1 and T2 colorectal cancer. *Hepatogastroenterology.* 2005; 52(66): 1688-91. PMID: 16334758
13. Halefoglu AM, Yildirim S, Avlanmis O, Sakiz D, Baykan A. Endorectal ultrasonography versus phased-array magnetic resonance imaging for preoperative staging of rectal cancer. *World J Gastroenterol.* 2008; 14(22): 3504-10. PMID: 18567078
14. Hsieh PS, Changchien CR, Chen JS, Tang R, Chiang JM, Yeh CY, Wang JY. Comparing Results of Preoperative Staging of Rectal Tumor Using Endorectal Ultrasonography and Histopathology. *Chang Gung Med J.* 2003; 26(7): 474-8. PMID: 14515969
15. Maleki Z, Erozan Y, Geddes S, Li QK. Endorectal ultrasound-guided fine-needle aspiration: a useful diagnostic tool for perirectal and intraluminal lesions. *Acta Cytol.* 2013; 57(1): 9–18. PMID: 23221104, DOI: 10.1159/000342919
16. Kolev N, Tonev A, Ignatov V, Zlatarov A, Bojkov V, Kirilova T, Encheva E, Ivanov K. The role of 3-D endorectal ultrasound in rectal cancer: our experience. *Int Surg.* 2014; 99(2): 106–11. PMID: 24670018, DOI: 10.9738/INTSURG-D-13-00227.1
17. Waage JER, Leh S, Røsler C, Pfeffer F, Bach SP, Havre RF, Haldorsen IS, Odegaard S, Baatrup G. Endorectal ultrasonography, strain elastography and MRI differentiation of rectal adenomas and adenocarcinomas. *Colorectal Dis.* 2015; 17(2): 124–31. PMID: 25407010, DOI: 10.1111/codi.12845
18. Xu W, Shi J, Zeng X, Li X, Xie WF, Guo J, Lin Y. EUS elastography for the differentiation of benign and malignant lymph nodes: a meta-analysis. *Gastrointest Endosc.* 2011; 74(5): 1001-9. PMID: 22032315, DOI: 10.1016/j.gie.2011.07.026
19. Okasha HH, Mansour M, Attia KA, Khattab HM, Sakr AY, Naguib M, Aref W, Al-Naggar AAM, Ezzat R. Role of high resolution ultrasound/endosonography and elastography in predicting lymph node malignancy. *Endosc Ultrasound.* 2014; 3(1): 58-62. PMID: 24949412, DOI: 10.4103/2303-9027.121252
20. Iannicelli E, Di Renzo S, Ferri M, Pillozzi E, Di Girolamo M, Saporì A, Ziparo V, David V. Accuracy of high-resolution MRI with lumen distention in rectal cancer staging and circumferential margin involvement prediction. *Korean J Radiol.* 2014; 15(1): 37-44. PMID: 24497790, DOI: 10.3348/kjr.2014.15.1.37
21. Giusti S, Buccianti P, Castagna M, Fruzzetti E, Fattori S, Castelluccio E, Caramella D, Bartolozzi C. Preoperative rectal cancer staging with phased-array MR. *Radiat Oncol.* 2012; 7: 29. PMID: 22390136, DOI: 10.1186/1748-717X-7-29
22. Yang SH, Lee RC, Chen CC, Jiang JK, Lin JK, Li AFY, Liang WY, Wang LW. Is decrease of tumor volume correlated with stage change after preoperative concurrent chemoradiotherapy? *Hepatogastroenterology.* 2005; 52(63): 765-9. PMID: 15966201
23. Bărcă M, Ilie M, Baconi DL, Ciobanu AM, Bălălaşu D, Burcea GT. Spectrofluorimetric methotrexate assay in human plasma. *Farmacia.* 2010; 58: 95-101.
24. Quirke P, Steele R, Monson J, Grieve R, Khanna S, Couture J, O’Callaghan C, Myint AS, Bessell E, Thompson LC, Parmar M, Stephens RJ, Sebag-Montefiore D, on behalf of the MRC CR07/NCIC-CTG CO16 trial investigators and the NCRI colorectal cancer study group. Effect of the plane of surgery achieved on local recurrence in patients with operable rectal cancer: a prospective study using

- data from the MRC CR07 and NCIC-CTG CO16 randomised clinical trial. *Lancet*. 2009; 373(9666): 821–8. PMID: 19269520, DOI: 10.1016/S0140-6736(09)60485-2
25. MERCURY Study Group, Shihab OC, Taylor F, Bees N, Blake H, Jeyadevan N, Bleehen R, Blomqvist L, Creagh M, George C, Guthrie A, Massouh H, Peppercorn D, Moran BJ, Heald RJ, Quirke P, Tekkis P, Brown G. Relevance of magnetic resonance imaging detected pelvic sidewall lymph node involvement in rectal cancer. *Br J Surg*. 2011; 98(12): 1798-804. PMID: 21928408, DOI: 10.1002/bjs.7662
  26. Dong XS, Xu HT, Yu ZW, Liu M, Cui BB, Zhao P, Wang XS. Effect of extended radical resection for rectal cancer. *World J Gastroenterol*. 2003; 9(5): 970-3. PMID: 12717840
  27. Wu ZY, Wan J, Li JH, Zhao G, Yao Y, Du JL, Liu QF, Peng L, Wang ZD, Huang ZM, Lin HH. Prognostic value of lateral lymph node metastasis for advanced low rectal cancer. *World J Gastroenterol*. 2007; 13(45): 6048-52. PMID: 18023098
  28. Ueno H, Mochizuki H, Hashiguchi Y, Hase K. Prognostic determinants of patients with lateral nodal involvement by rectal cancer. *Ann Surg*. 2001; 234(2): 190-7. PMID: 11505064
  29. Ueno H, Mochizuki H, Hashiguchi Y, Ishiguro M, Miyoshi M, Kajiwara Y, Sato T, Shimazaki H, Hase K. Potential prognostic benefit of lateral pelvic node dissection for rectal cancer located below the peritoneal reflection. *Ann Surg*. 2007; 245(1): 80-7. PMID: 17197969, DOI: 10.1097/01.sla.0000225359.72553.8c
  30. Ueno H, Yamauchi C, Hase K, Ichikura T, Mochizuki H. Clinicopathologic study of intrapelvic cancer spread to the iliac area in lower rectal adenocarcinoma by serial sectioning. *Br J Surg*. 1999; 86(12): 1532–7. PMID: 10594501, DOI: 10.1046/j.1365-2168.1999.01271.x
  31. Shirouzu K, Ogata Y, Araki Y, Sasatomi T, Nozoe Y, Nakagawa M, Matono K. Total mesorectal excision, lateral lymphadenectomy and autonomic nerve preservation for lower rectal cancer: significance in the long-term follow-up study. *Kurume Med J*. 2001; 48(4): 307-19. PMID: 11830931
  32. Quadros CA, Lopes A, Araújo I. Retroperitoneal and lateral pelvic lymphadenectomy mapped by lymphoscintigraphy for rectal adenocarcinoma staging. *Jpn J Clin Oncol*. 2010; 40(8): 746–53. PMID: 20457722, DOI: 10.1093/jjco/hyq060
  33. Kyo K, Sameshima S, Takahashi M, Furugori T, Sawada T. Impact of autonomic nerve preservation and lateral node dissection on male urogenital function after total mesorectal excision for lower rectal cancer. *World J Surg*. 2006; 30(6): 1014-9. PMID: 16736330, DOI: 10.1007/s00268-005-0050-9
  34. Ishida H, Hatano S, Ishiguro T, Kumamoto K, Ishibashi K, Haga N. Prediction of lateral lymph node metastasis in lower rectal cancer: analysis of paraffin-embedded sections. *Jpn J Clin Oncol*. 2012; 42(6): 485–90. PMID: 22457325, DOI: 10.1093/jjco/hys041
  35. Hatano S, Ishida H, Ishiguro T, Kumamoto K, Ishibashi K, Mochiki E, Tamaru J. Prediction of metastasis to mesorectal, internal iliac and obturator lymph nodes according to size criteria in patients with locally advanced lower rectal cancer. *Jpn J Clin Oncol*. 2015; 45(1): 35-42. PMID: 25324477, DOI: 10.1093/jjco/hyu162
  36. Matsuoka H, Nakamura A, Masaki T, Sugiyama M, Nitatori T, Ohkura Y, Sakamoto A, Atomi Y. Optimal diagnostic criteria for lateral pelvic lymph node metastasis in rectal carcinoma. *Anticancer Res*. 2007; 27(5B): 3529-33. PMID: 17972513
  37. Cheng H, Deng Z, Wang ZJ, Zhang W, Su JT. Lateral lymph node dissection with radical surgery versus single radical surgery for rectal cancer: a meta-analysis. *Asian Pac J Cancer Prev*. 2011; 12(10): 2517-21. PMID: 22320950
  38. Lemmens VE, van Lijnschoten I, Janssen-Heijnen ML, Rutten HJ, Verheij CD, Coebergh JW. Pathology practice patterns affect lymph node evaluation and outcome of colon cancer: a population-based study. *Ann Oncol*. 2006; 17(12): 1803-9. PMID: 16971667, DOI: 10.1093/annonc/mdl312
  39. Nelson H, Petrelli N, Carlin A, Couture J, Fleshman J, Guillem J, Miedema B, Ota D, Sargent D. National Cancer Institute Expert Panel. Guidelines 2000 for colon and rectal surgery. *J Nat Cancer Instit*. 2001; 93(8): 583-96. PMID: 11309435
  40. Yoshimatsu K, Ishibashi K, Umehara A, Yokomizo H, Yoshida K, Fujimoto T, Watanabe K, Ogawa K. How many lymph nodes should be examined in Dukes' B colorectal cancer? Determination on the basis of cumulative survival rates. *Hepatogastroenterology*. 2005; 52(66): 1703-6. PMID: 16334761
  41. Engstrom PF, Arnoletti JP, Benson AB 3rd, Chen YJ, Choti MA, Cooper HS, Covey A, Dilawari RA, Early DS, Enzinger PC, Fakih MG, Fleshman J Jr,

- Fuchs C, Grem JL, Kiel K, Knol JA, Leong LA, Lin E, Mulcahy MF, Rao S, Ryan DP, Saltz L, Shibata D, Skibber JM, Sofocleous C, Thomas J, Venook AP, Willett C; NCCN Clinical Practice Guidelines in Oncology: rectal cancer. *J Natl Compr Canc Netw*. 2009; 7(8): 838-81. PMID: 19755047
42. Resch A, Langner C. Lymph node staging in colorectal cancer: old controversies and recent advances. *World J Gastroenterol*. 2013; 19(46): 8515-26. PMID: 24379568, DOI: 10.3748/wjg.v19.i46.8515
43. Elferink MA, Siesling S, Visser O, Rutten HJ, van Krieken JH, Tollenaar RA, Lemmens VE. Large variation between hospitals and pathology laboratories in lymph node evaluation in colon cancer and its impact on survival, a nationwide population-based study in The Netherlands. *Ann Oncol*. 2011; 22(1): 110-7. PMID: 20595447, DOI: 10.1093/annonc/mdq312
44. Wong J, Johnson S, Hemmings D, Hsu A, Imai T, Tominaga G. Assessing the quality of colorectal cancer staging: documenting the process in improving the staging of node-negative colorectal cancer. *Arch Surg*. 2005; 140(9): 881-7. PMID: 16172297, DOI: 10.1001/archsurg.140.9.881
45. Baxter N, Virnig D, Rothenberger D, Morris A, Jessurun J, Virnig B. Lymph node evaluation in colorectal cancer patients: a population-based study. *J Natl Cancer Instit*. 2005; 97(3): 219-25. PMID: 15687365, DOI: 10.1093/jnci/dji020
46. Horzic M, Kopljarić M. Minimal number of lymph nodes that need to be examined for adequate staging of colorectal cancer – factors influencing lymph node harvest. *Hepatogastroenterology*. 2005; 52(61): 86-9. PMID: 15783001
47. Wijesuriya R, Deen K, Hewavisenthi J, Balawardana J, Perera M. Neoadjuvant therapy for rectal cancer down-stages the tumor but reduces lymph node harvest significantly. *Surg Today*. 2005; 35(6): 442-5. PMID: 15912290, DOI: 10.1007/s00595-004-2956-5
48. Märkl B, Kerwel T, Wagner T, Anthuber M, Arnholdt H. Methylene blue injection into the rectal artery as a simple method to improve lymph node harvest in rectal cancer. *Modern Pathol*. 2007; 20(7): 797-801. PMID: 17483817, DOI: 10.1038/modpathol.3800824
49. Baton O, Lasser P, Sabourin JC, Boige V, Duvillard P, Elias D, Malka D, Ducreux M, Pocard M. Ex vivo sentinel lymph node study for rectal adenocarcinoma: preliminary study. *World J Surg*. 2005; 29(9): 1166-70. PMID: 16086211, DOI: 10.1007/s00268-005-7867-0
50. Vilcea ID, Vasile I, Mirea CS, Meșină C, Enache SD, Țenovici M, Mogoantă S, Ghiță C. Sentinel lymph node study in colorectal cancer using serial sectioning and Hematoxylin–Eosin staining: importance and limitations. *Rom J Morphol Embryol*. 2011; 52(1 Suppl): 379-83. PMID: 21424078
51. Wong J, Steineman S, Calderia C, Bowles J, Namiki T. Ex vivo sentinel node mapping in carcinoma of the colon and rectum. *Ann Surg*. 2001; 233(4): 515-21. PMID: 11303133
52. Gurzu S, Jung I, Bara T, Bara T Jr, Szentirmay Z, Azamfirei L, Toth E, Turcu M, Egyed-Zsigmond E. Practical value of the complex analysis of sentinel lymph nodes in colorectal carcinomas. *Rom J Morphol Embryol*. 2011; 52(2): 593-8. PMID: 21655648
53. Yagci G, Unlu A, Kurt B, Can MF, Kaymakcioglu N, Cetiner S, Tufan T, Sen D. Detection of micrometastases and skip metastases with ex vivo sentinel node mapping in carcinoma of the colon and rectum. *Int J Colorectal Dis*. 2007; 22(2): 167-73. PMID: 16721490, DOI: 10.1007/s00384-006-0132-7
54. Constantin VD, Socea B, Popa F, Carâp AC, Popescu G, Vlădescu T, Ceașu Z, Berteșteanu ȘV, Ceașu MC. A histopathological and immunohistochemical approach of surgical emergencies of GIST. An interdisciplinary study. *Rom J Morphol Embryol*. 2014; 55(2 Suppl): 619-27. PMID: 25178335
55. Cai HK, He HF, Tian W, Zhou MQ, Hu Y, Deng YC. Colorectal cancer lymph node staining by activated carbon nanoparticles suspension in vivo or methylene blue in vitro. *World J Gastroenterol*. 2012; 18(42): 6148-54. PMID: 23155345, DOI: 10.3748/wjg.v18.i42.6148
56. Wang FL, Shen F, Wan DS, Lu ZH, Li LR, Chen G, Wu XJ, Ding PR, Kong LH, Pan ZZ. Ex vivo localization and immunohistochemical detection of sentinel lymph node micrometastasis in patients with colorectal cancer can upgrade tumor staging. *Diagn Pathol*. 2012; 7: 71. PMID: 22726450, DOI: 10.1186/1746-1596-7-71
57. Koyanagi K, Bilchik A, Saha S, Turner R, Wiese D, McCarter M, Shen P, Deacon L, Elashoff D, Hoon D. Prognostic relevance of occult nodal micrometastases and circulating tumor cells in colorectal cancer in a prospective multicenter trial. *Clin Cancer Res*. 2008; 14(22): 7391-6. PMID: 19010855, DOI: 10.1158/1078-0432.CCR-08-0290

58. Liefers GJ, Cleton-Jansen AM, van de Velde C, Hermans J, van Krieken J, Cornelisse C, Tollenaar R. Micrometastases and survival in stage II colorectal cancer. *N Engl J Med.* 1998; 339(4): 223-8. PMID: 9673300, DOI: 10.1056/NEJM199807233390403
59. Oh TY, Moon SM, Shin US, Lee HR, Park SH. Impact on prognosis of lymph node micrometastasis and isolated tumor cells in stage II colorectal cancer. *J Korean Soc Coloproctol.* 2011; 27(2): 71-7. PMID: 21602965, DOI: 10.3393/jksc.2011.27.2.71
60. Nagtegaal I, Tot T, Jayne D, McShane P, Nihlberg A, Marshall H, Pahlman L, Brown J, Guillou P, Quirke P. Lymph nodes, tumor deposits, and TNM: are we getting better? *J Clin Oncol.* 2011; 29(18): 2487-92. PMID: 21555695, DOI: 10.1200/JCO.2011.34.6429
61. Sfeclan MC, Vilcea ID, Barišić G, Mogoantă SŞ, Moraru E, Ciorbăgiu MC, Vasile I, Vere CC, Vilcea AM, Mirea CS. The sentinel lymph node (SLN) significance in colorectal cancer: methods and results. General report. *Rom J Morphol Embryol.* 2015; 56(3): 943-7. PMID: 26662126
62. Vilcea ID, Vasile I, Tomescu P, Pasalega M, Meşină C, Calotă F, Mihaela C, Georgescu E, Ionescu M, Mirea C, Traşcă E, Tenea T, Mogoanta S. Loco-regional advanced colorectal cancer: diagnostic and therapeutic features. *Chirurgia (Bucur).* 2008; 103(2): 189-94. PMID: 18457097