



MESTRADO

MEDICINA

Intraoperative evoked potentials: a review of clinical impact and limitations

Ana Sofia Marafona

M

2018



Intraoperative evoked potentials: a review of clinical impact and limitations.

Estudante candidata ao grau de Mestre em Medicina:

Ana Sofia Matias Correia de Ferreira Marafona

Endereço Eletrónico: smarafona@hotmail.com

Mestrado Integrado em Medicina

Instituto de Ciência Biomédicas Abel Salazar, Universidade do Porto

Orientador:

Humberto José da Silva Machado

Universidade e Unidade Orgânica: Universidade do Porto

Unidade do SNS e Serviço: Centro Hospitalar do Porto, Serviço de Anestesiologia

Grau Académico ou título: Doutor

Categoria Académica: Professor Associado Convidado

Categoria das carreiras médicas: Assistente Graduado Sénior

Categoria da carreira de investigação: Orientador

Maio, 2018

Porto, 2 de maio de 2018.

A handwritten signature in black ink, reading "Ana Sofia Matias Correia de Ferreira Marafona". The signature is written in a cursive style and is contained within a light gray rectangular background.

(Candidata ao grau de Mestre Ana Sofia Matias Correia de Ferreira Marafona)

A handwritten signature in black ink, reading "Humberto Machado". The signature is written in a cursive style and is positioned above a horizontal line.

(Orientador Prof. Dr. Humberto Machado)

Dedicatória

Aos meus pais e à minha irmã pelo apoio incondicional ao longo dos 6 anos de curso e pelo valor que sempre atribuíram ao meu esforço e à minha dedicação.

À minha família pelos discursos motivadores, pela crença no meu sucesso e apoio inestimável.

Ao Nuno pela compreensão, imensa paciência e companheirismo durante os períodos de estudo e, mais importante, pela sua perspetiva realista perante os obstáculos aparentemente insuperáveis.

Aos meus colegas, que partilharam comigo esta longa e incrível jornada, pela valorização do meu empenho, motivação constante, auxílio e amizade.

Agradecimentos

Em primeiro lugar, agradeço ao meu orientador, Professor Doutor Humberto José da Silva Machado, a quem devo a inspiração inicial para a presente dissertação, para além disso, tenho de agradecer pela disponibilidade, motivação, apoio constante e paciência para me orientar neste trabalho. Não obstante também foi ao longo do curso uma referência como médico e professor, pelo carisma, humanismo e entusiasmo característico das aulas lecionadas. Devo também reconhecer o papel preponderante na motivação para a publicação da presente revisão bibliográfica.

Em segundo lugar, não posso deixar de agradecer à minha colega Joana Patrícia Meireles pela disponibilidade e correção linguística da redação enaltecendo, deste modo, o seu conteúdo.

Resumo

Na atualidade, os potenciais evocados intraoperatórios constituem uma recomendação em diversos procedimentos não obstante a carência de protocolos de montagem e consensos relativamente a critérios de alarme. Os estudos perante esta temática foram fomentados pelas limitações inerentes ao teste de Stagnara, que se tem vindo a demonstrar pouco fiável tendo em consideração o stress despoletado e o aumento do tempo cirúrgico associado.

A presente revisão literária tem como objetivo reunir os achados encontrados na bibliografia publicada na última década, na língua inglesa, relativamente aos potenciais evocados intraoperatórios, os avanços tecnológicos e fundamentar o impacto clínico nos diversos contextos de entre os quais se incluem as recomendações formais.

A pesquisa bibliográfica revelou que a modalidade combinada deste tipo de monitorização intraoperatória tem uma sensibilidade e especificidade de 100 e 98%, respetivamente, para a deteção de défice sensoriomotor. Adicionalmente, estudos comprovam que o córtex sensorial e motor é identificado em 91 e 99% pelas modalidades a estes dirigidos. Posto isto, a combinação de modalidades de medição de potenciais evocados intraoperatórios é essencial uma vez que impedem a morbilidade potencialmente evitável. Em cerca de 44.4% dos casos, em alguns grupos, as alterações são ainda reversíveis. Apesar da necessidade de identificar fatores preditivos para lesão neurológica, a sua reversibilidade e curta duração sugerem um prognóstico favorável, com base na avaliação da apresentação e de alta. Em oposição, a irreversibilidade da deterioração do sinal relaciona-se com a diminuição da escala de prognóstico Glasgow a longo prazo.

Por fim, a monitorização com potenciais evocados demonstrou, repetidamente, alta sensibilidade, especificidade e valor preditivo negativo. A referida modalidade de monitorização é um instrumento adjuvante e fundamentado por estudos de avaliação de risco-benefício que recomendam o seu uso em cirurgias com risco elevado de lesão neurológica. Estes achados são corroborados pela integridade das vias neurológicas, sendo os procedimentos caracterizados como mais precisos, o impacto clínico tende a ser positivo e também mais previsível. Com a presente pesquisa torna-se evidente a necessidade de elaborar protocolos por forma a orientar os procedimentos nos diferentes centros, estabelecer critérios de alarme, sendo ainda necessária uma equipa de especialistas vocacionados e com boas competências comunicacionais para que haja uma deteção precoce e objetiva das alterações dos sinais e exclusão de artefactos.

Abstract

Background: Nowadays, intraoperative evoked potentials are recommended in a variety of procedures but there is still a lack of standard protocols and consensus about warning criteria. Moreover, studies are now being made to fundament its risk – beneficial ratio through recordings' predictive value for short and long term outcomes. Furthermore, wake up test limitations encouraged intraoperative evoked potentials research, a reliable monitoring technology.

Objectives: This literature revision aims to acknowledge last decade intraoperative evoked potentials technological advances and fundament its clinical impact in multiple contexts.

Methods: A literature review based on clinical series from 2007 to June 2017.

Results: Combined intraoperative evoked potentials sensitivity and specificity of intraoperative neuromonitoring for sensory motor impairment was 100 and 98%, respectively. Somatosensory evoked potentials and motor evoked potentials responses successfully recognize sensory and motor cortex, 91% and 99%, correspondingly. Upon that, combined monitoring modalities are considered essential since they can limit unnecessary morbidity. In Sahaya et al series, 3.83% of recordings were altered and 44.44% reversible. Despite requiring predictive factors for neurological injury identification, reversibility and decreased duration of altered waveform indicates a favorable outcome, based on presentation and discharge evaluation. In opposition, irreversibility of signal's deterioration is related to a decrease on Glasgow outcome scale at long-term follow up. At last, intraoperative evoked potentials demonstrated high sensitivity, specificity and negative predictive value.

Conclusions: Intraoperative evoked potentials have a role as an adjuvant-monitoring tool. Risk-beneficial studies recommend its use in surgeries with known risk of neurological injury. Furthermore, surgical procedures are more accurate and integrity of neurologic pathways better preserved when real time monitored is used. As a result, outcomes tend to be better and more predictable. Nevertheless, standardized protocols, warning signals criterion and specialized teams with adequate communication are still required in order to accurately detect waveform deterioration and exclude artifacts.

Keywords: Intraoperative evoked potentials; patient outcome assessment; intraoperative monitoring; somatosensory evoked potentials; motor evoked potentials.

Abbreviations

BAEP	Brainstem auditory evoked potentials
BFI	Blood flow insufficiency
CBF	Cerebral flow insufficiency
CSF	Cerebrospinal fluid
EEG	Electroencephalogram
EP	Evoked potentials
IONM	Intraoperative evoked potentials
ICU	Intensive care unit
MAP	Mean arterial pressure
MEP	Motor evoked potentials
PND	Postoperative neurological deficit
SC	Spinal cord
SCI	Spinal cord ischemia
SSEP	Somatosensory evoked potentials
TAAA	Thoracic abdominal aortic aneurysm

Index

Dedicatória	
Agradecimentos	i
Resumo.....	ii
Abstract.....	iii
Abbreviations	iv
Index of figures.....	vi
Index of tables.....	vii
Introduction	1
Objectives	3
Materials and Methods	4
Results	5
Discussion.....	10
Conclusion	17
Appendix	
Appendix A: Key highlights	18
Appendix B: Published review article	22
References.....	34

Index of Figures

Figure 1 – Inclusion/exclusion methodology of manuscripts 39

Index of Tables

Table I – Evidence based recommendations.....	40
Table II – Quality of evidence.....	41
Table III – Strength of recommendation	42

Introduction

Since the 20th century intraoperative evoked potentials have been initially used to improve spine surgery's safety through real time assessment of neural structures at risk. According to Pastorelli et al a cost-effectiveness analysis led to more extended recommendations.¹

Currently, intraoperative neurophysiological monitoring is known to enhance specialist's ability to prevent intraoperative nocive maneuvers, predict and improve both outcomes and decision-making.²⁻⁸ Even more, surgical approach became more aggressive and accurate along with a greater impact in patients' outcome plus quality of care during surgical procedures.⁹

Thus, intraoperative assessment of functional integrity of the brain, brainstem, spinal cord and peripheral nerves becomes helpful once increased risk is recognized.^{10,11} And, thereafter, to identify sensorimotor cortex and recognize structures in order to guide procedures. Furthermore, special caution is needed since previous neurological deficits may represent a false positive result, in addition to the fact that IONM assessment is avoided once limb edema, peripheral neuropathy or anatomical variant are present.^{12,13} Thus, total disappearance of recordings is a strong predictor of early paralysis or paresis either permanent or temporary. Besides, waveform disappearance isn't a sufficient criteria outside SC monitoring, so that, additional criteria is required.¹⁴ Moreover, neuromonitoring can include spontaneous activity recording (e.g. electroencephalogram and spontaneous electromyogram) or evoked response to stimulus, which reassembles SSEP, MEP and BAEP. As a result, a diversity of techniques increases reliability of the recordings and overcome most of the singular limitations along with excellent clinical outcome correlation. Exceptionally, IONM may be rather useless during certain surgical procedures (i.e. pituitary adenoma resection without cavernous sinus invasion).^{2,12,15-18}

Still, one of the aspects brought on by these techniques is the replacement of Stagnara test, which depends on patient's cooperation and is highly variable. However, the wake up test may remain set when SSEP are used isolated due to corticospinal tract injury alone.¹

SSEP recordings are able to detect BFI during intracerebral surgeries, regarding cortical and subcortical function. Furthermore, limb malpositioning, may cause peripheral nerve conduction failure which may resemble BFI; these situations are often concurrent with MEP signal deterioration. Peripheral sensitive evoked potentials may help to identify these problems.^{18,19}

In addition, neuromonitoring requires a multidisciplinary, trained staff with clinical neurophysiologic knowledge in order to exclude artifacts and accurately identify signal drop or disappearance with clinical meaning. Plus, monitoring modality should be chosen by the surgeon and his team to better locate, monitor and protect structures known to be at risk depending on surgical approach.^{7,20,21}

For instance, recordings' changes can result from surgical maneuvers, pharmacological interventions, patient's positioning during the procedure and anatomical variation, always including the physiological component.^{7,21,22}

Moreover, complications related to positioning on the operating table may consist of severe motor deficit, a secondary damage of nervous plexus extreme positioning (i.e. brachial plexopathy). Eventually, it may be avoided once IONM manifests alterations for upper limbs, despite this might be recognized as a tangential benefit.¹

In fact, IONM potentiates procedures' strategic alterations aiming to prevent perpetual neurological deficit, such as degree of distraction adjustment, retractors or grafts correction, reimplanting or unclamping arteries, placing vascular bypass grafts and minimizing the remaining portion of the surgery of others.^{17,23,24}

Furthermore, IONM evaluates cortical and subcortical structures as well as their perfusion level. This may lead to greater sensitivity and specificity when evaluating neural structures at risk during a technically demanding surgical approach.¹

Objectives

This review aims to update IONM clinical utility evolution, mainly, in neuro, vascular and orthopedic surgeries. Furthermore, to understand the impact of this technology in patients' immediate and long term outcome.

Materials and Methods

Search strategy

An online search of PUBMED and GOOGLE SCHOLAR from 2007 to June 2017 was carried out. This subject exploration was restricted to studies published in English language.

Search terms included intraoperative evoked potentials, motor evoked potentials, MEP, intraoperative neuromonitoring, evoked potentials utility, intraoperative evoked potentials indications, limitations of intraoperative neuromonitoring, patients' outcome, neuromonitoring. In addition, the reference lists of all retrieved articles were examined for further relevant articles.

Selection criteria and definitions

Articles eligible for inclusion were manuscripts where some relevant evidence of Intraoperative evoked potentials benefits, usefulness and limitations was encountered, as studies to evaluate possible awareness criterion and clinical relation.

Exclusion criteria included: other language of publication, case reports, and case series including less than 20 patients.

Figure 1 shows inclusion/exclusion methodology of manuscripts.

Results

In 2007, a series of 87 cases of endovascular aortic repair reassured IONM recommendation since it allowed SC ischemia detection and subsequent protective interventions. In fact, benefits outweighed associated risks with a sensitivity of 93% and specificity of 96% for IONM.

In 2010 AHA Aortic Guidelines states that IONM may be considered a strategy to detect SC ischemia. Nevertheless, MEP sensitivity and specificity remain in need of more evidence.²⁵

In 2011 combined SEP and transcranial MEP sensitivity and specificity for sensory motor deficiency was 100 and 98%, respectively.¹ Individually these methods are successful for identifying sensory and motor cortex in 91 and 99%, correspondingly.²

In 2012, a 1500 cases series review of MEP monitoring stated that it is sufficiently safe for clinical use in instructed hands and with proper precautions since some rare adverse events like bite wounds, dangerous output, seizures or arrhythmia were identified.¹⁹

In 2014, IONM was routinely being used during endovascular or microsurgical repair of intracranial aneurysm at main centers with great sensitivity, specificity and negative predictive value. In the Sahaya et al series (N=470) recordings were altered in 3.83% of which 44.44% reversible. Despite requiring predictive factors for postoperative neurological deficit identification, reversibility indicates a favorable outcome. In comparison, signal drop irreversibility (33.33%) was related to deterioration in Glasgow outcome scale at long term follow up. Some studies documented SSEP usefulness in postoperative neurological deficit detection, along with the fact that increasing MAP successfully reversed few false negatives and multiple altered waveforms.^{18,20,26}

Regarding a study from 2010 to 2014, the ability to monitor transcranial MEP and SSEP was 92% and 57% respectively. In this cohort, cases of transcranial MEP irreversible waveform drop from 50 to 80%, with a high risk of a permanent neurological deficit, did not have this anticipated negative ending since all patients recovered in about 1 month after surgical procedures. Also, disregarding any medical intervention, clinical result and walking function may be predicted by transcranial MEP after SC lesion.

In context of IONM during arthrodesis in adolescent idiopathic scoliosis changes occurred about 5.3% in severe conditions and with technological advances, in 2006, a study revealed a rate of 0.5% of which 61% recovered completely.¹⁰

Furthermore, cortical pathways are affected by anesthesia in a greater extent than subcortical and SC recordings, regarding inhibitory effect of general anesthesia on neurotransmission. Meanwhile, the level of influence is variable according to monitoring

method, such as BAEP are less sensitive to its effects and visual EP are the most vulnerable ones. In addition, administering opioids or nitrous oxide with midazolam or propofol, preserves the cortical SSEP while benzodiazepines result in its moderate depression. Effectively, morphine effect on SSEP recordings was greater when in bolus and the subarachnoid administration of meperidine produced 60% decrease in cortical posterior tibial nerve SSEP amplitude and a 10% increase in latency. In this context, since a 2015 randomized controlled trial, dexmedetomidine has consistently proven to be a safe adjuvant to intravenous anesthesia on SSEP, MEP and visual EP recordings, without latencies and amplitudes shifts in therapeutic doses. Upon that, neuromuscular blocking drugs may improve waveform quality by amplifying signal to noise ratio and eliminating electromyography (EMG) artifact.^{7,27}

As stated by Wicks et al, anesthesia effects, manipulation and temporary clipping were possible to track by SSEP during intracranial aneurysms surgery. Moreover, Clark et al (N=277) intervention anterior circulation aneurysms with SSEP monitoring. Hence, an amplitude decrease over 50% reversed after procedure's adjustment demonstrated better neurologic outcomes than a persistent decline.²⁸

In descending and thoracoabdominal aorta aneurysm repair, MEP monitoring (N=1297) revealed normal signal in 69.6% and decreased in 30.4%. Also, normal SSEP were reported despite permanent neurological deficit. In order to regain MEP, a diversity of strategies were attempted, such as increase of distal aortic perfusion or central venous pressure, CSF drainage and re-implantation of intercostal arteries.^{10,22,29}

Furthermore, D-waves produced by motor cortex pyramidal cells (white matter), have little value during descending aortic surgery, because motor deficits may occur due to grey mater insult, without D-wave changes. In addition, white matter has relative resistance to ischemia. An amplitude reduction over 50% has been used as warning criteria in motor cortex monitoring.¹⁴ Thus, an acute spinal cord ischemia disables anterior horn cells causing myogenic MEP loss, while corticospinal tract conduction and D-wave may be unaffected or begin to fail later.³⁰

Thereafter, MEP recordings during aneurysm clipping were related to 8 minutes of gradual signal deterioration after clipping and 12 minutes until signal recovery. As stated by Hayashi et al, MEP monitoring may be more useful in unruptured aneurysm surgery.^{31,32}

Regarding Coselli et al, intercostal re-implantation was performed in 61,3% of the patients, CSF drainage and distal aortic perfusion were also performed in lower percentage, yet, neuromonitoring was not used and overall incidence of spinal cord injury was about 3.8% although it was higher for severe thoracic abdominal aortic aneurism. Altogether these strategies are able to decrease the incidence of SCI, particularly in

severe cases.^{33,34}

Recent studies elucidate that 25% of MEP alterations displayed simultaneous SSEP changes and persistent loss of MEP was associated with paraplegia development even when SSEP recovered. Furthermore, SSEP monitoring facilitates CSF drainage and catheter insertion although there is no evidence that CSF drainage may prevent SCI after open aortic surgery.^{33,35}

In neurovascular surgery, SSEP changes reversibility and decreased duration, based on presentation and discharge evaluation, were associated with a more favorable outcome.^{28,36} There was SSEP signal deterioration in 4% of the patients and its sensitivity was 25%, also, overall positive predictive value was about 30%.³⁶

Currently, some IONM physiological confounding factors are recognized and categorized as follows: body temperature interfering with temporary axonal conduction alterations, hypocapnia which causes latency shortening and increase cortical amplitude, in opposition to hypoxia and hypotension recording features. Still, SSEP monitoring is useful once cerebral blood flow is around 18mL/100g/min, where other modalities were inept to predict postoperative neurological deficit.^{19,37}

Moreover, in neurovascular surgeries, the majority of patients with SSEP changes, either reversible or not, did well postoperatively, although return to baseline was related to fewer deleterious complications.³⁶

Although SSEP decreased accuracy for posterior circulation aneurysm monitoring is known, it had been reported to predict postoperative neurological dysfunction as well. Indeed, for unruptured aneurysm procedures, positive predictive value is 40% against 22% in ruptured ones. For instance, irreversible SSEP decline in unruptured aneurysms procedures were followed by stroke in 80% while the same waveform behavior, in ruptured ones, represented 76% false results plus cases of stroke remain undetected in 72%.²⁸

Whenever CBF is below 14mL/100g/min a persistent reduction in SSEP amplitude by 50% is observed. Regarding its low sensitivity, every SSEP alert for ischemia may be allied to reversal maneuvers (e.g. intraluminal shunt, MAP elevation).³⁸

According to Malcharek et al, when it was possible to reverse signal loss, its recovery occurred within 30 seconds to 27 minutes after intervention, in all patients (N=600). Further, transient motor deficits recovered within 30 minutes to 2 days. About 31% of the patients had signal recovery with MAP increase or shunt plus false negative results from 0 to 3% reassured SSEP and MEP detection ability.^{39,40}

For instance, combination of SSEP and MEP recordings increased ischemic events recognition by reducing false negatives to 0.4%. In addition, SSEP have shown

to be more effective to monitor medial cerebral artery, transcranial SSEP for anterior cerebral artery and to recognize focal ischemia events at corticospinal tract, transcranial MEP were the more appropriate.⁴¹

As stated by Chiang et al, IONM is a reliable tool to localize the recurrent laryngeal nerve and facilitate its timely identification during thyroid operation.⁴² Moreover, Genther et al referred that an abnormal signal would represent an ipsilateral vocal fold palsy in more than 70% of the cases, so that, surgeon's decision for a second stage surgery to the contralateral fold would certainly depend on that information in order to minimize future complications.⁴³

Additionally, Jimenez et al have shown solitary electromyography monitoring of the deltoid muscle to cause a dramatic reduction on the incidence of C5 nerve root palsy, 7.3% to 0.9%. Indeed, delayed C5 palsy interferes with evaluation of multimodality IONM efficacy.⁵

Furthermore, intraoperative MAP above 80 mmHg for more than 55 minutes was an independent predictor of lower incidence of neurapraxia, which is common in upper limbs often due to mechanical factors.⁴⁴

Plus, microsurgical removal of SC hemangiomas with IONM enhances long term outcome. So, unaltered IONM findings are associated with lower risk of new deficit.⁴⁵ According to recent publications, initial postoperative deterioration after intramedullary SC tumor surgery ranges between 18 and 34.6%.⁴⁶

In agreement with recent studies there is a proven relationship between lost transcranial MEP and permanent postoperative neurological deficit during aneurysm occlusion of the basilar, vertebral and medial cerebral artery aneurysms. Also in this context IONM improve surgical decision-making and patient's outcome.^{2,12,14}

As stated by Chen et al, transcranial electric stimulation and MEP recordings are used for high-risk vascular neurosurgery and orthopedic procedures, with greater sensitivity in upper limbs (98% vs 81%). Plus, influenced by motor deficit and lesion's location.⁴⁷ Forward, direct cortical stimulation MEP is a useful predictor of postoperative neurological deficit since warning criteria allows 60% to be reversed. So, whenever direct cortical stimulation MEP is lost it should elicit neuroprotective maneuvers regarding its prognostic value.⁴⁸

Regarding SC surgery, neurologic impairment suffered a reduction, 6.8% to 0.7%, with continuous SSEP monitoring.⁴⁶ In fact, MacDonald et al perceived D-wave to be linear and stable, once intertrial amplitude variability is < 10%. So, there is evidence for decrease of more than 50% for transcranial electric stimulation D-wave monitoring in intramedullary SC tumor and good evidence for 30% to 40% during peri-rolandic brain tumor surgery.^{14,49}

Actually, tumor resection surgery achieved gross total resection in about 72.4% and subtotal in 19.2% alongside with IONM. Likewise, at hospital discharge 22.7% of the patients recovered from preoperative symptoms, though 7.4% shown aggravation.⁴⁶

Moreover, studies concluded that more than 50% decrease in SSEP amplitude and 10% increase in latency is pathologic. Even though sustained by few evidence, a similar conclusion was shown in brainstem auditory evoked potentials and motor evoked potentials.¹⁸

Although cerebral ischemia is detected by SSEP 15 minutes from the event, both EEG and transcranial MEP may identify it earlier. Furthermore, IONM may evaluate cortical and subcortical perfusion level despite SSEP lower sensitivity for subcortical hypoperfusion. However, correlation between SSEP changes and ischemia is well defined even though time to infarction is not clear.³⁶ Plus, may not be obtainable after mielectomy in about 30% of the patients.^{2,4,28}

Discussion

Vascular procedures

In 2014, IONM recommendation was validated regarding its continuous real time functional status update, which enables early neurological damage detection and stroke prevention in endovascular procedures.⁵⁰

Effectively, carotid endarterectomy is the gold standard surgical procedure in symptomatic carotid stenosis to reduce risk of stroke, yet, perioperative stroke is a major complication.^{36,39}

In 2016, Hokari et al referred that tolerance to ischemia is dependent on collateral CBF and duration of ischemia for which the threshold has not been defined. Nevertheless, carotid endarterectomy complications are either thromboembolic or, in 20%, hemodynamic. On this regard, MEP recordings are quite valuable for identification of critical cerebral ischemia during neurosurgery and seems to be more sensitive than SSEP, that still required in order to avoid false negative, especially when only motor pathways are affected, meaning that there might be a role for its use during carotid endarterectomy.

Whenever a carotid artery is clamped, MEP are recorded every minute as indicated, because amplitude reduction below 50% from the control is of notice plus, critical when reduction is up to 70%. Accordingly, mean distal internal carotid artery pressure below 20mmHg may potentiate MEP deterioration, once cerebral hypoperfusion was experienced by 15% of patients. Also, medial cerebral artery pressures below 20mmHg may cause severe brain dysfunction. Since IONM may detect patients who will eventually require intraluminal shunting, intraoperative ischemic events may be timely avoided. However, MEP during carotid endarterectomy are limited and data about ischemia tolerance above 7 minutes is inexistent.^{7,38,40,41,51,52}

Actually, carotid clamping induced IONM changes may occur with more frequency if there is a contralateral carotid stenosis. Diabetes and female gender, are conditions in which the need of shunt is expected, unless they are receiving β - blockers which can produce false positive results.⁵² The same is observed in cerebral and TAAA surgeries in which IONM may predict risk of postoperative motor dysfunction.^{7,52}

According to Malcharek et al, in general, IONM did not increase surgery duration, although period of clamping was prolonged in MEP group. Thereafter, postoperative motor dysfunction presented whenever interval between loss of transcranial MEP signal and intervention enlarged. Nevertheless, transcranial MEP isolated declines may be caused by small vessel disease, such as lacunae ischemia along with internal carotid artery stenosis.^{39,40}

Another condition with high morbidity and mortality is vasospasm, which follows aneurysm rupture. As motor cortex is more vulnerable to ischemia, it is expected that vasospasm of medial cerebral artery will increase MEP threshold of the contralateral upper extremity muscles, whereas the anterior cerebral artery is on lower limbs. Likewise, vasospasm of vertebral or basilar arteries may produce similar alterations due to vascular architecture. In fact, transcranial Doppler, as a bedside inexpensive and noninvasive method may be a great approach. Nevertheless, MEP recordings revealed to be an ideal method regarding its high diagnostic accuracy, reproducibility and information is obtained in time to provide proper treatment and prevent brain tissue necrosis. As a result, its special usefulness in ICU due to quick results and recording tolerability, although limited in diagnostic. Hence, it can contribute to a reduction in rate of cerebral ischemia following vasospasm.^{3,53}

In cases of descending and thoracic abdominal aortic revascularization, paraplegia is a devastating iatrogenic consequence (22%) and MEP monitoring are useful in predicting SCI through non-recovery of recordings. As such, some strategies evolved to reduce rates towards MEP monitoring changes, for example, CSF drainage, hypothermia, distal aortic perfusion and intercostal artery re-implantation, for selected cases. Yet, there are many intraoperative protocols and a general evidence-based consensus is needed. Although most MEP signals are recovered, around 14% don't recover to baseline and are predicted to exhibit permanent postoperative motor deficit.^{10,23,29} Moreover, the last strategy used may be re-implantation of intercostal arteries which besides its positive results may relate to prolonged surgery time, increased risk of bleeding and blood loss never minding the risk of paraplegia plus incidence of late pseudo aneurysm formation. Other strategies have few but strong evidence, such as CSF drainage and cardiopulmonary bypass, in selected cases based on SSEP recordings.^{29,35}

According to Griep et al, paraplegia rates achieved 2% with refining of collateral network; still, long-term adequacy may be obsolete due to hemodynamic conditions.⁵⁴

Even though SSEP permanent changes increase risk of immediate deficit, MEP introduces more sensitivity to SC ischemia detection and reduces Intercostal artery re-implantation rates in initial context. Additionally, MEP demonstrate a greater correlation with outcome than SSEP, due to specificity for anterior horn grey matter.³⁵

As stated by Phillips et al, SSEP monitoring in neurovascular procedures is more consistent in unruptured rather than ruptured aneurysms. Some authors attribute SSEP positive predictive value deterioration to edematous cerebral matter. Interestingly, Wicks et al pointed that irreversible changes in unruptured ones had 80% stroke rate, while similar changes in ruptured may develop without stroke in 58%.^{29,36}

Still, IONM is limited by insufficient data about potential problems and possible successful solutions as its accuracy measurement challenged by surgical procedure's adjustment, generating false positives.^{28,55,56} Nevertheless, unrecovered SSEP had 97% chance of an ischemic perioperative insult; likely caused by hypoperfusion, thromboemboli, shunt malformation or inadequate blood pressure control. Hence, SSEP may assess collateral network, shunt requirements and correlates with neurological outcome.^{36,38,39}

Interestingly, in Lancet's randomized study related to aneurysm procedure, no significant differences in outcome were found when comparing carotid endarterectomy under general and local anesthesia with IONM. Indeed, MEP are useful for anterior and posterior circulation approaches. Lastly, real time monitoring is a valuable tool to guide surgical and anesthesia management. In fact, IONM have great sensitivity for postoperative neurological deficit, plus emboli and hyperperfusion syndrome when monitoring from surgery to postoperative period.^{41,57}

Vocal cords monitoring and cervical procedures

Currently, incidence of recurrent laryngeal nerve (RLN) injury after a neck surgery is between 2.3% to 5.2%. In fact, success in preventing RLN injury and utility of IONM during esophagectomy made it a standard method.^{2,7}

According to Chiang et al, the RLN anatomical variations can be a potential cause of nerve injury because of visual misidentification. Thus, RLN palsy occurs in 1 to 2 % and temporarily in 5 to 6% with IONM, although a facilitated recognition of the anatomical variety led to a decline in nerve injury, particularly in cases of re- intervention and surgical malignant disease.^{42,58}

As follows, Alesina et al (N=250) presented higher percentage of RLN palsy when assisted by IONM, which was contradictory to results obtained in similar studies, Barczynski et al (N=151), Frattini et al (N=152), Zheng et al (N=36487) and Caló et al (N=2034). Effectively, majority demonstrated significantly lower RLN morbidity when assisted by IONM, partial or transient palsy but less difference in permanent injury. Nevertheless, it improved thyroid surgery outcome with excellent specificity and negative predictive value.^{42,59-62}

Once dissected, RLN loss of signal had 90% chance of intraoperative recovery. So that, unchanged positive signal is highly predictive of intact nerve function. According to Genther et al, IONM of RLN with electromyography provides real time information regarding its integrity and may predict immediate postoperative vocal fold palsy reliably when accepted a cut-off of 200 μ V. Mainly, it provides vital information when manipulated bilaterally because of airway complication, which may require tracheostomy or re-

intubation. In fact, real time data are important for surgical guidance and planning, particularly for bilateral thyroid surgery. Meanwhile, once electromyography is abnormal, IONM predictive value is limited.^{43,62}

Furthermore, routine laryngeal exam is needed to avoid underestimation of incidence of temporary or permanent vocal fold palsy later. Nevertheless, isolated symptomatic voice assessment is insufficient to avoid this condition and may be limited by intraoperative situations. Currently, direct visualization results in a lower rate of recurrent laryngeal nerve injury in comparison to neural avoidance alone. Meanwhile, there are inconsistent findings when comparing methods.⁴³

Regarding posterior cervical surgery, Lee et al evaluated multimodality IONM efficacy shown limited detection and prevention of delayed onset of cervical C5 palsy, mainly iatrogenic injury, which may also simulate false positive result and appear in 1.2% of posterior decompression surgery. Plus, detection rate may increase with electromyography and transcranial MEP combination, nevertheless, IONM alteration is not influenced by comorbidity and age although these may not correlate with outcome.⁵

Cerebral surgery

Effectively, IONM may detect cortical and superficial subcortical ischemia, nevertheless, direct cerebral stimulation has focal activation and achieves ischemia detection without instigating involuntary movements which interfere with micro- dissection as transcranial electrical stimulation MEP.^{7,26}

Nevertheless, these modalities may cause subdural bleeding and brain injury plus both are vulnerable to anesthesia protocol and variability may be reduced using close to motor threshold stimulation and focal one-electrode montages.

For instance, a reproducible decrease of more than 50% and latency increase above 10% plus recording disappearance for more than 10 minutes is likely to be followed by postoperative motor deficit.^{20,26,48}

Similarly, MEP may also be more sensitive than SSEP detecting brainstem ischemia caused by perforating artery occlusion. However, MEP recordings should not replace SSEP monitoring during aneurysm surgery.^{20,26,63}

Recently, it has been demonstrated that cerebral metastases infiltrate surrounding brain tissue, so that, IONM minimizes postoperative motor deficit and increases resection area, although correlation to MEP deterioration pattern is yet to be found. Additionally, 21% exhibited postoperative neurological improvement depending on tumor location.⁶⁴

In fact, residual tumor occurred in 29% of cases with MEP reduction, suggesting an association, likewise, secondary hemorrhage or ischemia may explain false negative

results in IONM. On this regard, one should include all evoked potentials in multimodality IONM during selected surgeries, such as transphenoidal surgery, aneurysm clipping of posterior circulation and removal of tumors that lie near the optical radiation.⁶⁴

Regarding visual evoked potentials, useful vision pathways integrity may not be expressed unless electroretinography and monochromatic stimulator are combined. Furthermore, anesthesia protocols may exclude volatile general anesthesia and specialists must notice that new major vision field alteration may pass undetected. Finally, real time monitoring is impractical due to time required to obtain each waveform, plus minimum visual function must be defined and its changes take 32 seconds to measure. Then turns out to be impossible to correlate injuries and causative events or timely prevent it.^{6,7,31,65,66}

Cerebral arteriovenous malformation

Ichikawa et al stated MEP recordings plus mapping facilitate detection of BFI and direct injury towards corticospinal tract. In several arterial venous malformation surgeries, MEP potentiated feeding arteries location and replaced the previous invasive standard method, intraoperative fluorescence angiography. For instance, MEP change within 1 minute of BFI in perforators (i.e. anterior choroidal artery, lenticulostriate arteries), also changing with excessive pressure and tratrography may fail to localize corticospinal tract lesions because of brain shift due to CSF drainage.^{13,26}

Regarding MEP alterations, surgery should be stopped, and corticospinal tract released from pressure in order to preserve motor function. Forward, for anterior circulation aneurysms SSEP and EEG are often used and in monitorization of posterior circulation abnormalities brainstem auditory evoked potential are added. Moreover, transcranial MEP are added whenever internal capsule or subcortical tracts and large-sized aneurysm are involved. Nevertheless, postsurgical period may be monitored by SSEP since they are less affected by anesthesia protocols and muscle relaxants.^{20,33,35}

According to Lepski et al, MEP reduction of less than 15% from baseline was related to good recovery of motor function, meanwhile, disappearance correlates with long term impairment.⁶⁷

Effectively, perioperative risk may be significantly reduced if surgical strategy is defined while taking into account anatomic functional mapping of motor cortex and descending pathways.⁶⁷

In reality, expectant treatment of arterial venous malformations is related to hemorrhagic risk (1% to 4%) and may increase during the first year after an hemorrhagic event. Hereafter, 16% were moderate to severely disabled after this event which outrange

treatment related morbidity. Whenever previous neurologic disability is present, IONM is ineffective due to drastic reorganization of cortical representation.⁶⁷

In this context, MEP assessment reduced surgical time not being limited by general anesthesia or surgery related cerebral edema and real time information makes it suitable for arterial venous malformation procedures with postoperative motor deficit risk.^{13,26}

Spinal cord surgery

Currently, both MEP and SSEP are used in spine surgery integrity in order to increase sensitivity. For instance, motor and sensory pathways are anatomically distinct and have different vascular supply in cortical areas, brainstem and SC.^{1,19,26}

Furthermore, early detection encourages surgical team to perform a quick intervention and prevent injury progression or to reverse impending neurological sequel.^{1,24}

Thereafter, loss of monitoring signal may occur in various occasions, such as, during correction (57%) or placement of the instruments (26%), mispositioning of instruments and few led to neurological injury (1.4%). Raynor et al also attributed recordings' changes to systemic factors. Interestingly, IONM changes were more common in revision surgeries than in primary.^{1,40,68,69}

As stated by Koht et al, risk of paralysis during scoliosis correction is reduced using MEP monitoring whereas SSEP would occasionally fail to detect motor pathways lesion. As expected, transcranial MEP monitoring is believed to improve outcome and reduce risk in a wide variety of axial skeletal deformity surgeries. Therefore, muscle response of the transcranial MEP is more sensitive to corticospinal tract ischemia because it implicates synapses in the spinal grey matter and its vascular supply. By contrast, white matter can be monitored by SSEP as well as corticospinal tract by D- waves, though with lower sensitivity.^{12,20}

Indeed, sudden drop in SSEP and MEP recordings at lower limbs following deformity correction have reversal correction and implant removal as effective strategies to recover. Then, false positive and false negative may be reduced by multimodal approach.^{1,5,47}

Whenever SSEP deteriorate successful resuscitative maneuvers like reversal of hypotension, positioning adjustment, distraction release, cessation of manipulation and/or grafts removal and duroplasty may be attempted.^{1,4}

Interestingly, isolated motor changes may result from mechanical, vascular injuries or hypotensive anesthesia. Actually, insult from SC hypoperfusion may be due to a mechanical stress without blood pressure alteration.¹

In truth, pathological IONM findings correlate with worse long-term outcome as detected with Oswestry Disability index score. Further, rate of gross total resection was higher when used IONM. In fact, electromyography may complement anatomical location of nerve roots as well as recognize irritation or traction features.¹⁸

Although controversial, some factors may negatively affect the prognosis, such as, tumor volume, ventral localization and association with peritumoral edema, even though relation with outcome was not found. Additionally, partial removal procedures' outcome could not be evaluated.⁴⁵

Also, disappearance criterion may not be sensitive enough to detect partial SCI that leads to postoperative motor deficit, but it is still the best predictor for long term prognosis regarding its specificity.⁷⁰

Effectively, IONM is considered to be a valuable tool to predict risk of adverse outcomes, such as, paraparesis, paraplegia and quadriplegia. Moreover, its predictive value enables guidance over intraoperative decision-making and subsequent measures to be taken. Several studies have shown that IONM allows postoperative prognosis and preoperative deficits recovery recognition. Nevertheless, preoperative motor weakness or neuromuscular scoliosis decrease MEP recording value, still, Wang et al concluded MEP monitoring is feasible for most high risk diagnosis and complicated surgical procedures with sudden loss meaning postoperative neurological deficit. Nevertheless, patients with preoperative deficit may present neuromonitoring signal drop with normal spinal function, so that, stays as an important question if monitoring loss is a strong predictor of PND.^{14,21,23,50,68,71,72}

Limitations

Even though the strongest evidence is earned by controlled randomized studies, several ethical and methodical concerns are responsible for the lack of these trials. Indeed, IONM techniques known value is highly limitative and subsequently many studies were abandoned since no IONM meant more frequent PND. Therefore, most studies are observational and lack evidence quality, in addition, demographic factors and vascular risk facts differences may introduce some bias.^{3,20,39,49}

Also, lack of standardized protocols is a constant limitation, which jeopardizes comparison between studies since the procedure and warning criterion may vary between centers.⁴³

In addition, Sala et al enhanced that only after 3 months of follow up, significant difference in neurologic status between procedures with or without IONM could be observed. This could be explained by neurologic deterioration pattern. Indeed, a greater

recovery is seen in presence of transient or minor change in waveforms.^{14,46}

Some valid studies lack to demonstrate which strategies followed an alert signal. Despite recovery success, there is no consensus in progress. So that, clinical utility of IONM remains difficult to attend.^{29,50}

Furthermore, the monitoring team has to be multidisciplinary, trained and experienced in neurophysiology, plus its clinical aspects, and EP application knowledge. Essential artifact discriminations, clinical significance and wellness of surgical patients must be achieved.¹⁰

Conclusion

Effectively, intraoperative EP have a role as an adjuvant tool to several types of procedures. In fact, risk-benefit studies recommend its use in certain surgeries with known risk of PND.

Furthermore, the current trend shows that procedures are becoming more accurate and integrity of neurologic pathways is being monitored in real time, as a result, outcomes tend to be better and, sometimes, predictable. In fact, it enables specialists to prevent PND and facilitates real time decision-making. Also, there is crescent evidence related to recordings' recovery and successful discharge status.

In order to potentiate multicenter trials comparison there is a need for standardized protocols, with defined warnings threshold and properly defined concepts, plus a specialized team with adequate communication to accurately detect events and react effectively.

Moreover, the wake up test has important limitations and further evolution in IONM devices will overcome its restrictions.

Nowadays, IONM devices function in multimodality mode and are not only assessable solutions for spine, neurologic and vascular procedures, but also allow customized settings and direct access to any parameter whenever necessary during surgery.

Appendix A

Key highlights

1. **IONM evidence-based recommendations and relevant features**

- Proven effectivity in neurosurgery tumor or epileptic focus resection near motor cortex or corticospinal tract, intracranial aneurysm clipping, posterior fossa surgery, cranial-cervical junction, spinal cord procedures and *cauda equina* approach.
- In orthopaedics, a valuable tool in spinal deformity correction surgery, fracture, vertebral tumor resection and anterior cervical discectomy.
- In vascular surgery has indication in descending aorta procedures, arterial venous malformation in spinal cord and carotid endarterectomy.¹⁹
- Costs are less than direct ones from care related to acquired deficits in experienced teams with the best outcomes.³
- Spinal deformity surgery is the leading indication and its absence in thoracic and thoracolumbar spinal deformity surgeries reduces patient's good outcome.²⁴
- A preoperative checklist may include anesthesia protocol, warning criteria for postoperative neurological deficit, plus, reversal maneuvers on response to a positive alarm.¹

2. **Anesthesia effect**

- Anesthesia protocols are required to avoid interference with MIOM recordings.
- Total intravenous anesthesia is recommended with propofol and opioids combination.
- Halogenated inhalation agents, high dosage and muscle relaxants may decrease recordings register.
- Ketamine seems to increase amplitude of evoked potentials.^{73,74}

3. **Enables early preventive maneuvers**

- In spinal surgery enhances the assessment of neural integrity and guides surgeon through the procedure by predicting neurological outcomes, enabling the relevant preventive measures to be taken.^{4,50}
- Majority of SSEP changes can be reversed resulting in no permanent deficit in spinal surgery context.⁶⁸
- The lesion level guides corrective maneuvers in deformity correction surgery in order to improve neurological outcome.²⁴
- After transcranial MEP application, motor deficits were avoided in 12 of 98 patients by institution of adequate corrective maneuvers in response to these alerts.⁷⁵

4. **Limitations IONM recordings**

- **MEP** have less value if preoperative motor weakness or neuromuscular scoliosis is present.^{14,21}
- Requires more restrictive anesthesia protocols, may cause patients' movements and has less clear established alarm criteria.²³
- Has an imperfect correlation to early postoperative motor function.¹⁹
- **High rate of false positive** alarm and may lead to premature and unnecessary

interruption in the surgery so that it was proposed a decrease in limit to peak-to- peak amplitude decrease to 80% to MEP monitoring.⁷⁶

- **MEP monitoring** are criticized because of the high intertrial variability of muscle MEP amplitude, sensitivity to insult of spinal cord is quite high, and the incidence of false positive results will increase if judgment is based purely on this potentials.
- **SSEP** monitoring may be affected by fluctuation of systemic factors like core temperature, hemodynamic aspects or, even an increased signal due to neuromuscular blocking agents at the intubation moment.
- False negative are hard to evaluate since surgeons alter their conduct in concordance to MEP waveform alteration.⁶⁶
- **Potential injuries** could include brain damage, seizures, kindling, epidural complications and accidental injuries caused by bite injuries, adverse cognitive or affective squeal and others like cardiac arrhythmia, intraoperative awareness, scalp burns, pain or headache, and disturbances of hormonal or hematological hemostasis.^{3,19}
- SSEP gives an average signal for the dorsal column and, as a result warning alert is delayed and injury may become permanent before any changes in SSEP.³

5. IONM as an alternative to wake up test

- Some patients may not be capable to **cooperate** with the wake up test due to age, language barriers or mental status.
- Awaken a patient requires a **prolonged pause** in the surgery and progressive reduction of the pharmacological load with consequent rise in blood pressure; interestingly this maneuver may improve spinal cord function.¹
- **MEP** have the ability to detect changes in motor strip and tract but not the premotor strip and tract in opposition to neurological examination. So that, it should be done together in order to increase both sensitivity and specificity of intraoperative monitoring awake examination.
- Still, is used in procedures like tumor resection, epilepsy surgery, deep brain stimulation and carotid endarterectomy.
- Wake up test is not effective to detect subtle weakness, timing or location of injury especially in patients that still partially sedated and unable to follow commands because intellectual or development disabilities or preoperative weakness too. May happen self- extubation, loss of intravenous access, loss of positioning, air embolus and/or event recollection.¹⁰
- Given time for patients to awake from general anesthesia may be insufficient for an accurate examination leading to anesthesia-induced hemiparesis.^{76,77}

6. Transcranial Motor Evoked Potentials (tcMEP) deterioration

- High rate of false positive alarm may lead to premature and unnecessary interruption in the surgery and prognosis prediction becomes harder.⁷⁶

- Patients with alarm criteria on transcranial MEP showed postoperative deficit for a month, otherwise, in cases of 50 to 80% attenuation of waveform in transcranial MEP gradually recovered 1 month later.⁵⁰

7. Multimodality IONM group

- **More high cervical lesions** than control group have been shown. These have more complex neural and vascular integrity than lower cervical lesions, so multimodality IONM should be thought.
- False positive results may come from electrocautery irritation or muscle tightness from prolonged prone positioning with skull fixation.
- If recovery of trapezius electromyography changes during surgery were seen, there were not encountered post-operative neurological deficits.
- Multimodality IONM may play a restrictive role in preventing delayed onset C5 palsy in lower cervical regions so far (only in C1-C2 joint seems to have a drop and recovery when maneuvered).
- Multimodality IONM may have limited value in routine, non-traumatic or non- severe deformity cases based on great results without IONM.⁵

8. Congruent MEP deterioration do not necessarily imply ischemia

- Antagonist α 2 adrenergic or antihypertensive drugs can reduce MEP by elevating motor neuron excitability.
- Magnesium sulfate reduces blood pressure so may reduce MEP; in addition may potentiate neuromuscular blockage.
- Low temperatures raise latencies and higher reduce it. In a deep hypothermia muscle MEP are obliterated.
- Severe electrolyte abnormalities, hypoxemia, hypercapnia, hypocapnia or anemia can produce MEP deterioration.¹

9. Relative contraindications for MEP

- Epilepsy, cortical lesions, skull defects, intracranial vascular clips, shunts or electrodes.
- Pacemakers or other implanted bioelectric device, yet there is no evidence of increasing transcranial electric stimulation complications.¹⁹

10. Evidence-based recommendations¹⁹ (table I, II and III)

Appendix B

Published review article

Review Article

Intraoperative Evoked Potentials: A Review of Clinical Impact and Limitations

Ana Sofia Marafona¹ and Humberto S Machado^{1,2,3*}

¹Instituto Ciências Biomédicas Abel Salazar, Universidade do Porto, Portugal

²Serviço de Anestesiologia, Centro Hospitalar do Porto, Portugal

³Centro de Investigação Clínica em Anestesiologia, Centro Hospitalar do Porto, Portugal

* **Corresponding author:** Humberto S Machado, Serviço de Anestesiologia, Centro Hospitalar do Porto, Portugal, Tel: +351.935848475; E-mail: hjs.machado@gmail.com

Received date: December 26, 2017; **Accepted date:** January 22, 2018; **Published date:** January 29, 2018

Copyright: ©2018 Marafona AS, et al. This is an open-access article distributed under the terms of the Creative Commons Attribution License, which permits unrestricted use, distribution, and reproduction in any medium.

Abstract

Background: Nowadays, intraoperative evoked potentials are recommended in a variety of procedures but there is still a lack of standard protocols and consensus about warning criteria. Moreover, studies are now being made to fundament its risk-beneficial ratio through recordings' predictive value for short and long term outcomes. Furthermore, wake up test limitations encouraged intraoperative evoked potentials research, a reliable monitoring technology.

Objectives: This literature revision aims to acknowledge last decade intraoperative evoked potentials technological advances and fundament its clinical impact in multiple contexts.

Methods: A literature review based on clinical series from 2007 to June 2017.

Results: Combined intraoperative evoked potentials sensitivity and specificity of IONM for sensory motor impairment was 100 and 98%, respectively. SSEP (somatosensory evoked potentials) and MEP (motor evoked potentials) responses successfully recognize sensory and motor cortex, 91% and 99%, correspondingly. Upon that, combined monitoring modalities are considered essential since they can limit unnecessary morbidity. In series, 3.83% of recordings were altered and 44.44% reversible. Despite requiring predictive factors for neurological injury identification, reversibility and decreased duration of altered waveform indicates a favorable outcome, based on presentation and discharge evaluation. In opposition, irreversibility of signal's deterioration is related to a decrease on Glasgow outcome scale at long-term follow up. At last, intraoperative evoked potentials demonstrated high sensitivity, specificity and negative predictive value.

Conclusions: Intraoperative evoked potentials have a role as an adjuvant-monitoring tool. Risk-beneficial studies recommend its use in surgeries with known risk of neurological injury. Furthermore, surgical procedures are more accurate and integrity of neurologic pathways better preserved when real time monitored is used. As a result, outcomes tend to be better and more predictable. Nevertheless, standardized protocols, warning signals criterion and specialized teams with adequate communication are still required in order to accurately detect waveform deterioration and exclude artifacts.

Keywords: Intraoperative evoked potentials; Patient outcome assessment; Intraoperative monitoring; Somatosensory evoked potentials; Motor evoked potentials

Introduction

Since the 20th century intraoperative evoked potentials (EP) have been initially used to improve spine surgery's safety through real time assessment of neural structures at risk. According to Pastorelli et al. a cost-effectiveness analysis led to more extended recommendations [1].

Currently, intraoperative neurophysiological monitoring (IONM) is known to enhance specialist's ability to prevent intraoperative nocive maneuvers, predict and improve both outcomes and decision-making [2-8]. Even more, surgical approach became more aggressive and accurate along with a greater impact in patients' outcome plus quality of care during surgical procedures [9].

Thus, intraoperative assessment of functional integrity of the brain, brainstem, spinal cord (SC) and peripheral nerves becomes helpful once increased risk is recognized [10,11]. And, thereafter, to identify sensorimotor cortex and recognize structures in order to guide procedures. Furthermore, special caution is needed since previous neurological deficits may represent a false positive result, in addition to the fact that IONM assessment is avoided once limb edema, peripheral neuropathy or anatomical variant are present [12,13].

Thus, total disappearance of recordings is a strong predictor of early paralysis or paresis either permanent or temporary. Besides, waveform disappearance is not a sufficient criteria outside SC monitoring, so that, additional criteria is required [14].

Moreover, neuromonitoring can include spontaneous activity recording (e.g. electroencephalogram and spontaneous electromyogram) or evoked response to stimulus, which reassembles

somatosensory evoked potentials (SSEP), motor evoked potentials (MEP) and brainstem auditory evoked potentials (BAEP). As a result, a diversity of techniques increases reliability of the recordings and overcome most of the singular limitations along with excellent clinical outcome correlation. Exceptionally, IONM may be rather useless during certain surgical procedures (i.e. pituitary adenoma resection without cavernous sinus invasion) [2,12,15-18].

Still, one of the aspects brought on by these techniques is the replacement of wake up test, which depends on patient's cooperation and is highly variable. However, the wake up test may remain set when SSEP are used isolated due to corticospinal tract injury alone [1].

SSEP recordings are able to detect blood flow insufficiency (BFI) during intracerebral surgeries, regarding cortical and subcortical function. Furthermore, limb malpositioning, may cause peripheral nerve conduction failure which may resemble BFI; these situations are often concurrent with MEP signal deterioration. Peripheral sensitive evoked potentials may help to identify these problems [18,19].

In addition, neuromonitoring requires a multidisciplinary, trained staff with clinical neurophysiologic knowledge in order to exclude artifacts and accurately identify signal drop or disappearance with clinical meaning. Plus, monitoring modality should be chosen by the surgeon and his team to better locate, monitor and protect structures known to be at risk depending on surgical approach [7,15,20,21].

For instance, recordings' changes can result from surgical maneuvers, pharmacological interventions, patient's positioning during the procedure and anatomical variation, always including the physiological component [7,21,22].

Moreover, complications related to positioning on the operating table may consist of severe motor deficit, a secondary damage of nervous plexus extreme positioning (i.e. brachial plexopathy). Eventually, it may be avoided once IONM manifests alterations for upper limbs, despite this might be recognized as a tangential benefit [1].

In fact, IONM potentiates procedures' strategic alterations aiming to prevent perpetual neurological deficit, such as degree of distraction adjustment, retractors or grafts correction, reimplanting or unclamping arteries, placing vascular bypass grafts and minimizing the remaining portion of the surgery of others [17,23,24].

Furthermore, IONM evaluates cortical and subcortical structures as well as their perfusion level. This may lead to greater sensitivity and specificity when evaluating neural structures at risk during a technically demanding surgical approach [18].

Objectives

This review aims to update IONM clinical utility evolution, mainly, in neuro, vascular and orthopedic surgeries. Furthermore, to understand the impact of this technology in patients' immediate and long term outcome.

Materials and Methods

Search strategy

An online search of PUBMED and GOOGLE SCHOLAR from 2007 to June 2017 was carried out. This subject exploration was restricted to studies published in English language.

Search terms included Intraoperative evoked potentials, motor evoked potentials, MEP, intraoperative neuromonitoring, evoked potentials utility, intraoperative evoked potentials indications, limitations of intraoperative neuromonitoring, patients' outcome, neuromonitoring. In addition, the reference lists of all retrieved articles were examined for further relevant articles.

Selection criteria and definitions

Articles eligible for inclusion were manuscripts where some relevant evidence of Intra-Operative evoked potentials benefits, usefulness and limitations was encountered, as studies to evaluate possible awareness criterion and clinical relation.

Exclusion criteria included: other language of publication, case reports, and case series including less than 20 patients.

Figure 1 shows inclusion/exclusion methodology of manuscripts.

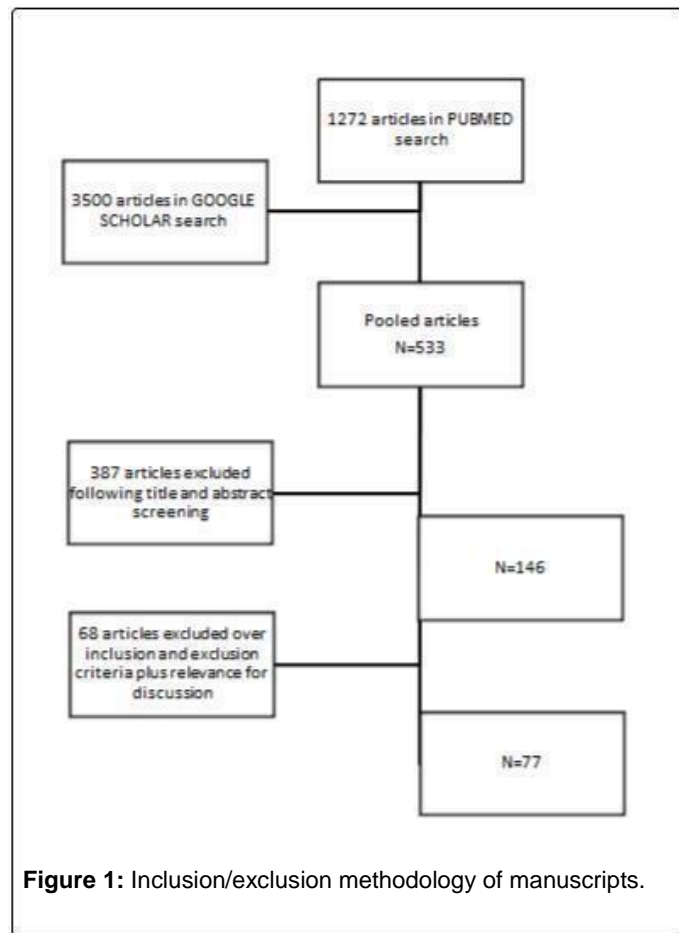


Figure 1: Inclusion/exclusion methodology of manuscripts.

Results

In 2007, a series of 87 cases of endovascular aortic repair reassured IONM recommendation since it allowed SC ischemia detection and subsequent protective interventions. In fact, benefits outweighed associated risks with a sensitivity of 93% and specificity of 96% for IONM.

In 2010 AHA Aortic Guidelines states that IONM may be considered a strategy to detect SC ischemia. Nevertheless, MEP sensitivity and specificity remain in need of more evidence. [25].

In 2011 combined sensory evoked potentials (SEP) and transcranial MEP sensitivity and specificity for sensory motor deficiency was 100 and 98%, respectively [1]. Individually these methods are successful for identifying sensory and motor cortex in 91 and 99%, correspondingly [2].

In 2012, a 1500 cases series review of MEP monitoring stated that it is sufficiently safe for clinical use in instructed hands and with proper precautions since some rare adverse events like bite wounds, dangerous output, seizures or arrhythmia were identified [19].

In 2014, IONM was routinely being used during endovascular or microsurgical repair of intracranial aneurysm at main centers with great sensitivity, specificity and negative predictive value. In the Sahaya et al. series (N=470) recordings were altered in 3.83% of which 44.44% reversible. Despite requiring predictive factors for postoperative neurological deficit identification, reversibility indicates a favorable outcome. In comparison, signal drop irreversibility (33.33%) was related to deterioration in Glasgow outcome scale at long term follow up. Some studies documented SSEP usefulness in postoperative neurological deficit detection, along with the fact that increasing MAP successfully reversed few false negatives and multiple altered waveforms [18,20,26].

Regarding a study from 2010 to 2014, the ability to monitor transcranial MEP and SSEP was 92% and 57% respectively. In this cohort, cases of transcranial MEP irreversible waveform drop from 50 to 80%, with a high risk of a permanent neurological deficit, did not have this anticipated negative ending since all patients recovered in about 1 month after surgical procedures. Also, disregarding any medical intervention, clinical result and walking function may be predicted by transcranial MEP after SC lesion.

In context of IONM during arthrodesis in adolescent idiopathic scoliosis changes occurred about 5.3% in severe conditions and with technological advances, in 2006, a study revealed a rate of 0.5% of which 61% recovered completely [10].

Furthermore, cortical pathways are affected by anesthesia in a greater extent than subcortical and SC recordings, regarding inhibitory effect of general anesthesia on neurotransmission. Meanwhile, the level of influence is variable according to monitoring method, such as brainstem auditory EP are less sensitive to its effects and visual EP are the most vulnerable ones. In addition, administering opioids or nitrous oxide with midazolam or propofol, preserves the cortical SSEP while benzodiazepines result in its moderate depression. Effectively, morphine effect on SSEP recordings was greater when in bolus and the subarachnoid administration of meperidine produced 60% decrease in cortical posterior tibial nerve SSEP amplitude and a 10% increase in latency. In this context, since a 2015 randomized controlled trial, dexmedetomidine has consistently proven to be a safe adjuvant to intravenous anesthesia on SSEP, MEP and visual evoked potentials recordings, without latencies and amplitudes shifts in therapeutic doses. Upon that, neuromuscular blocking drugs may improve waveform quality by amplifying signal to noise ratio and eliminating electromyography (EMG) artifact [7,27].

As stated by Wicks et al. anesthesia effects, manipulation and temporary clipping were possible to track by SSEP during intracranial aneurysms surgery. Moreover, Clark et al. (N=277) intervention anterior circulation aneurysms with SSEP monitoring. Hence, an amplitude decrease over 50% reversed after procedure's adjustment demonstrated better neurologic outcomes than a persistent decline [28].

In descending and thoracoabdominal aorta aneurysm repair, MEP monitoring (N=1297) revealed normal signal in 69.6% and decreased in 30.4%. Also, normal SSEP were reported despite permanent neurological deficit. In order to regain MEP, a diversity of strategies were attempted, such as increase of distal aortic perfusion or central venous pressure, cerebrospinal fluid (CSF) drainage and re-implantation of intercostal arteries [10,22,29].

Furthermore, D-waves produced by motor cortex pyramidal cells (white matter), have little value during descending aortic surgery, because motor deficits may occur due to grey matter insult, without D wave changes. In addition, white matter has relative resistance to ischemia. An amplitude reduction over 50% has been used as warning criteria in motor cortex monitoring [14]. Thus, an acute spinal cord ischemia disables anterior horn cells causing myogenic MEP loss, while corticospinal tract conduction and D-wave may be unaffected or begin to fail later [30].

Thereafter, MEP recordings during aneurysm clipping were related to 8 min of gradual signal deterioration after clipping and 12 min until signal recovery. As stated by Hayashi et al. MEP monitoring may be more useful in unruptured aneurysm surgery [31,32].

Regarding Coselli et al. intercostal re-implantation was performed in 61.3% of the patients, CSF drainage and distal aortic perfusion were also performed in lower percentage, yet, neuromonitoring was not used and overall incidence of spinal cord injury (SCI) was about 3.8% although it was higher for severe thoracic abdominal aortic aneurysm. Altogether these strategies are able to decrease the incidence of SCI, particularly in severe cases [33,34].

Recent studies elucidate that 25% of MEP alterations displayed simultaneous SSEP changes and persistent loss of MEP was associated with paraplegia development even when SSEP recovered. Furthermore, SSEP monitoring facilitates CSF drainage and catheter insertion although there is no evidence that CSF drainage may prevent SCI after open aortic surgery [33,35].

In neurovascular surgery, SSEP changes reversibility and decreased duration, based on presentation and discharge evaluation, were associated with a more favorable outcome [28,36]. There was SSEP signal deterioration in 4% of the patients and its sensitivity was 25%, also, overall positive predictive value was about 30% [36].

Currently, some IONM physiological confounding factors are recognized and categorized as follows: body temperature interfering with temporary axonal conduction alterations, hypocapnia which causes latency shortening and increase cortical amplitude, in opposition to hypoxia and hypotension recording features. Still, SSEP monitoring is useful once cerebral blood flow (CBF) is above 18 ml/100 g/min, where other modalities were inept to predict postoperative neurological deficit (PND) [19,37].

Moreover, in neurovascular surgeries, the majority of patients with SSEP changes, either reversible or not, did well postoperatively, although return to baseline was related to fewer deleterious complications [36].

Although SSEP decreased accuracy for posterior circulation aneurysm monitoring is known, it had been reported to predict postoperative neurological dysfunction as well. Indeed, for unruptured aneurysm procedures, positive predictive value is 40% against 22% in ruptured ones. For instance, irreversible SSEP decline in unruptured aneurysms procedures were followed by stroke in 80% while the same

waveform behavior, in ruptured ones, represented 76% false results plus cases of stroke remain undetected in 72% [28].

Whenever CBF is below 14 ml/100 g/min a persistent reduction in SSEP amplitude by 50% is observed. Regarding its low sensitivity, every SSEP alert for ischemia may be allied to reversal maneuvers (e.g. intraluminal shunt, MAP elevation) [38].

According to Malcharek et al. when it was possible to reverse signal loss, its recovery occurred within 30 S to 27 min after intervention, in all patients (N=600). Further, transient motor deficits recovered within 30 min to 2 days. About 31% of the patients had signal recovery with MAP increase or shunt plus false negative results from 0 to 3% reassured SSEP and MEP detection ability [39,40].

For instance, combination of SSEP and MEP recordings increased ischemic events recognition by reducing FN to 0.4%. In addition, SSEP have shown to be more effective to monitor medial cerebral artery, transcranial SSEP for anterior cerebral artery and to recognize focal ischemia events at corticospinal tract, transcranial MEP were the more appropriate [41].

As stated by Chiang et al. IONM is a reliable tool to localize the recurrent laryngeal nerve and facilitate its timely identification during thyroid operation [42]. Moreover, Genther et al. referred that an abnormal signal would represent an ipsilateral vocal fold palsy in more than 70% of the cases, so that, surgeon's decision for a second stage surgery to the contralateral fold would certainly depend on that information in order to minimize future complications [43].

Additionally, Jimenez et al. have shown solitary electromyography monitoring of the deltoid muscle to cause a dramatic reduction on the incidence of C5 nerve root palsy, 7.3% to 0.9%. Indeed, delayed C5 palsy interferes with evaluation of multimodality IONM efficacy [5].

Furthermore, intraoperative MAP above 80 mmHg for more than 55 min was an independent predictor of lower incidence of neurapraxia, which is common in upper limbs often due to mechanical factors [44].

Plus, microsurgical removal of SC hemangiomas with IONM enhances long term outcome. So, unaltered IONM findings are associated with lower risk of new deficit [45]. According to recent publications, initial postoperative deterioration after intramedullary SC tumor surgery ranges between 18 and 34.6% [46].

In agreement with recent studies there is a proven relationship between lost transcranial MEP and permanent postoperative neurological deficit during aneurysm occlusion of the basilar, vertebral and medial cerebral artery aneurysms. Also in this context IONM improve surgical decision-making and patient's outcome [2,12,14].

As stated by Chen et al. transcranial electric stimulation and MEP recordings are used for high-risk vascular neurosurgery and orthopedic procedures, with greater sensitivity in upper limbs (98% vs. 81%). Plus, influenced by motor deficit and lesion's location [47]. Forward, direct cortical stimulation MEP is a useful predictor of postoperative neurological deficit since warning criteria allows 60% to be reversed. So, whenever direct cortical stimulation MEP is lost it should elicit neuroprotective maneuvers regarding its prognostic value [48].

Regarding SC surgery, neurologic impairment suffered a reduction, 6.8% to 0.7%, with continuous SSEP monitoring [46]. In fact, MacDonald et al. perceived D-wave to be linear and stable, once intertrial amplitude variability is <10%. So, there is evidence for

decrease of more than 50% for transcranial electric stimulation D-wave monitoring in intramedullary SC tumor and good evidence for 30% to 40% during peri-rolandic brain tumor surgery [14,49].

Actually, tumor resection surgery achieved gross total resection in about 72.4% and subtotal in 19.2% alongside with IONM. Likewise, at hospital discharge 22.7% of the patients recovered from preoperative symptoms, though 7.4% shown aggravation [46].

Moreover, studies concluded that more than 50% decrease in SSEP amplitude and 10% increase in latency is pathologic. Even though sustained by little evidence, a similar conclusion was shown in brainstem auditory evoked potentials and motor evoked potentials [18].

Although cerebral ischemia is detected by SSEP 15 min from the event, both EEG and transcranial MEP may identify it earlier. Furthermore, IONM may evaluate cortical and subcortical perfusion level despite SSEP lower sensitivity for subcortical hypoperfusion. However, correlation between SSEP changes and ischemia is well defined even though time to infarction is not clear [36]. Plus, may not be obtainable after mielectomy in about 30% of the patients [2,4,28].

Discussion

Vascular procedures

In 2014, IONM recommendation was validated regarding its continuous real time functional status update, which enables early neurological damage detection and stroke prevention in endovascular procedures [50].

Effectively, carotid endarterectomy is the gold standard surgical procedure in symptomatic carotid stenosis to reduce risk of stroke, yet, perioperative stroke is a major complication [36,39].

In 2016, Hokari et al. referred that tolerance to ischemia is dependent on collateral CBF and duration of ischemia for which the threshold has not been defined. Nevertheless, carotid endarterectomy complications are either thromboembolic or, in 20%, hemodynamic. On this regard, MEP recordings are quite valuable for identification of critical cerebral ischemia during neurosurgery and seems to be more sensitive than SSEP, that still required in order to avoid false negative, especially when only motor pathways are affected, meaning that there might be a role for its use during carotid endarterectomy.

Whenever a carotid artery is clamped, MEP are recorded every min as indicated, because amplitude reduction below 50% from the control is of notice plus, critical when reduction is up to 70%. Accordingly, mean distal internal carotid artery pressure below 20 mmHg may potentiate MEP deterioration, once cerebral hypoperfusion was experienced by 15% of patients. Also, medial cerebral artery pressures below 20 mmHg may cause severe brain dysfunction. Since IONM may detect patients who will eventually require intraluminal shunting, intraoperative ischemic events may be timely avoided. However, MEP during carotid endarterectomy are limited and data about ischemia tolerance above 7 min is inexistent [7,38,40,41,51,52].

Actually, carotid clamping induced IONM changes may occur with more frequency if there is a contralateral carotid stenosis. Diabetes and female gender are conditions in which the need of shunt is expected, unless they are receiving β -blockers which can produce false positive results [52]. The same is observed in cerebral and TAAA surgeries in

which IONM may predict risk of postoperative motor dysfunction [7,52].

According to Malcharek et al. in general, IONM did not increase surgery duration, although period of clamping was prolonged in MEP group. Thereafter, postoperative motor dysfunction presented whenever interval between loss of transcranial MEP signal and intervention enlarged. Nevertheless, transcranial MEP isolated declines may be caused by small vessel disease, such as lacunae ischemia along with internal carotid artery stenosis [39,40].

Another condition with high morbidity and mortality is vasospasm, which follows aneurysm rupture. As motor cortex is more vulnerable to ischemia, it is expected that vasospasm of medial cerebral artery will increase MEP threshold of the contralateral upper extremity muscles, whereas the anterior cerebral artery is on lower limbs. Likewise, vasospasm of vertebral or basilar arteries may produce similar alterations due to vascular architecture. In fact, transcranial Doppler, as a bedside inexpensive and noninvasive method may be a great approach. Nevertheless, MEP recordings revealed to be an ideal method regarding its high diagnostic accuracy, reproducibility and information is obtained in time to provide proper treatment and prevent brain tissue necrosis. As a result, its special usefulness in ICU due to quick results and recording tolerability, although limited in diagnostic. Hence, it can contribute to a reduction in rate of cerebral ischemia following vasospasm [3,53].

In cases of descending and thoracic-abdominal aortic revascularization, paraplegia is a devastating iatrogenic consequence (22%) and MEP monitoring are useful in predicting SCI through non-recovery of recordings. As such, some strategies evolved to reduce rates towards MEP monitoring changes, for example, CSF drainage, hypothermia, distal aortic perfusion and intercostal artery re-implantation, for selected cases. Yet, there are many intraoperative protocols and a general evidence-based consensus is needed. Although most MEP signals are recovered, around 14% don't recover to baseline and are predicted to exhibit permanent postoperative motor deficit [10,23,29]. Moreover, the last strategy used may be re-implantation of intercostal arteries which besides its positive results may relate to prolonged surgery time, increased risk of bleeding and blood loss never minding the risk of paraplegia plus incidence of late pseudo aneurysm formation. Other strategies have few but strong evidence, such as CSF drainage and cardiopulmonary bypass, in selected cases based on SSEP recordings [29,35].

According to Griep et al. paraplegia rates achieved 2% with refining of collateral network; still, long-term adequacy may be obsolete due to hemodynamic conditions [54].

Even though SSEP permanent changes increase risk of immediate deficit, MEP introduces more sensitivity to SC ischemia detection and reduces Intercostal artery re-implantation rates in initial context. Additionally, MEP demonstrates a greater correlation with outcome than SSEP, due to specificity for anterior horn grey matter [35].

As stated by Phillips et al. SSEP monitoring in neurovascular procedures is more consistent in unruptured rather than ruptured aneurysms. Some authors attribute SSEP positive predictive value deterioration to edematous cerebral matter. Interestingly, Wicks et al. pointed that irreversible changes in unruptured ones had 80% stroke rate, while similar changes in ruptured may develop without stroke in 58% [28,36].

Still, IONM is limited by insufficient data about potential problems and possible successful solutions as its accuracy measurement challenged by surgical procedure's adjustment, generating false positives [28,55,56]. Nevertheless, unrecovered SSEP had 97% chance of an ischemic perioperative insult; likely caused by hypoperfusion, thromboemboli, shunt malformation or inadequate BP control. Hence, SSEP may assess collateral network, shunt requirements and correlates with neurological outcome [36,38,39].

Interestingly, in Lancet's randomized study related to aneurysm procedure, no significant differences in outcome were found when comparing carotid endarterectomy under general and local anesthesia with IONM. Indeed, MEP is useful for anterior and posterior circulation approaches. Lastly, real time monitoring is a valuable tool to guide surgical and anesthesia management. In fact, IONM have great sensitivity for postoperative neurological deficit, plus emboli and hyperperfusion syndrome when monitoring from surgery to postoperative period [41,57].

Vocal cords monitoring and cervical procedures

Currently, incidence of recurrent laryngeal nerve (RLN) injury after a neck surgery is between 2.3% to 5.2% [2,7]. In fact, success in preventing RLN injury and utility of IONM during esophagectomy made it a standard method [2,7].

According to Chiang et al. the RLN anatomical variations can be a potential cause of nerve injury because of visual misidentification. Thus, RLN palsy occurs in 1 to 2 % and temporarily in 5 to 6% with IONM, although a facilitated recognition of the anatomical variety led to a decline in nerve injury, particularly in cases of re-intervention and surgical malignant disease [42,58].

As follows, Alesina et al. (N=250) presented higher percentage of RLN palsy when assisted by IONM, which was contradictory to results obtained in similar studies, Barczynski et al. (N=151), Frattini et al. (N=152), Zheng et al. (N=36487) and Caló et al. (N=2034). Effectively, majority demonstrated significantly lower RLN morbidity when assisted by IONM, partial or transient palsy but less difference in permanent injury. Nevertheless, it improved thyroid surgery outcome with excellent specificity and negative predictive value [42,59-62].

Once dissected, RLN loss of signal had 90% chance of intraoperative recovery. So that, unchanged positive signal is highly predictive of intact nerve function. According to Genter et al. IONM of RLN with electromyography provides real time information regarding its integrity and may predict immediate postoperative vocal fold palsy reliably when accepted a cutoff of 200 μ V. Mainly, it provides vital information when manipulated bilaterally because of airway complication, which may require tracheostomy or re-intubation. In fact, real time data are important for surgical guidance and planning, particularly for bilateral thyroid surgery. Meanwhile, once electromyography is abnormal, IONM predictive value is limited. [43,62].

Furthermore, routine laryngeal exam is needed to avoid underestimation of incidence of temporary or permanent vocal fold palsy later. Nevertheless, isolated symptomatic voice assessment is insufficient to avoid this condition and may be limited by intraoperative situations. Currently, direct visualization results in a lower rate of recurrent laryngeal nerve injury in comparison to neural avoidance alone. Meanwhile, there are inconsistent findings when comparing methods [43].

Regarding posterior cervical surgery, Lee et al. evaluated multimodality IONM efficacy shown limited detection and prevention of delayed onset of cervical C5 palsy, mainly iatrogenic injury, which may also simulate false positive result and appear in 1.2% of posterior decompression surgery. Plus, detection rate may increase with electromyography and transcranial MEP combination, nevertheless, IONM alteration is not influenced by comorbidity and age although these may not correlate with outcome [5].

Cerebral surgery

Effectively, IONM may detect cortical and superficial subcortical ischemia; nevertheless, direct cerebral stimulation has focal activation and achieves ischemia detection without instigating involuntary movements which interfere with micro-dissection as transcranial electrical stimulation MEP [7,26].

Nevertheless, these modalities may cause subdural bleeding and brain injury plus both are vulnerable to anesthesia protocol and variability may be reduced using close to motor threshold stimulation and focal one-electrode montages.

For instance, a reproducible decrease of more than 50% and latency increase above 10% plus recording disappearance for more than 10 min is likely to be followed by postoperative motor deficit. [20,26,48].

Similarly, MEP may also be more sensitive than SSEP detecting brainstem ischemia caused by perforating artery occlusion. However, MEP recordings should not replace SSEP monitoring during aneurysm surgery [20,26,63].

Recently, it has been demonstrated that cerebral metastases infiltrate surrounding brain tissue, so that, IONM minimizes postoperative motor deficit and increases resection area, although correlation to MEP deterioration pattern is yet to be found. Additionally, 21% exhibited postoperative neurological improvement depending on tumor location [64].

In fact, residual tumor occurred in 29% of cases with MEP reduction, suggesting an association; likewise, secondary hemorrhage or ischemia may explain false negative results in IONM. On this regard, one should include all evoked potentials in multimodality IONM during selected surgeries, such as transphenoidal surgery, aneurysm clipping of posterior circulation and removal of tumors that lie near the optical radiation [64].

Regarding visual evoked potentials, useful vision pathways integrity may not be expressed unless electroretinography and monochromatic stimulator are combined. Furthermore, anesthesia protocols may exclude volatile general anesthesia and specialists must notice that new major vision field alteration may pass undetected. Finally, real time monitoring is impractical due to time required to obtain each waveform, plus minimum visual function must be defined and its changes take 32 S to measure. Then turns out to be impossible to correlate injuries and causative events or timely prevent it [6,7,31,65,66].

Cerebral arteriovenous malformation

Ichikawa et al. stated MEP recordings plus mapping facilitate detection of BFI and direct injury towards corticospinal tract. In several arterial venous malformation surgeries, MEP potentiated feeding arteries location and replaced the previous invasive standard method, intraoperative fluorescence angiography. For instance, MEP

change within 1 min of BFI in perforators (i.e. anterior choroidal artery, lenticulostriate arteries), also changing with excessive pressure and tratrography may fail to localize corticospinal tract lesions because of brain shift due to CSF drainage [13,26].

Regarding MEP alterations, surgery should be stopped, and corticospinal tract released from pressure in order to preserve motor function. Forward, for anterior circulation aneurysms SSEP and EEG are often used and monitorization of posterior circulation abnormalities and brainstem auditory evoked potential are added. Moreover, transcranial MEP are added whenever internal capsule or subcortical tracts and large-sized aneurysm are involved. Nevertheless, postsurgical period may be monitored by SSEP since they are less affected by anesthesia protocols and muscle relaxants [20,33,35].

According to Lepski et al. MEP reduction of less than 15% from baseline was related to good recovery of motor function, meanwhile, disappearance correlates with long term impairment [67].

Effectively, perioperative risk may be significantly reduced if surgical strategy is defined while taking into account anatomic functional mapping of motor cortex and descending pathways [67].

In reality, expectant treatment of arterial venous malformations is related to hemorrhagic risk (1% to 4%) and may increase during the first year after a hemorrhagic event. Hereafter, 16% were moderate to severely disable after this event which outrange treatment related morbidity. Whenever previous neurologic disability is present, IONM is ineffective due to drastic reorganization of cortical representation [67].

In this context, MEP assessment reduced surgical time not being limited by general anesthesia or surgery related cerebral edema and real time information makes it suitable for arterial venous malformation procedures with postoperative motor deficit risk [13,26].

Spinal cord surgery

Currently, both MEP and SSEP are used in spine surgery integrity in order to increase sensitivity. For instance, motor and sensory pathways are anatomically distinct and have different vascular supply in cortical areas, brainstem and SC [1,19,26].

Furthermore, early detection encourages surgical team to perform a quick intervention and prevent injury progression or to reverse impending neurological sequel [1,24].

Thereafter, loss of monitoring signal may occur in various occasions, such as, during correction (57%) or placement of the instruments (26%), mispositioning of instruments and few led to neurological injury (1.4%). Raynor et al. also attributed recordings' changes to systemic factors. Interestingly, IONM changes were more common in revision surgeries than in primary [1,40,68-71].

As stated by Koht et al. risk of paralysis during scoliosis correction is reduced using MEP monitoring whereas SSEP would occasionally fail to detect motor pathways lesion. As expected, transcranial MEP monitoring is believed to improve outcome and reduce risk in a wide variety of axial skeletal deformity surgeries. Therefore, muscle response of the transcranial MEP is more sensitive to corticospinal tract ischemia because it implicates synapses in the spinal grey matter and its vascular supply. By contrast, white matter can be monitored by SSEP as well as corticospinal tract by D-waves, though with lower sensitivity [12,20].

Indeed, sudden drop in SSEP and MEP recordings at lower limbs following deformity correction have reversal correction and implant removal as effective strategies to recover. Then, false positive and false negative may be reduced by multimodal approach [1,5,47].

Whenever SSEP deteriorate successful resuscitative maneuvers like reversal of hypotension, positioning adjustment, distraction release, cessation of manipulation and/or grafts removal and duroplasty may be attempted [1,4].

Interestingly, isolated motor changes may result from mechanical, vascular injuries or hypotensive anesthesia. Actually, result from SC hypoperfusion may be due to a mechanical stress without BP alteration [1].

In truth, pathological IONM findings correlate with worse long-term outcome as detected with Oswestry Disability index score. Further, rate of gross total resection was higher when used IONM. In fact, electromyography may complement anatomical location of nerve roots as well as recognize irritation or traction features [17].

Although controversial, some factors may negatively affect the prognosis, such as, tumor volume, ventral localization and association with peritumoral edema, even though relation with outcome was not found. Additionally, partial removal procedures' outcome could not be evaluated [45].

Also, disappearance criterion may not be sensitive enough to detect partial SCI that leads to postoperative motor deficit, but it is still the best predictor for long term prognosis regarding its specificity [70].

Effectively, IONM is considered to be a valuable tool to predict risk of adverse outcomes, such as, paraparesis, paraplegia and quadriplegia. Moreover, its predictive value enables guidance over intraoperative decision-making and subsequent measures to be taken. Several studies have shown that IONM allows postoperative prognosis and preoperative deficits recovery recognition. Nevertheless, preoperative motor weakness or neuromuscular scoliosis decrease MEP recording value, still, Wang et al. concluded MEP monitoring is feasible for most high risk diagnosis and complicated surgical procedures with sudden loss meaning postoperative neurological deficit. Nevertheless, patients with preoperative deficit may present neuromonitoring signal drop with normal spinal function, so that, stays as an important question if monitoring loss is a strong predictor of PND [14,21,23,50,68,71,72].

Limitations

Even though the strongest evidence is earned by controlled randomized studies, several ethical and methodical concerns are responsible for the lack of these trials. Indeed, IONM techniques known value is highly limitative and subsequently many studies were abandoned since no IONM meant more frequent PND. Therefore, most studies are observational and lack of evidence quality, in addition, demographic factors and vascular risk facts differences may introduce some bias [3,20,39,49].

Also, lack of standardized protocols is a constant limitation, which jeopardizes comparison between studies since the procedure and warning criterion may vary between centers [43].

In addition, Sala et al. enhanced that only after 3 months of follow up, significant difference in neurologic status between procedures with or without IONM could be observed. This could be explained by neurologic deterioration pattern. Indeed, a greater recovery is seen in presence of transient or minor change in waveforms [14,46].

Some valid studies lack to demonstrate which strategies followed an alert signal. Despite recovery success, there is no consensus in progress. So that, clinical utility of IONM remains difficult to attend [29,50].

Furthermore, the monitoring team has to be multidisciplinary, trained and experienced in neurophysiology, plus its clinical aspects, and EP application knowledge. Essential artifact discriminations, clinical significance and wellness of surgical patients must be achieved [10].

Conclusion

Effectively, intraoperative EP has a role as an adjuvant tool to several types of procedures. In fact, risk-benefit studies recommend its use in certain surgeries with known risk of PND.

Furthermore, the current trend shows that procedures are becoming more accurate and integrity of neurologic pathways is being monitored in real time, as a result, outcomes tend to be better and, sometimes, predictable. In fact, it enables specialists to prevent PND and facilitates real time decision-making. Also, there is crescent evidence related to recordings' recovery and successful discharge status.

In order to potentiate multicentric studies comparison there is a need for standardized protocols, with defined warnings threshold and properly defined concepts, plus a specialized team with adequate communication to accurately detect events and react effectively.

Moreover, the wake up test has important limitations and further evolution in IONM devices will overcome its restrictions.

Nowadays, IONM devices function in multimodality mode and are not only assessable solutions for spine, neurologic and vascular procedures, but also allow customized settings and direct access to any parameter whenever necessary during surgery.

Key-Highlights

IONM evidence-based recommendations and relevant features

- Proven effectivity in neurosurgery tumor or epileptic focus resection near motor cortex or corticospinal tract, intracranial aneurysm clipping, posterior fossa surgery, cranial-cervical junction, spinal cord procedures and cauda equina approach.
- In orthopedics a valuable tool in spinal deformity correction surgery, fracture, vertebral tumor resection and anterior cervical discectomy.
- Meanwhile, in vascular has indication in descending aorta procedures, arterial venous malformation in spinal cord and carotid endarterectomy [19].
- Costs are less than direct ones from care related to acquired deficits in experienced teams with the best outcomes[3].
- Spinal deformity surgery is the leading indication and its absence in thoracic and thoracolumbar spinal deformity surgeries reduces patient's good outcome [24].
- Finally, a preoperative checklist may include anesthesia protocol, warning criteria for postoperative neurological deficit, plus, reversal maneuvers on response to a positive alarm [1].

Anesthesia effect

- Anesthesia protocols are required to avoid interference with MIOM recordings.
- Total intravenous anesthesia is recommended with propofol and opioids combination.
- Halogenated inhalation agents, high dosage and muscle relaxants may decrease recordings register.
- Ketamine seems to increase amplitude of evoked potentials [73,74].

Enables early preventive maneuvers

- In spinal surgery enhances the assessment of neural integrity and guides surgeon through the procedure by predicting neurological outcomes, enabling the relevant preventive measures to be taken [4,50].
- Majority of SSEP changes can be reversed resulting in no permanent deficit in spinal surgery context [68].
- The lesion level guides corrective maneuvers in deformity correction surgery in order to improve neurological outcome [24].
- After transcranial MEP application, motor deficits were avoided in 12 of 98 patients by institution of adequate corrective maneuvers in response to these alerts [75].

Limitations IONM recordings

- MEP has less value if preoperative motor weakness or neuromuscular scoliosis is present [14,21].
- Requires more restrictive anesthesia protocols, may cause patients' movements and has less clear established alarm criteria [22].
- Has an imperfect correlation to early postoperative motor function [18].
- High rate of false positive alarm and may lead to premature and unnecessary interruption in the surgery so that it was proposed a decrease in limit to peak-to-peak amplitude decrease to 80% to MEP monitoring [76].
- MEP monitoring are criticized because of the high intertrial variability of muscle MEP amplitude, sensitivity to insult of spinal cord is quite high, and the incidence of false positive results will increase if judgment is based purely on this potentials.
- SSEP monitoring may be affected by fluctuation of systemic factors like core temperature, hemodynamic aspects or, even an increased signal due to neuromuscular blocking agents at the intubation moment.
- False negative are hard to evaluate since surgeons alter their conduct in concordance to MEP waveform alteration [64].
- Potential injuries could include brain damage, seizures, kindling, epidural complications and accidental injuries caused by bite injuries, adverse cognitive or affective sequelae and others like cardiac arrhythmia, intraoperative awareness, scalp burns, pain or headache, and disturbances of hormonal or hematological hemostasis [3,19].
- SSEP gives an average signal for the dorsal column and, as a result warning alert is delayed and injury may become permanent before any changes in SSEP [3].

IONM as an alternative to wake up test

- Some patients may not be capable to cooperate with the wake up test due to age, language barriers or mental status [1].

- Awaken a patient requires a prolonged pause in the surgery and progressive reduction of the pharmacological load with consequent rise in blood pressure; interestingly this maneuver may improve spinal cord function [1].
- MEP has the ability to detect changes in motor strip and tract but not the premotor strip and tract in opposition to neurological examination. So that, it should be done together in order to increase both sensitivity and specificity of intraoperative monitoring awake examination.
- Still, is used in procedures like tumor resection, epilepsy surgery, deep brain stimulation and CEA.
- Wake up test is not effective to detect subtle weakness, timing or location of injury especially in patients that still partially sedated and unable to follow commands because intellectual or development disabilities or preoperative weakness too. May happen self-extubation, loss of intravenous access, loss of positioning, air embolus and/or event recollection [10].
- Given time for patients to awake from general anesthesia may be insufficient for an accurate examination leading to anesthesia-induced hemiparesis [76,77].

Transcranial Motor Evoked Potentials (tcMEP) deterioration

- High rate of false positive alarm may lead to premature and unnecessary interruption in the surgery and prognosis prediction becomes harder [75].
- Patients with alarm criteria on tcMEP showed postoperative deficit for a month, otherwise, in cases of 50 to 80% attenuation of waveform in tcMEP gradually recovered 1 month later [51].

Multimodality IONM group

- More high cervical lesions than control group have been shown. These have more complex neural and vascular integrity than lower cervical lesions, so multimodality IONM should be thought.
- False positive results may come from electrocautery irritation or muscle tightness from prolonged prone positioning with skull fixation.
- If recovery of trapezius electromyography changes during surgery were seen, there were not encountered postoperative neurological deficits.
- Multimodality IONM may play a restrictive role in preventing delayed onset C5 palsy in lower cervical regions so far (only in C1-C2 joint seems to have a drop and recovery when maneuvered).
- Multimodality IONM may have limited value in routine, non-traumatic or non-severe deformity cases based on great results without IONM [5].

Congruent MEP deterioration do not necessarily imply ischemia

- Antagonist α_2 adrenergic or antihypertensive drugs can reduce MEP by elevating motor neuron excitability.
- Magnesium sulfate reduces blood pressure so may reduce MEP; in addition may potentiate neuromuscular blockage.
- Low temperatures raise latencies and higher reduce it. In a deep hypothermia muscle MEP are obliterated.
- Severe electrolyte abnormalities, hypoxemia, hypercapnia, hypocapnia or anemia can produce MEP deterioration [19].

Relative contraindications for MEP

- Epilepsy, cortical lesions, skull defects, intracranial vascular clips, shunts or electrodes.
- Pacemakers or other implanted bioelectric device, yet there is no evidence of increasing transcranial electric stimulation complications [19]. Evidence-based recommendations (Tables 1-3).

Recommendation	Evidence Level
Qualified personnel should acquire and interpret intraoperative MEP	Class III, type C
Intraoperative MEP techniques are considered safe once handled by trained personnel, plus taken precautions	Class II and III, type B
MEP as an option for localizing motor cortex, proximity to corticospinal tract fibers and motor pathways monitoring during risk related surgeries.	Class II and III, type B
Total intravenous anesthesia usually based on propofol and opioid infusion is optimal for muscle MEP monitoring. Benzodiazepines, ketamine and etomidate may be suitable intravenous alternatives.	Class II and III, type B
Interpretation should consider limitations and confounding factors (Monitoring should include tracing of anesthetic dosages and physiological parameters, and rostral or contralateral control MEP when possible)	Class III, type C
Warning criteria for D-waves are based on amplitude reduction having no apparent confounding factor explanation (intramedullary spinal cord tumor surgery with more da 505% baseline; Brain surgery with DCS cervical D-waves with more than 30-40% reduction; Orthopedic spine and other surgeries: No established criterion)	Class III
Spinal cord procedures: disappearance is always a major criterion	Class II and III, type B
Intramedullary spinal cord tumor surgery marked amplitude reduction, acute threshold elevation could be additional moderate criteria	Class II and III, type B
Descending aortic surgery: marked amplitude reduction or acute threshold elevation could be additional moderate criteria	Class II and III, type B
Brain and brainstem: major criteria include disappearance or more than 50% amplitude reduction if recordings are stable, or amplitude reduction clearly exceeding variability when responses are less stable and an acute threshold elevation might be relevant	Class III, type C
Facial nerve: major criteria include disappearance or consistent more than 50% amplitude reduction in stable recordings	Class III, type C
Nerve roots: no established criterion	Class III, type U

Table 1: Evidence based recommendations.

Quality of evidence [19]	
	Class I: one or more well-designed, prospective, blinded, controlled studies;
	Class II: one or more well-designed, clinical studies such as case control, cohort studies
	Class III: expert opinion, non-randomized historical controls or case reports

Table 2: Quality of evidence.

Strength of recommendation [19]	
	Type A: strong positive recommendation based on Class I, or overwhelming Class II evidence
	Type B: Positive recommendation based on Class II evidence
	Type C: Positive recommendation based on strong consensus Class III evidence
	Type D: Negative recommendation based on inconclusive or conflicting Class II evidence
	Type E: Negative recommendation based on evidence of ineffectiveness
	Type U: No recommendation, based on divided expert opinion or insufficient data

Table 3: Strength of recommendation.

References

1. Pastorelli F, Di Silvestre M, Plasmati R, Michelucci R, Greggi T, et al. (2011) The prevention of neural complications in the surgical treatment of scoliosis: the role of the neurophysiological intraoperative monitoring. *Eur Spine J* 20: 105-114.
2. Jameson LC, Sloan TB (2012) Neurophysiologic monitoring in neurosurgery. *Anesthesiol Clin* 30: 311-331.
3. Moller AR, Ansari S, Cohen-Gadol AA (2011) Techniques of intraoperative monitoring for spinal cord function: their past, present, and future directions. *Neurol Res* 33: 363-370.
4. Park P, Wang AC, Sangala JR, Kim SM, Hervey-Jumper S, et al. (2011) Impact of multimodal intraoperative monitoring during correction of symptomatic cervical or cervicothoracic kyphosis. *J Neurosurg Spine* 14: 99-105.
5. Lee HJ, Kim IS, Sung JH, Lee SW, Hong JT (2016) Significance of multimodal intraoperative monitoring for the posterior cervical spine surgery. *Clin Neurol Neurosurg* 143: 9-14.
6. Luo Y, Regli L, Bozinov O, Sarnthein J (2015) Clinical utility and limitations of intraoperative monitoring of visual evoked potentials. *PLoS One* 10: e0120525.
7. Kim SM, Kim SH, Seo DW, Lee KW (2013) Intraoperative neurophysiologic monitoring: basic principles and recent update. *J Korean Med Sci* 28: 1261-1269.
8. Koht A, Sloan TB (2016) Intraoperative Monitoring. *Anesthesiology Clin* 34: 525-535.
9. Galloway GM (2010) Intraoperative neurophysiologic monitoring. Cambridge; New York: Cambridge University Press; pp:241.
10. Samdani AF, Bennett JT, Ames RJ, Asghar JK, Orlando G, et al. (2016) Reversible Intraoperative Neurophysiologic Monitoring Alerts in Patients Undergoing Arthrodesis for Adolescent Idiopathic Scoliosis: What Are the Outcomes of Surgery? *J Bone Joint Surg Am* 98: 1478-1483.
11. Feng B, Qiu G, Shen J, Zhang J, Tian Y, et al. (2012) Impact of multimodal intraoperative monitoring during surgery for spine deformity and potential risk factors for neurological monitoring changes. *J Spinal Disord Tech* 25: E108-E114.
12. Koht A, Sloan TB (2016) Intraoperative Monitoring: Recent Advances in Motor Evoked Potentials. *Anesthesiol Clin* 34: 525-535.
13. Ichikawa T, Suzuki K, Sasaki T, Matsumoto M, Sakuma J, et al. (2010) Utility and the limit of motor evoked potential monitoring for preventing complications in surgery for cerebral arteriovenous malformation. *Neurosurgery* 67: 222-228.
14. MacDonald DB (2017) Overview on Criteria for MEP Monitoring. *J Clin Neurophysiol* 34: 4-11.
15. Lall RR, Lall RR, Hauptman JS, Munoz C, Cybulski GR, et al. (2012) Intraoperative neurophysiological monitoring in spine surgery:

- indications, efficacy, and role of the preoperative checklist. *Neurosurg Focus* 33: E10.
16. Taskiran E, Brandmeier S, Erdinc O, Ramazan S, Bolukbasi F, et al. (2017) Multimodal Intraoperative Neurophysiological Monitoring in Spinal Cord Surgery. *Turk Neurosurg* 27: 439-440.
 17. Nuwer MR, Emerson RG, Galloway G, Legatt AD, Lopez J, et al. (2012) Evidence-based guideline update: Intraoperative spinal monitoring with somatosensory and transcranial electrical motor evoked potentials Report of the Therapeutics and Technology Assessment Subcommittee of the American Academy of Neurology and the American Clinical Neurophysiology Society. *Neurology* 78: 585-589.
 18. Singh H, Vogel RW, Lober RM, Doan AT, Matsumoto CI, et al. (2016) Intraoperative Neurophysiological Monitoring for Endoscopic Endonasal Approaches to the Skull Base: A Technical Guide. *Scientifica* 2016: 1751245.s
 19. Macdonald DB, Skinner S, Shils J, Yingling C (2013) Intraoperative motor evoked potential monitoring—a position statement by the American Society of Neurophysiological Monitoring. *Clin Neurophysiol* 124: 2291-2316.
 20. Sahaya K, Pandey AS, Thompson BG, Bush BR, Minecan DN (2014) Intraoperative monitoring for intracranial aneurysms: the Michigan experience. *J Clin Neurophysiol* 31: 563-567.
 21. Zhuang Q, Wang S, Zhang J, Zhao H, Wang Y, et al. (2014) How to make the best use of intraoperative motor evoked potential monitoring? Experience in 1162 consecutive spinal deformity surgical procedures. *Spine* 39: E1425-E1432.
 22. Bhagat S, Durst A, Grover H, Blake J, Lutchman L, et al. (2015) An evaluation of multimodal spinal cord monitoring in scoliosis surgery: a single centre experience of 354 operations. *Eur Spine J* 24: 1399-1407.
 23. Fehlings MG, Brodke DS, Norvell DC, Dettori JR (2010) The evidence for intraoperative neurophysiological monitoring in spine surgery: does it make a difference? *Spine* 35: S37-S46.
 24. Gavaret M, Pesenti S, Diop-Sene M, Choufani E, Bollini G, et al. (2017) Intraoperative spinal cord monitoring: Lesional level diagnosis. *Orthop Traumatol Surg Res* 103: 33-38.
 25. Hiratzka LF, Bakris GL, Beckman JA, Bersin RM, Carr VF, et al. (2010) ACCF/AHA/AATS/ACR/ASA/SCA/SCAI/SIR/STS/SVM guidelines for the diagnosis and management of patients with thoracic aortic disease. *J Am Coll Cardiol* 55: e27-e129.
 26. Guo L, Gelb AW (2011) The use of motor evoked potential monitoring during cerebral aneurysm surgery to predict pure motor deficits due to subcortical ischemia. *Clin Neurophysiol* 122: 648-655.
 27. Rozet I, Metzner J, Brown M, Treggiari MM, Slimp JC, et al. (2015) Dexmedetomidine Does Not Affect Evoked Potentials During Spine Surgery. *Anesth Analg* 121: 492-501.
 28. Wicks RT, Pradilla G, Raza SM, Hadelsberg U, Coon AL, et al. (2012) Impact of changes in intraoperative somatosensory evoked potentials on stroke rates after clipping of intracranial aneurysms. *Neurosurgery* 70: 1114-1124.
 29. Fok M, Jafarzadeh F, Sancho E, Abello D, Rimmer L, et al. (2015) Is There Any Benefit of Neuromonitoring During Descending and Thoracoabdominal Aortic Aneurysm Repair? *Innovations (Phila)* 10: 342-348.
 30. Legatt AD, Emerson RG, Epstein CM, MacDonald DB, Deletis V, et al. (2016) ACNS Guideline: Transcranial Electrical Stimulation Motor Evoked Potential Monitoring. *J Clin Neurophysiol* 33: 42-50.
 31. Hayashi H, Kawaguchi M (2015) Intraoperative Visual Evoked Potential Monitoring. *Masui* 64: 508-514.
 32. Bharadwaj S, Venkatraghavan L (2016) Intraoperative Phase Reversal Monitoring Using a Novel Technique. *J Neurosurg Anesthesiol* 28: 82.
 33. Estrera AL, Sheinbaum R, Miller CC, Harrison R, Safi HJ (2010) Neuromonitor-guided repair of thoracoabdominal aortic aneurysms. *J Thorac Cardiovasc Surg* 140: S131-S135.
 34. Coselli JS, Bozinovski J, LeMaire SA (2007) Open surgical repair of 2286 thoracoabdominal aortic aneurysms. *Ann Thorac Surg* 83: S862-S864.
 35. Pillai JB, Pellet Y, Panagopoulos G, Sadek MA, Abjigitova D, et al. (2013) Somatosensory-evoked potential-guided intercostal artery reimplantation in thoracoabdominal aortic aneurysm surgery. *Innovations (Phila)* 8: 302-306.
 36. Phillips JL, Chalouhi N, Jabbour P, Starke RM, Bovenzi CD, et al. (2014) Somatosensory evoked potential changes in neuroendovascular procedures: incidence and association with clinical outcome in 873 patients. *Neurosurgery* 75: 560-567.
 37. Li F, Gorji R (2017) Spine Surgery and Intraoperative Monitoring. *Anesthesiology* 121-131.
 38. Nwachuku EL, Balzer JR, Yabes JG, Habeych ME, Crammond DJ, et al. (2015) Diagnostic value of somatosensory evoked potential changes during carotid endarterectomy: A systematic review and meta-analysis. *JAMA Neurol* 72: 73-80.
 39. Malcharek MJ, Herbst V, Bartz GJ, Manceur AM, Gille J, et al. (2015) Multimodal evoked potential monitoring in asleep patients versus neurological evaluation in awake patients during carotid endarterectomy: a single-centre retrospective trial of 651 patients. *Minerva Anestesiol* 81: 1070-1078.
 40. Malcharek MJ, Ulkatan S, Marino V, Geyer M, Llado-Carbo E, et al. (2013) Intraoperative monitoring of carotid endarterectomy by transcranial motor evoked potential: a multicenter study of 600 patients. *Clin Neurophysiol* 124: 1025-1030.
 41. Malcharek MJ, Kulpok A, Deletis V, Ulkatan S, Sablotzki A, et al. (2015) Intraoperative multimodal evoked potential monitoring during carotid endarterectomy: a retrospective study of 264 patients. *Anesth Analg* 120: 1352-1360.
 42. Chiang FY, Lu IC, Chen HC, Chen HY, Tsai CJ, et al. (2010) Intraoperative neuromonitoring for early localization and identification of recurrent laryngeal nerve during thyroid surgery. *The Kaohsiung J Medical Sci* 26: 633-639.
 43. Genter DJ, Kandil EH, Noureldine SI, Tufano RP (2014) Correlation of final evoked potential amplitudes on intraoperative electromyography of the recurrent laryngeal nerve with immediate postoperative vocal fold function after thyroid and parathyroid surgery. *JAMA Otolaryngology Head Neck Surg* 140: 124-128.
 44. Kamel I, Zhao H, Koch SA, Brister N, Barnette RE (2016) The Use of Somatosensory Evoked Potentials to Determine the Relationship Between Intraoperative Arterial Blood Pressure and Intraoperative Upper Extremity Position-Related Neurapraxia in the Prone Surrender Position During Spine Surgery: A Retrospective Analysis. *Anesth Analg* 122: 1423-1433.
 45. Siller S, Szelényi A, Herlitz L, Tonn JC, Zausinger S (2017) Spinal cord hemangioblastomas: significance of intraoperative neurophysiological monitoring for resection and long-term outcome. *J Neurosurgery Spine* 26: 483-493.
 46. Forster MT, Marquardt G, Seifert V, Szelényi A (2012) Spinal cord tumor surgery-importance of continuous intraoperative neurophysiological monitoring after tumor resection. *Spine* 37: E1001-E1008.
 47. Chen X, Sterio D, Ming X, Para DD, Butusova M, et al. (2007) Success rate of motor evoked potentials for intraoperative neurophysiologic monitoring: effects of age, lesion location, and preoperative neurologic deficits. *J Clin Neurophysiol* 24: 281-285.
 48. Seidel K, Beck J, Stieglitz L, Schucht P, Raabe A (2013) The warning-sign hierarchy between quantitative subcortical motor mapping and continuous motor evoked potential monitoring during resection of supratentorial brain tumors. *J Neurosurg* 118: 287-296.
 49. Langeloo DD, Journée HL, De Kleuver M, Grotenhuis J (2007) Criteria for transcranial electrical motor evoked potential monitoring during spinal deformity surgery: a review and discussion of the literature. *Neurophysiol Clin* 37: 431-439.
 50. Rho Y, Rhim S, Kang J (2016) Is intraoperative neurophysiological monitoring valuable predicting postoperative neurological recovery? *Spinal cord* 54: 1121-1126.
 51. Hokari M, Ito Y, Yamazaki K, Chiba Y, Isobe M, et al. (2016) The Relationship between Carotid Stump Pressure and Changes in Motor-

- Evoked Potentials in Carotid Endarterectomy Patients. *J Neurol Surg A Cent Eur Neurosurg* 77: 291-296.
52. Sridharan ND, Thirumala P, Chaer R, Balzer J, Long B, et al. (2017) Predictors of cross-clamp-induced intraoperative monitoring changes during carotid endarterectomy using both electroencephalography and somatosensory evoked potentials. *J Vasc Surg* 67: 191-198.
53. Grossauer S, Koeck K, Kraschl J, Olipitz O, Hausegger KA, et al. (2016) Detection of Cerebral Vasospasm Following Aneurysmal Subarachnoid Hemorrhage Using Motor Evoked Potentials. *Neurosurgery* 78: 265-273.
54. Etz CD, Di Luozzo G, Zoli S, Lazala R, Plestis KA, et al. (2009) Direct spinal cord perfusion pressure monitoring in extensive distal aortic aneurysm repair. *Ann Thorac Surg* 87: 1764-1773.
55. ter Wolbeek C, Hartert M, Conzelmann L, Peivandi A, Czerny M, et al. (2010) Value and pitfalls of neurophysiological monitoring in thoracic and thoracoabdominal aortic replacement and endovascular repair. *Thorac Cardiovasc Surg* 58: 260-264.
56. McGarvey ML (2012) Effective tool or necessary evil: intraoperative monitoring during thoracic aneurysm repairs. *J Clin Neurophysiol* 29: 154-156.
57. Group GTC (2009) General Anesthesia Versus Local Anesthesia for Carotid Surgery (GALA): A Multicentre Randomised Controlled Trial. *J Vasc Surg* 49: 1626.
58. Chiang FY, Lu IC, Chen HC, Chen HY, Tsai CJ, et al. (2010) Anatomical variations of recurrent laryngeal nerve during thyroid surgery: how to identify and handle the variations with intraoperative neuromonitoring. *Kaohsiung J Med Sci* 26: 575-583.
59. Barczyński M, Konturek A, Stopa M, Hubalewska-Dydejczyk A, Richter P, et al. (2011) Clinical value of intraoperative neuromonitoring of the recurrent laryngeal nerves in improving outcomes of surgery for well-differentiated thyroid cancer. *Pol Przegl Chir* 83: 196-203.
60. Frattini F, Mangano A, Boni L, Rausei S, Biondi A, et al. (2010) Intraoperative neuromonitoring for thyroid malignancy surgery: technical notes and results from a retrospective series. *Updates Surg* 62: 183-187.
61. Alesina PF, Rolfs T, Hommeltenberg S, Hinrichs J, Meier B, et al. (2012) Intraoperative neuromonitoring does not reduce the incidence of recurrent laryngeal nerve palsy in thyroid reoperations: results of a retrospective comparative analysis. *World J Surg* 36: 1348-1353.
62. Dequanter D, Charara F, Shahla M, Lothaire P (2015) Usefulness of neuromonitoring in thyroid surgery. *Eur Arch Otorhinolaryngol* 272: 3039-3043.
63. Irie T, Yoshitani K, Ohnishi Y, Shinzawa M, Miura N, et al. (2010) The efficacy of motor-evoked potentials on cerebral aneurysm surgery and new-onset postoperative motor deficits. *J Neurosurg Anesthesiol* 22: 247-251.
64. Krieg SM, Schäffner M, Shiban E, Droese D, Obermüller T, et al. (2013) Reliability of intraoperative neurophysiological monitoring using motor evoked potentials during resection of metastases in motor-eloquent brain regions. *J Neurosurg* 118: 1269-1278.
65. Subramanian SK, Gaur GS, Narayan SK (2013) Low luminance/eyes closed and monochromatic stimulations reduce variability of flash visual evoked potential latency. *Ann Indian Acad Neurol* 16: 614-618.
66. Kodama K, Goto T, Sato A, Sakai K, Tanaka Y, et al. (2010) Standard and limitation of intraoperative monitoring of the visual evoked potential. *Acta Neurochir (Wien)* 152: 643-648.
67. Lepski G, Honegger J, Liebsch M, Sória MG, Narischat P, et al. (2011) Safe resection of arteriovenous malformations in eloquent motor areas aided by functional imaging and intraoperative monitoring. *Neurosurgery* 70: 276-288.
68. Epstein NE (2013) The need to add motor evoked potential monitoring to somatosensory and electromyographic monitoring in cervical spine surgery. *Surg Neurol Int* 4: S383-S391.
69. Raynor BL, Bright JD, Lenke LG, Ra'Kerry KR, Bridwell KH, et al. (2013) Significant change or loss of intraoperative monitoring data: a 25-year experience in 12,375 spinal surgeries. *Spine* 38: E101-E108.
70. Kim DG, Choi YD, Jin SH, Kim CH, Lee KW, et al. (2017) Intraoperative Motor-Evoked Potential Disappearance versus Amplitude-Decrement Alarm Criteria During Cervical Spinal Surgery: A Long-Term Prognosis. *J Clin Neurol* 13: 38-46.
71. Shilian P, Zada G, Kim AC, Gonzalez AA (2016) Overview of Intraoperative Neurophysiological Monitoring During Spine Surgery. *J Clin Neurophysiol* 33: 333-339.
72. Wang S, Zhang J, Tian Y, Shen J, Zhao Y, et al. (2015) Intraoperative motor evoked potential monitoring to patients with preoperative spinal deficits: judging its feasibility and analyzing the significance of rapid signal loss. *Spine J* 17: 777-783.
73. Sloan TB, Toleikis JR, Toleikis SC, Koht A (2015) Intraoperative neurophysiological monitoring during spine surgery with total intravenous anesthesia or balanced anesthesia with 3% desflurane. *J Clin Monit Comput* 29: 77-85.
74. Polly DW, Rice K, Tamkus A (2016) What Is the Frequency of Intraoperative Alerts During Pediatric Spinal Deformity Surgery Using Current Neuromonitoring Methodology? A Retrospective Study of 218 Surgical Procedures. *Neurodiagn J* 56: 17-31.
75. Yeon JY, Seo DW, Hong SC, Kim JS (2010) Transcranial motor evoked potential monitoring during the surgical clipping of unruptured intracranial aneurysms. *J Neurol Sci* 293: 29-34.
76. Liu Q, Wang Q, Liu H, Wu WKK, Chan MTV (2017) Warning criteria for intraoperative neurophysiologic monitoring. *Curr Opin Anesthesiol* 30: 557-562.
77. Suzuki K, Mikami T, Sugino T, Wanibuchi M, Miyamoto S, et al. (2014) Discrepancy between voluntary movement and motor-evoked potentials in evaluation of motor function during clipping of anterior circulation aneurysms. *World neurosurgery* 82: e739- e745.

References

1. Pastorelli F, Di Silvestre M, Plasmati R, Michelucci R, Greggi T, Morigi A, et al. The prevention of neural complications in the surgical treatment of scoliosis: the role of the neurophysiological intraoperative monitoring. *European Spine Journal*. 2011;20(1):105-14.
2. Jameson LC, Sloan TB. Neurophysiologic monitoring in neurosurgery. *Anesthesiology clinics*. 2012;30(2):311-31.
3. Moller AR, Ansari S, Cohen-Gadol AA. Techniques of intraoperative monitoring for spinal cord function: their past, present, and future directions. *Neurological research*. 2011;33(4):363-70.
4. Park P, Wang AC, Sangala JR, Kim SM, Hervey-Jumper S, Than KD, et al. Impact of multimodal intraoperative monitoring during correction of symptomatic cervical or cervicothoracic kyphosis. *Journal of Neurosurgery: Spine*. 2011;14(1):99-105.
5. Lee HJ, Kim IS, Sung JH, Lee SW, Hong JT. Significance of multimodal intraoperative monitoring for the posterior cervical spine surgery. *Clinical neurology and neurosurgery*. 2016;143:9-14.
6. Luo Y, Regli L, Bozinov O, Sarnthein J. Clinical utility and limitations of intraoperative monitoring of visual evoked potentials. *PloS one*. 2015;10(3):e0120525.
7. Kim S-M, Kim SH, Seo D-W, Lee K-W. Intraoperative neurophysiologic monitoring: basic principles and recent update. *Journal of Korean medical science*. 2013;28(9):1261-9.
8. Koht A, Sloan TB. Intraoperative Monitoring. *Anesthesiology clinics*. 2016;34(3):525-35.
9. Galloway GM. Intraoperative neurophysiologic monitoring. Cambridge ; New York: Cambridge University Press; 2010. x, 241 p. p.
10. Samdani AF, Bennett JT, Ames RJ, Asghar JK, Orlando G, Pahys JM, et al. Reversible Intraoperative Neurophysiologic Monitoring Alerts in Patients Undergoing Arthrodesis for Adolescent Idiopathic Scoliosis: What Are the Outcomes of Surgery? *The Journal of bone and joint surgery American volume*. 2016;98(17):1478-83.
11. Feng B, Qiu G, Shen J, Zhang J, Tian Y, Li S, et al. Impact of multimodal intraoperative monitoring during surgery for spine deformity and potential risk factors for neurological monitoring changes. *Journal of spinal disorders & techniques*. 2012;25(4):E108-14.
12. Koht A, Sloan TB. Intraoperative Monitoring: Recent Advances in Motor Evoked Potentials. *Anesthesiology clinics*. 2016;34(3):525-35.
13. Ichikawa T, Suzuki K, Sasaki T, Matsumoto M, Sakuma J, Oinuma M, et al. Utility and the limit of motor evoked potential monitoring for preventing complications in surgery for cerebral arteriovenous malformation. *Neurosurgery*. 2010;67(3 Suppl Operative):ons222-8; discussion ons8.
14. MacDonald DB. Overview on criteria for MEP monitoring. *Journal of Clinical Neurophysiology*. 2017;34(1):4-11.
15. Lall RR, Hauptman JS, Munoz C, Cybulski GR, Koski T, et al. Intraoperative neurophysiological monitoring in spine surgery: indications, efficacy, and role of the preoperative checklist. *Neurosurgical focus*. 2012;33(5):E10.
16. Taskiran E, Brandmeier S, Erdinc O, Ramazan S, Bolukbasi F, Elmaci I. Multimodal Intraoperative Neurophysiological Monitoring in Spinal Cord Surgery. *Turkish neurosurgery*. 2017;27(3).
17. Nuwer MR, Emerson RG, Galloway G, Legatt AD, Lopez J, Minahan R, et al. Evidence-based guideline update: Intraoperative spinal monitoring with somatosensory and transcranial electrical motor evoked potentials Report of the Therapeutics and Technology Assessment Subcommittee of the American Academy of Neurology and the American Clinical Neurophysiology Society. *Neurology*. 2012;78(8):585-9.

18. Singh H, Vogel RW, Lober RM, Doan AT, Matsumoto CI, Kenning TJ, et al. Intraoperative Neurophysiological Monitoring for Endoscopic Endonasal Approaches to the Skull Base: A Technical Guide. Scientifica. 2016;2016.
19. Macdonald DB, Skinner S, Shils J, Yingling C. Intraoperative motor evoked potential monitoring - a position statement by the American Society of Neurophysiological Monitoring. Clin Neurophysiol. 2013;124(12):2291-316.
20. Sahaya K, Pandey AS, Thompson BG, Bush BR, Minecan DN. Intraoperative monitoring for intracranial aneurysms: the Michigan experience. Journal of Clinical Neurophysiology. 2014;31(6):563-7.
21. Zhuang Q, Wang S, Zhang J, Zhao H, Wang Y, Tian Y, et al. How to make the best use of intraoperative motor evoked potential monitoring? Experience in 1162 consecutive spinal deformity surgical procedures. Spine. 2014;39(24):E1425-E32.
22. Bhagat S, Durst A, Grover H, Blake J, Lutchman L, Rai A, et al. An evaluation of multimodal spinal cord monitoring in scoliosis surgery: a single centre experience of 354 operations. European Spine Journal. 2015;24(7):1399-407.
23. Fehlings MG, Brodke DS, Norvell DC, Dettori JR. The evidence for intraoperative neurophysiological monitoring in spine surgery: does it make a difference? Spine. 2010;35(9S):S37-S46.
24. Gavaret M, Pesenti S, Diop-Sene M, Choufani E, Bollini G, Jouve J-L. Intraoperative spinal cord monitoring: Lesional level diagnosis. Orthopaedics & Traumatology: Surgery & Research. 2017;103(1):33-8.
25. Hiratzka LF, Bakris GL, Beckman JA, Bersin RM, Carr VF, Casey DE, et al. 2010 ACCF/AHA/AATS/ACR/ASA/SCA/SCAI/SIR/STS/SVM guidelines for the diagnosis and management of patients with thoracic aortic disease. Journal of the American College of Cardiology. 2010;55(14):e27-e129.
26. Guo L, Gelb AW. The use of motor evoked potential monitoring during cerebral aneurysm surgery to predict pure motor deficits due to subcortical ischemia. Clinical Neurophysiology. 2011;122(4):648-55.
27. Rozet I, Metzner J, Brown M, Treggiari MM, Slimp JC, Kinney G, et al. Dexmedetomidine Does Not Affect Evoked Potentials During Spine Surgery. Anesthesia and analgesia. 2015;121(2):492-501.
28. Wicks RT, Pradilla G, Raza SM, Hadelsberg U, Coon AL, Huang J, et al. Impact of changes in intraoperative somatosensory evoked potentials on stroke rates after clipping of intracranial aneurysms. Neurosurgery. 2012;70(5):1114-24.
29. Fok M, Jafarzadeh F, Sancho E, Abello D, Rimmer L, Howard C, et al. Is There Any Benefit of Neuromonitoring During Descending and Thoracoabdominal Aortic Aneurysm Repair? Innovations (Philadelphia, Pa). 2015;10(5):342-8.
30. Legatt AD, Emerson RG, Epstein CM, MacDonald DB, Deletis V, Bravo RJ, et al. ACNS Guideline: Transcranial Electrical Stimulation Motor Evoked Potential Monitoring. Journal of clinical neurophysiology : official publication of the American Electroencephalographic Society. 2016;33(1):42-50.
31. Hayashi H, Kawaguchi M. Intraoperative Visual Evoked Potential Monitoring. Masui The Japanese journal of anesthesiology. 2015;64(5):508-14.
32. Bharadwaj S, Venkatraghavan L. Intraoperative Phase Reversal Monitoring Using a Novel Technique. Journal of neurosurgical anesthesiology. 2016;28(1):82.
33. Estrera AL, Sheinbaum R, Miller CC, 3rd, Harrison R, Safi HJ. Neuromonitor-guided repair of thoracoabdominal aortic aneurysms. The Journal of thoracic and cardiovascular surgery. 2010;140(6 Suppl):S131-5; discussion S42-S46.
34. Coselli JS, Bozinovski J, LeMaire SA. Open surgical repair of 2286 thoracoabdominal aortic aneurysms. Ann Thorac Surg. 2007;83(2):S862-4; discussion S90-2.
35. Pillai JB, Pellet Y, Panagopoulos G, Sadek MA, Abjigitova D, Weiss D, et al. Somatosensory-evoked potential-guided intercostal artery reimplantation in thoracoabdominal aortic aneurysm surgery. Innovations (Philadelphia, Pa). 2013;8(4):302-

6.

36. Phillips JL, Chalouhi N, Jabbour P, Starke RM, Bovenzi CD, Rosenwasser RH, et al. Somatosensory evoked potential changes in neuroendovascular procedures: incidence and association with clinical outcome in 873 patients. *Neurosurgery*. 2014;75(5):560-7; discussion 6-7; quiz 7.

37. Li F, Gorji R. Spine Surgery and Intraoperative Monitoring. *Anesthesiology*: Springer; 2017. p. 121-31.

38. Nwachuku EL, Balzer JR, Yabes JG, Habeych ME, Crammond DJ, Thirumala PD. Diagnostic value of somatosensory evoked potential changes during carotid endarterectomy: A systematic review and meta-analysis. *JAMA Neurology*. 2015;72(1):73-80.

39. Malcharek MJ, Herbst V, Bartz GJ, Manceur AM, Gille J, Hennig G, et al. Multimodal evoked potential monitoring in asleep patients versus neurological evaluation in awake patients during carotid endarterectomy: a single-centre retrospective trial of 651 patients. *Minerva anesthesiologica*. 2015;81(10):1070-8.

40. Malcharek MJ, Ulkatan S, Marino V, Geyer M, Llado-Carbo E, Perez-Fajardo G, et al. Intraoperative monitoring of carotid endarterectomy by transcranial motor evoked potential: a multicenter study of 600 patients. *Clinical neurophysiology : official journal of the International Federation of Clinical Neurophysiology*. 2013;124(5):1025-30.

41. Malcharek MJ, Kulpok A, Deletis V, Ulkatan S, Sablotzki A, Hennig G, et al. Intraoperative multimodal evoked potential monitoring during carotid endarterectomy: a retrospective study of 264 patients. *Anesthesia & Analgesia*. 2015;120(6):1352-60.

42. Chiang F-Y, Lu I-C, Chen H-C, Chen H-Y, Tsai C-J, Lee K-W, et al. Intraoperative neuromonitoring for early localization and identification of recurrent laryngeal nerve during thyroid surgery. *The Kaohsiung journal of medical sciences*. 2010;26(12):633-9.

43. Genther DJ, Kandil EH, Noureldine SI, Tufano RP. Correlation of final evoked potential amplitudes on intraoperative electromyography of the recurrent laryngeal nerve with immediate postoperative vocal fold function after thyroid and parathyroid surgery. *JAMA Otolaryngology–Head & Neck Surgery*. 2014;140(2):124-8.

44. Kamel I, Zhao H, Koch SA, Brister N, Barnette RE. The Use of Somatosensory Evoked Potentials to Determine the Relationship Between Intraoperative Arterial Blood Pressure and Intraoperative Upper Extremity Position–Related Neurapraxia in the Prone Surrender Position During Spine Surgery: A Retrospective Analysis. *Anesthesia & Analgesia*. 2016;122(5):1423-33.

45. Siller S, Szelényi A, Herlitz L, Tonn JC, Zausinger S. Spinal cord hemangioblastomas: significance of intraoperative neurophysiological monitoring for resection and long-term outcome. *Journal of Neurosurgery: Spine*. 2017;26(4):483-93.

46. Forster M-T, Marquardt G, Seifert V, Szelényi A. Spinal cord tumor surgery—importance of continuous intraoperative neurophysiological monitoring after tumor resection. *Spine*. 2012;37(16):E1001-E8.

47. Chen X, Sterio D, Ming X, Para DD, Butusova M, Tong T, et al. Success rate of motor evoked potentials for intraoperative neurophysiologic monitoring: effects of age, lesion location, and preoperative neurologic deficits. *Journal of clinical neurophysiology : official publication of the American Electroencephalographic Society*. 2007;24(3):281-5.

48. Seidel K, Beck J, Stieglitz L, Schucht P, Raabe A. The warning-sign hierarchy between quantitative subcortical motor mapping and continuous motor evoked potential monitoring during resection of supratentorial brain tumors. *Journal of neurosurgery*. 2013;118(2):287-96.

49. Langeloo D-D, Journée H-L, De Kleuver M, Grotenhuis J. Criteria for transcranial electrical motor evoked potential monitoring during spinal deformity surgery: a review and discussion of the literature. *Neurophysiologie Clinique/Clinical Neurophysiology*. 2007;37(6):431-9.

50. Rho Y, Rhim S, Kang J. Is intraoperative neurophysiological monitoring valuable predicting postoperative neurological recovery? *Spinal cord*. 2016;54(12):1121-6.
51. Hokari M, Ito Y, Yamazaki K, Chiba Y, Isobe M, Isu T. The Relationship between Carotid Stump Pressure and Changes in Motor-Evoked Potentials in Carotid Endarterectomy Patients. *Journal of Neurological Surgery Part A: Central European Neurosurgery*. 2016;77(04):291-6.
52. Sridharan ND, Thirumala P, Chaer R, Balzer J, Long B, Crammond D, et al. Predictors of cross-clamp-induced intraoperative monitoring changes during carotid endarterectomy using both electroencephalography and somatosensory evoked potentials. *Journal of Vascular Surgery*. 2017.
53. Grossauer S, Koeck K, Kraschl J, Olipitz O, Hausegger KA, Vince GH. Detection of Cerebral Vasospasm Following Aneurysmal Subarachnoid Hemorrhage Using Motor Evoked Potentials. *Neurosurgery*. 2016;78(2):265-73.
54. Etz CD, Di Luozzo G, Zoli S, Lazala R, Plestis KA, Bodian CA, et al. Direct spinal cord perfusion pressure monitoring in extensive distal aortic aneurysm repair. *The Annals of thoracic surgery*. 2009;87(6):1764-73; discussion 73-4.
55. ter Wolbeek C, Hartert M, Conzelmann L, Peivandi A, Czerny M, Gottardi R, et al. Value and pitfalls of neurophysiological monitoring in thoracic and thoracoabdominal aortic replacement and endovascular repair. *The Thoracic and cardiovascular surgeon*. 2010;58(05):260-4.
56. McGarvey ML. Effective tool or necessary evil: intraoperative monitoring during thoracic aneurysm repairs. *Journal of Clinical Neurophysiology*. 2012;29(2):154-6.
57. Group GTC. General Anesthesia Versus Local Anesthesia for Carotid Surgery (GALA): A Multicentre, Randomised Controlled Trial. *Journal of Vascular Surgery*. 2009;49(6):1626.
58. Chiang F-Y, Lu I-C, Chen H-C, Chen H-Y, Tsai C-J, Hsiao P-J, et al. Anatomical variations of recurrent laryngeal nerve during thyroid surgery: how to identify and handle the variations with intraoperative neuromonitoring. *The Kaohsiung journal of medical sciences*. 2010;26(11):575-83.
59. Barczyński M, Konturek A, Stopa M, Hubalewska-Dydejczyk A, Richter P, Nowak W. Clinical value of intraoperative neuromonitoring of the recurrent laryngeal nerves in improving outcomes of surgery for well-differentiated thyroid cancer. *Polish Journal of Surgery*. 2011;83(4):196-203.
60. Frattini F, Mangano A, Boni L, Rausei S, Biondi A, Dionigi G. Intraoperative neuromonitoring for thyroid malignancy surgery: technical notes and results from a retrospective series. *Updates in surgery*. 2010;62(3-4):183-7.
61. Alesina PF, Rolfs T, Hommeltenberg S, Hinrichs J, Meier B, Mohmand W, et al. Intraoperative neuromonitoring does not reduce the incidence of recurrent laryngeal nerve palsy in thyroid reoperations: results of a retrospective comparative analysis. *World journal of surgery*. 2012;36(6):1348-53.
62. Dequanter D, Charara F, Shahla M, Lothaire P. Usefulness of neuromonitoring in thyroid surgery. *European Archives of Oto-Rhino-Laryngology*. 2015;272(10):3039-43.
63. Irie T, Yoshitani K, Ohnishi Y, Shinzawa M, Miura N, Kusaka Y, et al. The efficacy of motor-evoked potentials on cerebral aneurysm surgery and new-onset postoperative motor deficits. *Journal of neurosurgical anesthesiology*. 2010;22(3):247-51.
64. Krieg SM, Schäffner M, Shiban E, Droese D, Obermüller T, Gempt J, et al. Reliability of intraoperative neurophysiological monitoring using motor evoked potentials during resection of metastases in motor-eloquent brain regions. *Journal of neurosurgery*. 2013;118(6):1269-78.
65. Subramanian SK, Gaur GS, Narayan SK. Low luminance/eyes closed and monochromatic stimulations reduce variability of flash visual evoked potential latency. *Ann Indian Acad Neurol*. 2013;16(4):614-8.

66. Kodama K, Goto T, Sato A, Sakai K, Tanaka Y, Hongo K. Standard and limitation of intraoperative monitoring of the visual evoked potential. *Acta neurochirurgica*. 2010;152(4):643-8.
67. Lepski G, Honegger J, Liebsch M, Sória MG, Narischat P, Ramina KF, et al. Safe resection of arteriovenous malformations in eloquent motor areas aided by functional imaging and intraoperative monitoring. *Operative Neurosurgery*. 2011;70(suppl_2):ons276-ons89.
68. Epstein NE. The need to add motor evoked potential monitoring to somatosensory and electromyographic monitoring in cervical spine surgery. *Surgical neurology international*. 2013;4(Suppl 5):S383-91.
69. Raynor BL, Bright JD, Lenke LG, Ra'Kerry KR, Bridwell KH, Riew KD, et al. Significant change or loss of intraoperative monitoring data: a 25-year experience in 12,375 spinal surgeries. *Spine*. 2013;38(2):E101-E8.
70. Kim D-G, Choi Y-D, Jin S-H, Kim CH, Lee K-W, Park KS, et al. Intraoperative Motor-Evoked Potential Disappearance versus Amplitude-Decrement Alarm Criteria During Cervical Spinal Surgery: A Long-Term Prognosis. *Journal of Clinical Neurology*. 2017;13(1):38-46.
71. Shilian P, Zada G, Kim AC, Gonzalez AA. Overview of Intraoperative Neurophysiological Monitoring During Spine Surgery. *Journal of Clinical Neurophysiology*. 2016;33(4):333-9.
72. Wang S, Zhang J, Tian Y, Shen J, Zhao Y, Zhao H, et al. Intraoperative motor evoked potential monitoring to patients with preoperative spinal deficits: judging its feasibility and analyzing the significance of rapid signal loss. *The Spine Journal*. 2015.
73. Sloan TB, Toleikis JR, Toleikis SC, Koht A. Intraoperative neurophysiological monitoring during spine surgery with total intravenous anesthesia or balanced anesthesia with 3% desflurane. *Journal of clinical monitoring and computing*. 2015;29(1):77-85.
74. Polly DW, Jr., Rice K, Tamkus A. What Is the Frequency of Intraoperative Alerts During Pediatric Spinal Deformity Surgery Using Current Neuromonitoring Methodology? A Retrospective Study of 218 Surgical Procedures. *The Neurodiagnostic journal*. 2016;56(1):17-31.
75. Yeon JY, Seo D-W, Hong S-C, Kim J-S. Transcranial motor evoked potential monitoring during the surgical clipping of unruptured intracranial aneurysms. *Journal of the neurological sciences*. 2010;293(1):29-34.
76. Liu Q, Wang Q, Liu H, Wu WKK, Chan MTV. Warning criteria for intraoperative neurophysiologic monitoring. *Current Opinion in Anesthesiology*. 2017;30(5):557-62.
77. Suzuki K, Mikami T, Sugino T, Wanibuchi M, Miyamoto S, Hashimoto N, et al. Discrepancy between voluntary movement and motor-evoked potentials in evaluation of motor function during clipping of anterior circulation aneurysms. *World neurosurgery*. 2014;82(6):e739-e45.

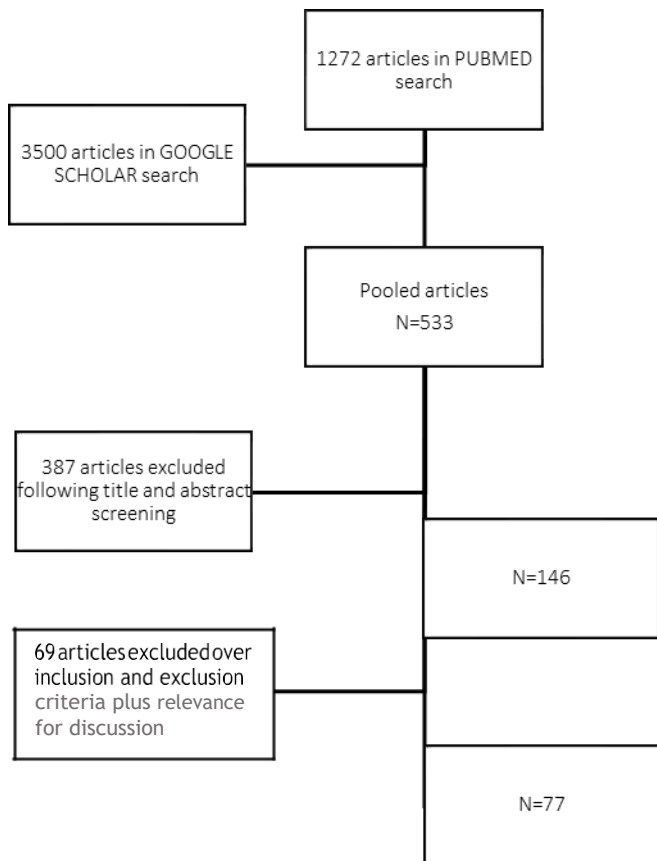


Figure 1 – Inclusion / exclusion methodology of manuscripts.

Table I – Evidence based recommendations²⁰

Recommendation	Evidence Level
Qualified personnel should acquire and interpret intraoperative MEP	Class III, type C
Intraoperative MEP techniques are considered safe once handled by trained personnel, plus taken precautions	Class II and III, type B
MEP as an option for localizing motor cortex, proximity to corticospinal tract fibers and motor pathways monitoring during risk related surgeries.	Class II and III, type B
Total intravenous anesthesia usually based on propofol and opioid infusion is optimal for muscle MEP monitoring. Benzodiazepines, ketamine and etomidate may be suitable intravenous alternatives.	Class II and III, type B
Interpretation should consider limitations and confounding factors (Monitoring should include tracing of anesthetic dosages and physiological parameters, and rostral or contralateral control MEP when possible)	Class III, type C
Warning criteria for D-waves are based on amplitude reduction having no apparent confounding factor explanation (intramedullary spinal cord tumor surgery with more than 50% baseline; Brain surgery with DCS cervical D-waves with more than 30-40% reduction; Orthopedic spine and other surgeries: No established criterion)	Class III
Spinal cord procedures: disappearance is always a major criterion	Class II and III, type B
Intramedullary spinal cord tumor surgery marked amplitude reduction, acute threshold elevation could be additional moderate criteria	Class II and III, type B
Descending aortic surgery: marked amplitude reduction or acute threshold elevation could be additional moderate criteria	Class II and III, type B
Brain and brainstem: major criteria include disappearance or more than 50% amplitude reduction if recordings are stable, or amplitude reduction clearly exceeding variability when responses are less stable and an acute threshold elevation might be relevant	Class III, type C
Facial nerve: major criteria include disappearance or consistent more than 50% amplitude reduction in stable recordings	Class III, type C
Nerve roots: no established criterion	Class III, type U

Table II - Quality of evidence²⁰

Quality of evidence	Class I: one or more well-designed, prospective, blinded, controlled studies;
	Class II: one or more well-designed, clinical studies such as case control, cohort studies
	Class III: expert opinion, non-randomized historical controls or case reports

Table III – Strength of recommendation²⁰

Strength of recommendation	Type A: strong positive recommendation based on Class I, or overwhelming Class II evidence
	Type B: Positive recommendation based on Class II evidence
	Type C: Positive recommendation based on strong consensus Class III evidence
	Type D: Negative recommendation based on inconclusive or conflicting Class II evidence
	Type E: Negative recommendation based on evidence of ineffectiveness
	Type U: No recommendation, based on divided expert opinion or insufficient data

Instituto de Ciências Biomédicas Abel Salazar

