

## GUIDELINES

# Joint recommendations for the diagnosis and treatment of vulvo-vaginal atrophy in women in the peri- and post-menopausal phases from the Società Italiana per la Menopausa (SIM) and the Società Italiana della Terza Età (SIGiTE)

Angelo CAGNACCI<sup>1\*</sup>, Mario GALLO<sup>2</sup>, Marco GAMBACCIANI<sup>3</sup>,  
Stefano LELLO<sup>4</sup> on behalf of the Società Italiana della Menopausa (SIM) and  
the Società Italiana di Ginecologia della Terza Età (SIGiTE)

<sup>1</sup>Department of Obstetrics and Gynecology, San Martino Hospital, Genoa, Italy; <sup>2</sup>Department of Obstetrics and Gynecology, Presidio Ospedaliero Riunito di Ciriè-Lanzo, Ciriè, Turin, Italy; <sup>3</sup>Menopause Center, Department of Obstetrics and Gynecology, Pisa University Hospital, Pisa, Italy; <sup>4</sup>Department of Women's and Children's Health, A. Gemelli Polyclinic, Rome, Italy

\*Corresponding author: Angelo Cagnacci, Department of Obstetrics and Gynecology, San Martino Hospital, Genoa, Italy.  
E-mail: [angelo.cagnacci@unige.it](mailto:angelo.cagnacci@unige.it)

## ABSTRACT

Herein, joint recommendations for diagnosis and treatment of vulvo-vaginal atrophy (VVA) in women in the peri- and post-menopausal phases from the Società Italiana per la Menopausa (SIM) and the Società Italiana della Terza Età (SIGiTE) are presented. The recommendations are aimed at all healthcare personnel caring for women in the menopausal transition or postmenopausal phase, and are also intended to raise awareness of VVA. Recent data clearly indicate VVA is a highly prevalent condition among postmenopausal women, and that the vast majority of women with VVA are not adequately treated. In reality, diagnosis of VVA is simple and largely clinical. Many types of treatments are available for VVA, ranging from preventive education measures to local non-hormonal therapies, local agents that modulate hormonal receptors and systemic as well as laser therapy and radiofrequency. Regardless of the therapeutic approach adopted, greater communication between the physician and the woman with VVA should be actively encouraged. This is also in light of the difficulty of talking about the VVA and related disorders. Greater communication also encourages adequate therapy and thus minimizes the impact of VVA on the quality of life of the woman and her partner.

*(Cite this article as: Cagnacci A, Gallo M, Gambacciani M, Lello S; Società Italiana della Menopausa (SIM); Società Italiana di Ginecologia della Terza Età (SIGiTE). Joint recommendations for the diagnosis and treatment of vulvo-vaginal atrophy in women in the peri- and post-menopausal phases from the Società Italiana per la Menopausa (SIM) and the Società Italiana della Terza Età (SIGiTE). Minerva Ginecol 2019;71:345-52. DOI: 10.23736/S0026-4784.19.04469-1)*

KEY WORDS: Atrophy; Postmenopause; Diagnosis; Guideline; Quality of life.

The present recommendations are aimed at all healthcare personnel who care for women in the menopausal transition or postmenopausal phase. The recommendations are addressed to Italian healthcare professionals, although many considerations can have more outreaching value.

The present considerations are intended to raise awareness and provide guidance on diagnosis and therapy of vulvo-vaginal atrophy (VVA). The need for these recommendations arises from two major considerations:

1) a recent study in Italy indicated that al-

most all (98%) of women with VVA are not adequately treated. This is attributable to a number of factors, including the lack of diagnosis, which is often linked to the lack of physician-patient communication, and to wide differences in treatments and their length of use;

2) there are no clear indications in the literature on how a diagnosis of VVA should be made and how it should be managed, in terms of therapies, doses and time of administration.

### Signs and symptoms of VVA

VVA refers to a clinical picture of dystrophy of the external genitals and vagina that is related to the combination of several factors, most often aging, reduced sexual activity and reduced or absent hormonal stimulation. The clinical features present with objective signs that are observed by the physician during clinical evaluation as well as patient-reported symptoms. Objective signs include reduction of the maturation index of the vaginal epithelium and a vaginal pH>5. The signs revealed by the physician comprise vaginal dryness, pallor and thinning of the mucosa, reduction and disappearance of vaginal folds, reduced vaginal elasticity, appearance of petechiae and mucosa lesions due to minimal trauma. At the vulvar level, there is a progressive reduction of the large and small lips, reduction of the clitoris, alterations of the urethral meatus that can become lumpy and lead to the appearance of urethral caruncles, narrowing of the vaginal introitus, thinning and pallor of the vulvar mucosa and appearance of petechiae, excoriations and ulcerations on the mucosa. These alterations are also associated with modifications of the microbiological niche up to the disappearance of lactobacilli and colonization of the vagina by other microorganisms, which although not always pathogenic, are less likely to defend the vagina from pathogenic bacteria. The symptoms of VVA are the sensation of dryness, pain during intercourse, burning, itching and recurrent vaginal infections.

### Epidemiology of VVA

Many studies have attempted to define the prevalence of VVA with different approaches, but all

are burdened by methodological defects that prevent obtaining a clear picture of its actual prevalence. In epidemiological studies performed by hospital outpatient services across Italy, it emerged that in postmenopausal women prevalence of vaginal atrophy is 79-81%. Prevalence appears to be around 65% at one year after menopause, reaching 85% at 5 years after menopause. The most frequent objective sign is elevated pH, followed by the detection of a drier, paler mucosa with reduced folds. Roughly 64% women with vaginal atrophy also have vulvar atrophy. Vaginal atrophy also occurs in 20% to 55% of younger women between the age of 40 and 55 years.

The most frequent symptom of VVA is the sensation of vaginal dryness. Pain at intercourse is the second most common symptom, although its prevalence is higher in younger women and abruptly reduced at 5-7 years after menopause. The symptom referred to as the most bothersome by women is vaginal dryness, which is also present in a 3-10% of post-menopausal women and in 25% of peri-menopausal women in which a clear diagnosis of VVA has not been established.

### Quality of life and VVA

VVA normally appears in the period in which hormonal variations related to peri- and post-menopause cause imbalances in the central nervous system, which manifest as neurovegetative disorders, changes in mood and reduction in sexual desire. Within the framework outlined above, the symptoms resulting from VVA have a profound influence on the woman's quality of life. The feeling of dryness and pain during intercourse inevitably leads to feelings of inadequacy and decreased feeling of femininity, as well as a reduced number of sexual intercourse, desire and sexual satisfaction. These effects cannot be understood in their entirety if one does not consider the reflexes of the partner who perceives a rejection of sexual intimacy. Such a situation leads to misunderstandings that, when generated in the sexual sphere, are transferred to personal relationships with moments of conflict and misinterpretation. Ultimately, the couple's relationship is undermined, with heavy repercussions on the quality of life of the couple and family.

## Patient-physician communication

The Italian AGATA study showed that a clear diagnosis of VVA is not made in about 60% of postmenopausal women. This is related to the lack of communication between a woman and her gynecologist. Women do not easily talk about VVA and related disorders for a number of reasons: 1) they do not consider the symptoms to be relevant, as they believe the condition is an inevitable part of aging; 2) they consider the symptoms as not entirely burdensome and thus do not warrant therapy; 3) are embarrassed in dealing with the topic with their physician; 4) they perceive that the physician has a low level of interest; 5) they believe that there are no effective therapies. On the other hand, most physicians do not query about the symptoms of VVA and about half of those who do seem to give little weight to patient-reported symptoms. A pro-active approach by the physician is needed in dealing with problems related to VVA. In addition to careful evaluation of the genitals, the physician must investigate any symptoms reported, as well as any other potential problems that the couple may have, and outline the course of VVA along with possible therapies.

## Diagnosis of VVA

A diagnosis of VVA is established based on three parameters:

- vaginal pH>5;
- the sensation of vaginal dryness as reported by the patient;
- the presence of at least one of the following objective signs seen by the physician: presence of dry mucosa, pallor of the mucosa, fragility of the mucosa, thinning of vaginal folds, or presence of petechiae.

Thus, diagnosis is simple and is clinically feasible in any ambulatory setting. The symptom of vaginal dryness as reported by the patient, exceeds a diagnosis of VVA in 3-9% of postmenopausal women and in 27% of women between 40 and 55 years. However, even in the absence of a clear diagnosis of VVA, the presence of symptoms, such as vaginal dryness, is an indication to start a therapy.

## Preventive educational measures

Even in the presence of low hormonal levels, the epithelium of the vaginal mucosa responds to the mechanical stimulus of the sexual act by preservation of its trophism and lubrication. The promotion of sexual intercourse is thus a mechanism in itself for prevention of VVA. The use of endo-vaginal stimulators can increase vascularization and vaginal trophism and can be seen as an option to propose to women. In case of painful intercourse, lubricants can be useful, such as a gel based on lidocaine to be used on the vulvar region and the vaginal introit. In the case of vaginal narrowing, vaginal dilators together with lubricants may be considered.

## Local non-hormonal therapies

The use of substances that can reduce the sensation of vaginal dryness is also of benefit in women who do not have sexual activity, as the sensation of dryness, even when isolated, is perceived by the majority women as the most bothersome symptom. Reduction in vaginal dryness can be achieved with vaginal lubricants and moisturizers. It is important to note that these remedies are not able to restore the physiology of the vagina or promote maturation of the vaginal epithelium.

Water based lubricants and moisturizers contain excipients that give them the appropriate viscosity, osmolarity and pH. The osmolarity should be around 320 and 1200 mOsm/kg, as higher values are irritating to the mucosa and are cytotoxic. The pH should be in the range of 3.8 and 4.5. Among excipients, parabens may be present, which have weak estrogenic activity, as well as glycols and glycerol/glycerin which influence osmolarity. In order to maintain an appropriate osmolarity, the amount of glycols should be <8.3% and that of glycerol/glycerin <9.9%. The excessive presence of glycerol and glycols is toxic to lactobacilli and promotes both herpes simplex infection and bacterial vaginosis. Furthermore, glycerol/glycerin can be used as a nutrient source by *Candida albicans*.

## Vaginal lubricants

Vaginal lubricants are products based on aqueous gels, mineral oils, vegetable oils, or silicone-

based products. Their application in the vagina provides short-lasting but rapid relief of vaginal dryness and pain during intercourse. Lubricants are therefore an acceptable option for women who only have dyspareunia or vaginal dryness during sexual intercourse. To reduce local side effects, water-based lubricants are preferred over those containing silicone. The WHO suggests the use of lubricants in association with condoms for menopausal women, in order to reduce the transmission of sexually transmitted diseases.

### Vaginal moisturizers

Vaginal moisturizers adhere to the vaginal mucosa, promoting rehydration and mimicking the effect of vaginal secretions. They are used regularly with a frequency that can range from one application per day to one every three days, depending on the severity of the condition. Being moisturizers, the preparations contain water and other substances such as hyaluronic acid or polycarbophil. Some 3-month studies indicate that both hyaluronic acid and polycarbophil-based compounds are effective in reducing the symptoms of VVA, although studies on the latter compounds in oncology patients have documented only transient benefits.

### Other agents

There is some evidence to suggest that gels containing bovine colostrum, vitamin D (not present in Italy), or oxytocin (not present in Italy) may have some benefits on symptoms.

## Local agents that modulate hormonal receptors

### Estrogens

Local therapy with estrogens is considered to be the most effective treatment for VVA. Systemic estrogenic therapies are not indicated when the only symptom is disorders related to VVA. Systemic or local hormone therapies are associated with an improvement in symptoms in 75% to 85% of women, while the rate of remission of symptoms is observed in only about around 50% of cases. This indicates that all therapies have some degree of failure and that the perceived

improvement can sometimes be considered unsatisfactory.

Locally, various types of estrogens can be used, such as estradiol or estriol. Several formulations are now available (e.g. creams, gels, vaginal tablets, or vaginal ring). All therapies performed with vaginal creams, gels, rings, or tablets with estradiol or estriol are equally effective, and the choice of formulation depends on the woman's personal choice. Vaginal tablets and gels are less messy than creams and are often more pleasing for the woman in the long term. The available clinical studies suggest daily administration for the first 3 weeks, followed by two administrations per week for 3-6 or 12 months. This dosage is based on controlled clinical trials, but it can be modified based on personal needs. The ring is left in place for 3 months and can be used for long-term administration.

Systemic absorption of hormones is minimal with most hormonal formulations, but still occurs and for this reason the indication is to administer the estrogen at the lowest effective dose. This is most easily achieved with the administration of estriol in the form of a gel or vaginal tablets. Of note, due to systemic absorption such formulations are contraindicated in women with previous hormone-sensitive tumors. Regarding safety, increases in the incidence of venous thromboembolism and breast and endometrium cancer have not been reported in women undergoing low-dose vaginal estrogen therapy.

The safety of local estrogen on the endometrium has been demonstrated in studies with duration <12 months. The absence of long-term safety data suggests that in women who continue therapy for a longer period of time, ultrasound examinations of endometrial thickness should be performed; while there are no specific recommendations regarding timing, it is reasonable to hypothesize once every 12 months.

### Promestriene

There are few controlled clinical studies on the use of promestriene (3 propyl-ether-17 beta-methyl-ether of estradiol) for the treatment of VVA. All short-term studies to date (20–40 days) seem to indicate that promestriene is effective for VVA. Promestriene is an estrogen that is not me-

tabolized into estradiol and estrone, but which induces a marked increase in uterine volume in experimental animal studies. Although some authors have suggested that promestriene can be used in women with hormone-sensitive tumors, there are as yet no data on safety to support this affirmation.

### DHEA

DHEA can be administered as vaginal ovules (6.5 mg). Four randomized placebo-controlled studies have shown that, compared to placebo, 12-weeks of treatment with DHEA led to improvement of both objective signs and symptoms of VVA. In comparative studies, the efficacy of DHEA was similar to that of conjugated equine estrogens or estradiol. DHEA is converted to estradiol and testosterone in the vaginal epithelium. While this effect is local, pharmacokinetic data indicate that there is an increase in exposure to the estrogenic and androgenic metabolites of DHEA, even if circulating levels of estrogens and androgens remain in the normal range for postmenopausal women. No increases in the incidence of venous thromboembolism or breast and endometrium cancer have been reported in women treated with DHEA ovules at a dose of 6.5 mg/day. Safety data are available for up to 12 months of use, and there are no data on efficacy and safety in the longer term. Although its potential use has been hypothesized in women with hormone-sensitive/tumors, the compound does not currently have this indication. There are no data on the efficacy and safety of galenic preparations.

### Testosterone

There are no registered and approved preparations for treatment of VVA based on testosterone. The use of testosterone in vaginal creams has been evaluated in a few clinical studies, which are mostly observational and limited to a period of 3 months. The scarcity of clinical studies suggests that it should not be the first choice of treatment. The administration of testosterone may induce a small increase in circulating estradiol. There are no data on the efficacy and safety of galenic preparations in the literature.

### Phyto-estrogens

Plant-based products containing phytoestrogens may weakly stimulate the vaginal epithelium. Phyto-estrogens contained in *Humulus lupulum*, soy, or *Pereraria mirifica*, generally genistein, genistin and daidzein, dispersed in a gel formulation and administered daily, may be effective in improving the symptoms and signs of VVA. However, there is limited information from clinical studies on effectiveness, which have also been limited to a few weeks of treatment. Phyto-estrogens are absorbed into systemic circulation, and their systemic safety has not been ascertained.

### Systemic modulation of hormone receptors

#### Ospemifene

Ospemifene is the only oral molecule that is indicated for treatment of VVA. It is a selective estrogen receptor modulator (SERM) that exerts its action at the genito-urinary level. Clinical studies have shown that the administration of ospemifene at 60 mg/day improves the signs of vaginal atrophy, as well as the symptoms of VVA and sexual desire. Clinical studies have also shown that ospemifene improves both vulvar atrophy and vulvar pain. Being a SERM, ospemifene does not stimulate breast tissue and can also be administered to women who have undergone surgical intervention for breast cancer, following the end of adjuvant therapies. Post-marketing observational studies with data up to 2 years have excluded that the daily and long-term administration of this drug is associated with an increased risk of breast tumors, endometrial hyperplasia, gynecological pathologies of any kind, or an increased risk of thrombosis and cardiovascular disease. Clinical studies appear to indicate that the efficacy of ospemifene on the symptoms and signs of VVA is similar to that of locally administered estrogen, although there are no comparative studies.

#### Systemic hormonal therapies

Systemic hormone therapies are not indicated for the treatment of VVA alone. However, when

they are used for treatment of the systemic symptoms of menopause or for prevention of post-menopausal osteoporosis, they do improve the signs and symptoms of VVA similar to that seen with local estrogen treatment, even if there are no comparative studies. Systemic hormone therapies include several types of estrogens associated with various types of progestins, administered orally or transcutaneously, tibolone and the combination of estrogen and bazedoxifene (TSEC). The benefits and risks associated with systemic hormone therapies should be carefully be evaluated on a case by case basis.

### Other therapies

#### Laser therapy

Laser therapy has been used to manage VVA. Two types of lasers have been employed for VVA: a microablative CO<sub>2</sub> laser and the non-ablative Erbium-Smooth® laser. Application of a laser increases the temperature of tissue in a controlled manner, thus activating vasodilation and remodeling of collagen. Laser therapy has been standardized and consists of three administrations every 30 days. The results between the two types of lasers regarding vaginal atrophy appear to be broadly similar.

The data published to date indicates that laser treatment improves all the symptoms and the objective signs of VVA, and improves both sexuality and the quality of life of women, similar to local pharmacological treatments. The effects of laser therapy seem to be lost at about 12 months after the end of treatment, and it is still unclear how often laser treatments should be repeated in the long-term. Similarly, it is not clear if laser therapy is associated with any undesirable vaginal effects in the long term. Laser therapy can be considered among the range of therapeutic options based on the woman's specific needs and preferences and is of particular interest to women in whom systemic or local hormone therapies are contraindicated.

#### Radiofrequency

Radiofrequency creates an electric field that generates heat by moving molecules in tissue. The

device can be monopolar, bipolar, or multipolar, which differ in how the current passes through tissues where heat is generated. At a tissue temperature of 40-45 °C, collagen synthesis, vascularization and mucosal thickness are all stimulated. The instrument is activated and moved manually by the operator, without direct or indirect automatic control of the temperatures reached in tissues. There are only very few clinical studies with radiofrequency, and long-term controlled clinical trials assessing efficacy and safety in adequate populations are lacking. It should be highlighted that method and its effects are dependent on the operator, and are difficult to standardize and reproduce.

#### Duration of treatment

VVA develops when the vaginal mucosa or its hormone receptors are no longer stimulated by sexual activity and hormones. Long-term therapy consists of the use of treatments that favor or substitute sexual activity and the possibility to obtain adequate hormonal stimulation. There are no long-term data on the efficacy and safety of currently-available treatments for VVA. In the absence of this information, it is advisable to alternate among different types of therapy according to the age and needs of the woman with the objective of providing constant treatment (Figure 1). In the absence of long-term clinical trials, prolonging therapy requires reassessment of the efficacy and safety of the treatment at established times, with the possibility to adapt the dose and switch therapies in order to satisfy the needs and desires of the female patient.<sup>1-42</sup>

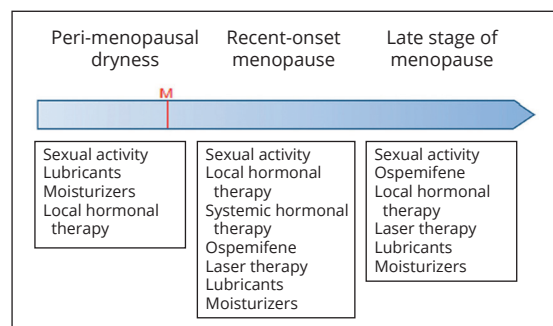


Figure 1.—Indications for therapy for vulvo-vaginal atrophy (VVA) at various life stages.

## References

1. Archer DF, Labrie F, Montesino M, Martel C. Comparison of intravaginal 6.5mg (0.50%) prasterone, 0.3mg conjugated estrogens and 10µg estradiol on symptoms of vulvovaginal atrophy. *J Steroid Biochem Mol Biol* 2017;174:1–8.
2. Barentsen R, van de Weijer PH, Schram JH. Continuous low dose estradiol released from a vaginal ring versus estriol vaginal cream for urogenital atrophy. *Eur J Obstet Gynecol Reprod Biol* 1997;71:73–80.
3. Barton DL, Shuster LT, Dockter T, Atherton PJ, Thielen J, Birrell SN, *et al.* Systemic and local effects of vaginal dehydroepiandrosterone (DHEA): NCCTG N10C1 (Alliance). *Support Care Cancer* 2018;26:1335–43.
4. Bachmann GA, Schaefer M, Uddin A, Utian WH. Microdose transdermal estrogen therapy for relief of vulvovaginal symptoms in postmenopausal women. *Menopause* 2009;16:877–82.
5. Bell RJ, Rizvi F, Islam RM, Davis SR. A systematic review of intravaginal testosterone for the treatment of vulvovaginal atrophy. *Menopause* 2018;25:704–9.
6. Biglia N, Peano E, Sgandurra P, Moggio G, Panuccio E, Migliardi M, *et al.* Low-dose vaginal estrogens or vaginal moisturizer in breast cancer survivors with urogenital atrophy: a preliminary study. *Gynecol Endocrinol* 2010;26:404–12.
7. Bruyniks N, Biglia N, Palacios S, Mueck AO. Systematic indirect comparison of ospemifene versus local estrogens for vulvar and vaginal atrophy. *Climacteric* 2017;20:195–204.
8. Bruyniks N, De Gregorio F, Gibbs T, Carroll R, Fraeman KH, Nordstrom BL. Safety of ospemifene during real-life use. *J Gynecol Wom Health* 2018;9:1–14.
9. Bygdeman M, Swahn ML. Replens versus dienoestrol cream in the symptomatic treatment of vaginal atrophy in postmenopausal women. *Maturitas* 1996;23:259–63.
10. Cagnacci A, Palma F, Napolitano A, Xholli A. Association between pelvic organ prolapse and climacteric symptoms in postmenopausal women. *Maturitas* 2017;99:73–8.
11. Cagnacci A, Xholli A, Sclauzero M, Venier M, Palma F, Gambacciani M; writing group of the ANGEL study. Vaginal atrophy across the menopausal age: results from the ANGEL study. *Climacteric* 2019;22:85–9.
12. Delgado JL, Estevez J, Radicioni M, Loprete L, Moscoso Del Prado J, Nieto Magro C. Pharmacokinetics and preliminary efficacy of two vaginal gel formulations of ultra-low-dose estriol in postmenopausal women. *Climacteric* 2016;19:172–80.
13. Del Pup L, Di Francia R, Cavaliere C, Facchini G, Giorda G, De Paoli P, *et al.* Promestriene, a specific topic estrogen. Review of 40 years of vaginal atrophy treatment: is it safe even in cancer patients? *Anticancer Drugs* 2013;24:989–98.
14. Edwards D, Panay N. Treating vulvovaginal atrophy/genitourinary syndrome of menopause: how important is vaginal lubricant and moisturizer composition? *Climacteric* 2016;19:151–61.
15. Faubion SS, Sood R, Kapoor E. Genitourinary Syndrome of Menopause: Management Strategies for the Clinician. *Mayo Clin Proc* 2017;92:1842–9.
16. Gambacciani M, Levancini M, Russo E, Vacca L, Simoncini T, Cervigni M. Long-term effects of vaginal erbium laser in the treatment of genitourinary syndrome of menopause. *Climacteric* 2018;21:148–52.
17. Goldstein SW, Winter AG, Goldstein I. Improvements to the vulva, vestibule, urethral meatus, and vagina in women treated with ospemifene for moderate to severe dyspareunia: a prospective vulvoscopy pilot study. *Sex Med* 2018;6:154–61.
18. Hammar ML, van de Weijer P, Franke HR, Pornel B, von Mauw EM, Nijland EA; TOTAL Study Investigators Group. Tibolone and low-dose continuous combined hormone treatment: vaginal bleeding pattern, efficacy and tolerability. *BJOG* 2007;114:1522–9.
19. Karpuzoglu E, Holladay SD, Gogal RM Jr. Parabens: potential impact of low-affinity estrogen receptor binding chemicals on human health. *J Toxicol Environ Health B Crit Rev* 2013;16:321–35.
20. Labrie F, Archer DF, Martel C, Vaillancourt M, Montesino M. Combined data of intravaginal prasterone against vulvovaginal atrophy of menopause. *Menopause* 2017;24:1246–56.
21. Le Donne M, Caruso C, Mancuso A, Costa G, Iemmo R, Pizzimenti G, *et al.* The effect of vaginally administered genistein in comparison with hyaluronic acid on atrophic epithelium in postmenopause. *Arch Gynecol Obstet* 2011;283:1319–23.
22. Lee A, Kim TH, Lee HH, Kim YS, Enkhbold T, Lee B, *et al.* Therapeutic approaches to atrophic vaginitis in postmenopausal women: a systematic review with a network meta-analysis of randomized controlled trials. *J Menopausal Med* 2018;24:1–10.
23. Leiblum S, Bachmann G, Kemmann E, Colburn D, Swartzman L. Vaginal atrophy in the postmenopausal woman. The importance of sexual activity and hormones. *JAMA* 1983;249:2195–8.
24. Lello S, Capozzi A, Scambia G. The tissue-selective estrogen complex (bazedoxifene/conjugated estrogens) for the treatment of menopause. *Int J Endocrinol* 2017;2017:5064725.
25. Lethaby A, Ayeleke RO, Roberts H. Local oestrogen for vaginal atrophy in postmenopausal women. *Cochrane Database Syst Rev* 2016;(8):CD001500.
26. Levine KB, Williams RE, Hartmann KE. Vulvovaginal atrophy is strongly associated with female sexual dysfunction among sexually active postmenopausal women. *Menopause* 2008;15:661–6.
27. López-Belmonte J, Nieto C, Estevez J, Delgado JL, del Prado JM. Comparative uterine effects on ovariectomized rats after repeated treatment with different vaginal estrogen formulations. *Maturitas* 2012;72:353–8.
28. Muhleisen AL, Herbst-Kralovetz MM. Menopause and the vaginal microbiome. *Maturitas* 2016;91:42–50.
29. Murina F, Di Francesco S, Oneda S. Vulvar vestibular effects of ospemifene: a pilot study. *Gynecol Endocrinol* 2018;34:631–5.
30. Nappi RE, Kingsberg S, Maamari R, Simon J. The CLOSER (CLarifying Vaginal Atrophy's Impact On Sex and Relationships) survey: implications of vaginal discomfort in postmenopausal women and in male partners. *J Sex Med* 2013;10:2232–41.
31. Palacios S, Nappi RE, Bruyniks N, Particco M, Panay N; EVES Study Investigators. The European Vulvovaginal Epidemiological Survey (EVES): prevalence, symptoms and impact of vulvovaginal atrophy of menopause. *Climacteric* 2018;21:286–91.
32. Palma F, Volpe A, Villa P, Cagnacci A; Writing group of AGATA study. Vaginal atrophy of women in postmenopause. Results from a multicentric observational study: the AGATA study. *Maturitas* 2016;83:40–4.
33. Palma F, Della Vecchia E, Cagnacci A; as the Writing Group of the AGATA study. Medical and patient attitude towards vaginal atrophy: the AGATA study. *Climacteric* 2016;19:553–7.
34. Palma F, Xholli A, Cagnacci A; as the writing group of

the AGATA study. Management of vaginal atrophy: a real mess. Results from the AGATA study. *Gynecol Endocrinol* 2017;33:702–7.

35. Palma F, Xholli A, Cagnacci A; as the writing group of the AGATA study. The most bothersome symptom of vaginal atrophy: evidence from the observational AGATA study. *Maturitas* 2018;108:18–23.

36. Pitsouni E, Grigoriadis T, Falagas ME, Salvatore S, Athanasiou S. Laser therapy for the genitourinary syndrome of menopause. A systematic review and meta-analysis. *Maturitas* 2017;103:78–88.

37. Rahn DD, Carberry C, Sanses TV, Mamik MM, Ward RM, Meriwether KV, *et al.*; Society of Gynecologic Surgeons Systematic Review Group. Vaginal estrogen for genitourinary syndrome of menopause: a systematic review. *Obstet Gynecol* 2014;124:1147–56.

38. Simon JA, Nappi RE, Kingsberg SA, Maamari R, Brown V. Clarifying Vaginal Atrophy's Impact on Sex and Relationships (CLOSER) survey: emotional and physical impact of

vaginal discomfort on North American postmenopausal women and their partners. *Menopause* 2014;21:137–42.

39. Suwanvesh N, Manonai J, Sophonsritsuk A, Cherdshewasart W. Comparison of Pueraria mirifica gel and conjugated equine estrogen cream effects on vaginal health in postmenopausal women. *Menopause* 2017;24:210–5.

40. The North Menopause Society Menopause Position Statement: Management of symptomatic vulvovaginal atrophy: 2013 Position Statement of The North American Menopause Society. *Menopause* 2013;888:902.

41. Utian WH, Shoupe D, Bachmann G, Pinkerton JV, Pickar JH. Relief of vasomotor symptoms and vaginal atrophy with lower doses of conjugated equine estrogens and medroxyprogesterone acetate. *Fertil Steril* 2001;75:1065–79.

42. World Health Organization. Use and procurement of additional lubricants for male and female condoms: WHO/UNFPA/FHI360 advisory note; 2012 [Internet]. Available from: [http://apps.who.int/iris/bitstream/10665/76580/1/WHO\\_RHR\\_12.33\\_eng.pdf](http://apps.who.int/iris/bitstream/10665/76580/1/WHO_RHR_12.33_eng.pdf) [cited 2019, Oct 4].

*Conflicts of interest.*—The authors certify that there is no conflict of interest with any financial organization regarding the material discussed in the manuscript.

*Group name.*—*Società Italiana della Menopausa* (SIM). President: M. Gambacciani. Past President: A. Volpe. Vice-Presidents: A. Cagnacci, A. Lanzone. Treasurer: C. Di Carlo. Secretary: V. De Leo. Advisors: N. Biglia, S. Caruso, E. Cicinelli, M. Farris, A. Gambera, S. Guaschino, A.M. Paoletti, N. Russo, F. Vicariotto, P. Villa. *Società Italiana di Ginecologia della Terza Età* (SIGITE). President: M. Gallo. Past-President: F. Nocera. Vice-Presidents: S. Maffei, M. Pandolfo. Secretary: S. Lello. Advisors: S. Ambroggio, G. Grassi, F. De Seta, M. Stomati, D. Gullo. Board of Arbitrators: A. Becorpi, F. Cancellieri, F. Fiorillo. Revisors: L. Del Pup, C. Mapell, S. Ottanelli.

Manuscript accepted: September 26, 2019. - Manuscript received: September 17, 2019.