

IRIS A<sub>per</sub>TO



UNIVERSITÀ  
DEGLI STUDI  
DI TORINO

**This is the author's final version of the contribution published as:**

Mastropasqua L, Lanzini M, **Curcio C**, Calienno R, Mastropasqua R, Colasante M, Mastropasqua A, Nubile M. Structural modifications and tissue response after standard epi-off and iontophoretic corneal crosslinking with different irradiation procedures. *Invest Ophthalmol Vis Sci.* 55:2526-2533, 2014

**The publisher's version is available at:**

PMID: 24667859

**When citing, please refer to the published version.**

**Link to this full text:**

<https://iovs.arvojournals.org>

This full text was downloaded from iris-AperTO: <https://iris.unito.it/>

---

iris-AperTO

University of Turin's Institutional Research Information System and Open Access Institutional Repository

# Structural Modifications and Tissue Response After Standard Epi-Off and Iontophoretic Corneal Crosslinking With Different Irradiation Procedures

Leonardo Mastropasqua,<sup>1</sup> Manuela Lanzini,<sup>1</sup> Claudia Curcio,<sup>1,2</sup> Roberta Calienno,<sup>1</sup>  
Rodolfo Mastropasqua,<sup>3</sup> Martina Colasante,<sup>1</sup> Alessandra Mastropasqua,<sup>4</sup> and Mario Nubile<sup>1</sup>

<sup>1</sup>Department of Medicine and Ageing Sciences, Ophthalmology Clinic, University "G. d'Annunzio" of Chieti-Pescara, Chieti and Pescara, Italy

<sup>2</sup>Department of Medicine and Ageing Sciences, Visual Science Laboratory, CeSI, University "G. d'Annunzio" of Chieti-Pescara, Chieti and Pescara, Italy

<sup>3</sup>Ophthalmology Clinic, University of Verona, Verona, Italy

<sup>4</sup>Ophthalmology Clinic, Campus Biomedico, Roma, Italy

Correspondence: Manuela Lanzini,  
Via S. Silvestro 294, 65129 Pescara,  
Italy;  
m.lanzini@unich.it.

Submitted: September 29, 2013

Accepted: March 13, 2014

Citation: Mastropasqua L, Lanzini M, Curcio C, et al. Structural modifications and tissue response after standard epi-off and iontophoretic corneal crosslinking with different irradiation procedures. *Invest Ophthalmol Vis Sci.* 2014;55:2526-2533. DOI: 10.1167/iovs.13-13363

**PURPOSE.** The aim of this study is to investigate modifications in human cadaver corneas after different crosslinking procedures, including standard epi-off treatment, iontophoresis imbibition, and different exposure to ultraviolet A (UVA) sources (30 minutes at 3 mW and 9 minutes at 10 mW).

**METHODS.** A total of 12 human cadaver corneas was examined and divided as follows: 3 served as control (group 1), 3 were treated with a standard epi-off procedure (group 2), 6 underwent iontophoresis imbibition for 5 minutes, and then 3 were irradiated for 30 minutes with 3 mW UVA (group 3), and 3 for 9 minutes at 10 mW UVA (group 4). Deformation amplitude index was measured before and after the corneas underwent treatment. After treatment, corneas were prepared for hematoxylin-eosin and immunohistochemistry evaluation. The expression of TUNEL, matrix metalloproteinase-1 (MMP-1), collagen type I, and CD34 was investigated in all samples.

**RESULTS.** The deformation amplitude index decreased in all groups, in particular in group 4, indicating an improvement of corneal biomechanical properties. Immunohistochemical staining showed a significant stromal alteration in group 2, mild damage in group 3, and no modifications in corneal morphology in group 4. The TUNEL ( $P < 0.001$ ) and MMP-1 ( $P = 0.002$ ) positivity was more evident in group 4. Collagen type I positivity significantly increased in groups 3 ( $P = 0.002$ ) and 4 ( $P = 0.002$ ). The CD34 expression was more evident in groups 2 ( $P = 0.003$ ) and 3 ( $P = 0.003$ ).

**CONCLUSIONS.** Iontophoresis imbibition followed by UVA irradiation for 9 minutes at 10 mW determined less tissue damage and better stromal remodeling.

Keywords: crosslinking, keratoconus, iontophoresis

Iontophoresis is a noninvasive delivery system designed to enhance the penetration of molecules into tissue using a small electric current. This technique is used in various fields of medicine,<sup>1-3</sup> including delivery of drugs to intraocular compartments.<sup>4,5</sup> This system yields higher concentrations in exposed tissue compared to a free drug solution,<sup>6</sup> and was adopted in ophthalmology mainly for the treatment of posterior segment disease.<sup>4,7</sup>

Iontophoresis was proposed as a method to increase riboflavin absorption in crosslinking (CXL) treatment.<sup>8</sup> Corneal CXL is a new technique introduced for the treatment of progressive keratoconus, with the aim of increasing the stiffness of the cornea, improving biomechanical strength, inducing keratocyte apoptosis, and increasing resistance to enzymatic digestion by the combined action of the photosensitizer riboflavin (vitamin B2) and ultraviolet A (UVA) rays.<sup>9-14</sup> Further indications, such as iatrogenic keratectasia,<sup>15</sup> infectious

keratitis,<sup>16</sup> bullous keratopathy,<sup>17</sup> corneal ulcers,<sup>18</sup> and progressive myopia,<sup>19</sup> were proposed for CXL.

Riboflavin in the form used for iontophoresis is negatively charged. It has been shown that a corneal iontophoresis imbibition lasting five minutes achieves a sufficient riboflavin concentration in corneal stroma for CXL treatment, with the advantage of shortening the imbibition time while preserving epithelial integrity.<sup>20</sup> Changes in corneal structure, mainly in collagen composition and keratocyte phenotype, have been reported in keratoconus and after CXL treatment.<sup>21,22</sup>

This study aimed at investigating ex vivo corneal histologic and biomechanical modifications after CXL performed with different imbibition and irradiation protocols, including standard technique and iontophoretic transepithelial imbibition with various irradiation procedures.

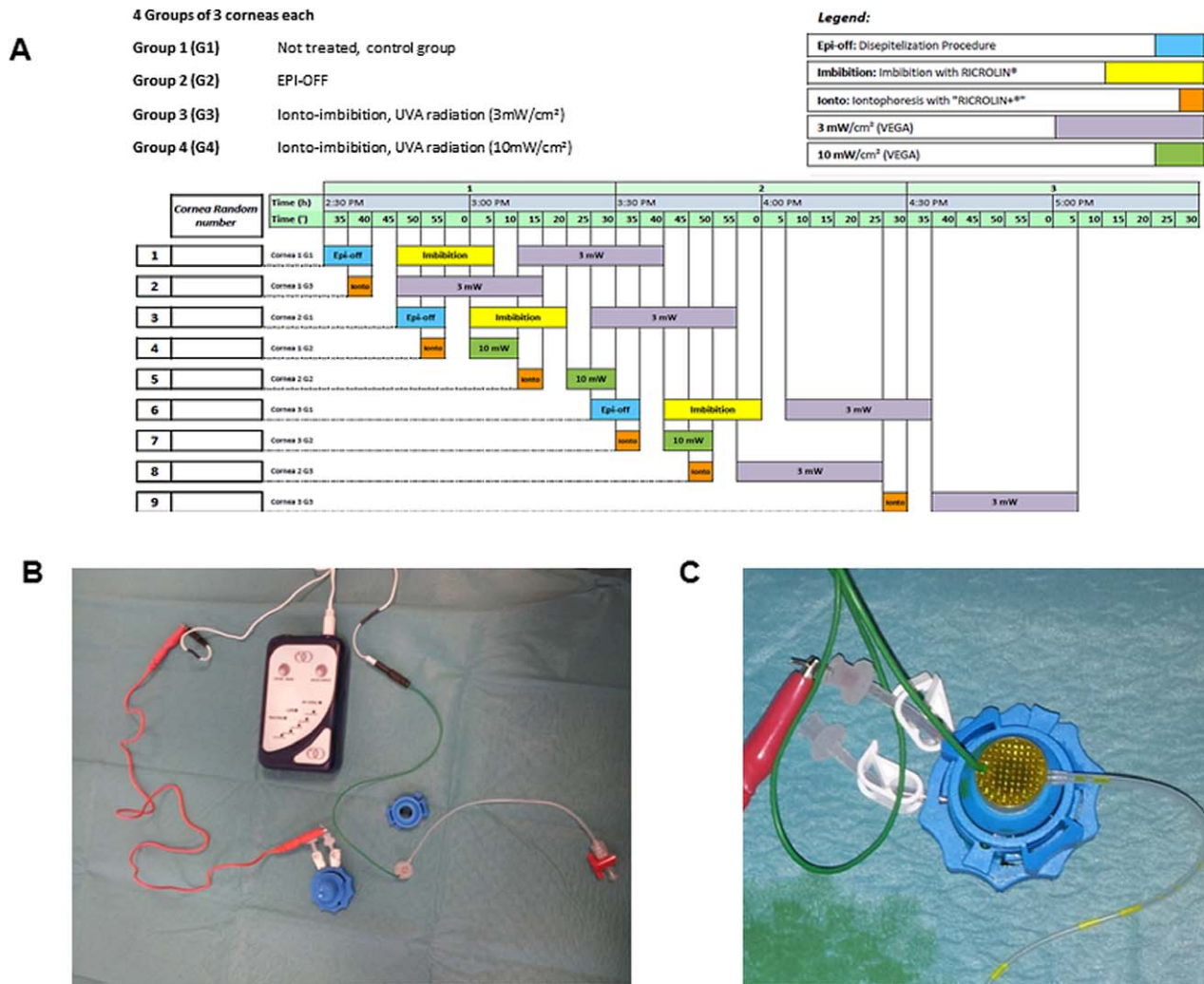


FIGURE 1. (A) Study design. (B) Representative image of the electric circuit used for iontophoresis imbibition. (C) Cadaver cornea mounted on artificial anterior chamber for iontophoresis imbibition: the corneal applicator is filled with riboflavin up to the steel grate (negative pole of the circuit).

**MATERIALS AND METHODS**

**Sample Preparation**

This study conformed to the tenets of the Declaration of Helsinki. The study design is described in Figure 1A. A total of 12 human cadaver corneas was examined. The mean storage time between eye bank procedures and crosslinking imbibitions was 52 hours (range, 24–96 hours). Corneas were randomized in 4 groups as follows: 3 untreated corneas served as controls (group 1), 3 corneas were treated with standard epi-off technique following the procedure described previously<sup>23</sup> (group 2), and 6 corneas underwent iontophoresis imbibition lasting 5 minutes with a hypoosmolar riboflavin 0.1% dextran-free solution enriched with trometamol EDTA (Ricrolin +; SOOFT, Montegiorgio, Italy). Of the later six corneas, 3 (group 3) subsequently were irradiated for 30 minutes with 3 mW UVA (VEGA 3 mW; C.S.O. Srl, Firenze Italy), and 3 (group 4) were treated for 9 minutes at 10 mW UVA (Vega 10 mW; C.S.O. Srl). Tissue procurement and use was carried out in accordance with local regulations. All corneas were mounted on a disposable artificial anterior chamber (Katena Products, Inc., Denville, NJ, USA) equipped

with a syringe filled with an eusol solution used to maintain positive pressure, and with a steel wire that acted as the positive pole of the circuit that connected one end to the anterior chamber to a current generator system (I-ON CXL; SOOFT) that permitted automated setting of treatment duration and intensity (5 minutes, 1 mA). The same generator connected by another cable to a steel electrode grid inserted in a special corneal applicator (Iontofor CXL; SOOFT) that acted as the negative pole of the circuit (Fig. 1B). The stability of the applicator on the corneal surface was guaranteed by a system of vacuum aspiration. The applicator was filled with riboflavin to cover the steel grate (Fig. 1C). Before starting the imbibition, the emission intensity of electrical continuous current was evaluated using a suitable digital tester and fixed to 1 mA ± 5%.

Before and after treatment, all samples underwent measurement of corneal deformation amplitude index (DAI) with an Ultra High-Speed Scheimpflug noncontact air pulse tonometer (Corvis ST; Oculus, Wetzlar, Germany). The measurement was acquired mounting the artificial anterior chamber on a dedicated support while maintaining an anterior chamber pressure of 10 to 18 mm Hg. The final measurement was a mean of 5 acquisitions. The DAI is a repeatable and reproducible

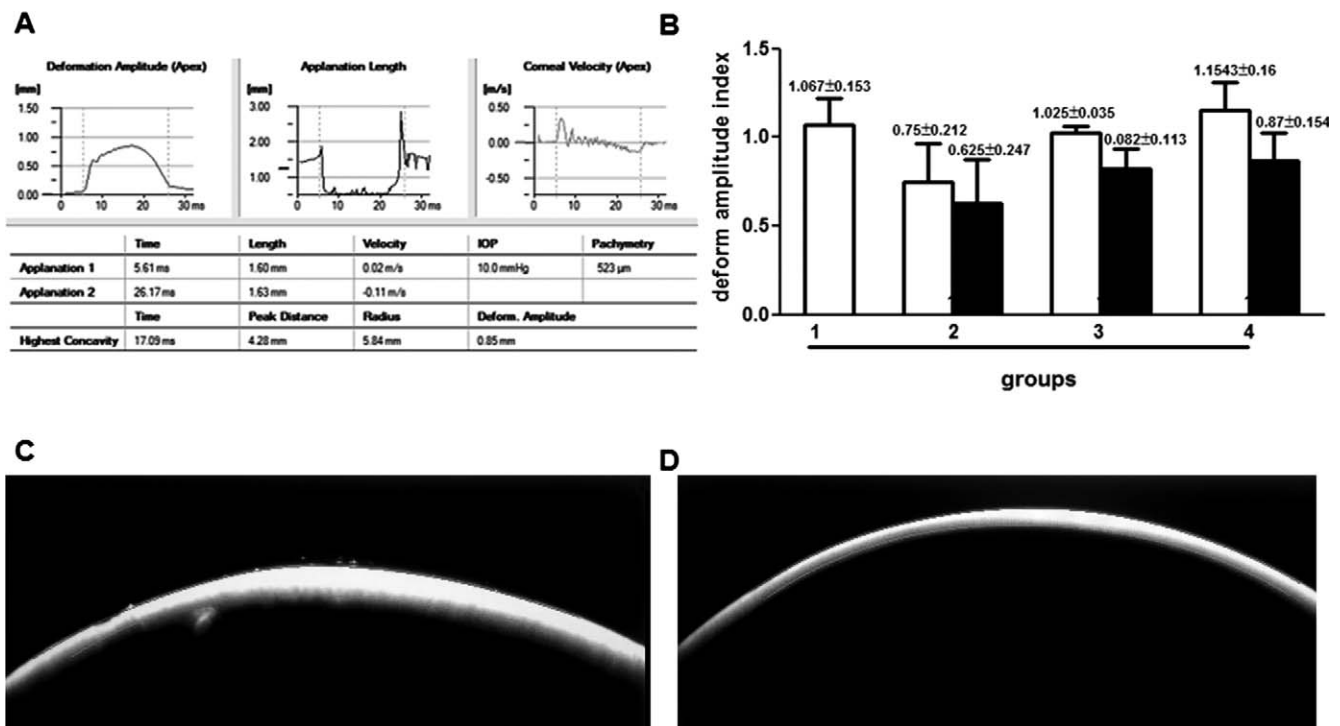


FIGURE 2. (A) Example of results obtained with CORVIS: the “Deform. Amplitude” (*bottom right*) represents an index of corneal maximum deformation amplitude at corneal apex. (B) Variation of Deformation Amplitude Index among groups between untreated (*white columns*) and treated (*black columns*) values. Data are expressed as mean  $\pm$  SD. No statistically significant difference was observed between untreated corneas of each group. After different CXL procedures no significant variation of DAI was observed. (C, D) Representative images obtained with CORVIS of the same cornea before (C) and after (D) treatment.

measurement,<sup>24</sup> defined as the highest concavity displacement of the corneal apex, and is an indirect measurement of corneal biomechanical resistance (Fig. 2A, 2C, 2D).

Immediately after CXL treatment, corneas were prepared for hematoxylin and eosin, and immunohistochemistry evaluation.

### Immunohistochemistry

Formalin-fixed, paraffin-embedded serial tissue sections were cut into 4- $\mu$ m thick slices and peroxidase activity was inhibited by immersing the slides in 3% hydrogen peroxide aqueous solution for 5 minutes. Each sample was stained for the following antibodies: CD34 (1:70, order number ab81289; Abcam, Cambridge, UK), matrix metalloproteinase-1 (MMP-1, 1:50, order number ab52631; Abcam), collagen type I (1:50, order number SAB4500363; Sigma-Aldrich, St. Louis, MO, USA), and Apo bromodeoxyuridine (BrdU) in situ DNA fragmentation assay kit (TUNEL, according to manufactured instruction, code K403-50; BioVision, Inc., Milpitas, CA, USA). Tissue samples were deparaffinized, pretreated by microwave antigen retrieval using buffer EDTA pH9 (required for MMP-1). For all these antigens, the En Vision system (Dako, Milano, Italy) was used before diaminobenzidine tetrahydrochloride (Dako) incubation. A negative control was performed for each antigen using the specific isotype control. All slides were stained for the same antigen together with the same antigen retrieval buffer, if required, and antibody dilution.

### Evaluation of Immunoreactivity

Results were evaluated independently by two investigators in a masked fashion. Three  $\times 200$  fields covering almost the whole sample were examined and the positive cells or positive areas were evaluated.

### Image and Statistical Analysis

Adobe Photoshop program (Adobe Systems, Inc., San Jose, CA, USA) as described previously<sup>21,22</sup> was used to evaluate total and positive pixels for cytoplasmic staining (MMP-1, collagen type I, and CD34). For nuclear staining (TUNEL) the same software was used to count keratocytes manually to obtain number of positive cells per area.<sup>22</sup> A nonparametric test (Mann-Whitney) was used to evaluate between-group differences in the mean levels of marker expression for selected antigens (GraphPad Prism 5; GraphPad Software, Inc., San Diego, CA, USA). Probabilities of less than 0.05 ( $P < 0.05$ ) were considered statistically significant.

## RESULTS

### Biomechanical Resistance Study

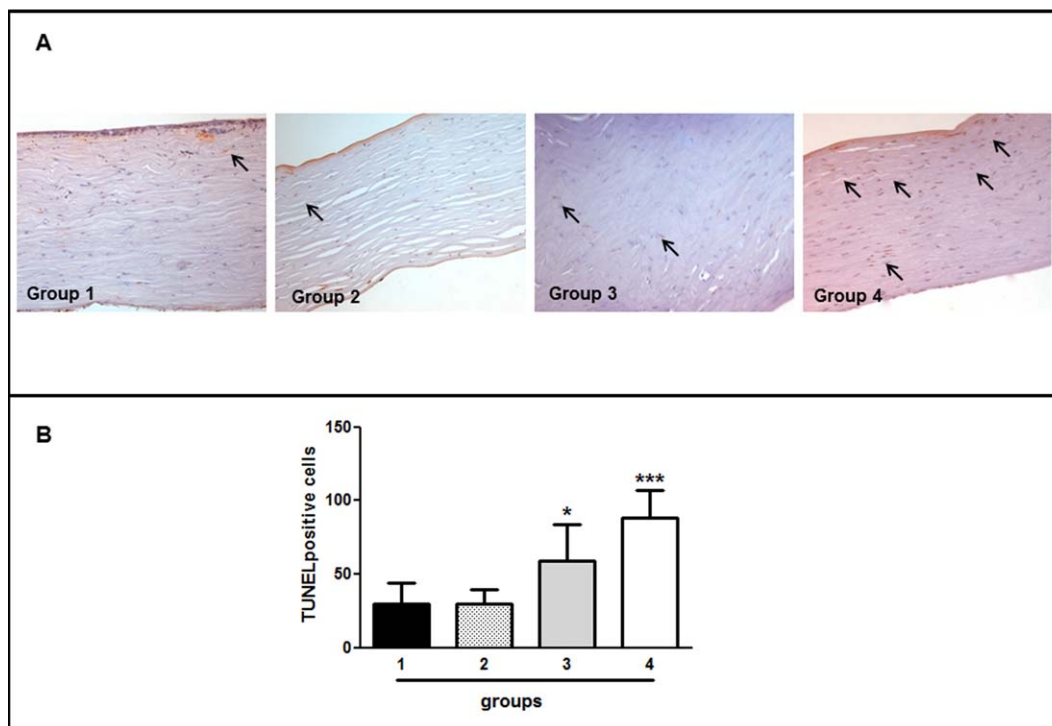
The results of the biomechanical resistance study are summarized in Figure 2B. No statistical difference between corneas of each group was recorded preoperatively in DAI measurements.

The Corvis DAI decreased in all postoperative tests in all groups. The greatest decrease was observed in group 4, suggesting a more effective improvement of corneal biomechanical resistance in corneas treated with iontophoresis imbibition and irradiation at 10 mW lasting 9 minutes.

### Morphologic Evaluation

Morphologic evaluation of corneal modification induced by different CXL procedures was performed analyzing hematoxylin and eosin-stained samples (not shown). An evident alteration of normal collagen architecture was observed in all





**FIGURE 3.** (A) Assessment of TUNEL-positive cells (arrows) in the experimental groups evaluated with immunohistochemistry. The images are representative of a single experiment. Each section was counterstained with hematoxylin ( $\times 400$ ). (B) Statistical analysis of data obtained from different samples. TUNEL-positive cells were identified by counting the number of cells showing an intense immune-labeling in three  $\times 200$  fields from each sample. Data are expressed as mean  $\pm$  SD. The Mann-Whitney test was used to evaluate between-group differences in the mean levels of marker expression. \* $P = 0.0337$ , \*\*\* $P = 0.0004$  versus control.

corneas treated with standard epi-off procedure (group 2). Normal orientation and definition of collagen lamellae was lost, and a diffuse suffusion of stromal edema was present mainly in anterior and middle stroma.

Group 3 showed marked signs of epithelial damage and edema infiltration in the anterior stroma that was less evident than that described for group 2.

Group 4 did not show epithelial alteration, and stromal collagen conserved the normal orientation and structure.

The apoptotic cells, evaluated with TUNEL assay, were distributed in the stroma of treated corneas. We observed a similar number of positive cells in controls and group 2 (Fig. 3A), in contrast to the significant increase observed in groups 3 ( $P = 0.0337$ ) and 4 ( $P = 0.0004$ ) (Fig. 3B), suggesting that treatment with iontophoresis imbition increases keratocyte apoptosis.

To evaluate corneal degradation and thinning induced by iontophoresis treatment, quantification of MMP-1 expression was done (Fig. 4A). We observed a significantly higher expression of MMP-1 in group 4 compared to untreated corneas ( $P = 0.0238$ ). No differences were observed between group 1, and groups 2 and 3 (Fig. 4B). These results suggested that the treatment with iontophoresis and irradiation at 10 mW was able to stimulate significantly stromal fibroblasts and corneal remodeling for reestablishing a normal cornea.<sup>25</sup>

To analyze the collagen fiber diameter, immunohistochemical staining with anticollagen type I antibody was done (Fig. 5A). The statistically significant increase in collagen fiber thickness in both iontophoresis imbition groups (group 3,  $P = 0.0018$  and group 4,  $P = 0.0018$ ; versus control, Fig. 5B) suggested that these treatments affected the mechanical properties of corneal collagen tissue.

The CD34 staining was used to study the stromal keratocytes of cornea and showed the presence of these cells

in the entire thickness of the cornea (Fig. 6A). A statistically significant increase of CD34 was observed in groups 2 ( $P = 0.0028$ ) and 3 ( $P = 0.0028$ ) compared to normal controls. On the other hand, a significant difference was not observed for group 4 (Fig. 6B). This result suggested that a reestablishing of the normal corneal structure can be obtained with iontophoresis imbition and irradiation at 10 mW.

## DISCUSSION

It has been reported that a sufficient concentration of riboflavin in corneal stroma was essential to obtain a biomechanical effect of corneal CXL.<sup>26</sup> It is known that intact epithelium constituted a diffusion barrier for riboflavin<sup>27</sup>; therefore, in traditional CXL protocol corneal epithelium must be removed before the application of drug solution. However, preserving the corneal epithelial layer can represent an important clinical advantage because it would reduce intraoperative and postoperative pain, possibly avoid the need of a therapeutic contact lens, and reduce infection-related complications and the risk of loss of corneal transparency due to abnormal scarring processes.<sup>13,28</sup> The possibility of performing transepithelial treatments has been introduced recently to clinical practice to obtain these advantages.<sup>29,30</sup> The penetration of riboflavin through the epithelium can be increased by different strategies, including increasing contact time, the intercellular permeability, or altering physicochemical properties of the riboflavin solution.<sup>20</sup> It was shown recently that during a 5-minute iontophoresis imbition, a sufficient riboflavin concentration can be obtained in the stroma for CXL treatment, thus combining the advantage of preserving epithelium integrity while shortening treatment time.<sup>20</sup>

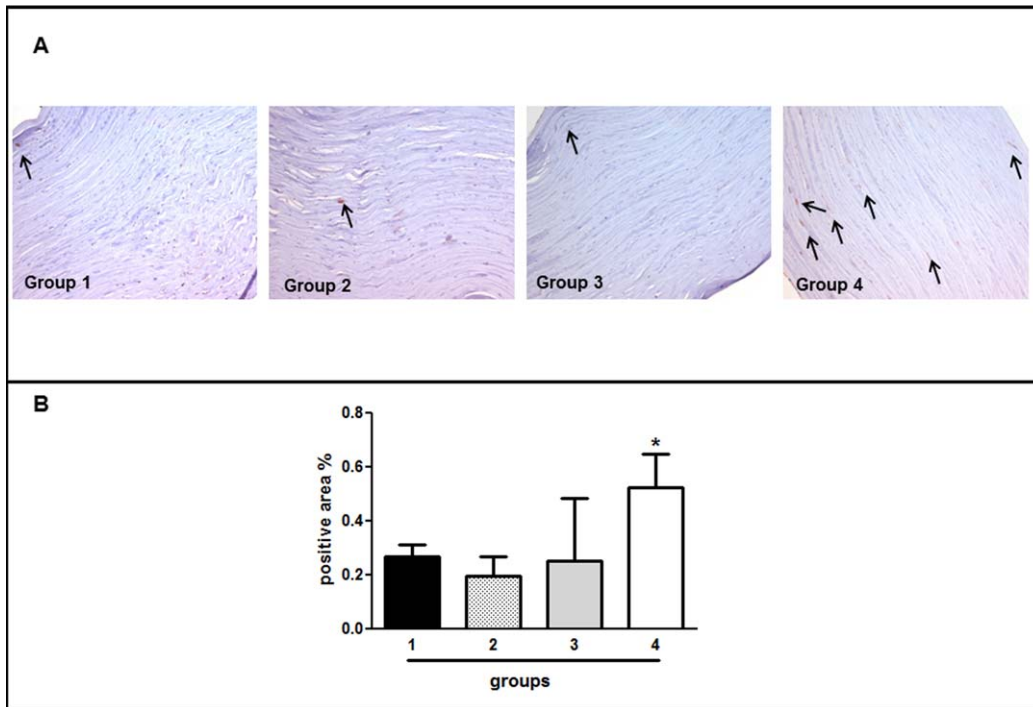


FIGURE 4. (A) Expression of MMP-1 (arrows) in experimental groups evaluated by immunohistochemistry. A significant expression of MMP-1 was observed in corneas of group 4, while the percentage of positive areas in the second and third groups are similar to the control. Hematoxylin counterstained ( $\times 200$ ). (B) Computer-quantification of MMP-1 staining using Adobe Photoshop software in three fields ( $\times 200$ ) for each sample. The Mann-Whitney test was used to evaluate between-group differences in the mean levels of marker expression. \* $P = 0.0238$  versus control.

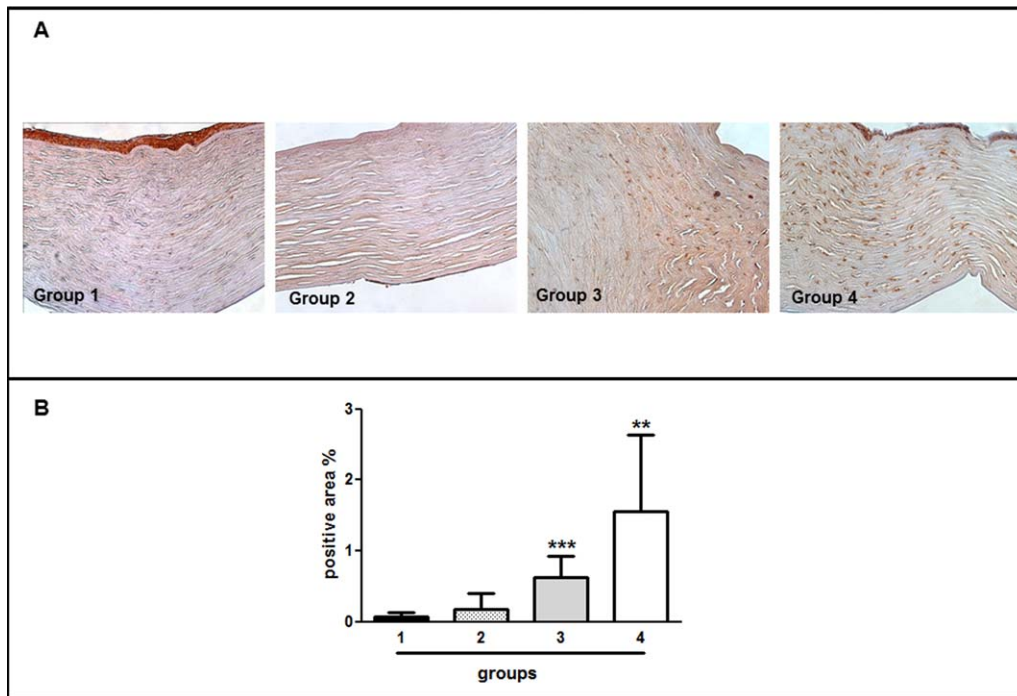
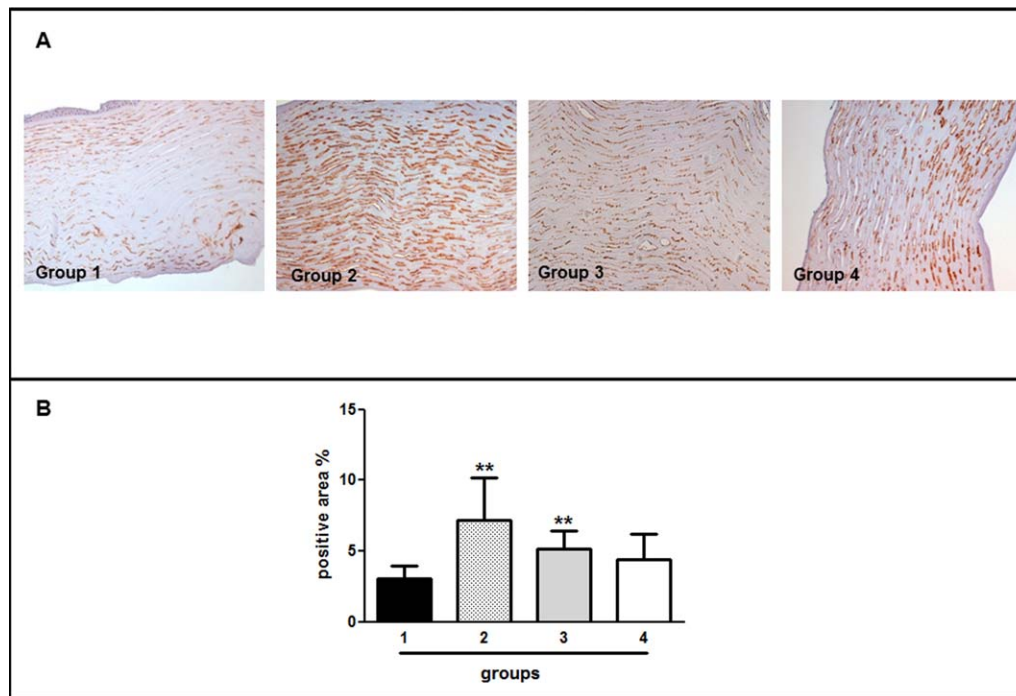


FIGURE 5. (A) Immunohistochemistry evaluation of collagen type I expression in experimental groups. A strong expression of collagen type I was observed in group 4. Hematoxylin counterstained ( $\times 200$ ). (B) Computer-assisted quantification of fiber size using Adobe Photoshop in three fields ( $\times 200$ ) for each sample. The Mann-Whitney test was used to evaluate between-group differences in the mean levels of marker expression. \*\* $P$  and \*\*\* $P = 0.0018$  versus control.



**FIGURE 6.** (A) CD34 expression in experimental groups detected in keratocytes of the entire corneal stroma observed with immunohistochemistry. In group 4 CD34-positivity is lost in small areas that are most frequently located in the anterior stroma. Hematoxylin counterstained ( $\times 200$ ). (B) Computer-assisted quantification of CD34 staining using Adobe Photoshop in three fields ( $\times 200$ ) for each sample. The Mann-Whitney test was used to evaluate between-group differences in the mean levels of marker expression. \*\* $P = 0.0028$  versus control.

In this study the real effect of different CXL procedures was investigated in terms of changes in corneal biomechanical properties and tissue modifications induced by treatment.

The Corvis ST is a new clinical instrument for corneal deformation assessment using an ultra high-speed Scheimpflug technology incorporated in a noncontact tonometer. The few first reports presented in the literature show a very good repeatability of IOP and central corneal thickness measured by this device, while discordant results were reported for the DAI and the first A-time applanation.<sup>24,31,32</sup> The DAI is a repeatable parameter that evaluates corneal elasticity and resistance by analyzing dynamic morphologic modifications in response to a mechanical pressure stimulus.<sup>24</sup> The measurement of DAI was performed in treated corneas and preoperative values were comparable in each groups. The results showed a reduction of DAI in all groups after CXL treatment, indicating an increase of corneal biomechanical rigidity in all treated corneas. This trend of reduction was more evident in corneas treated with iontophoretic imbibition and 9 minutes of 10 mW irradiation, even if this difference was not statistically significant.

A previous ex vivo study on porcine corneas<sup>33</sup> showed, in corneas stored in different medium, that hydration and preservation change corneal biomechanics, in particular its relaxation over a period of 24 hours. Our corneas were stored in the same medium, so this influence is not dissimilar among the groups. After treatment, stromal edema was particularly evident in group 2. This element may explain the unexpected result of a lower improvement of corneal rigidity in epi-off CXL that theoretically is related with a higher rate of riboflavin penetration.<sup>27</sup> Moreover, it's already known that corneal curvature and thickness affect corneal rigidity,<sup>34</sup> but possible preoperative differences among our samples were not as important to generate a significant difference of DAI in experimental groups. The poor and not significant differences observed after CXL treatment are so likely related to the

procedure. However, the smallness of the groups, the variation of IOP among the acquisitions, and differences in corneal characteristics or storage procedures affect the reliability of the reported results.

These preliminary results suggested that CXL treatment was effective in improving corneal biomechanical resistance to ectatic processes, but this finding must be confirmed in a larger number of samples. Moreover, it will be extremely interesting to evaluate if these differences also will be observed in vivo with DAI evaluation.

Morphologic analysis of corneas treated with standard procedure shows an evident damage to stromal structure with significant alteration of normal fiber architecture and presence of edema. These results were in accordance with in vivo findings using confocal microscopy that revealed an evident inflammatory response after traditional treatment.<sup>35</sup> In group 3 epithelial damage was observed, while in group 4 alterations in corneal morphology were not found, suggesting that epithelial damage was caused mainly by the irradiation procedure, the only difference between the two groups. However, the integrity and permeability of corneal epithelium are affected by the storage time that could have influenced the results obtained in groups 3 and 4.

Previous studies on rabbit corneas<sup>26,36</sup> demonstrated that riboflavin/UVA crosslinking leads to a dose-dependent damage with keratocyte apoptosis, probably due to accumulation of oxygen species.<sup>36</sup> Keratocyte apoptosis was massive when analyzed 24 hours after treatment followed by a gradual repopulation process of the anterior corneal stroma.<sup>36</sup> These results were confirmed in human corneas treated with traditional CXL, in which an overexpression of TUNEL and ki67 was observed, indicating that CXL treatment stimulated keratocytes apoptosis and repopulation.<sup>21</sup> Our study in human specimens showed a more evident keratinocytes apoptosis in CXL treatment with iontophoresis imbibition and, in particular,



after the irradiation at 10 mW. It is known that keratoconus is a noninflammatory ectasia of the cornea with documented changes of the corneal epithelial basement membrane, in extracellular matrix components, in keratocyte morphology, of cell-matrix interactions, and in stromal collagen composition, distribution, and organization (that can lead to lamellar and/or fibrillar slippage). However, the underlying pathologic mechanisms still are poorly understood. It was suggested that corneal degradation and thinning in keratoconus are caused mainly by MMPs. In normal cornea, MMP-1 was seen only in some of the epithelial cells, which were weakly positive, indicating a relatively low level of expression.<sup>25</sup> In keratoconus, MMP-1 was seen in a larger proportion of epithelial cells and staining was relatively intense.<sup>25</sup> To the best of our knowledge, for the first time the expression of MMP-1 was investigated in human corneas after CXL treatment. We observed an upregulation of this marker only in group 4, probably due to matrix remodeling induced by the specific treatment. We observed this effect immediately after the procedure and it would be interesting to analyze if the level of MMP-1 decreased over time.

Mencucci et al.<sup>21</sup> noticed a statistically significant increase in corneal collagen fiber diameter in the anterior stroma in traditional CXL-treated corneas, probably due to the physical CXL action. This indicated the increased biomechanical stiffness of the cornea after the treatment. In groups 3 and 4 analyzed immediately after treatment, we observed the same increase of collagen type I expression that already was described for corneas 6 months after therapy.<sup>21</sup> These preliminary data suggest that iontophoresis imbibition led to reshaping of collagen fibers with increased resistance to ectatic processes.

The stem cell marker CD34 is expressed strongly by human corneal keratocytes.<sup>37</sup> It was supposed that CD34 has a role in cytoadhesion and signaling related to differentiation and proliferation.<sup>38</sup> Interestingly, the treatment with iontophoresis imbibition and irradiation at 10 mW was able to reduce the number of CD34-positive cells that became similar to the one present in control corneas. According to data obtained by Mencucci et al.,<sup>21</sup> in human cornea the apoptotic keratocytes may be replaced by precursor cells that may be activated by specific stimuli and that can readily respond to regenerate native corneal stroma, thus, restoring transparency.

Our data on iontophoresis imbibition and 10 mW irradiation lasting 9 minutes showed that this procedure is likely able to reestablish a close to normal structure of corneal stroma. To the best of our knowledge this study represents the first report of early corneal modifications after CXL with iontophoretic imbibition and investigates differences among surgical procedures; in fact, to our knowledge the only two studies about iontophoresis imbibition and corneal CXL already published in the literature concern clinical parameters<sup>39</sup> and quantification of riboflavin penetration after different imbibition strategies.<sup>40</sup>

However, in this study specimens were analyzed immediately after the treatment, and we observed the same positivity grade with a good replicate in three different corneas per group, collected at the same time after death. Probably, this finding is the result of a tissue modification that occurs during and immediately after the procedure. Of course, it will be of interest to analyze in vivo differences in long-term corneal response that can be related to the efficacy of each CXL procedure to set up the best method for clinic routine.

### Acknowledgments

The authors thank Giulio Luciani for the collaboration in the study design.

Supported by Progetto Obiettivo Regione Abruzzo.

Disclosure: **L. Mastropasqua**, None; **M. Lanzini**, None; **C. Curcio**, None; **R. Calienno**, None; **R. Mastropasqua**, None; **M. Colasante**, None; **A. Mastropasqua**, None; **M. Nubile**, None

### References

- Prasad R, Koul V. Transdermal delivery of methotrexate: past, present and future prospects. *Ther Deliv*. 2012;3:315-325.
- Dubinsky RM, Kabbani H, El-Chami Z, Boutwell C, Ali H. Practice parameter: treatment of post-herpetic neuralgia: an evidence-based report of the Quality Standards Subcommittee of the American Academy of Neurology. *Neurology*. 2004;63:959-965.
- Gomez I, Szabò A, Pap L, Boda K, Szekecz Z. In vivo calcium and phosphate iontophoresis for the topical treatment of osteoporosis. *Phys Ther*. 2012;92:289-297.
- Gaudana R, Ananthula HK, Parenky A, Mitra AK. Ocular drug delivery. *AAPS J*. 2010;12:348-360.
- Frucht-Pery J, Raiskup F, Mechoulam H, Shapiro M, Eljarrat-Binstock M, Domb A. Iontophoretic treatment of experimental pseudomonas keratitis in rabbit eyes using gentamicin-loaded hydrogels. *Cornea*. 2006;25:1182-1186.
- Jiang J, Gill HS, Ghate D, et al. Coated microneedles for drug delivery to the eye. *Invest Ophthalmol Vis Sci*. 2007;48:4038-4043.
- Yasukawa T, Ogura Y, Tabata Y, Kimura H, Wiedemann P, Honda Y. Drug delivery systems for vitreoretinal disease. *Prog Retin Eye Res*. 2004;23:253-281.
- Vinciguerra P, Rechichi M, Rosetta P, et al. High fluence iontophoretic corneal collagen crosslinking: in vivo OCT imaging of riboflavin penetration. *J Refract Surg*. 2013;29:376-377.
- Wollensak G, Spoerl E, Seiler T. Riboflavin/ultraviolet A-induced collagen crosslinking for the treatment of keratoconus. *Am J Ophthalmol*. 2003;135:620-627.
- Henriquez MA, Izquierdo L, Bernilla C, et al. Riboflavin/ultraviolet A corneal collagen crosslinking for the treatment of keratoconus: visual outcomes and Scheimpflug analysis. *Cornea*. 2011;30:281-286.
- Spoerl E, Huhle M, Seiler T. Induction of crosslinks in corneal tissue. *Exp Eye Res*. 1998;66:97-103.
- Kohlhaas M, Spoerl E, Schilde T, et al. Biomechanical evidence of the distribution of crosslinks in corneas treated with riboflavin and ultraviolet A light. *J Cataract Refract Surg*. 2006;32:279-283.
- Abdelghaffar W, Hantera M, Elsabagh H. Corneal collagen crosslinking: promises and problems. *Br J Ophthalmol*. 2010;94:1559-1560.
- Koller T, Iseli HP, Hafezi F, et al. Scheimpflug imaging of corneas after collagen crosslinking. *Cornea*. 2009;28:510-515.
- Richoz O, Mavranakas N, Pajic B, Hafezi F. Corneal collagen crosslinking for ectasia after LASIK and photorefractive keratectomy: long term results. *Ophthalmology*. 2013;120:1354-1359.
- Makdoui K, Mortensen J, Crafoord S. Infectious keratitis treated with corneal crosslinking. *Cornea*. 2010;29:1353-1358.
- Ghanem RC, Santhiago MR, Berti TB, Thomaz S, Netto MV. Collagen crosslinking with riboflavin and ultraviolet-A in eyes with pseudophakic bullous keratopathy. *J Cataract Refract Surg*. 2010;36:273-276.
- Ehlers N, Hjortdal J, Nielsen K, et al. Riboflavin UVA treatment in the management of edema and non healing ulcers of the cornea. *J Refract Surg*. 2009;25:S803-S806.



19. Abdelghaffar W, Hantera M, Elsabagh H. Corneal collagen crosslinking: promises and problems. *Br J Ophthalmol*. 2010;94:1559-1560.
20. Raskup F, Spoerl E. Corneal crosslinking with riboflavin and ultraviolet A. I. Principles. *Ocul Surf*. 2013;11:65-74.
21. Mencucci R, Marini M, Paladini I, et al. Effects of riboflavin/UVA corneal crosslinking on keratocytes and collagen fibres in human cornea. *Clin Exp Ophthalmol*. 2010;38:49-56.
22. Messmer EM, Meyer P, Herwig MC, et al. Morphological and immunohistochemical changes after corneal crosslinking. *Cornea*. 2013;32:111-117.
23. Hashemi H, Seyedian MA, MirafTAB M, Fotouhi A, Asgari S. Corneal collagen crosslinking with riboflavin and ultraviolet A irradiation for keratoconus: long-term results. *Ophthalmology*. 2013;120:1515-1520.
24. Hon Y, Lam AK. Corneal deformation measurement using Scheimpflug noncontact tonometry. *Optom Vis Sci*. 2013;90:1-8.
25. Seppälä HP, Määttä M, Rautia M, et al. EMMPRIN and MMP-1 in keratoconus. *Cornea*. 2006;25:325-330.
26. Wollensak G, Spoerl E, Wilsch M, Seiler T. Endothelial cell damage after riboflavin- ultraviolet-A treatment in the rabbit. *J Cataract Refract Surg*. 2003;29:1786-1790.
27. Baiocchi S, Mazzotta C, Cerretani D, Caporossi T, Caporossi A. Corneal crosslinking: riboflavin concentration in corneal stroma exposed with and without epithelium. *J Cataract Refract Surg*. 2009;35:893-899.
28. Ashwin PT, McDonnell PJ. Collagen crosslinkage: a comprehensive review and directions for future research. *Br J Ophthalmol*. 2010;94:965-970.
29. Filippello M, Stagni E, O'Brart D. Transepithelial corneal collagen crosslinking: bilateral study. *J Cataract Refract Surg*. 2012;38:283-291.
30. Salman AG. Transepithelial corneal collagen crosslinking for progressive keratoconus in a pediatric age group. *J Cataract Refract Surg*. 2013;39:1164-1170.
31. Nemeth G, Hassan Z, Csutak A, Szalai E, Berta A, Modis L Jr. Repeatability of ocular biomechanical data measurements with a Scheimpflug-based noncontact device on normal corneas. *J Refract Surg*. 2013;29:558-563.
32. Reznicek L, Muth D, Kampik A, Neubauer AS, Hirneiss C. Evaluation of a novel Scheimpflug-based non-contact tonometer in healthy subjects and patients with ocular hypertension and glaucoma. *Br J Ophthalmol*. 2013;97:1410-1414.
33. Kling S, Marcos S. Effect of hydration state and storage media on corneal biomechanical response from in vitro inflation tests. *Refract Surg*. 2013;29:490-497.
34. Beshtawi IM, O'Donnell C, Radhakrishnan H. Biomechanical properties of corneal tissue after ultraviolet-A-riboflavin crosslinking. *J Cataract Refract Surg*. 2013;39:451-462.
35. Mastropasqua L, Nubile M, Lanzini M, et al. Morphological modification of the cornea after standard and transepithelial corneal crosslinking as imaged by anterior segment optical coherence tomography and laser scanning in vivo confocal microscopy. *Cornea*. 2013;32:855-861.
36. Wollensak G, Spoerl E, Wilsch M, Seiler T. Keratocyte apoptosis after corneal collagen crosslinking using riboflavin/UVA treatment. *Cornea*. 2004;23:43-49.
37. Dua HS, Joseph A, Shanmuganathan VA, Jones RE. Stem cell differentiation and the effects of deficiency. *Eye (Lond)*. 2003;17:877-885.
38. Joseph A, Hossain P, Jham S, et al. Expression of CD34 and L-selectin on human corneal keratocytes. *Invest Ophthalmol Vis Sci*. 2003;44:4689-4692.
39. Bikbova G, Bikbov M. Transepithelial corneal collagen crosslinking by iontophoresis of riboflavin. *Acta Ophthalmol*. 2014;92:e30-e34.
40. Mastropasqua L, Nubile M, Calienno R, et al. Corneal crosslinking: Intrastromal riboflavin concentration in iontophoresis-assisted imbibition versus traditional and transepithelial techniques. *Am J Ophthalmol*. 2014;157:623-630.