



Cortical Bone Trajectory Screw Placement Accuracy with a Patient-Matched 3-Dimensional Printed Guide in Lumbar Spinal Surgery: A Clinical Study

Nicola Marengo¹, Keitaro Matsukawa², Matteo Monticelli¹, Marco Ajello¹, Paolo Pacca¹, Fabio Cofano¹, Federica Penner¹, Francesco Zenga¹, Alessandro Ducati¹, Diego Garbossa¹

■ **BACKGROUND:** Cortical bone trajectory (CBT) screw is an attractive technique in terms of fixation strength and less invasiveness. However, the insertion of a pedicle screw penetrating cortical bone on the ideal trajectory is technically demanding. The use of 3-dimensional (3D) patient-matched guides may facilitate the use of this technique. In this technical note and case series, the use of a patient-matched 3D targeting guide for a circumferential fixation with CBT screws is described.

■ **METHODS:** Eleven patients with a mean age of 49 years were treated. The MySpine MC (Medacta International SA, Castel San Pietro, Switzerland) technology was used to place CBT screws. A computed tomography (CT) scan-derived 3D model of the patient vertebra was created after the surgeons planned the best custom CBT screw trajectory. Then, scaffolds were printed and used during surgery to guide the screw through the patient pedicle. An intersomatic arthrodesis was also performed.

■ **RESULTS:** The images of the planned trajectory were superimposed on the postoperative CT scan, confirming the accuracy of the trajectory. The mean deviation from the planned pedicle midpoint was 0.91 mm; 85.2% of the screws were placed within 2° from the planned trajectory. There were 2 grade A (<2 mm) and no grade B or C perforations. The actual entry point was always within 2 mm from the planned entry point.

■ **CONCLUSIONS:** This technical note and case series is the first clinical description on the use of a patient-matched guide for posterior CBT screw placement. The

use of these devices could also improve placement accuracy and decrease the risk of nerve damage.

INTRODUCTION

It is well known that degenerative spine surgery is highly demanding and requires effective precision to cause minimal damage to the surrounding tissues, especially with posterior approaches.¹⁻⁵ Significant developments and various advances have characterized the screw implantation technique in the past years.⁶⁻⁸ The cortical bone trajectory (CBT) technique has been developed to reduce the morbidity rate associated with the classic open posterior approach, such as soft tissue damage, maintaining the often indisputable necessity of a direct decompression.¹⁻³ First reported by Santoni et al.,⁴ CBT was conceived with the aim of maximizing the pullout strength in osteoporotic bones. Screws follow a mediolateral path in the axial plane and a caudocephalad path in the sagittal plane.⁴ The medial isthmic entry point, indeed, requires less muscular exposure and damage to the facet joints. Moreover, in contrast with conventional pedicle screw fixation, CBT screws do not penetrate the vertebral body trabecular space. According to the literature, bilateral cortical screw-rod fixation provides similar strength compared with traditional pedicle screws.⁵ Because of their favorable entry point, better bone purchase is achieved and less muscular dissection is required. Therefore, spine fusion surgeries performed with cortical screws are expected to reduce the rate of facet joint violation and achieve better short-term clinical outcomes. Regarding long-term outcomes, there has not been any validated data, but good expectations are generally

Key words

- 3D patient-matched guides
- CBT screws
- Lumbar spinal surgery
- Minimally invasive spinal surgery
- Navigation system
- Screws placement accuracy

Abbreviations and Acronyms

- 3D: 3-Dimensional
- CBT: Cortical bone trajectory
- CT: Computed tomography

From the ¹Department of Neuroscience, Neurosurgery Division, AOU Città della Salute e della Scienza, Torino, Italy; and ²Department of Orthopaedic Surgery, National Defense Medical College, Tokorozawa, Saitama, Japan

To whom correspondence should be addressed: Matteo Monticelli, M.D.
[E-mail: mmonticelli89@gmail.com]

Citation: *World Neurosurg.* (2019) 130:e98-e104.
<https://doi.org/10.1016/j.wneu.2019.05.241>

Journal homepage: www.journals.elsevier.com/world-neurosurgery

Available online: www.sciencedirect.com

1878-8750/\$ - see front matter © 2019 Elsevier Inc. All rights reserved.

Table 1. Patients Data

Patient Number	Age (years)	Level of Diskopathy	Modic Pfirrmann		Limb Affected	Motor Deficit	Sensitive Deficit
1	53	L4-5	II	IV	Right	Toe dorsiflexion weakness (3/5 MRC)	x
2	52	L4-5	II	IV	Right	Toe dorsiflexion weakness (4/5 MRC)	x
3	43	L4-5	II	IV	Right	Toe dorsiflexion weakness (4/5 MRC)	x
4	46	L4-5	II	IV	Left	Toe dorsiflexion weakness (4/5 MRC)	x
5	49	L4-5	II	IV	Right	Toe dorsiflexion weakness (4/5 MRC)	x
6	45	L5-S1	II	IV	Left	Low back pain with sciatalgic irradiation	x
7	57	L5-S1	II	IV	Right	Low back pain with sciatalgic irradiation	x
8	43	L4-5	II	IV	Left	Low back pain with sciatalgic irradiation, toe dorsiflexion weakness (3/5 MRC)	x
9	42	L5-S1	II	IV	Left	Low back pain with sciatalgic irradiation	x
10	55	L4-5	II	IV	Right	Low back pain with sciatalgic irradiation, toe dorsiflexion weakness (4/5 MRC)	x
11	56	L5-S1	II	IV	Right	Low back pain with sciatalgic irradiation	x

MODIC indicates Pathological changes in the bones of the spine (see Modic classification).
 X indicates presence of sensitive deficit.
 MRC, medical research council scale.

anticipated, as suggested by several studies.⁶⁻¹² Accurate screw placement in spinal surgery has always been a challenge for surgeons. Many technologies and useful tools have been developed in recent years, including fluoroscopy, navigation software, electrical conductivity-based systems, neuromonitoring, and custom-made template guides. In this technical note and case series, the use of a patient-matched 3-dimensional (3D) targeting guide for a circumferential posterior interbody fusion with CBT screws is described.

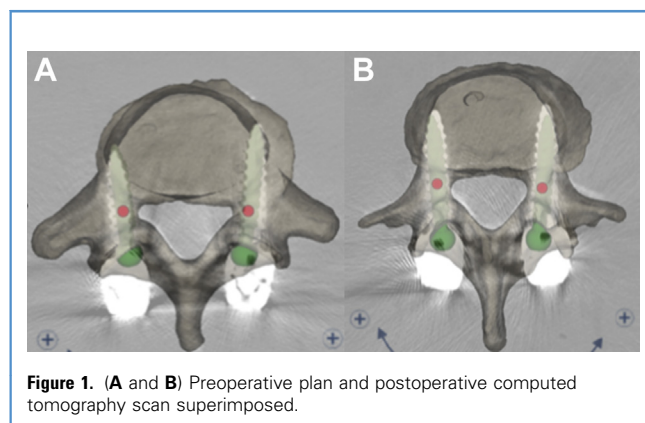
MATERIALS AND METHODS

Eleven patients with degenerative disease with a mean age of 49.18 years (Table 1) needed circumferential fixation surgery after conservative treatments failed. The MySpine MC (Medacta

International SA, Castel San Pietro, Switzerland) technology was used to place CBT screws. A computed tomography (CT) scan-derived 3D model of the patient that reproduced the posterior anatomy of the vertebra was also produced, allowing the surgeon to confirm the anatomic structures. The guide was used as a contact area. Then, scaffolds that fit exactly the vertebral surface were printed and used during surgery to guide the screw through the patient pedicle. An intersomatic arthrodesis with T-PAL (DePuy-Synthes GmbH, Oberdorf, Switzerland) was also performed. Accurate placement was evaluated by comparing the preoperative plan and postoperative placement superimposing plan images on the postoperative CT scan (Figure 1).

MySpine MC Technology Description

MySpine MC is a patient-matched pedicle targeted toward specific guides for implant placement, based on the patient's anatomy. Using this platform, it is possible to realize a 3D preoperative plan (Figure 2) based on the patient's spinal CT image acquisition, therefore assisting screw positioning with custom-made devices. CBT screws are then guided through the patient's anatomically matched guide. Planning requires active participation of the surgeon to choose the best trajectory in all planes and to select the most appropriate pedicle screw in accordance with the pedicle size and length. Specific protocol regarding CT imaging is used to create a 3D model of the vertebra according to the specific patient's anatomy. The subsequent vertebral model represents the template used to generate the corresponding scaffold to fit exactly the vertebral surface. Guides are designed to fully optimize bony contact on the lamina and part of the inferior articular process, to ensure an optimal fit. Then, a plastic 3D anatomic model reproducing the patient's vertebra is provided to simulate the correct



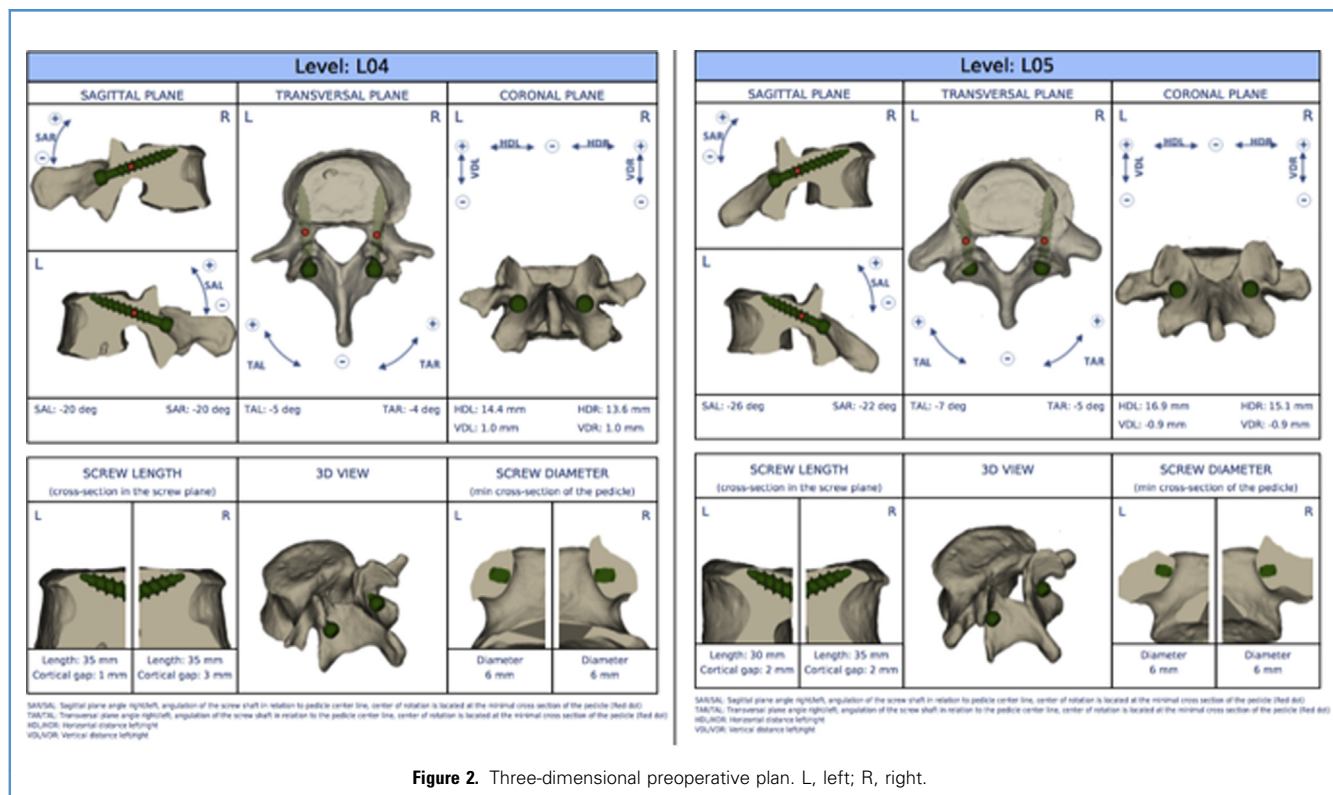


Figure 2. Three-dimensional preoperative plan. L, left; R, right.

positioning of the MySpine MC guides in the operating room (Figure 3).

Surgical Technique for L4-5 Circumferential Arthrodesis

After standard antibiotic prophylaxis, the patient, under general anesthesia, was placed in a prone position on an appropriate padded support to avoid increased intra-abdominal pressure. Skin preparation and sterile draping were done. The procedure was performed under continuous neuromonitoring and triggered electromyography to safely ensure screw placement.¹³

Under fluoroscopic guidance, the L4 spinous process was identified and a 5-cm skin incision was performed. Spinous processes and laminae of L4 and L5 vertebrae were exposed with preservation of the cranial facet joints. Subsequently, a size- and length-adapted self-retaining retractor with an integrated lighting system was positioned. The plastic guides were then placed on the corresponding vertebra and the contact surfaces checked to avoid any mismatch (Figure 4). The cortical bone was entered using a high-speed drill (Colibri II [DePuy-Synthes GmbH]) through the guide tubes. Drilling could be easily and safely performed up to the planned depth thanks to the stop mechanism provided by the guides (Figure 5). Then, guidewires were introduced into the pedicle and vertebral body, and undertapping (0.5 mm) was performed with a cannulated instrument. The ball tip feeler was used at every step to check the pedicle walls on both sides for possible violations, then smooth temporary shanks were placed to easily carry out the discectomy. Right laminectomy and

artrectomy were performed under direct visual control. Discectomy with end plate preparation was performed. A 28-mm length and 5° lordosis titanium kidney-shaped pivoting cage filled with morselized autologous bone graft was implanted (T-PAL). Three 6 × 35 mm and one 6 × 30 mm CBT screws (Medacta Unconstrained Screw Technology [Medacta International SA]) were then placed.

Thereafter, compression was applied to load the cage and increase lumbar lordosis. Proper positioning of the implants and alignment were finally verified on a biplanar fluoroscopy. After irrigation and hemostasis, the surgical site was sutured layer by layer. The total radiographic dose for the procedure was 0.53 mGy/cm². Fluoroscopy was used to verify the accuracy of the system in the first cases and then only for a final fluoroscopic control (Figure 6).

A CT scan and a standing lumbar radiograph were performed on the first postoperative day showing excellent screw placement, with all 4 screws falling into grade 0 according to the Rao et al. classification¹⁴ (Figure 7).

The postoperative clinical course was uneventful, and the patient referred to an improvement in her symptoms compared with baseline. On the first postoperative day, she was able to walk autonomously using a soft lumbar brace.

All patients were discharged from the hospital on the second postoperative day.

The patients showed an important clinical improvement without new neurologic deficits or radiologic pathologic findings at 6-month follow-up.

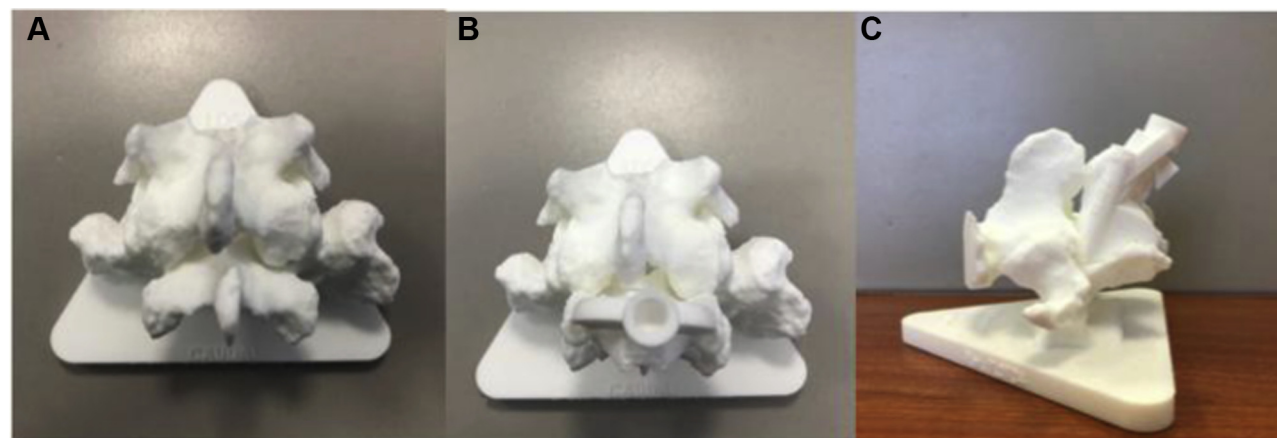


Figure 3. Plastic 3-dimensional anatomic model reproducing the patient's L5 vertebra: (A) L5 vertebra and (B and C) guides on [KG1] the L5 vertebra model.

RESULTS

Four screws for each patient were positioned; in total, 44 screws were placed.

A 3-D reconstruction of the vertebra, including the inserted screws, was created from a postoperative CT scan. The pre- and postoperative reconstructed vertebra was then superimposed, and any deviations of the screws from the planned parameters were measured. The placement accuracy was graded based on the degree of perforation of the pedicle by the pedicle screw using an acceptance criterion (no perforation, grade A [0–2 mm], grade B [2–4 mm], and grade C [>4 mm]).^{15,16} Grade B and C perforations were deemed unacceptable.

The mean deviation from the planned pedicle midpoint was 0.91 mm, and 85.2% of the screws were placed within 2° from the planned trajectory calculated in the axial plane as suggested by other authors.^{15,17} In a total of 44 screws, there were 2 grade A (<2 mm) (4%) and no grade B or C perforations. The actual

entry point was always within 2 mm from what was planned. The mean deviation between the planned and actual pedicle screw positions on the coronal plane at the midpoint of the pedicle was 0.6 mm. The mean angular deviation between the planned and actual screw positions in the sagittal plane was 1.7° , and the mean deviation in the transverse plane was 2.1° . The mean deviation in screw depth between the planned and actual screw positions was 0.2 mm.

All patients were discharged from the hospital on the second postoperative day. The patients showed significant clinical improvement without new neurological deficits or radiological pathological findings at the 6-month follow up.

DISCUSSION

During the last decade, several tools have been developed to improve safe screw positioning and accuracy such as and above

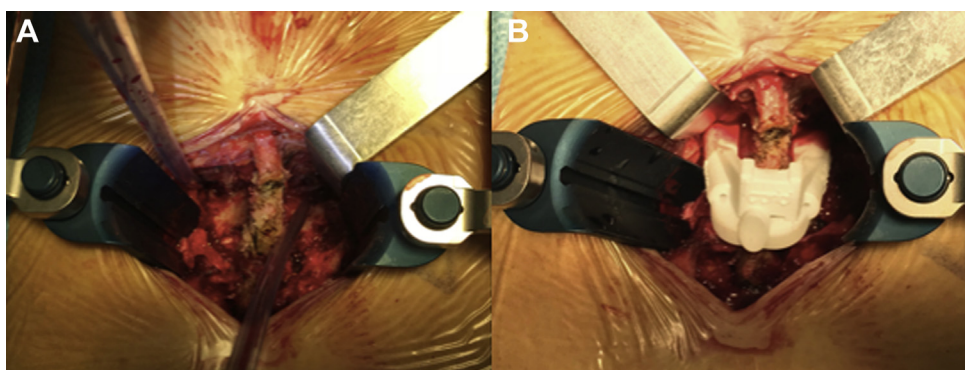


Figure 4. Intraoperative image of L4 (A) and intraoperative image of L4 with 3-dimensional guide placed (B).

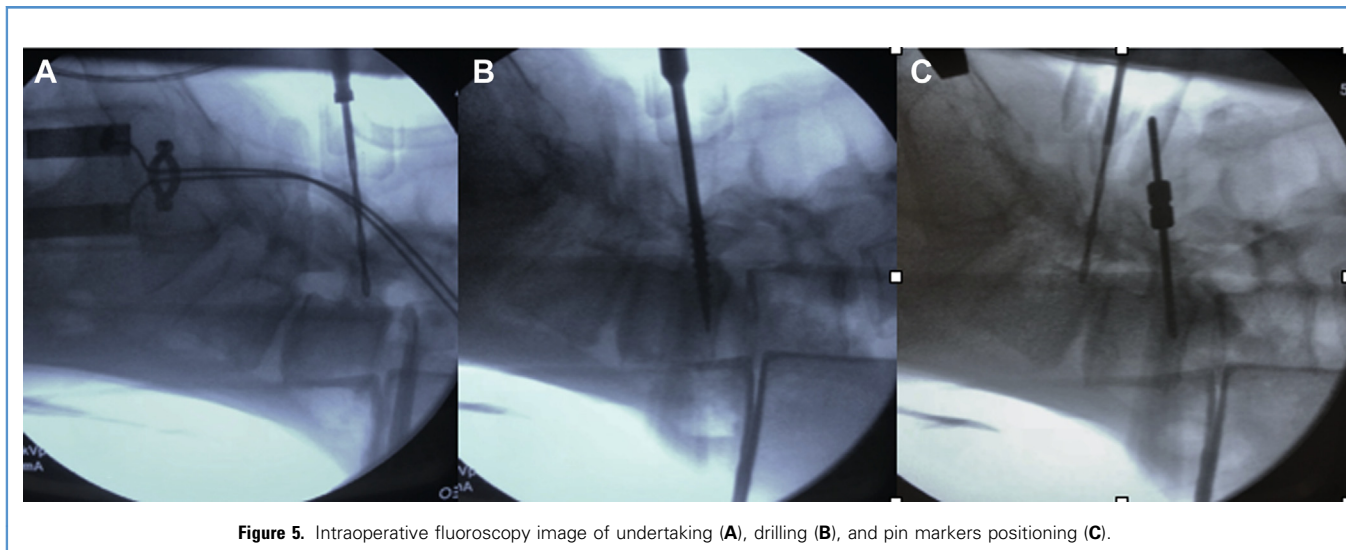


Figure 5. Intraoperative fluoroscopy image of undertaking (A), drilling (B), and pin markers positioning (C).

all, 3D navigation. This technology has advanced thanks to the high-speed software, which has evolved to integrate data. However, questions still remain about the advantages of using 3D navigation over the freehand fluoroscopy-assisted technique, especially considering costs and availability in spine centers. In particular, the costs are much less, both to purchase and maintain with respect to traditional navigation systems, such as intraoperative CT scan or intraoperative magnetic resonance imaging.¹⁸⁻²³

Radermacher et al.²⁴ first described, in 1998, a patient-specific template used as an in situ drill guide, designed with a preoperative CT scan. This tool was then further developed, which improved accuracy rates of pedicle screw insertion.²⁵⁻²⁸

Although some reports have revealed no clear differences comparing the freehand technique with the custom-made guide technique to implant pedicle screws,²³ the template guides have become a well-established and useful tool in spine deformity surgery^{29,30} after several cadaveric studies.³¹

In 2017, Farshad et al.³² compared time of instrumentation, accuracy, and radiation exposure between patient-specific template-guided and freehand fluoroscopically controlled pedicle screw placement in the thoracic and lumbar spine, assessing the superiority of template-guided positioning. A significantly higher pullout strength of thoracic-lumbar pedicle screws when inserted via a patient-specific tubular guide was found by Aichmair et al.,³³ and this potentially was associated with better screw trajectory. Moreover, Putzier et al.³⁰ conducted a pilot study proving that custom-made positioning guides are a feasible navigational tool that permit a safe and accurate implantation of pedicle screws in patients with severe scoliosis.

Compared with the traditional pedicle screws technique, CBT screw fixation allows muscle fibers to be well preserved and a diminished rate of facet joint violation. A better short-term clinical outcomes has been reported as well. Moreover, they have been demonstrated to have a superior fixation strength and good stiffness in flexion and extension.^{8,11,34-37}

This technical note and case series is, to our knowledge, the first clinical description on the use of a patient-matched guide for posterior CBT screw placement. Only cadaveric studies have existed until now.³⁸ The use of these devices for CBT fixation allows not only a customized plan, but could also improve placement accuracy and decrease the risk of nerve damage. The results demonstrate that cortical pedicle screw placement using 3D planning and a placement guide achieved an average deviation from the planned position at the midpoint of the pedicle of 0.6 mm, which is comparable with the accuracy achieved by traditional pedicle screw placement using a 3D patient-matched guide.³¹ In all parameters, the deviation

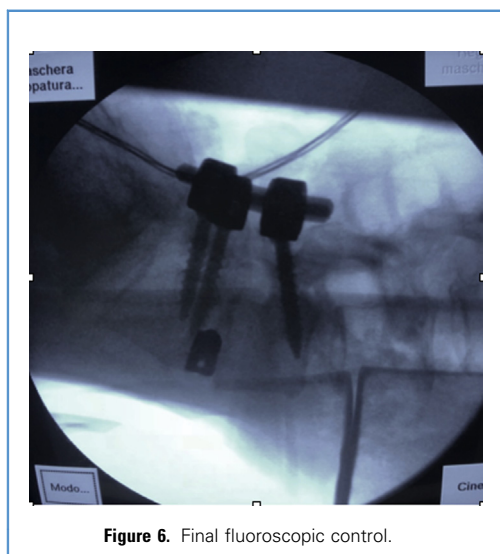


Figure 6. Final fluoroscopic control.

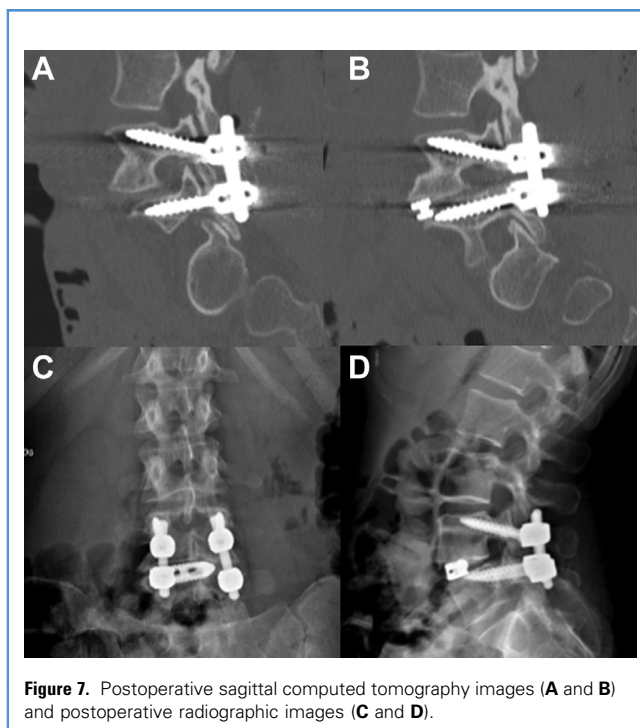


Figure 7. Postoperative sagittal computed tomography images (A and B) and postoperative radiographic images (C and D).

between the planned and actual screw positions were within the acceptance criteria. Furthermore, there were zero grade B or C

pedicle perforations, and 42 evaluated screws and pins were placed fully inside the pedicle. Another benefit is provided by the fact that the use of a guide can reduce the amount of radiation exposure.³⁹ Minimally invasive pedicle screw insertion techniques, including cortical bone and percutaneous pedicle screws, are usually accompanied with increased radiation exposure because visibility of anatomic structures is generally limited in the operative field.

Although the use of a guide cannot eliminate the use of an radiograph machine because it is necessary to secure the correct positioning of the guide, it can however significantly reduce its frequency of use during cortical bone screw insertion by shortening the time required to make the initial hole along the correct trajectory, which is the rate-controlling step during screw insertion.

CONCLUSIONS

This technical note and case series is, our knowledge, the first clinical description on the use of a patient-matched guide for posterior CBT screw placement. The use of these devices for CBT fixation allows not only a customized plan, but could also improve placement accuracy and decrease the risk of nerve damage. Furthermore, the need of fluoroscopy could potentially be set down to zero.

However, this a small series and despite the encouraging results, a greater number of patients are required to adequately comment on the accuracy, safety, and applicability of this technology and evaluate long-term outcomes.

REFERENCES

- Luther N, Iorgulescu JB, Geannette C, et al. Comparison of navigated versus non-navigated pedicle screw placement in 260 patients and 1434 screws: screw accuracy, screw size, and the complexity of surgery. *J Spinal Disord Tech.* 2015;28:E298-E303.
- Gautschi OP, Garbossa D, Tessitore E, et al. Maximal access surgery for posterior lumbar interbody fusion with divergent, cortical bone trajectory pedicle screws: a good option to minimize spine access and maximize the field for nerve decompression. *J Neurosurg Sci.* 2017;61:335-341.
- Matsukawa K, Yato Y, Hynes RA, et al. Cortical bone trajectory for thoracic pedicle screws: a technical note. *Clin Spine Surg.* 2017;30:E497-E504.
- Santoni BG, Hynes RA, McGilvray KC, et al. Cortical bone trajectory for lumbar pedicle screws. *Spine J.* 2009;9:366-373.
- Perez-Orribo L, Kalb S, Reyes PM, Chang SW, Crawford NR. Biomechanics of lumbar cortical screw-rod fixation versus pedicle screw-rod fixation with and without interbody support. *Spine (Phila Pa 1976).* 2013;38:635-641.
- Matsukawa K, Yato Y, Nemoto O, Imabayashi H, Asazuma T, Nemoto K. Morphometric measurement of cortical bone trajectory for lumbar pedicle screw insertion using computed tomography. *J Spinal Disord Tech.* 2013;26:E248-E253.
- Baluch DA, Patel AA, Lullo B, et al. Effect of physiological loads on cortical and traditional pedicle screw fixation. *Spine (Phila Pa 1976).* 2014;39:E1297-E1302.
- Matsukawa K, Yato Y, Kato T, Imabayashi H, Asazuma T, Nemoto K. In vivo analysis of insertional torque during pedicle screwing using cortical bone trajectory technique. *Spine (Phila Pa 1976).* 2014;39:E240-E245.
- Matsukawa K, Yato Y, Kato T, Imabayashi H, Asazuma T, Nemoto K. Cortical bone trajectory for lumbosacral fixation: penetrating S-1 endplate screw technique: technical note. *J Neurosurg Spine.* 2014;21:203-209.
- Calvert GC, Lawrence BD, Abtahi AM, Bachus KN, Brodke DS. Cortical screws used to rescue failed lumbar pedicle screw construct: a biomechanical analysis. *J Neurosurg Spine.* 2015;22:166-172.
- Marengo N, Ajello M, Pecoraro MF, et al. Cortical bone trajectory screws in posterior lumbar interbody fusion: minimally invasive surgery for maximal muscle sparing—a prospective comparative study with the traditional open technique. *Biomed Res Int.* 2018;2018:7.
- Marengo N, Berjano P, Cofano F, et al. Cortical bone trajectory screws for circumferential arthrodesis in lumbar degenerative spine: clinical and radiological outcomes of 101 cases. *Eur Spine J.* 2018;27:213-221.
- Cofano F, Zenga F, Mammi M, et al. Intraoperative neurophysiological monitoring during spinal surgery: technical review in open and minimally invasive approaches. *Neurosurg Rev.* 2019;42:297-307.
- Rao G, Brodke DS, Rondina M, Bacchus K, Dailey AT. Inter- and intraobserver reliability of computed tomography in assessment of thoracic pedicle screw placement. *Spine (Phila Pa 1976).* 2003;28:2527-2530.
- Aoude AA, Fortin M, Figueiredo R, Jarzem P, Ouellet J, Weber MH. Methods to determine pedicle screw placement accuracy in spine surgery: a systematic review. *Eur Spine J.* 2015;24:990-1004.
- Gertzbein SD, Robbins SE. Accuracy of pedicular screw placement in vivo. *Spine (Phila Pa 1976).* 1990;15:11E4.
- Penner F, Marengo N, Ajello M, et al. Preoperative 3D CT planning for cortical bone trajectory screws: a retrospective radiological cohort study [e-pub ahead of print]. *World Neurosurg.* 2019. <https://doi.org/10.1016/j.wneu.2019.03.121>. Accessed March 20, 2019.
- Watkins RG, Gupta A, Watkins RG. Cost-effectiveness of image-guided spine surgery. *Open Orthop J.* 2010;4:228-233.

19. Hartl R, Lam KS, Wang J, Korge A, Kandziara F, Audigé L. Worldwide survey on the use of navigation in spine surgery. *World Neurosurg.* 2013;79:162-172.
20. Costa F, Porazzi E, Restelli U, et al. Economic study: a cost-effectiveness analysis of an intraoperative compared with a preoperative image-guided system in lumbar pedicle screw fixation in patients with degenerative spondylolisthesis. *Spine J.* 2014;14:1790-1796.
21. Al-Khouja L, Shweikeh F, Pashman R, Patrick Johnson J, Kim TT, Drazinl D. Economics of image guidance and navigation in spine surgery. *Surg Neurol Int.* 2015;6(suppl 10):S323-S326.
22. Dea N, Fisher CG, Batke J, et al. Economic evaluation comparing intraoperative cone beam CT-based navigation and conventional fluoroscopy for the placement of spinal pedicle screws: a patient-level data cost-effectiveness analysis. *Spine J.* 2016;16:23-31.
23. Zhao X, Zhao J, Xie Y, Miet J. The utility of a digital virtual template for junior surgeons in pedicle screw placement in the lumbar spine. *Biomed Res Int.* 2016;2016:3076025.
24. Radermacher K, Portheine F, Anton M, et al. Computer assisted orthopaedic surgery with image based individual templates. *Clin Orthop Relat Res.* 1998;354:28-38.
25. Li X, Zhang Q, Zhao C, Yuan Z, Cai J. [Surgical application of pedicle drill template navigation technology for complicated scoliosis]. *Zhonghua Yi Xue Za Zhi.* 2014;94:840-843 [in Chinese].
26. Merc M, Drstvensek I, Vogrin M, Brajlilh T, Friedrich T, Recnik G. Error rate of multi-level rapid prototyping trajectories for pedicle screw placement in lumbar and sacral spine. *Chin J Traumatol.* 2014;17:261-266.
27. Hu Y, Yuan ZS, Spiker WR, et al. A comparative study on the accuracy of pedicle screw placement assisted by personalized rapid prototyping template between pre- and post-operation in patients with relatively normal mid-upper thoracic spine. *Eur Spine J.* 2016;25:1706-1715.
28. Takemoto M, Fujibayashi S, Ota E, et al. Additive-manufactured patient-specific titanium templates for thoracic pedicle screw placement: novel design with reduced contact area. *Eur Spine J.* 2016;25:1698-1705.
29. Lamartina C, Capuzzo A, Cecchinato R, Zerbi A, Berjano P. Adolescent idiopathic scoliosis surgery with patient-specific screw placement-guides. *Eur Spine J.* 2014;23:2765-2766.
30. Putzier M, Strube P, Cecchinato R, Lamartina C, Hoff EK. A new navigational tool for pedicle screw placement in patients with severe scoliosis: a pilot study to prove feasibility, accuracy, and identify operative challenges. *Clin Spine Surg.* 2017;30:E430-E439.
31. Lamartina C, Cecchinato R, Fekete Z, Lipari A, Fiechter M, Berjano P. Pedicle screw placement accuracy in thoracic and lumbar spinal surgery with a patient-matched targeting guide: a cadaveric study. *Eur Spine J.* 2015;24(suppl 7):937-941.
32. Farshad M, Betz M, Farshad-Amacker NA, Moser M. Accuracy of patient-specific template-guided vs. free-hand fluoroscopically controlled pedicle screw placement in the thoracic and lumbar spine: a randomized cadaveric study. *Eur Spine J.* 2017;26:738-749.
33. Aichmair A, Moser M, Bauer MR, et al. Pull-out strength of patient-specific template-guided vs. free-hand fluoroscopically controlled thoracolumbar pedicle screws: a biomechanical analysis of a randomized cadaveric study. *Eur Spine J.* 2017;26:2865-2872.
34. Matsukawa K, Kato T, Yato Y, et al. Incidence and risk factors of adjacent cranial facet joint violation following pedicle screw insertion using cortical bone trajectory technique. *Spine (Phila Pa 1976).* 2016;41:E851-E856.
35. Matsukawa K, Yato Y, Imabayashi H, Hosogane N, Asazuma T, Nemoto K. Biomechanical evaluation of the fixation strength of lumbar pedicle screws using cortical bone trajectory: a finite element study. *J Neurosurg Spine.* 2015;23:471-478.
36. Matsukawa K, Yato Y, Imabayashi H, Hosogane N, Asazuma T, Nemoto K. Biomechanical evaluation of fixation strength among different sizes of pedicle screws using the cortical bone trajectory: what is the ideal screw size for optimal fixation? *Acta Neurochir (Wien).* 2016;158:465-471.
37. Matsukawa K, Yato Y, Hynes RA, et al. Comparison of pedicle screw fixation strength among different transpedicular trajectories: a finite element study. *Clin Spine Surg.* 2017;30:301-307.
38. Kaito T, Matsukawa K, Abe Y, Fiechter M, Zhu X, Fantigrossi A. Cortical pedicle screw placement in lumbar spinal surgery with a patient-matched targeting guide: a cadaveric study. *J Orthop Sci.* 2018;23:865-869.
39. Ahn Y, Kim CH, Lee JH, Lee SH, Kim JS. Radiation exposure to the surgeon during percutaneous endoscopic lumbar discectomy: a prospective study. *Spine (Phila Pa 1976).* 2013;38:617-625.

Conflict of interest statement: The authors declare that the article content was composed in the absence of any commercial or financial relationships that could be construed as a potential conflict of interest.

Received 11 February 2019; accepted 16 May 2019

*Citation: World Neurosurg. (2019) 130:e98-e104.
https://doi.org/10.1016/j.wneu.2019.05.241*

Journal homepage: www.journals.elsevier.com/world-neurosurgery

Available online: www.sciencedirect.com

1878-8750/\$ - see front matter © 2019 Elsevier Inc. All rights reserved.