



Cervical Interfacet Spacers to Promote Indirect Decompression and Enhance Fusion in Degenerative Spine: A Review

Fabio Cofano¹, Giuseppe Junior Sciarrone², Michele Federico Pecoraro², Nicola Marengo¹, Marco Ajello¹, Federica Penner¹, Salvatore Petrone¹, Alessandro Ducati¹, Francesco Zenga¹, Corrado Musso², Diego Garbossa¹

Key words

- Atlantoaxial instability
- Cervical interfacet spacers
- Cervical radiculopathy
- Cervical spine surgery
- Indirect decompression
- Minimally invasive surgery

Abbreviations and Acronyms

ACDF: Anterior cervical discectomy and fusion

CIS: Cervical interfacet spacer

From the ¹Division of Neurosurgery, Department of Neuroscience, University of Turin, Turin, Italy; and ²Spinal Surgery, Humanitas Research Center, Bergamo, Italy

To whom correspondence should be addressed:

Fabio Cofano, M.D.

[E-mail: fabio.cofano@gmail.com]

Citation: *World Neurosurg.* (2019) 126:447-452.

<https://doi.org/10.1016/j.wneu.2019.03.114>

Journal homepage: www.journals.elsevier.com/world-neurosurgery

Available online: www.sciencedirect.com

1878-8750/\$ - see front matter © 2019 Elsevier Inc. All rights reserved.

INTRODUCTION

In degenerative cervical spine surgery, the anterior approach for discectomy and fusion (anterior cervical discectomy and fusion [ACDF]) has increased in popularity in the last decades, showing its reliability in radicular or canal decompression, restoring or consolidating lordosis, and promoting arthrodesis.^{1,2}

Cervical arthroplasty, developed with the aim of preserving movement and reducing the incidence of adjacent disease, has failed to maintain original expectations and, despite recent re-evaluations, is now promoted only in selected cases.³⁻⁵ Although the anterior approach has maintained its indisputable role, the incidence and severity of the related complications should not be underestimated. Both the surgical corridor and the implants can cause major or minor damage, leading to the well-known possibilities of postoperative dysphagia

■ **BACKGROUND:** Among the posterior techniques, the use of cervical interfacet spacers (CISs) represents a promising technology whose potentialities are still being studied. The purpose of the present review was to assess the available data on CISs.

■ **METHODS:** A search on PubMed was performed. The search terms were "cervical interfacet spacers," "facet spacers," "DTRAX facet system," "Goel facet spacer," "pseudarthrosis," "cervical lordosis," "iatrogenic kyphosis," "cervical foraminal decompression," "cervical biomechanics," "atlantoaxial instability," and "subaxial instability."

■ **RESULTS:** Mechanical studies have shown that stand-alone CISs promoted stiffness in all directions, except for extension. Foraminal distraction was recorded in 86% of the cases. Clinical studies have shown that the use of CISs could promote successful arthrodesis, given the large surface area affected by fusion and decreasing the need for autografts. The effectiveness for the treatment of radiculopathy has been confirmed by several clinical studies. In a series of 154 levels of implanted CISs, no evidence of significant loss of cervical lordosis was identified. CISs could help in enhancing fusion in C1-C2 fixation.

■ **CONCLUSIONS:** Biomechanical studies on specimens showed a positive trend in increasing stiffness of the cervical spine, despite some controversial results. In clinical studies, facet distraction was shown to be a safe and valid option for clinical indirect decompression, although longer follow-up is required for confirmation. No evidence of the loss of cervical lordosis has been recorded. The long-term effects and CIS use in revision procedures as adjuvant implants to treat pseudarthrosis or atlantoaxial instability are currently under investigation, and further studies are needed.

and dysphonia or clinical conditions due to lesions of visceral structures.⁶⁻⁸

Thus, the posterior approach is a valuable alternative for revision surgery to ensure a valid fusion rate. Also, in decompression procedures, the posterior approach is able to guarantee comparable outcomes despite the need for muscular dissection.⁹ Among the posterior techniques, the use of cervical interfacet spacers (CISs) represents a promising technology to achieve decompression or promote fusion. In the present report, the most recent data updates have been examined to understand the biomechanics and potential clinical

advantages of CISs studied by several investigators.

METHODS

The selection criteria and studies for the present review were identified through searches of PubMed using the search terms "cervical interfacet spacers," "facet spacers," "DTRAX," "DTRAX facet system," and "Goel facet spacer" according to standardized PRISMA (preferred reporting items for systematic reviews and meta-analysis) guidelines.¹⁰ The reports were then evaluated and analyzed considering different items: biomechanical aspects,

clinical evaluation for the treatment of pseudarthrosis, clinical evaluation for the treatment of radicular or canal compression, radiological evaluation of cervical lordosis, clinical evaluation for the management of atlantoaxial instability, and minimal invasiveness. Each report was evaluated using the methodological index for nonrandomized studies.¹¹

RESULTS

After review, 16 full-text articles were included for analysis according to the PRISMA guidelines (Figure 1).¹⁰ The methodological index for nonrandomized studies¹¹ scores for each study are reported in Table 1.

Biomechanical Evaluation

Investigators have sought to determine whether the use of a facet spacer could ensure and promote stiffness and fusion of the cervical spine in flexion-extension movements and lateral bending. Furthermore, facet distraction could potentially promote enlargement of the foraminal area, promoting indirect decompression. Leasure and Buckley¹⁵ used specimens to determine the biomechanical properties of CISs, placing them bilaterally at single

levels and then applying movement with 30,000 cycles at 2 Hz of nonsimultaneous flexion-extension and lateral bending under compressive loads. Three-dimensional images of the foramen were taken before and after CIS placement and the flexion-extension cycles. Radiographs were used to monitor any loosening. The stand-alone CISs promoted stiffness in all directions, except for extension. Foraminal distraction was recorded in 86% of cases and maintained in flexion, extension, and rotation postures. Loosening was only subclinical in some specimens (<0.5 mm). Thus, the results were encouraging. In 2016, Maulucci et al.¹⁷ studied the effects of CISs on intervertebral kinetics and the foraminal area in cadaveric cervical spine specimens. Although the enlargement of the foraminal area was statistically significant and confirmed previous studies, spinal segmental stability was not significantly increased statistically with the use of CISs alone. Only the addition of posterior instrumentation enhanced the stiffness and resulted in significant reduction in motion. In contrast, Voronov et al.^{18,19} showed in 2 cadaveric studies that CISs provide cervical segmental stability similar to that with lateral mass screws and rod constructs or ACDF. The

addition of lateral mass screws or intersomatic cages in specimens with CISs implanted ensured greater cervical spine stability in single- and multilevel conditions.^{18,19} Thus, although no doubts regarding foraminal decompression have seemed to emerge, the results on the stiffness and range of motion with stand-alone CISs have remained controversial despite a positive, but not statistically significant, trend found in biomechanical studies. However, a prospective multi-center study showed that 5.9% of 53 patients with implanted CISs had developed adjacent segment degeneration at 2 years of follow-up, reporting an indirect demonstration of the increased stiffness of the segment.²⁰

Clinical Evaluation for the Treatment of Pseudarthrosis

The pseudarthrosis rate in cervical arthrodesis has varied, with a range from a maximum of 20% in single-level procedures to 60% in multilevel procedures.²⁸ These values should not be underestimated because, even if not always the case, pseudarthrosis could be a source of persistent axial pain or compression symptoms and promote the development of deformities.²⁸⁻³⁰ Revision surgery of pseudarthrosis is challenging and requires careful planning. With the anterior approach, several complications become more likely during revision surgery because visceral lesions are more likely. Furthermore, because most cases of cervical arthrodesis are performed using the anterior approach, an anterior revision will constitute a second surgery in the same failed fusion bed.³¹ McAnany et al.²⁸ showed the best fusion rate with a posterior approach. Carreon et al.³² reported a greater incidence of nonunion after anterior revision requiring surgery. Other studies have confirmed these results, with fewer approach-related complications with posterior revisions.³³ Nevertheless, evidence regarding the clinical benefit of the posterior approach versus the anterior approach has remained controversial, and the optimal method for the treatment of cervical pseudarthrosis is still debated.³⁴ Regarding grafts, many studies have described the use of autologous or heterologous iliac crest bone or bone material in the interfacet space.^{28,29,35-38}

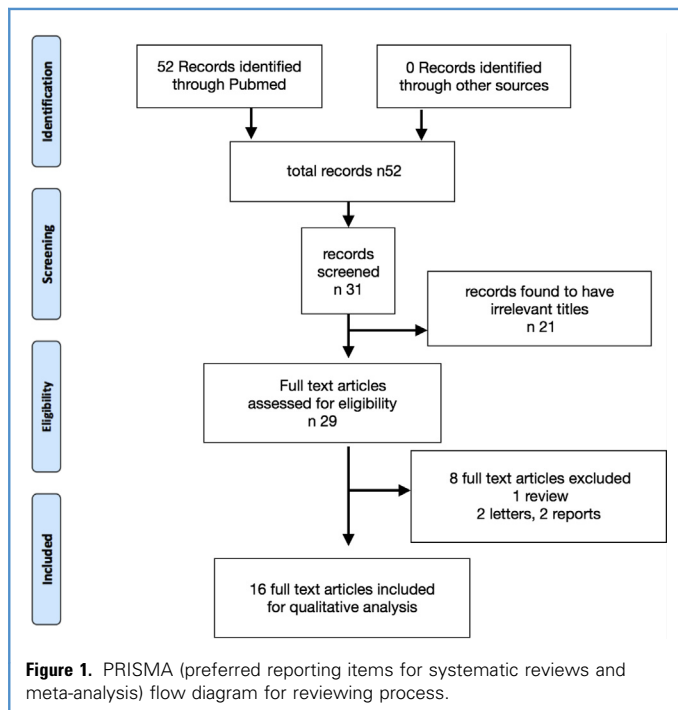


Table 1. Methodological Index for Nonrandomized Studies Scores for Each Study

Investigator	Study Title	MINORS Scale Score
Goel et al., ¹² 2011	Facetal distraction as treatment for single and multilevel cervical spondylotic radiculopathy and myelopathy: a preliminary report	12
McCormack et al., ¹³ 2013	Percutaneous posterior cervical fusion with the DTRAX facet system for single-level radiculopathy: results in 60 patients	14
Tan et al., ¹⁴ 2014	Effect of machined interfaclograft spacers on cervical foraminal height and area	10
Leasure et al., ¹⁵ 2014	Biomechanical evaluation of an interfacet joint decompression and stabilization system	15
Tan et al., ¹⁶ 2015	Cervical interfacet spacers and maintenance of cervical lordosis	7
Maulucci et al., ¹⁷ 2016	Cortical bone facet spacers for cervical spine decompression: effects on intervertebral kinetics and foraminal area	15
Voronov et al., ¹⁸ 2016	Biomechanical evaluation of DTRAX(®) posterior cervical cage stabilization with and without lateral mass fixation	21 (comparative)
Voronov et al., ¹⁹ 2016	Bilateral posterior cervical cages provide biomechanical stability: assessment of stand-alone and supplemental fixation for anterior cervical discectomy and fusion	21 (comparative)
Siemionow et al., ²⁰ 2016	Preliminary analysis of adjacent segment degeneration in patients treated with posterior cervical cages: 2-year follow-up	13
Kasliwal et al., ²¹ 2016	Posterior cervical fusion using cervical interfacet spacers in patients with symptomatic cervical pseudarthrosis	7
Siemionow et al., ²² 2016	Cervical cages placed bilaterally in the facet joints from a posterior approach significantly increase foraminal area	8
Siemionow et al., ²³ 2016	Clinical and radiographic results of indirect decompression and posterior cervical fusion for single-level cervical radiculopathy using an expandable implant with 2-year follow-up	11
McCormack et al., ²⁴ 2016	Novel instrumentation and technique for tissue sparing posterior cervical fusion	3
Turel et al., ²⁵ 2017	Machined cervical interfacet allograft spacers for the management of atlantoaxial instability	6
Siemionow et al., ²⁶ 2018	Length of stay associated with posterior cervical fusion with intervertebral cages: experience from a device registry	8
Cheng et al., ²⁷ 2019	Posterior cervical fusion utilizing cages placed bilaterally in the facets for the treatment of the upper cervical adjacent segment disease in the elderly	13

MINORS, methodological index for nonrandomized studies; DTRAX facet system, Providence Medical Technology, Pleasanton, California, USA.

Evidence is lacking regarding the use of CISs in revision surgery. Kasliwal et al.²¹ treated 19 patients for symptomatic pseudarthrosis with the use of CISs plus lateral mass screws. The results showed improvement in the clinical scores. Fusion had occurred at all levels treated. Goel and Shah¹² showed that CISs could create an area for solid, segmental, spinal arthrodesis. Because facets are responsible for a substantial proportion of axial loading forces and play a role in lateral bending and shearing/distraction forces, the use of CISs could promote successful arthrodesis, given the large surface area affected by fusion. However, no conclusions can be made, and further studies are needed. Furthermore, the advantages of CISs versus the use of bone grafts (autografts or allografts) for interfacet fusion should be determined.

CISs reduce the need for autografts such as iliac crest bone grafts with the associated morbidity^{14,16,28,29,35-38} and, theoretically, provide a dimensionally controlled support to promote fusion and decompression, when needed. However, evidence comparing the 2 techniques with radiological and clinical outcomes has been lacking. Equally, no conclusions can be made about the use of bone allografts. The topic has been investigated for cervical anterior surgery, and the available reports have suggested a trend toward the similar effectiveness of allografts and autografts in fusion rates, pain scores, and functional outcomes, with less morbidity. However, the quality of the evidence from the available studies has been very low.³⁸⁻⁴⁰ No studies have actually described the results with the use of bone allografts alone via the posterior

approach for the treatment of pseudarthrosis with acceptable follow-up or compared them with CISs. McCormack and Dhawan,²⁴ in 2016, described a minimally invasive technique to place a bone allograft in interfacet joints to achieve fusion in pseudarthrosis and avoid the risk of perioperative morbidity described with open, traditional approaches.^{32,41} Forty patients were treated, with no revision surgery required after the procedure. However, they did not provide a detailed description of the case series.²⁴ Therefore, although it is possible to pose the theoretical advantages of the surgical positioning of CISs against the graft because of the standardized setting, no conclusions can be drawn regarding differences in outcomes and fusion rates because no comparative studies have been performed.

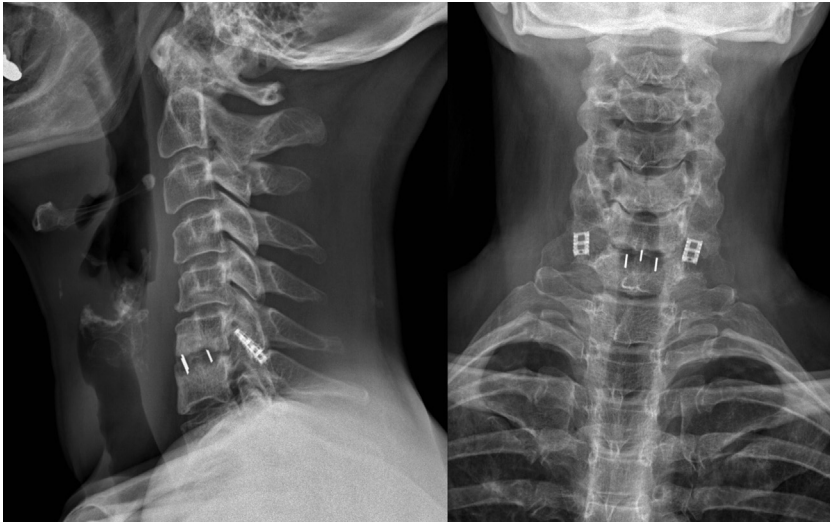


Figure 2. A 45-year-old woman was treated with anterior cervical discectomy and fusion for a left disc herniation. After 6 months she reported recurrence of radiculopathy. Radiographs showed intersomatic pseudarthrosis. Cervical interfacet spacers were then successfully used to obtain relief from the radicular impingement.

Clinical Evaluation for the Treatment of Radicular or Canal Compression

Goel and Shah¹² focused on the pathophysiology of cervical disease. They showed that facet joints could have a leading role in initiating degeneration and suggested their evaluation in clinical presentations should not be underestimated.¹² Decreasing in height of the interfacet space and the presence of retrolisthesis could be the only signs of microinstability justifying the presence of radicular symptoms. In 2011, Goel and Shah¹² presented a case series of 36 patients, demonstrating relief of symptoms caused by radiculopathy or myelopathy. McCormack et al.¹³ indicated that CISs were effective in the treatment of radiculopathy in a series of 60 patients. Further clinic studies confirmed these results.^{14,22,23,42} Facet distraction was shown to be a safe and valid option for clinical indirect decompression (Figure 2), although longer follow-up periods are needed.

Radiographic Evaluation of Cervical Lordosis After CISs Placement

The major concern regarding the use of interfacet spacers has been related to the risk of loss of segmental or global lordosis. Subsequently, several studies have tried to evaluate the sagittal

parameters after surgical procedures. The results never showed a loss of global lordosis. McCormack et al.¹³ and Cheng et al.,²⁷ in their series of 60 and 24 patients respectively, found no significant changes in overall cervical lordosis. Goel and Shah¹² described some degree of loss of lordosis in the segment treated but did not report any conclusions regarding the range of degrees lost owing to the small number of patients. However, none of the patients developed any degree of kyphosis after surgery.¹² Kasliwal et al.²¹ confirmed no significant effect on cervical lordosis and the C2–C7 sagittal vertical axis. Tan et al.¹⁶ investigated the maintenance of cervical lordosis with a series of CISs implanted in 154 levels. That study, the largest case series on this topic, found no evidence of significant loss of cervical lordosis in either single or multiple levels.¹⁶ Other studies have validated these findings.²³ The reported data seem to show that, overall, lordosis will not be affected by CIS placement. Thus, further studies are needed, especially of the expandable device.

Clinical Evaluation for the Management of Atlantoaxial Instability

Atlantoaxial instability will usually be caused by degenerative, inflammatory, or

traumatic pathologic features. For treatment, arthrodesis with fusion plays a key role and has historically been obtained with the aid of screws and bone grafts. Turel et al.²⁵ investigated the use of CISs to enhance stability in C1–C2 fixation. Interfacet spacers were used in 19 patients, together with poliaxial screws and bone graft, with a successful fusion rate of 95%, comparable with the best reported results.^{43,44} Joaquim et al.⁴⁵ confirmed these findings. The results from a single experience will clearly be limited; however, the use of CISs could theoretically be of help in enhancing fusion in challenging procedures such as C1–C2 fixation.

How Minimally Invasive?

The anterior approach in cervical surgery has undisputed advantages including the minimally invasive anatomical corridor, although visceral complications can be serious, even if rare.⁶ One of the major drawbacks of the posterior approach in cervical surgery is related to the need for muscular dissection and disruption of soft tissue, leading to common postoperative cervicgia. The use of CISs with percutaneous placement to treat cervical radiculopathies could lead to reassessment of the surgical scenario. Compared with posterior foraminotomy, no bone removal is needed with the subsequent risk of iatrogenic instability, no direct manipulation of the nerve roots (with the resultant risk of injury) is required, and fusion is promoted. Furthermore, a prospective multicenter study showed that the use of CISs reduced the length of postoperative hospitalization compared with that required after lateral mass fixation.²⁶ Further studies, prospective and randomized, are required to confirm the data regarding the clinical improvement of radiculopathies treated with CISs and compare them with the outcomes after ACDF. Interfacet spacers appear to be a promising solution even in the maximally degenerated cervical spine with foraminal impingements.⁴²

CONCLUSION

CISs represent a relatively new technology with promising evidence. Biomechanical studies have shown a positive trend in

increasing the stiffness of the cervical spine, despite some controversial results. In clinical studies, CISs were shown to provide reliable indirect neuroforaminal decompression and to promote fusion. No evidence regarding the loss of cervical lordosis has been recorded. Information about their use in revision procedures as adjuvant implants to treat pseudarthrosis or atlantoaxial instability with reasonable follow-up data are lacking.

REFERENCES

- Matz PG, Holly LT, Mummaneni PV, et al. Anterior cervical surgery for the treatment of cervical degenerative myelopathy. *J Neurosurg Spine*. 2009; 11:170-173.
- Mobbs RJ, Rao P, Chandran NK. Anterior cervical discectomy and fusion: analysis of surgical outcome with and without plating. *J Clin Neurosci*. 2007;14:639-642.
- Wenger M, Markwalder TM. Bryan total disc arthroplasty: a replacement disc for cervical disc disease. *Med Dev (Auckland, NZ)*. 2010;3:11-24.
- Zechmeister I, Winkler R, Mad P. Artificial total disc replacement versus fusion for the cervical spine: a systematic review. *Eur Spine J*. 2011;20:177-184.
- Bertagnoli R, Duggal N, Pickett GE, et al. Cervical total disc replacement, part two: clinical results. *Orthop Clin*. 2005;36:355-362.
- Fountas KN, Kapsalaki EZ, Nikolakakos LG, et al. Anterior cervical discectomy and fusion associated complications. *Spine (Phila Pa 1976)*. 2007;32:2310-2317.
- Heary RF, Benzel EC, Vaicys C. Single and multiple-single inter body fusion techniques. In: Benzel EC, ed. *Spine Surgery: Techniques, Complication Avoidance, and Management*. Philadelphia, PA: Elsevier; 2005:351-362.
- Riley LH III, Vaccaro AR, Dettori JR, Hashimoto R. Postoperative dysphagia in anterior cervical spine surgery. *Spine*. 2010;35(suppl):S76-S85.
- Mummaneni PV, Kaiser MG, Matz PG, et al. Cervical surgical techniques for the treatment of cervical spondylotic myelopathy. *J Neurosurg Spine*. 2009;11:130-141.
- Liberati A, Altman DG, Tetzlaff J, et al. The PRISMA statement for reporting systematic reviews and meta-analyses of studies that evaluate healthcare interventions: explanation and elaboration. *BMJ*. 2009;339:b2700.
- Slim K, Nini E, Forestier D, Kwiatkowski F, Panis Y, Chipponi J. Methodological index for non-randomized studies (minors): development and validation of a new instrument. *ANZ J Surg*. 2003;73:712-716.
- Goel A, Shah A. Facetal distraction as treatment for single and multilevel cervical spondylotic radiculopathy and myelopathy: a preliminary report. *J Neurosurg Spine*. 2011;14:689-696.
- McCormack BM, Bundoc RC, Ver MR, Ignacio JM, Berven SH, Eyster EF. Percutaneous posterior cervical fusion with the DTRAX Facet System for single-level radiculopathy: results in 60 patients. *J Neurosurg Spine*. 2013;18:245-254.
- Tan LA, Gerard CS, Anderson PA, Traynelis VC. Effect of machined interfacelagraft spacers on cervical foraminal height and area. *J Neurosurg Spine*. 2014;20:178-182.
- Leasure JM, Buckley J. Biomechanical evaluation of an interfacet joint decompression and stabilization system. *J Biomech Eng*. 2014;136.
- Tan LA, Straus DC, Traynelis VC. Cervical interfacet spacers and maintenance of cervical lordosis. *J Neurosurg Spine*. 2015;22:466-469.
- Maulucci CM, Sansur CA, Singh V, et al. Cortical bone facet spacers for cervical spine decompression: effects on intervertebral kinetics and foraminal area. *J Neurosurg Spine*. 2016;24:69-76.
- Voronov LI, Siemionow KB, Havej RM, Carandang G, Patwardhan AG. Biomechanical evaluation of DTRAX® posterior cervical cage stabilization with and without lateral mass fixation. *Med Devices (Auckl)*. 2016;9:285-290.
- Voronov LI, Siemionow KB, Havej RM, Carandang G, Phillips FM, Patwardhan AG. Bilateral posterior cervical cages provide biomechanical stability: assessment of stand-alone and supplemental fixation for anterior cervical discectomy and fusion. *Med Devices (Auckl)*. 2016;9:223-230.
- Siemionow K, Monsef JB, Janusz P. Preliminary analysis of adjacent segment degeneration in patients treated with posterior cervical cages: 2-year follow-up. *World Neurosurg*. 2016;89:730.e1-e7.
- Kasliwal MK, Corley JA, Traynelis VC. Posterior cervical fusion using cervical interfacet spacers in patients with symptomatic cervical pseudarthrosis. *Neurosurgery*. 2016;78:661-668.
- Siemionow K, Janusz P, Glowka P. Cervical cages placed bilaterally in the facet joints from a posterior approach significantly increase foraminal area. *Eur Spine J*. 2016;25:2279-2285.
- Siemionow K, Janusz P, Phillips FM, et al. Clinical and radiographic results of indirect decompression and posterior cervical fusion for single-level cervical radiculopathy using an expandable implant with 2-year follow-up. *J Neurol Surg A Cent Eur Neurosurg*. 2016;77:482-488.
- McCormack BM, Dhawan R. Novel instrumentation and technique for tissue sparing posterior cervical fusion. *J Clin Neurosci*. 2016;34:299-302.
- Turel MK, Kerolus MG, Traynelis VC. Machined cervical interfacet allograft spacers for the management of atlantoaxial instability. *J Craniocervical Junction Spine*. 2017;8:332-337.
- Siemionow K, Smith W, Gillespy M, McCormack BM, Gundanna MI, Block JE. Length of stay associated with posterior cervical fusion with intervertebral cages: experience from a device registry. *J Spine Surg*. 2018;4:281-286.
- Cheng L, McCormack B, Eyster EF. Posterior cervical fusion utilizing cages placed bilaterally in the facets for the treatment of the upper cervical adjacent segment disease in the elderly [e-pub ahead of print]. *J Clin Neurosci* <https://doi.org/10.1016/j.jcon.2019.01.018>.
- McAnany SJ, Baird EO, Overley SC, Kim JS, Qureshi SA, Anderson PA. A meta-analysis of the clinical and fusion results following treatment of symptomatic cervical pseudarthrosis. *Glob Spine J*. 2015;5:148-155.
- Kuhns CA, Geck MJ, Wang JC, Delamarter RB. An outcomes analysis of the treatment of cervical pseudarthrosis with posterior fusion. *Spine (Phila Pa 1976)*. 2005;30:2424-2429.
- Phillips FM, Carlson G, Emery SE, Bohlman HH. Anterior cervical pseudarthrosis: natural history and treatment. *Spine (Phila Pa 1976)*. 1997;22:1585-1589.
- Siambanes D, Mis GS. Treatment of symptomatic anterior cervical nonunion using the Rogers interspinous wiring technique. *Am J Orthop (Belle Mead NJ)*. 1998;27:792-796.
- Carreon L, Glassman SD, Campbell MJ. Treatment of anterior cervical pseudoarthrosis: posterior fusion versus anterior revision. *Spine J*. 2006;6:154-156.
- Liu H, Ploumis A, Schwender JD, Garvey TA. Posterior cervical lateral mass screw fixation and fusion to treat pseudarthrosis of anterior cervical fusion. *J Spinal Disord Tech*. 2012;25:138-141.
- Kaiser MG, Mummaneni PV, Matz PG, et al. Management of anterior cervical pseudarthrosis. *J Neurosurg Spine*. 2009;11:228-237.
- Farey ID, McAfee PC, Davis RF, Long DM. Pseudarthrosis of the cervical spine after anterior arthrodesis: treatment by posterior nerve-root decompression, stabilization, and arthrodesis. *J Bone Joint Surg Am*. 1990;72:1171-1177.
- Koerner JD, Kepler CK, Albert TJ. Revision surgery for failed cervical spine reconstruction: review article. *HSS J*. 2015;11:2-8.
- Zdeblick TA, Hughes SS, Riew KD, Bohlman HH. Failed anterior cervical discectomy and arthrodesis: analysis and treatment of thirty-five patients. *J Bone Joint Surg Am*. 1997;79:523-532.
- Coric D, Branch CL Jr, Jenkins JD. Revision of anterior cervical pseudarthrosis with anterior allograft fusion and plating. *J Neurosurg*. 1997;86:969-974.
- Tuchman A, Brodke DS, Youssef JA, et al. Autograft versus allograft for cervical spinal fusion: a systematic review. *Glob Spine J*. 2017;7:59-70.
- Leven D, Cho SK. Pseudarthrosis of the cervical spine: risk factors, diagnosis and management. *Asian Spine J*. 2016;10:776-786.
- Elder BD, Sankey EW, Theodoros D, et al. Successful anterior fusion following posterior cervical fusion for revision of anterior cervical discectomy

- and fusion pseudoarthrosis. *J Clin Neurosci.* 2016; 24:57-62.
42. Skovrlj B, Qureshi SA. Minimally invasive cervical spine surgery. *J Neurosurg Sci.* 2017;61:325-334.
43. Huang DG, Hai DJ, He BR, et al. Posterior atlantoaxial fixation: a review of all techniques. *Spine J.* 2015;15:2271-2281.
44. Salunke P, Sahoo SK, Futane S, Deepak AN, Khandelwal NK. "Atlas shrugged": congenital lateral angular irreducible atlantoaxial dislocation: a case series of complex variant and its management. *Eur Spine J.* 2016;25:1098-1108.
45. Joaquim AF, Tedeschi H, Chandra PS. Controversies in the surgical management of congenital craniocervical junction disorders—a critical review. *Neurol India.* 2018;66:1003-1015.
- Conflict of interest statement: The authors declare that the article content was composed in the absence of any commercial or financial relationships that could be construed as a potential conflict of interest.*
- Received 27 December 2018; accepted 11 March 2019*
- Citation: World Neurosurg. (2019) 126:447-452.*
<https://doi.org/10.1016/j.wneu.2019.03.114>
- Journal homepage: www.journals.elsevier.com/world-neurosurgery*
- Available online: www.sciencedirect.com*
- 1878-8750/\$ - see front matter © 2019 Elsevier Inc. All rights reserved.*