



## Preoperative 3D CT Planning for Cortical Bone Trajectory Screws: A Retrospective Radiological Cohort Study

Federica Penner, Nicola Marengo, Marco Ajello, Salvatore Petrone, Fabio Cofano, Filippo Veneziani Santonio, Francesco Zenga, Diego Garbossa

■ **BACKGROUND:** Pedicle screw instrumentation is a standard procedure in lumbar spinal fusion. The cortical bone trajectory (CBT) screw is an alternative technique, less invasive but harder to perform. The identification of the entry point and the appropriate direction can be tricky especially to the surgeons just at the beginning. Therefore, the aim of this study is to evaluate the reliability of preoperative computed tomography (CT) planning in the CBT screw placement.

■ **METHODS:** We retrospectively evaluated 82 patients who underwent a single-level posterior lumbar arthrodesis with CBT screws. The correct entry point and the best trajectory were identified on a 3-dimensional (3D) multiplanar reconstruction CT view. The concordance between achieved and planned trajectories was assessed on a postoperative CT.

■ **RESULTS:** A total of 328 screws was positioned. The average entry point distance from the target was 1.1 mm (standard deviation,  $\pm 0.15$  mm). In 301 screws (91.8%), the obtained trajectory differed no more than  $2^\circ$  from the planned one. No screws misplaced or new neurological deficit was recorded.

■ **CONCLUSIONS:** The CBT screw placement is a great alternative to the pedicle screw. Accurate preoperative 3D planning is useful to predict the entry point and the direction with accuracy similar to navigation systems, avoiding its costs and technical difficulties. The 3D CT planning is helpful in the customization of spine surgery,

and the results underline the radiological reliability of this technique.

### INTRODUCTION

Pedicle screw (PS) instrumentation is considered a standard procedure in lumbar spinal fusion to provide the stability needed to achieve bony union.<sup>1</sup> Minimally invasive techniques have been developed to reduce the morbidity associated with the posterior approach.<sup>1</sup> Santoni et al<sup>2</sup> in 2009 described the cortical bone trajectory (CBT) with the aim of maximizing the pullout resistance in osteoporotic bone. CBT screws offer a less invasive technique that maintains similar mechanical properties as traditional PS instrumentation.<sup>3-10</sup>

The large majority of arthrodesis using the CBT screw technique comes from degenerative spine disease.<sup>11</sup> However, the degenerative process does not always allow for easy and perfect identification of the pars interarticularis. Even more, every patient's vertebra is slightly different from one another, making it difficult to standardize the perfect screw trajectory.<sup>12</sup>

Accurate screw placement in spinal surgery has always been a challenge for surgeons. Many technologies and useful tools have been developed in the recent years, for example, the use of fluoroscopy to help the well-known freehand technique, navigation software,<sup>13</sup> electrical conductivity-based system, neuro-monitoring,<sup>14,15</sup> and the custom-made template guides.<sup>16</sup>

With this study, the capacity of a preoperative computed tomography (CT) scan-based plan to customize the CBT screw placement in patients with degenerative lumbar pathology is evaluated.

#### Key words

- Cortical bone trajectory
- Lumbar arthrodesis
- Lumbar spine surgery
- Minimally invasive surgery
- Planning

#### Abbreviations and Acronyms

- 3D:** Three-dimensional  
**CBT:** Cortical bone trajectory  
**CT:** Computed tomography  
**MAS PLIF:** Maximum Access Surgery Posterior Lumbar Interbody Fusion  
**MAS TLIF:** Maximum Access Surgery Transforaminal Lumbar Interbody Fusion

**MPR:** Multiplanar reconstruction

**PS:** Pedicle screw

Section of Neurosurgery, Department of Neuroscience, University of Turin, Turin, Italy

To whom correspondence should be addressed: Salvatore Petrone, M.D.  
 [E-mail: svt.petrone@gmail.com]

Citation: *World Neurosurg.* (2019) 126:e1468-e1474.

<https://doi.org/10.1016/j.wneu.2019.03.121>

Journal homepage: [www.journals.elsevier.com/world-neurosurgery](http://www.journals.elsevier.com/world-neurosurgery)

Available online: [www.sciencedirect.com](http://www.sciencedirect.com)

1878-8750/\$ - see front matter © 2019 Elsevier Inc. All rights reserved.

## MATERIAL AND METHODS

### Preoperative Planning

For all patients undergoing a CBT fixation, a thin slice CT scan (sliced equal to or thinner than 1 mm) was acquired using a low-dose protocol (kilovolt peak 120 kV or higher, X-ray tube current 30 mA or higher, exposure time 500 milliseconds or more, field of view: approximately 15 cm).

The images obtained were then processed using the Horos © software image viewer. In a 3-dimensional (3D) multiplanar reconstruction (MPR) view, the correct entry point was chosen according to both anatomical landmarks, in particular hyper-density of the cortical bone at the pars, and the patient's singular anatomy taking into strong account all 3 planes to define the best trajectory for the single case.

Then the best trajectory of the CBT screws was chosen (Figure 1). The criteria to find the best safe trajectory were as follows:

- Safety first: the screw course must be entirely in the pedicle avoiding getting too close to the inferior and medial edges of the pedicle
- Minimum screw length: 35–40 mm (try to maximize screw length)
- Minimum screw diameter: 5.5 mm (try to maximize bone purchase)
- Try to catch the most cortical bone that it can be found on the CT scan.

Once the following rules are applied, a line that resembles the screw is drawn from the chosen entry points. Next, a 3D volume

rendering reconstruction is performed. The 3D viewer is set with the following parameters:

- Graphics processing unit processor
- Maximum level of detail is chosen
- “Bone CT-white and black” preset imaging.

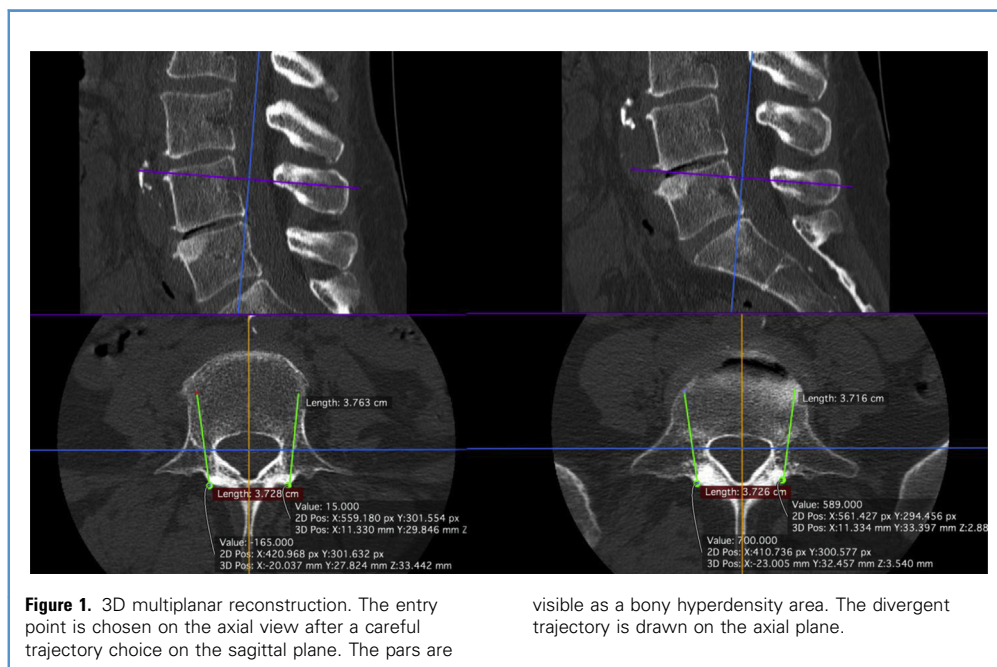
Having set all the above settings, an image is created; to capture the best definition, it is necessary to adjust the gray gradation until the vertebra bone is nicely seen without surrounding artifacts.

At this point, the entry points chosen on the 3D curved MPR view should be visible on the 3D volume rendering reconstruction (Figure 2). It is possible to check their positions relative to the vertebrae anatomical pars and eventually modify their location. The screw dimensions are then chosen on the 3D MPR after having made all the necessary changes in the entry point and directions.

### Surgical Technique

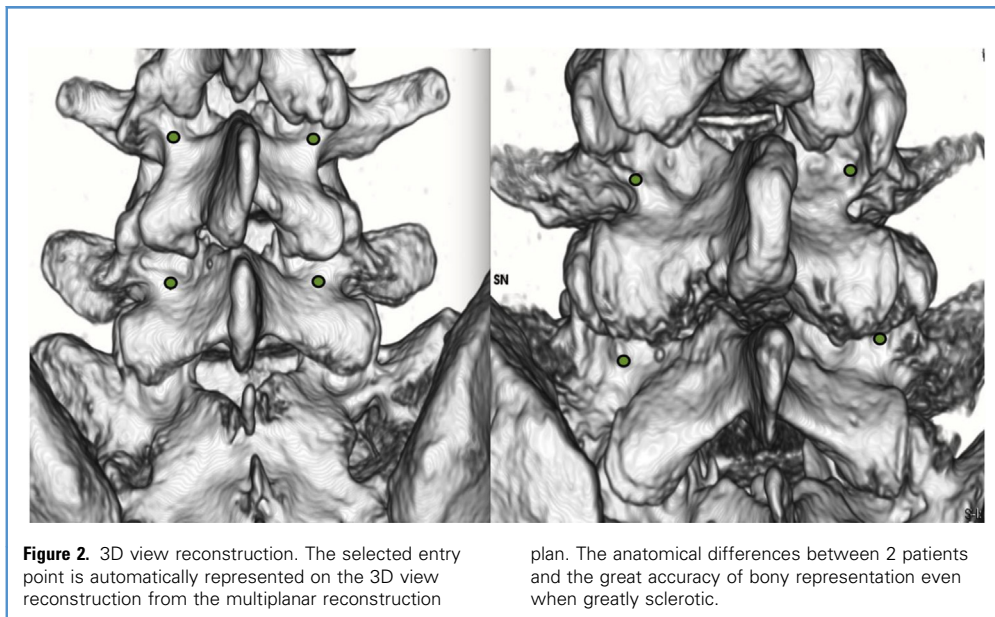
After standard antibiotic prophylaxis, the patient, under general anesthesia, is placed in a prone position on appropriate padded support to avoid increased intra-abdominal pressure. Skin preparation and sterile draping are performed. All the procedures are performed under continuous neuromonitoring and with triggered electromyography to safely ensure screw placement.

Under fluoroscopic guidance, the upper vertebra spinous process is identified and 5 cm skin incision is performed. The spinous processes and laminae are exposed with preservation of the cranial facet joint. Then a size and length-adapted self-retaining retractor with an integrated lighting system is positioned.<sup>17</sup> In vivo, it is possible to recognize the same bony landmarks seen in the 3D



**Figure 1.** 3D multiplanar reconstruction. The entry point is chosen on the axial view after a careful trajectory choice on the sagittal plane. The pars are

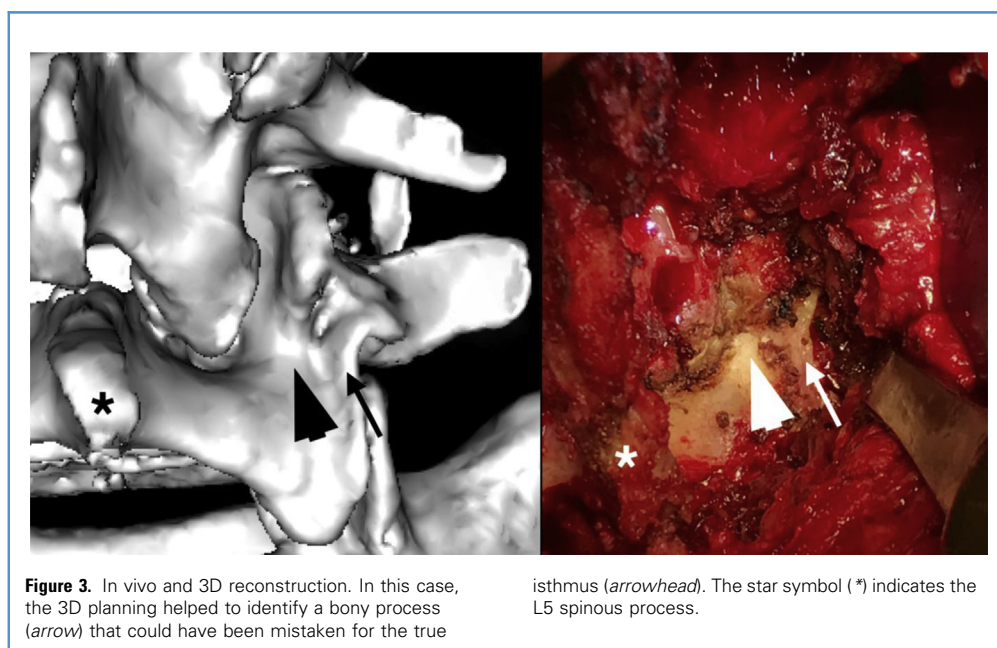
visible as a bony hyperdensity area. The divergent trajectory is drawn on the axial plane.



view. The entry point is then chosen according to the plan. In fact, the 3D reconstruction shows the minimal details of the actual intraoperative vertebral bone, and the entry point is recognized according to bony landmarks chosen during the planning process (Figure 3). The craniocaudal trajectory is based on the intraoperative fluoroscopy (usually approximately 25° cranially) to maximize thread contact with the cortical bone surface. On the other hand, the degree of divergence is decided during the

preoperative planning and pursued during surgery despite no certain landmarks.

The cortical bone at the point of entry is penetrated 10 mm deep using a high-speed drill, and then a hand drill is used to complete the trajectory. The pathway is palpated with a fine ball-tipped probe to both look for breaches and measure screw length.<sup>10</sup> Tapping is performed, and the screw is inserted by hand. The CBT screws used in this study (Maximum Access Surgery



Posterior Lumbar Interbody Fusion [MAS PLIF] or Maximum Access Surgery Transforaminal Lumbar Interbody Fusion [MAS TLIF]; NuVasive, San Diego, California, USA) are inserted without tulips to allow surgeons to easily perform decompression and insert posterior cages, without the bulk of the tulip screw heads (only when performing CBT PLIF or TLIF).<sup>10</sup>

This technique benefits from intraoperative neuromonitoring. In this study, the instrumentation set used (MAS PLIF or MAS TLIF; NuVasive) provides the possibility of monitoring every tool from the hand drill to the screw itself.

## RESULTS

We retrospectively evaluated 82 patients who underwent a single level TLIF/PLIF with CBT screws (Table 1). All the patients underwent preoperative CT scans of the segments involved. With 3D volume rendering reconstruction and 3D curved MPR, the optimal entry point and screw trajectory were planned for each patient. A postoperative CT study was performed to assess the concordance between the actual and planned trajectory (Figure 4). Due to the anatomical features of the pedicle and the great degeneration of the facet joints, three patients were excluded from the study. In preoperative planning, the screws would not have been sufficiently long and divergent. They underwent PS fixation.

Among 82 patients, a total of 328 screws were positioned. The average entry point distance from the target was 1.1 mm with a standard deviation of 0.15 mm. In 301 screws (91.8%), the actual trajectory was included in a cone diverting no more than 2° from the planned trajectory calculated on the craniocaudal and mediolateral angles. Only in 2 patients, with a total of 5 screws (1.5%), the length was changed, using a shorter size. This diversion from planned was caused by a lowering threshold found during neuromonitoring in screw placement (Figure 5). Twelve screws (3.6%) were found to have intercepted the cortical bone at a grade 1 of the Raley classification.<sup>18</sup> No screws misplaced required delayed surgical repositioning and no new neurological deficit was recorded.

**Table 1.** Sample Description and Results

|   |                                     |
|---|-------------------------------------|
| Number of patients                                  | 82                                  |
| Male:female   | 43:39                               |
| Age (average)                                       | 57 (40–72) years                    |
| Number of screws                                    | 328                                 |
| L3–L4 level, number of patients (%)                 | 4 (5%)                              |
| L4–L5 level, number of patients (%)                 | 45 (55%)                            |
| L5–S1 level, number of patients (%)                 | 33 (40%)                            |
| Mean deviation from the planned entry point         | 1.1 mm (standard deviation, 1.5 mm) |
| Screw trajectory accuracy, %                        | 91.8% (n = 301)                     |
| Raley pedicle break classification (grade I), n (%) | 12 (3.6%)                           |
| Undersized screws, n (%)                            | 5 (1.5%)                            |

## DISCUSSIONS

New technologies are helping in the planning process and in the procedure development, leading to a customized approach and personal cure. During the past few decades, several tools have been developed to improve screw placement safety and accuracy like, above all, 3D navigation.<sup>13</sup> This technology has advanced because of the high-speed software evolved to integrate data, but questions still remain about the concrete advantage of using navigation against the freehand fluoroscopy-assisted technique, especially considering costs and availability in spine centers.

With the help of thin sliced CT scan, 3D bone reconstruction is accurate to the minimal details. Also, most of the standard image viewers (Osirix ©, Horos ©) come with multiplanar reconstruction plugin that allows accurate planning of the screw trajectory.<sup>19</sup> The 3D printing era brought most surgical fields to an advanced new level where even minimal differences from standard anatomy are detected and taken into account.<sup>16</sup>

It is common, at our institution, to have all the patients planned for spinal stabilization and fusion undergo a preoperative CT scan to check for bone quality and defects. Thus, changing the protocol to a thin sliced, localized, and low-dose CT scan does not expose the patients to increased radiation exposure. Also, during the procedure, the use of fluoroscopy greatly decreased compared with the cases performed without 3D planning. In fact, the first lateral and all of the anterior-posterior views to check the entry point and mediolateral trajectory were discarded.

Using accurate preoperative 3D planning with free software can be a helpful aid to degenerative surgery avoiding the costs and technical difficulties of navigation systems.

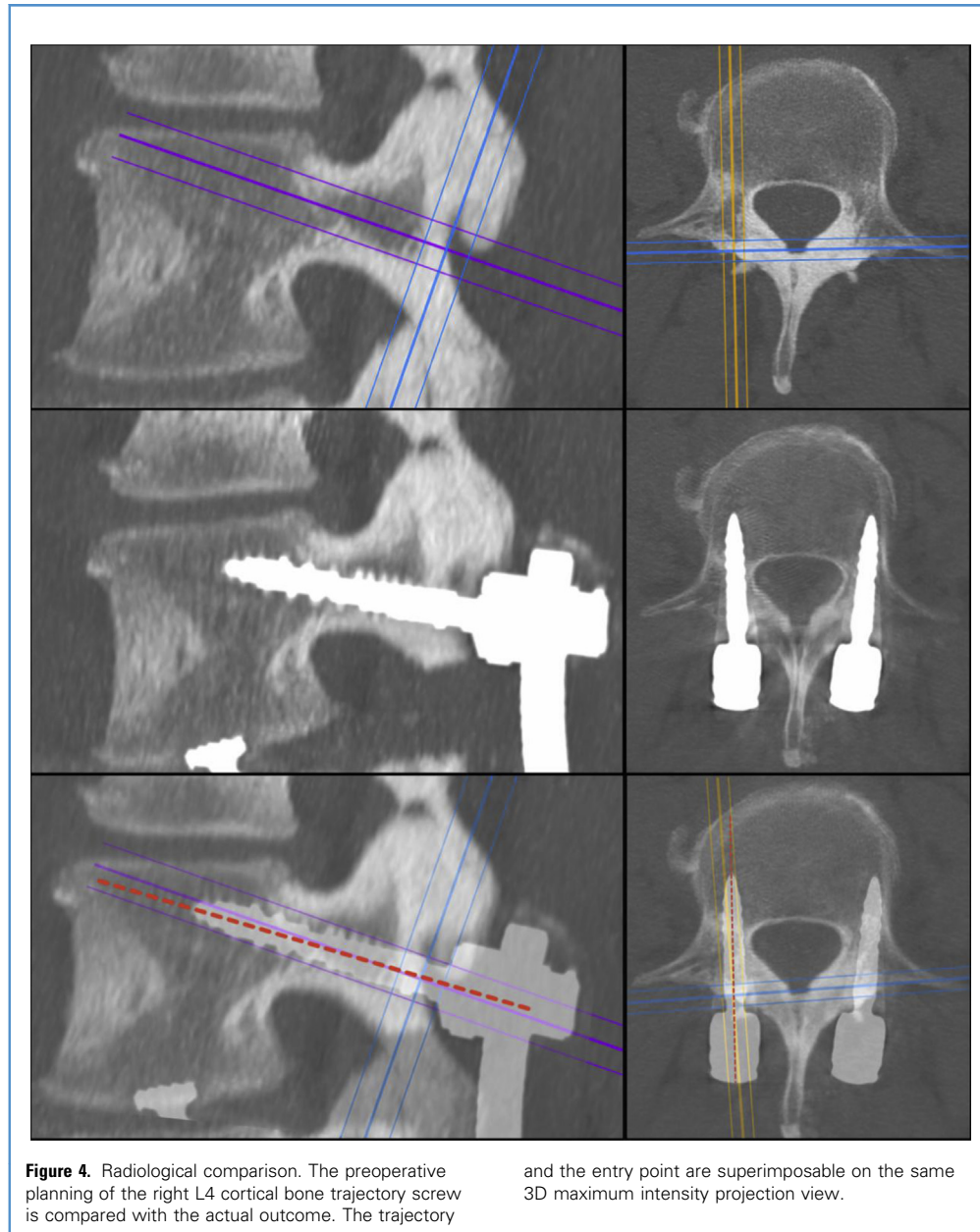
The CBT screw placement is a great alternative to classical PS,<sup>10</sup> but the identification of the entry point and the appropriate direction can be tricky especially to the surgeons just at the beginning in the use of this technique. With the above-mentioned preoperative planning, the surgeon is able to recognize and predict slight anatomical differences, even in the more degenerative spines. The size of the screw can be predicted, avoiding oversizing or undersizing of the screw.

The particular screws used at our institution did not interfere with the decompressive process. Screws without a tulip occupy a very limited volume, exactly on the screw entry point. Starting the procedure with decompression not only might alter the bony anatomy, but also the correct entry point might be accidentally disrupted. The CBT screws have always been placed by the surgeons working in our department before decompression, and also in larger series with longer follow-up, no patient underwent a second surgery for symptomatic stenosis.<sup>10</sup>

Because not all the patients are good candidates for CBT screws, for example those where their pars are not recognizable, the preoperative 3D reconstruction makes it clear before bringing the patient in the operating room avoiding any intraoperative changes of technique. The theoretical trajectory of CBT screws can be replaced with a new customized trajectory, which is able to give the better construct to each singular patient.

Comparing the results obtained with the data previously published by our group<sup>10</sup> without the use of preoperative 3D planning, the amount of intraoperative complications is significantly lower: 4 of 418 (0.95%) screws required delayed surgical repositioning





with standard surgery compared with zero of 328 (0%) screws with preoperative planning.

The accuracy of the described technique seems to be higher than or comparable to others described in the literature.<sup>20-23</sup> Dayani et al<sup>24</sup> described their experience reporting lower screw placement accuracy; however, they did not seem to use any preoperative 3D-reconstruction-based planning. Comparing CBT and PS, the misplaced rates reported to insert freehand lumbar PS vary from 5% to 41%, whereas data from the robot-assisted PS placement resemble the results obtained in

our study.<sup>25</sup> Keorochana et al<sup>26</sup> reported no statistically significant difference in intraoperative complication between the 2 techniques; however, they did not mention the exact accuracy rate difference. Overall, it seems that our percentages are comparable with the higher accuracy reported for the robot-assisted PS placement. Accurately planning the procedure led to no mistakes in the screw placement; the worst screw placement with the planning was a grade 1 of the Raley classification. In the 3 patients where the anatomy was not favorable, where the pars were not identifiable on the 3D reconstruction, or

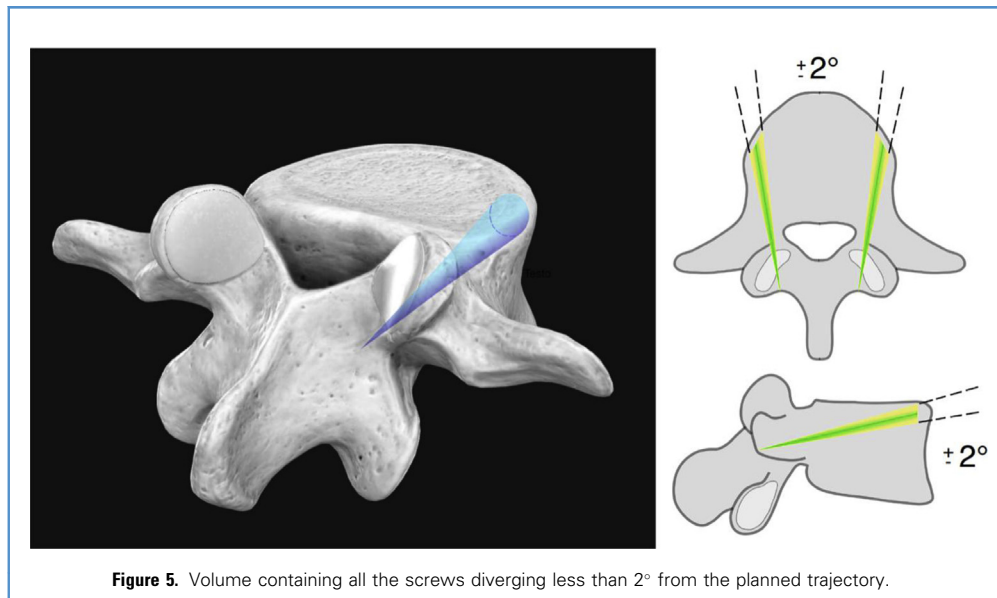


Figure 5. Volume containing all the screws diverging less than 2° from the planned trajectory.

where the planned screw trajectory could not be divergent for pedicle/entry point geometrical relations, surgery was preoperatively converted to classical PS stabilization.

## CONCLUSIONS

The outcomes obtained from preoperative 3D CT planning in the use of cortical bone trajectory screws are promising. It is

possible to create a valid bony 3D reconstruction model and a customized entry point and trajectory. This virtually cost-free technique is of great help in the customization of care in spine surgery with very little technology needed. The results obtained underlined the radiological reliability of this planning technique; however, more studies need to be performed.

## REFERENCES

- Snyder LA, Martinez-Del-Campo E, Neal MT, et al. Lumbar spinal fixation with cortical bone trajectory pedicle screws in 79 patients with degenerative disease: perioperative outcomes and complications. *World Neurosurg.* 2016;88:205-213.
- Santoni BG, Hynes RA, McGilvray KC, et al. Cortical bone trajectory for lumbar pedicle screws. *Spine J.* 2009;9:366-373.
- Than KD, Mummaneni PV, Bridges KJ, et al. Complication rates associated with open versus percutaneous pedicle screw instrumentation among patients undergoing minimally invasive interbody fusion for adult spinal deformity. *Neurosurg Focus.* 2017;43:E7.
- Gejo R, Matsui H, Kawaguchi Y, Ishihara H, Tsuji H. Serial changes in trunk muscle performance after posterior lumbar surgery. *Spine (Phila Pa. 1976).* 1999;24:1023-1028.
- Kojima K, Asamoto S, Kobayashi Y, Ishikawa M, Fukui Y. Cortical bone trajectory and traditional trajectory—a radiological evaluation of screw-bone contact. *Acta Neurochir (Wien).* 2015;157:1173-1178.
- Matsukawa K, Yato Y, Kato T, Imabayashi H, Asazuma T, Nemoto K. In vivo analysis of insertional torque during pedicle screwing using cortical bone trajectory technique. *Spine (Phila Pa 1976).* 2014;39:E240-E245.
- Matsukawa K, Yato Y, Imabayashi H, Hosogane N, Asazuma T, Nemoto K. Biomechanical evaluation of the fixation strength of lumbar pedicle screws using cortical bone trajectory: a finite element study. *J Neurosurg Spine.* 2015; 23:471-478.
- Marengo N, Ajello M, Pecoraro MF, et al. Cortical bone trajectory screws in posterior lumbar interbody fusion: minimally invasive surgery for maximal muscle sparing—a prospective comparative study with the traditional open technique. *BioMed Res Int.* 2018;2018:7424568.
- Gautschi OP, Garbossa D, Tessitore E, et al. Maximal access surgery for posterior lumbar interbody fusion with divergent, cortical bone trajectory pedicle screws: a good option to minimize spine access and maximize the field for nerve decompression. *J Neurosurg Sci.* 2017;61: 335-341.
- Marengo N, Berjano P, Cofano F, et al. Cortical bone trajectory screws for circumferential arthrodesis in lumbar degenerative spine: clinical and radiological outcomes of 101 cases. *Eur Spine J.* 2018;27(suppl 2):213-221.
- Ninomiya K, Iwatsuki K, Ohnishi YI, Ohkawa T, Yoshimine T. Significance of the pars interarticularis in the cortical bone trajectory screw technique: an in vivo insertional torque study. *Asian Spine J.* 2016;10:901-906.
- Senoglu M, Karadag A, Kinali B, et al. Cortical bone trajectory screw for lumbar fixation: a quantitative anatomic and morphometric evaluation. *World Neurosurg.* 2017;103:694-701.
- Mason A, Paulsen R, Babuska JM, et al. The accuracy of pedicle screw placement using intraoperative image guidance systems. *J Neurosurg Spine.* 2014;20:196-203.
- Parker SL, Amin AG, Farber SH, et al. Ability of electromyographic monitoring to determine the presence of malpositioned pedicle screws in the lumbosacral spine: analysis of 2450 consecutively placed screws. *J Neurosurg Spine.* 2011;15:130-135.
- Cofano F, Zenga F, Mammi M, et al. Intraoperative neurophysiological monitoring during spinal surgery: technical review in open and minimally invasive approaches. *Neurosurg Rev.* 2018.
- Wilcox B, Mobbs RJ, Wu A-M, Phan K. Systematic review of 3D printing in spinal surgery: the current state of play. *J Spine Surg.* 2017;3:433-443.
- Berjano P, Damilano M, Ismael M, Formica C, Garbossa D. Erratum to minimally invasive PLIF with divergent, cortical trajectory pedicle screws. *Eur Spine J.* 2015;24:2096.

18. Raley DA, Mobbs RJ. Retrospective computed tomography scan analysis of percutaneously inserted pedicle screws for posterior transpedicular stabilization of the thoracic and lumbar spine: accuracy and complication rates. *Spine (Phila. Pa. 1976)*. 2012;37:1092-1100.
19. Yamauchi T, Yamazaki M, Okawa A, et al. Efficacy and reliability of highly functional open source DICOM software (OsiriX) in spine surgery. *J Clin Neurosci*. 2010;17:756-759.
20. Lamartina C, Cecchinato R, Fekete Z, Lipari A, Fiechter M, Berjano P. Pedicle screw placement accuracy in thoracic and lumbar spinal surgery with a patient-matched targeting guide: a cadaveric study. *Eur Spine J*. 2015;24(Suppl 7):937-941.
21. Kaito T, Matsukawa K, Abe Y, Fiechter M, Zhu X, Fantigrossi A. Cortical pedicle screw placement in lumbar spinal surgery with a patient-matched targeting guide: a cadaveric study. *J Orthop Sci*. 2018.
22. Aoude AA, Fortin M, Figueiredo R, Jarzem P, Ouellet J, Weber MH. Methods to determine pedicle screw placement accuracy in spine surgery: a systematic review. *Eur Spine J*. 2015;24:990-1004.
23. Gertzbein SD, Robbins SE. Accuracy of pedicular screw placement in vivo. *Spine (Phila. Pa. 1976)*. 1990;15:11-14.
24. Dayani F, Chen YR, Johnson E, et al. Minimally invasive lumbar pedicle screw fixation using cortical bone trajectory—screw accuracy, complications, and learning curve in 100 screw placements. *J Clin Neurosci*. 2018;61:106-111.
25. Fan Y, Du JP, Liu JJ, et al. Accuracy of pedicle screw placement comparing robot-assisted technology and the free-hand with fluoroscopy-guided method in spine surgery. *Medicine (United States)*. 2018;97:1-7.
26. Keorochana G, Pairuchvej S, Trathitaphun W, Arirachakaran A, Predeeprompan P, Kongtharvonskul J. Comparative outcomes of

cortical screw trajectory fixation and pedicle screw fixation in lumbar spinal fusion: systematic review and meta-analysis. *World Neurosurg*. 2017;102:A6.

*Conflict of interest statement:* The authors declare that the article content was composed in the absence of any commercial or financial relationships that could be construed as a potential conflict of interest.

Received 17 December 2018; accepted 12 March 2019

Citation: *World Neurosurg*. (2019) 126:e1468-e1474.

<https://doi.org/10.1016/j.wneu.2019.03.121>

Journal homepage: [www.journals.elsevier.com/world-neurosurgery](http://www.journals.elsevier.com/world-neurosurgery)

Available online: [www.sciencedirect.com](http://www.sciencedirect.com)

1878-8750/\$ - see front matter © 2019 Elsevier Inc. All rights reserved.